



# Efficacy and Safety of Using Noninsulated Microneedle Radiofrequency Alone Versus in Combination with Polynucleotides for the Treatment of Melasma: A Pilot Study

Ma. Christina B. Gulfan · Rungsima Wanitphakdeedecha ·  
Supisara Wongdama · Nuttagarn Jantanapornchai · Chadakan Yan ·  
Sarawalai Rakchart

Received: February 12, 2022 / Accepted: April 8, 2022 / Published online: May 11, 2022  
© The Author(s) 2022

## ABSTRACT

**Introduction:** This split-face, double-blind, randomized controlled study investigated the efficacy and safety of using a microneedling radiofrequency (RF) device with polynucleotides (PN) versus RF alone for the treatment of melasma.

**Methods:** Thirty adult participants with melasma (Fitzpatrick skin types III–V) received three treatments with an invasive, bipolar, pulsed-type microneedling RF device on both sides of the face. The treatment sessions occurred once every 2 weeks. The hemifaces of each participant were designated for treatment and control with PN and normal saline solution (NSS), applied after treatment with RF. Measurements were made of melanin index (MI), erythema index (EI), skin roughness (by the Antera 3D system), modified melasma area severity index (mMASI) for each hemiface, and patients' self-assessed improvement. These occurred at baseline and again following the

final treatment (2 weeks and 1, 2, 3, and 6 months after). Mean values were obtained for MI, EI, skin roughness, and mMASI. A generalized estimating equation (GEE) was used to compare the obtained values for the outcome measures across all assessment points.

**Results:** All patients were women (mean age,  $43.2 \pm 7.0$  years). Mixed melasma predominated (61.5%;  $n = 16$ ), and the mean duration of melasma was  $8.9 \pm 6.5$  years. Twenty-six participants were followed up to the 6-month assessment point. Significant improvements were observed from baseline in MI, skin roughness, and mMASI scores for both the PN and control sides at 6 months, with no statistically significant differences between sides. Patients' self-assessed improvement scores also showed a positive trend. Melasma recurrence was observed in three patients at 2, 3, and 4 months after the last treatment session (10% recurrence rate).

**Conclusions:** The combination of an invasive, bipolar, pulsed-type microneedling RF with PN is not superior compared with microneedling RF alone in the treatment of melasma. Microneedling RF may be considered as safe and efficacious for the improvement of skin roughness, and as an adjunctive treatment option for melasma.

**Clinical Trial Registration:** This study was registered on ClinicalTrials.gov and assigned NCT number TCTR20210804002.

---

Ma. C. B. Gulfan · R. Wanitphakdeedecha (✉) ·  
S. Wongdama · N. Jantanapornchai · C. Yan  
Department of Dermatology, Faculty of Medicine  
Siriraj Hospital, Mahidol University, Bangkok,  
Thailand  
e-mail: rungsima.wan@mahidol.ac.th

S. Rakchart  
Innovative Skin and Laser Surgery (iSKY) Center,  
Bangkok, Thailand

**Keywords:** Chloasma; Disorder of pigmentation; Melasma; Microneedling; Polynucleotide; Pulsed radiofrequency

### Key Summary Points

#### *Why carry out this study?*

Despite the abundance of preexisting studies on various treatment modalities and therapeutic agents, complete resolution and long-term control of melasma remain elusive.

Radiofrequency has been shown to produce dermal changes in melasma lesions, whereas polynucleotides have been investigated for antimelanogenesis effects.

This study aimed to compare the efficacy of a pulsed, bipolar, microneedling radiofrequency device combined with polynucleotides versus radiofrequency alone for the treatment of melasma.

#### *What was learned from the study?*

Improvements in objective and subjective outcome measures were observed in 26 patients after 3 treatments at 2-week intervals. Recurrence of melasma was observed in three patients at 2, 3, and 4 months after the last treatment.

Pulsed, bipolar, microneedling radiofrequency with polynucleotides was not superior to microneedling radiofrequency alone in the treatment of melasma.

Microneedling radiofrequency may be considered as a safe adjunctive treatment option for melasma.

macules and patches on the central, malar, or mandibular areas of the face. It affects predominantly, but not exclusively, middle-aged women with darker Fitzpatrick skin phototypes. Ultraviolet (UV) radiation, female sex hormones, inflammation, and genetic predisposition are primary drivers of this disease. Its histopathological characteristics include increased melanin in keratinocytes and macrophages, increased mast cells, dilated vessels in the dermis, solar elastosis, and a disrupted basement membrane [1]. Such findings have recently led to the proposal that melasma is not only a disease of melanocytes but also a photoaging skin disorder, with treatment modalities such as laser and light systems, and energy-based devices aiming to address this aspect being proposed as possible options [2, 3].

Melasma has proven challenging to treat due to its chronicity, a tendency to relapse, and inherent recalcitrance. Topical depigmenting agents and the judicious use of broad-spectrum sunscreens with visible light coverage remain the first line and mainstay of treatment. The second line consists of supplementation with chemical peels. Lasers and light-based modalities are considered third-line treatment options, best suited for refractory cases. Among these, intense pulsed light, Q-switched lasers, picosecond lasers, and fractionated resurfacing lasers, both ablative and nonablative, have been studied extensively [4]. However, they have produced variable results, with recurrence, postinflammatory hyperpigmentation (PIH), and rebound hyperpigmentation limiting their widespread application.

Radiofrequency (RF) devices initially became popular due to their efficacy in skin tightening and rejuvenation, with a high safety profile in darker skin phototypes and minimal posttreatment recovery time [5]. With delivery through microneedles, electrical currents reach deeper target tissues at a predictable penetration depth [6, 7]. Advances in technology enabled the delivery of pulsed-type RF, which produces thermal and nonthermal effects through gated RF oscillations, in contrast to continuous-type RF that produces thermal ablative effects by continuous delivery of high-frequency energy over set conduction times [6, 8]. Its thermal and

## INTRODUCTION

Melasma is a common acquired pigmentation disorder characterized by tan to dark-brown

nonthermal effects, together with deeper tissue penetration, have led to the use of pulsed-type microneedling RF in the treatment of refractory melasma [9, 10]. Proposed theories behind the observed improvement of melasma were enhanced permeability to topical treatments, and dermal effects ranging from changes in lesion vasculature and melanin washout [9], to neocollagenesis and repair of damaged basement membranes [10]. Studies that followed attributed RF's efficacy to the observed loosening of melanocyte–keratinocyte attachments, promoting transdermal melanin elimination [11], and thermo-modulated shrinkage of CD31-positive blood vessels with decreased VEGF-A mRNA expression [8]. Radiofrequency reversed cellular and gene mediators of dermal senescence [12], repaired basement membranes, and reduced melanogenesis markers of the microphthalmia-associated transcription factor (MITF) pathway [13]. As melasma's pathogenesis involves an interplay of various factors, the definitive role of RF in its treatment remains to be validated.

Polynucleotides (PN) are highly purified natural DNA molecules comprising deoxyribonucleotide polymers of 50–200 base pairs [14]. Polynucleotides possess antiinflammatory, antiischemic, proangiogenic, and stimulatory effects on various cells [15]. Their capacity to accelerate tissue repair and regeneration led to aesthetic applications in rejuvenation of the face and body [16]. Their antimelanogenesis and skin-whitening properties were investigated by Noh et al. [17]. In the *in vitro* arm of the study, human melanocytes were incubated with polydeoxyribonucleotide. Decreased melanin synthesis and intracellular tyrosinase levels were observed. In the clinical study arm, lightening of lesions was observed in six patients (three with melasma, two with mottled pigmentation, and one with pigmented contact dermatitis) after receiving intradermal injections of polydeoxyribonucleotide every 4 weeks for a total of three treatment sessions. The study demonstrated that polydeoxyribonucleotides suppressed melanogenesis via reduction of MITF signaling and its downstream targets [17]. Similar findings were obtained in an *in vitro* study by Kim et al. [18], further demonstrating

PN's antimelanogenesis property. However, more clinical studies are needed to confirm PN's role in the treatment of melasma.

Given that the pathogenesis of melasma is complex and involves an interplay of photoinduced changes such as solar elastosis, increased vascularity, and cellular signaling pathways leading to increased melanogenesis, the avenue of treatment modalities that could potentially address these factors remains to be explored. Thus, the present study aimed to investigate the efficacy and safety of pulsed microneedle RF in combination with PN for the treatment of melasma.

## METHODS

### Subjects and Ethics

This pilot study was conducted at the Siriraj Skin Laser Center, Faculty of Medicine Siriraj Hospital, Mahidol University, Bangkok, Thailand. Thirty volunteer subjects were initially enrolled. They were between 18 and 60 years old, had Fitzpatrick skin types III to V, and had been diagnosed with bilateral facial melasma by a board-certified dermatologist. A Wood's lamp examination was performed to determine the type of melasma of each volunteer. Patients were not enrolled if they were pregnant, had an active infection or inflammatory dermatoses on the face, had a history of keloid or hypertrophic scar formation, or were taking oral anticoagulant or antiplatelet medications. Individuals were also excluded if they used topical treatments for melasma in the past month or received laser or light-based treatments for the face during the past 6 months.

Before this research began, its protocol was approved by the Ethics Committee of the Siriraj Institutional Review Board, Faculty of Medicine Siriraj Hospital, Mahidol University (reference number 409/2563). The study adhered to the guidelines of the Declaration of Helsinki of 1964 and its later amendments. Written informed consent was obtained from all study subjects. In addition, this work was registered with the Thai Clinical Trials Registry (identification number TCTR20210804002).

Before initiating RF treatment, block randomization was used to assign one side of the face of each participant to RF plus PN treatment. The contralateral side became the control and was treated with RF plus normal saline solution (NSS).

## Materials

The RF device was an invasive pulsed-type bipolar RF with noninsulated needles (SYLFIRM; Viol, Kyunggi, Korea). Pulsed-type RF was delivered at a frequency of 2 MHz, with a 10 × 10 mm disposable tip comprising 25 noninsulated, penetrating microneedles in a uniform 5 × 5 array. The microneedles were made of surgical stainless steel, each 0.3 mm thick and 3.5 mm long. The parameters for each treatment session were as follows: first pass (whole face): level II, 1.5-mm penetration depth; second pass (over melasma lesions only): level II, 1.5 mm penetration depth; third pass (whole face): level II, 0.8 mm penetration depth. Each pass was done with 10–30% overlap.

A transparent, colorless, and odorless liquid containing 0.3% PN as the primary component (REVS-NCFS 140 HPn; Reanzen, Gyeonggi-do, Korea) was used as the topical product for the designated treatment hemiface. At each treatment session, the designated hemiface received 3–5 drops (approximately 0.2 ml) of the PN.

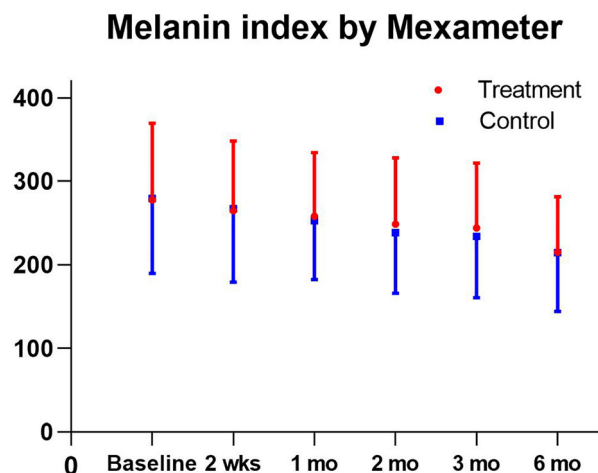
## Treatment Protocol

Before each treatment session, 2.5% lidocaine and 2.5% prilocaine cream (Liprikaine; T. Man Pharma Company Ltd., Bangkhunthian, Thailand) was applied under occlusion for 1 h. The participants were then asked to wash and dry their faces thoroughly, and the treatment areas were then cleaned with alcohol immediately before receiving RF treatment. Each patient received three passes of the RF treatment as previously described, with the treatment endpoint of mild erythema. Upon completion of the RF treatment, a research associate not involved with evaluation applied the PN and NSS to the designated hemifaces of each

**Table 1** Patient demographics and sum of hemifaces that received PN ( $n = 26$ )

Characteristic	Value ( $N = 26$ )
Age (years), mean $\pm$ SD (min–max)	43.2 $\pm$ 7.0 (24–54)
<i>Sex, n (%)</i>	
Female	26 (100%)
Male	0 (0%)
<i>Melasma type*</i>	
Malar	21 (80.8%)
Centrofacial	5 (19.2%)
Mandibular	5 (19.2%)
<i>Wood's lamp examination</i>	
Mixed	16 (61.5%)
Dermal	5 (19.2%)
Epidermal	5 (19.2%)
<i>Duration of melasma (years)</i>	8.9 $\pm$ 6.5 (2–30)
<i>Previous treatment, n (%)</i>	
Topical drugs	9 (45.0%)
Laser treatment	4 (20.0%)
<i>Sunscreen use, n (%)</i>	
Always	22 (84.6%)
Sometimes	4 (15.4%)
<i>Number of hemifaces that received PN</i>	
Right	13 (50%)
Left	13 (50%)

patient. The treating physicians as well as the patients were unaware of which hemiface received treatment with PN and which served as control. Immediately after the procedure, both treatment and control sides were occluded with a transparent dressing (Tegaderm; 3M Healthcare, St. Paul, MN, USA) for 1 h. Posttreatment instructions were to avoid the sun and apply a broad-spectrum sunscreen daily. The study participants were not allowed to use topical bleaching agents or any form of treatment for



**Fig. 1** Mean Melanin Index (MI) values for treatment (PN) and control (NSS) sides from baseline and across all assessment points

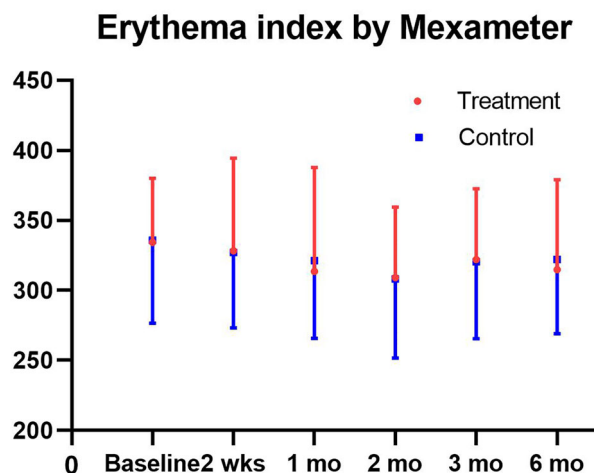
melasma. Treatment sessions were performed at 2-week intervals for a total of three sessions.

## Treatment Evaluations

### Subjective Assessment

Standard digital photographs were obtained at baseline and following the final treatment session (at 2 weeks and 1, 2, 3, and 6 months after). All digital photographs were taken with a facial photo fixture using a Canon PowerShot G9 standoff camera (OMNIA Imaging System; Canfield Scientific, Inc., Fairfield, NJ, USA).

Two blinded physicians independently determined the modified melasma area severity index (mMASI) score of each hemiface at baseline and each follow-up. For a hemiface, calculating the mMASI score is based on the percentage of the area involved (A) and darkness (D) of the lesion, applied to the formula: frontal  $0.15 \times (D \times A) + \text{malar } 0.30 \times (D \times A) + \text{chin } 0.05 \times (D \times A)$  [19]. Area of involvement was rated from 0 to 6, where 0 indicates absent; 1, < 10%; 2, 10–29%; 3, 30–49%; 4, 50–69%; 5, 70–89%; and 6, 90–100%. Darkness was rated from 0 to 4, where 0 indicates absent; 1, slight; 2, mild; 3, marked; 4, severe [20]. Treatment side effects were recorded at each



**Fig. 2** Mean Erythema Index (EI) values for treatment (PN) and control (NSS) sides from baseline and across all assessment points

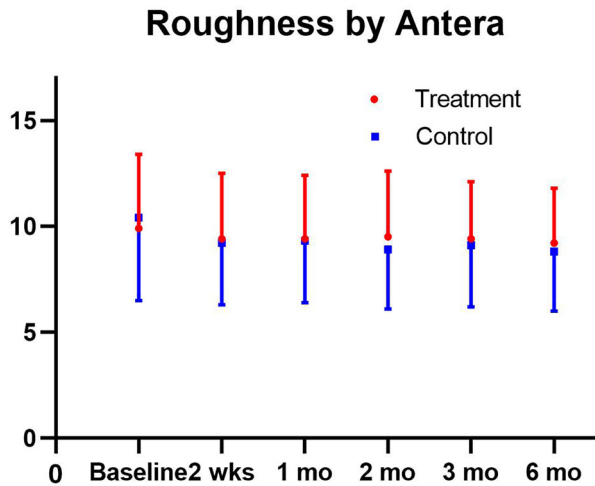
treatment session and follow-up visit. The study participants were also asked to evaluate the degree of improvement of their melasma lesions as slightly better (< 25%), fair (26%–50%), good (51%–75%), and excellent (> 75%). Pain levels during treatment were rated using a visual analog scale ranging from 0 (no pain) to 10 (severe pain).

### Objective Assessment

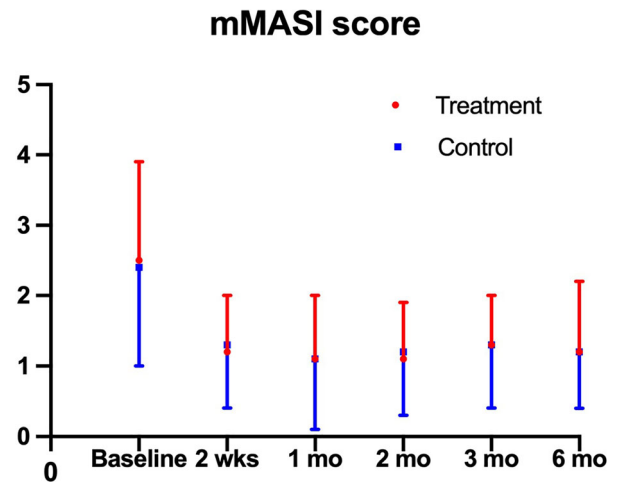
The Melanin Index (MI) and Erythema Index (EI) were measured bilaterally using a Mexameter (Courage–Khazaka, Köln, Germany) at the same assessment time points as above. A translucent sheet was used to mark and map the designated areas on the face for location consistency. Skin roughness was captured using macrophotography using the Antera 3D system (Miravex, Dublin, Ireland).

### Statistical Analyses

Mean values were obtained for the MI, EI, skin roughness, and mMASI scores together with their corresponding standard deviation. Due to the split-face study design, the comparison of MI, EI, skin roughness, and mMASI scores obtained over six time points was assessed using a generalized estimating equation (GEE) with



**Fig. 3** Mean skin roughness scores determined using Antera 3D for treatment (PN) and control (NSS) sides from baseline and across all assessment points



**Fig. 4** Mean Modified Melasma Area and Severity Index scores for treatment (PN) and control (NSS) sides from baseline and across all assessment points

exchangeable correlation structure. Treatment, time, and treatment  $\times$  time interaction were entered as independent variables in the full model. Interaction was found nonsignificant and was thus excluded from the final model. Data were analyzed using PASW Statistics for Windows, version 18.0 (SPSS Inc., Chicago, IL, USA). Significance was set at a value of  $p \leq 0.05$ . Descriptive statistics were used for the improvement evaluations of the participants.

## RESULTS

Of the 30 participants initially enrolled, 26 (86.67%) were included in the analyses. Four patients (13.3%) were excluded from the study: three developed melasma recurrence, and one could not complete follow-up. All study participants were women, with a mean age of  $43.2 \pm 7.0$  years. Mixed melasma predominated (61.5%;  $n = 16$ ), and the mean duration of the disease was  $8.9 \pm 6.5$  years. Fifteen patients received PN on the right hemiface, and 15 received PN on the left hemiface. Demographic characteristics and number of patients randomized to treatment and control sides are summarized in Table 1.

Figures 1, 2, 3, and 4 show means with standard deviation of the MI, EI, skin roughness, and mMASI scores for the PN (treatment) and NSS (control) sides from baseline and the five follow-up time points after the final treatment session, showing a decreasing trend. Comparison of the above outcome measures for the treatment and control sides over six time points was done using a generalized estimating equation, resulting in the values presented in Table 2. Comparing treatment with control, there was no significant difference in the results obtained for MI, EI, skin roughness, and mMASI score based on the obtained  $p$ -values. The MI, EI, skin roughness, and mMASI scores were decreased in both sides compared with baseline. With regards to time point, MI for both treatment and control groups showed a significant decrease starting from 1 month after ( $p = 0.010$ ) through to 6 months after the last treatment session ( $p < 0.001$ ) compared with baseline. Erythema index for both groups showed a significant decrease at 2 months after the last treatment session ( $p = 0.009$ ). Skin roughness and modified MASI scores obtained for both PN and NSS sides were significantly decreased as

**Table 2** Comparison of melanin index, erythema index, mMASI score, and skin roughness over six time points using generalized estimating equation. *b*, regression coefficient

	Melanin index		Erythema index		Skin roughness		mMASI	
	<i>b</i>	<i>p</i> -Value	<i>b</i>	<i>p</i> -Value	<i>b</i>	<i>p</i> -Value	<i>b</i>	<i>p</i> -Value
<i>Group</i>								
Control	−4.917	0.452	−2.450	0.624	−0.158	0.763	0.013	0.784
Treatment	–	–	–	–	–	–	–	–
<i>Time point</i>								
Baseline	–	–	–	–	–	–	–	–
2 weeks	−14.195	0.245	−7.228	0.447	−0.840	0.006*	−1.206	< 0.001*
1 month	−24.187	0.010*	−15.760	0.086	−0.814	0.006*	−1.356	< 0.001*
2 months	−36.350	< 0.001*	−26.126	0.009*	−0.942	0.002*	−1.292	< 0.001*
3 months	−38.231	< 0.001*	−12.808	0.176	−0.881	0.002*	−1.142	< 0.001*
6 months	−63.902	< 0.001*	−13.335	0.300	−1.136	< 0.001*	−1.287	< 0.001*

*b* regression coefficient, *mMASI* Modified Melasma Area and Severity Index

early as 2 weeks until 6 months after the last treatment session.

Figure 5 illustrates the patient evaluations of improvement in their melasma lesions. Subjects in both treatment and control groups rated their improvement as “good to excellent” (51% to ≥ 75%) as early as 2 weeks after the last treatment session, with a gradual and steady increase in the number of patients reporting a higher rating of improvement at 1, 2, and 3 months after the last treatment. This trend continued until the sixth month, and was similar for both treatment and control sides. Figure 6 shows representative clinical photographs of two study participants, with comparisons between assessment points.

All study participants tolerated treatment well, with a reported mean pain score of 2.0 ± 1.8 (minimum, 0; maximum, 6). Only mild, transient erythema was observed after treatment. As mentioned above, recurrence of melasma occurred in three patients (10% recurrence rate) at 2, 3, and 4 months after the last treatment session, respectively. These patients opted to be treated with topical

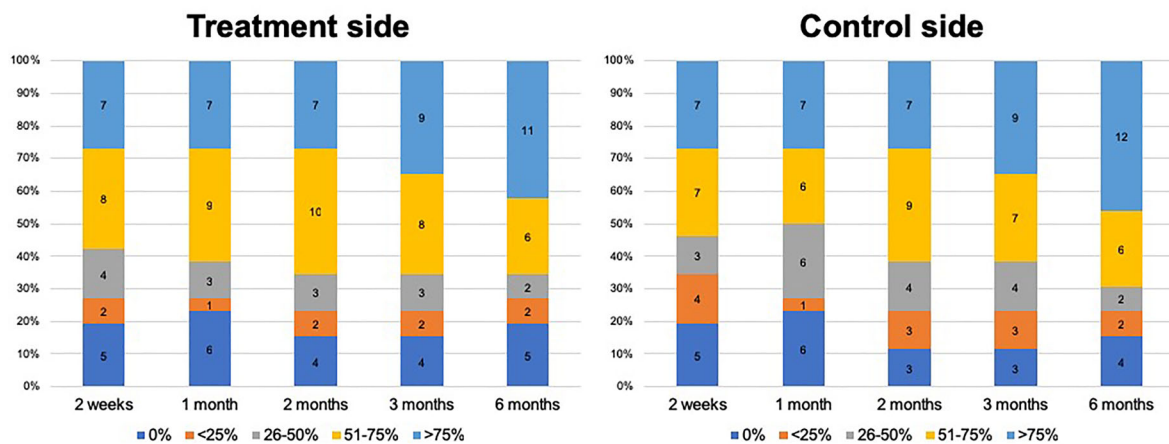
medications and no longer followed up throughout the course of the study.

## DISCUSSION

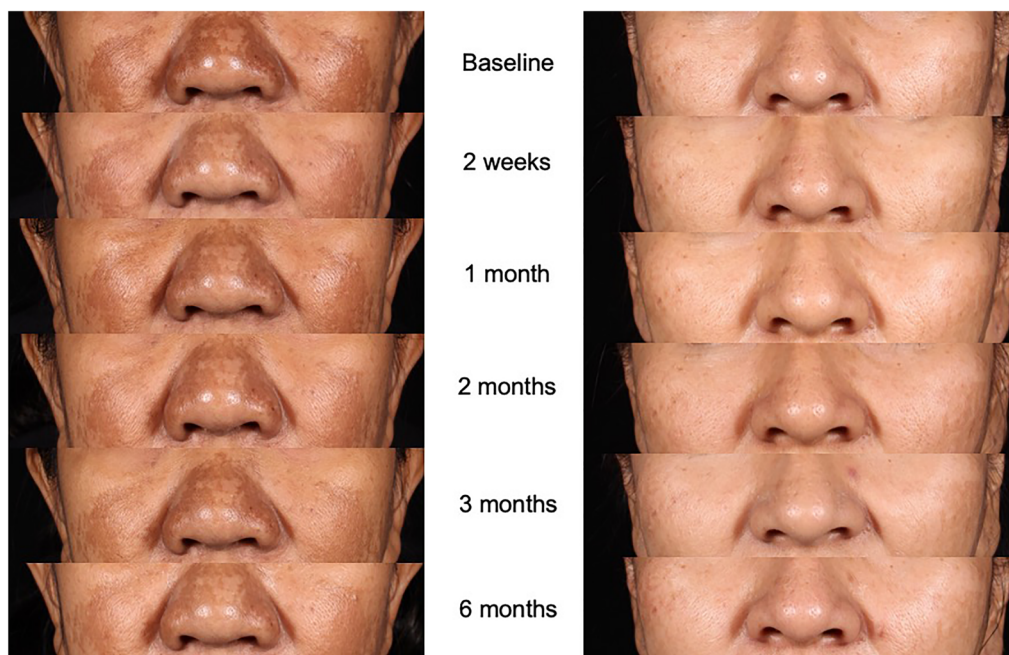
Chronic UV exposure is central to the dermal changes observed in melasma [21]. Metalloproteinases are stimulated by UV, and together with tryptase, type IV collagen is degraded leading to basement membrane disruption [22]. Melanocytes and melanin descend into the dermis, and crosstalk between epidermal melanocytes and dermal senescent fibroblasts [23] leads to the stimulation of melanogenesis [12, 24]. Solar elastosis and granzyme B from mast cells lead to increased vascularity in melasma lesions, a vicious cycle then ensues wherein endothelin-1 produced by endothelial cells further promotes melanogenesis [25]. Given its multifaceted pathogenesis, treatment protocols aimed at addressing the various structural aspects of melasma have been proposed [26].

We present the results of our comparison of the efficacy and safety of noninsulated, bipolar,

## Patients' improvements



**Fig. 5** Patient's subjective evaluation of melasma lesion improvement from baseline across all assessment time points, rated as follows: slightly better (< 25%), fair (26–50%), good (51–75%), and excellent (> 75%)



**Fig. 6** Representative clinical photos of lesions on the malar areas in two study participants. A steady decrease in darkness, area, and homogeneity of patches is noted on both the PN (right) and NSS (left) sides from baseline until

6 months after the last treatment session. For each patient, a similar degree of improvement is seen on the control and treatment sides



pulsed-type microneedle RF with PN versus RF alone to treat melasma. Objective and subjective assessments demonstrated consistent improvement at all follow-up time points compared with baseline. In particular, MI, skin roughness, and the mMASI scores showed significant improvements. There was also a concurrent improvement in the ratings given by participants for their melasma lesions. Furthermore, tolerance of the procedure was reported. More importantly, the degrees of improvement on the control and treatment sides were similar, indicating that efficacy is possible with RF alone. The recurrence however of melasma in three patients indicates that RF treatment may not suffice as monotherapy for melasma.

Our results are in line with those obtained by Park et al. [27], wherein pulsed-type microneedling RF was used to treat melasma in 24 Korean women. Patients received one full-face treatment once a week, every 2 weeks for a total of five treatment sessions. Similar to the current study, decreased MI and EI values were obtained, together with a similar degree of improvement versus baseline in physician and patient ratings. The patients also tolerated the treatment well. In contrast to the current study, melasma recurrence was not observed. A possible reason for this would be the improved efficacy of five microneedling RF treatment sessions compared with three sessions in the current study. Another possibility would be that the current study's longer follow-up led to increased detection of melasma recurrence. The works of Yoon et al. [12] and Lee et al. [13] demonstrated the capacity of microneedling RF to decrease basal epidermal pigmentation, decrease expression of MITF and tyrosinase, reverse UV-induced premature senescence, and restore expression of collagen type IV in the basement membrane, leading to the clinically observed lightening of solar lentigo [12] and age-associated facial pigmentation [13]. The authors believe that the observed lightening of melasma lesions in the current study may be attributed to the aforementioned effects of microneedling RF.

Improved skin roughness in the current study was also observed in melasma studies utilizing microneedling RF as monotherapy [10]

and in combination with Q-switched Nd:YAG (QSNY) laser toning [9, 13, 28]. Improved skin texture and tone was observed after 5–10 treatments at 2–3-week intervals with microneedling RF alone [10]. Combined with QSNY, improvements were achieved after 5–7 weekly treatments [9], and ten treatments done once a week [28] and every 2 weeks [13]. The current study differs in that improved skin roughness as measured by Antera 3D was obtained with three treatment sessions done every 2 weeks. Microneedling RF produces cocoon-shaped zones of subablative thermal injury in the dermis [29]. In turn, this triggers a wound healing response with dermal remodeling, neocollagenesis, and elastogenesis [30]. Clinically, this enhances skin texture, pore size, and brightness [31–33]. These effects may explain the improvement in skin roughness observed in this study.

We were not able to demonstrate added efficacy of PN to microneedling RF. The degree of improvement in MI, EI, and mMASI scores was similar for both control and treatment sides. The main difference between the study by Noh et al. [17] and the current study is the manner of PN delivery. Noh et al. administered PN via intradermal injections, thus possibly facilitating direct placement of PN at the target depth. The current study topically applied PN immediately after microneedling RF treatment, with the purpose of enhancing PN's transdermal delivery. However, there is no certainty that PN did indeed reach the intended target depth upon application after RF microneedling. Polynucleotides have a molecular weight ranging from 50 to 1500 kilodaltons (kDa) [18], and although a microneedling therapy system was used to enhance its delivery in an animal study [34], its skin permeability characteristics have not been directly evaluated.

One of the main limitations of this study is its small sample size. Another would be the lack of concurrent histological and immunohistochemistry studies that would aid in confirming and further characterizing RF's effects. Future studies with a bigger population, together with both histological and immunohistochemical confirmation, are thus warranted. With the observed recurrence of melasma in three of our patients, optimum treatment parameters and

intervals remain to be determined. In addition, more studies on PN are needed to determine a mode of delivery that will be both efficacious and tolerable to the patient.

## CONCLUSIONS

The combination of invasive, bipolar, pulsed-type microneedling RF with PN is not superior compared with microneedling RF alone in the treatment of melasma. Microneedling RF may be considered as safe and efficacious for the improvement of skin roughness, and as an adjunctive treatment option for melasma.

## ACKNOWLEDGEMENTS

**Funding.** This research project was supported by the Faculty of Medicine Siriraj Hospital, Mahidol University. The device was provided by IDS Medical Systems (Thailand) Company Ltd, Thailand, and the medications were provided by GFN Group Company Ltd, Thailand. The journal's Rapid Service Fee was funded by IDS Medical Systems (Thailand) Company Ltd.

**Authorship.** All named authors meet the International Committee of Medical Journal Editors criteria for authorship for this article, take responsibility for the integrity of the work, and have given their approval for this version to be published.

**Author Contributions.** All authors contributed to the study conception and design. Material preparation, data collection, and analyses were performed by Nuttagarn Jantana-pornchai, M.D., Yanisorn Nanchaipruek, Chadakan Yan, Supisara Wongdama, and Sarawalai Rakchart. Rungsima Wanitphakdeedecha had full access to all the data in the study and takes responsibility for the integrity of the data and the accuracy of the data analysis. The first draft of the manuscript was written by Ma. Christina B. Gulfan, and all authors commented on subsequent versions of the manuscript. All

authors read and approved the final manuscript.

**Medical Writing, Editorial, and Other Assistance.** The authors thank Ms. Phonsuk Yamlexnoi, Ms. Chutikan Kiatphansodsai, Ms. Apichaya Jutaphonrakul, and Dr. Surachet Sirisuthivoranunt for their assistance in recruiting subjects and managing the database. The authors would like to express their sincere gratitude to Assistant Professor Chulaluk Komoltri for her assistance with the statistical analysis of this study. The authors also gratefully acknowledge the English-language editing of this paper by Mr. David Park, funded by IDS Medical Systems (Thailand) Company Ltd.

**Disclosures.** Ma. Christina B. Gulfan, Rungsima Wanitphakdeedecha, Supisara Wongdama, Nuttagarn Jantana-pornchai, Chadakan Yan, and Sarawalai Rakchart have nothing to disclose.

**Compliance with Ethics Guidelines.** The study was approved by the Ethics Committee of the Siriraj Institutional Review Board (SI 702/2020). Written informed consent was obtained for the publication and use of all patients' images prior to their enrollment in the study. This study was performed in accordance with the Helsinki Declaration of 1964 and its subsequent amendments. This study was registered on ClinicalTrials.gov and assigned NCT number TCTR20210804002.

**Data Availability.** The datasets generated or analyzed during this study are available from the corresponding author on reasonable request.

**Thanking Patient Participants.** We thank the patients who participated in the study.

**Open Access.** This article is licensed under a Creative Commons Attribution-Non-Commercial 4.0 International License, which permits any non-commercial use, sharing, adaptation, distribution and reproduction in any medium or format, as long as you give appropriate credit to the original author(s) and

the source, provide a link to the Creative Commons licence, and indicate if changes were made. The images or other third party material in this article are included in the article's Creative Commons licence, unless indicated otherwise in a credit line to the material. If material is not included in the article's Creative Commons licence and your intended use is not permitted by statutory regulation or exceeds the permitted use, you will need to obtain permission directly from the copyright holder. To view a copy of this licence, visit <http://creativecommons.org/licenses/by-nc/4.0/>.

## REFERENCES

1. Lee AY. Recent progress in melasma pathogenesis. *Pigment Cell Melanoma Res.* 2015;28(6):648–60.
2. Kwon SH, et al. Melasma: updates and perspectives. *Exp Dermatol.* 2019;28(6):704–8.
3. Iranmanesh B, et al. The efficacy of energy-based devices combination therapy for melasma. *Dermatol Ther.* 2021;34(3): e14927.
4. Trivedi MK, Yang FC, Cho BK. A review of laser and light therapy in melasma. *Int J Women's Dermatol.* 2017;3(1):11–20.
5. Weiner SF. Radiofrequency microneedling: overview of technology, advantages, differences in devices, studies, and indications. *Facial Plast Surg Clin N Am.* 2019;27(3):291–303.
6. Cho SB, Kim H. High-frequency alternating electrical current: selective electromagnetic tissue reaction. *Med Lasers.* 2016;5:1–6.
7. Taheri A, et al. Electrosurgery: part I. Basics and principles. *J Am Acad Dermatol.* 2014;70(4):591.e1–14.
8. Cho SB, et al. In vivo skin reactions from pulsed-type, bipolar, alternating current radiofrequency treatment using invasive noninsulated electrodes. *Skin Res Technol.* 2018;24(2):318–25.
9. Choi M, et al. Successful treatment of refractory melasma using invasive micro-pulsed electric signal device CR (case report). *Med Lasers.* 2015;4:39–44.
10. Kim H, Lee M. Therapeutic efficacy and safety of invasive pulsed-type bipolar alternating current radiofrequency on melasma and rebound hyperpigmentation. *Med Lasers.* 2017;6:17–23.
11. Jung JW, et al. A face-split study to evaluate the effects of microneedle radiofrequency with Q-switched Nd:YAG laser for the treatment of melasma. *Ann Dermatol.* 2019;31(2):133–8.
12. Yoon JE, et al. Senescent fibroblasts drive ageing pigmentation: a potential therapeutic target for senile lentigo. *Theranostics.* 2018;8(17):4620–32.
13. Lee YI, et al. Synergistic effect of 300  $\mu\text{m}$  needle-depth fractional microneedling radiofrequency on the treatment of senescence-induced aging hyperpigmentation of the skin. *Int J Mol Sci.* 2021;22(14).
14. Squadrito F, et al. Pharmacological activity and clinical use of PDRN. *Front Pharmacol.* 2017;8:224.
15. De Caridi G, et al. Trophic effects of polynucleotides and hyaluronic acid in the healing of venous ulcers of the lower limbs: a clinical study. *Int Wound J.* 2016;13(5):754–8.
16. Cavallini M, et al. Consensus report on the use of PN-HPT™ (polynucleotides highly purified technology) in aesthetic medicine. *J Cosmet Dermatol.* 2020;20.
17. Noh TK, et al. Novel anti-melanogenesis properties of polydeoxyribonucleotide, a popular wound healing booster. *Int J Mol Sci.* 2016;17(9):1448.
18. Kim YJ, et al. Polydeoxyribonucleotide activates mitochondrial biogenesis but reduces MMP-1 activity and melanin biosynthesis in cultured skin cells. *Appl Biochem Biotechnol.* 2020;191(2): 540–54.
19. Pandya AG, et al. Reliability assessment and validation of the Melasma Area and Severity Index (MASI) and a new modified MASI scoring method. *J Am Acad Dermatol.* 2011;64(1):78–83 (83.e1–2).
20. Rodrigues M, et al. Interpretability of the Modified Melasma Area and Severity Index (mMASI). *JAMA Dermatol.* 2016;152(9):1051–2.
21. Kwon SH, et al. Heterogeneous pathology of Melasma and its clinical implications. *Int J Mol Sci.* 2016;17(6).
22. Rajanala S, Maymone MBC, Vashi NA. Melasma pathogenesis: a review of the latest research, pathological findings, and investigational therapies. *Dermatol Online J.* 2019;25(10).
23. Goyarts E, et al. Morphological changes associated with aging: age spots and the microinflammatory

- model of skin aging. *Ann N Y Acad Sci.* 2007;1119:32–9.
24. Briganti S, et al. Azelaic acid reduced senescence-like phenotype in photo-irradiated human dermal fibroblasts: possible implication of PPAR $\gamma$ . *Exp Dermatol.* 2013;22(1):41–7.
  25. Regazzetti C, et al. Endothelial cells promote pigmentation through endothelin receptor B activation. *J Investig Dermatol.* 2015;135(12):3096–104.
  26. Mehrabi JN, et al. A review of combined treatments for melasma involving energy-based devices and proposed pathogenesis-oriented combinations. *J Cosmet Dermatol.* 2022;21(2):461–72.
  27. Park BJ, et al. Therapeutic effects of new pulsed-type microneedling radiofrequency for refractory facial pigmentary disorders. *Dermatol Surg.* 2022;48(3):327–33.
  28. Kwon HH, et al. Combined treatment of melasma involving low-fluence Q-switched Nd:YAG laser and fractional microneedling radiofrequency. *J Dermatol Treat.* 2019;30(4):352–6.
  29. Zheng Z, et al. Histometric analysis of skin-radiofrequency interaction using a fractionated microneedle delivery system. *Dermatol Surg.* 2014;40(2):134–41.
  30. Hantash BM, et al. Bipolar fractional radiofrequency treatment induces neolastogenesis and neocollagenesis. *Lasers Surg Med.* 2009;41(1):1–9.
  31. Beasley KL, Weiss RA. Radiofrequency in cosmetic dermatology. *Dermatol Clin.* 2014;32(1):79–90.
  32. Kauvar ANB, Gershonowitz A. Clinical and histologic evaluation of a fractional radiofrequency treatment of wrinkles and skin texture with novel 1-mm long ultra-thin electrode pins. *Lasers Surg Med.* 2022;54(1):54–61. <https://doi.org/10.1002/lsm.23452> (Epub 2021 Jul 20, PMID: 34287975).
  33. Hong JY, et al. Prospective, preclinical comparison of the performance between radiofrequency microneedling and microneedling alone in reversing photoaged skin. *J Cosmet Dermatol.* 2020;19(5):1105–9.
  34. Kim HM et al. A mixture of topical forms of polydeoxyribonucleotide, vitamin c, and niacinamide attenuated skin pigmentation and increased skin elasticity by modulating nuclear factor erythroid 2-like 2. *Molecules.* 2022;27(4).