


## EDITORIAL COMMENT

# Have we missed AINything? Acute interstitial nephritis in SARS-CoV-2 infection and vaccination

Joshua Storrar<sup>1</sup>, Satoru Kudose<sup>2</sup> and Alexander Woywodt <sup>3,1</sup><sup>1</sup>Department of Nephrology, Northern Care Alliance NHS Foundation Trust, Salford Royal Hospital, Salford, UK,<sup>2</sup>Department of Pathology and Cell Biology, Columbia University Irving Medical Center, NY, NY, USA and<sup>3</sup>Department of Nephrology, Lancashire Teaching Hospitals NHS Foundation Trust, Preston, UKCorrespondence to: Alexander Woywodt; E-mail: [Alex.Woywodt@lthtr.nhs.uk](mailto:Alex.Woywodt@lthtr.nhs.uk); Twitter handle: @Pwoywodt

## ABSTRACT

Acute interstitial nephritis (AIN), defined by the presence of interstitial inflammation accompanied by tubulitis, is an often overlooked cause of acute kidney injury (AKI). It is now well established that severe acute respiratory syndrome coronavirus 2 (SARS-CoV-2) infection can cause a wide variety of kidney injuries, most commonly acute tubular injury and collapsing glomerulopathy. In comparison, AIN is rarely documented in association with SARS-CoV-2 both anecdotally and in larger series of autopsy or biopsy studies. In this issue of the Journal, León-Román describe five cases of AIN in patients with a history of coronavirus disease 2019 (COVID-19) and highlight AIN as a possibly under-reported or ignored facet of renal disease associated with SARS-CoV-2. They describe three scenarios in which AIN can be seen: (i) SARS-CoV-2 infection after diagnosis of AIN, (ii) AIN followed by SARS-CoV-2 infection in the same admission and (iii) Severe SARS-CoV-2 and AIN possibly associated with SARS-CoV-2 itself. Overall, AIN remains rare in SARS-CoV-2 and causality is difficult to ascertain. Interestingly, AIN is not only seen in association with the disease itself but also with SARS-CoV-2 vaccination. This scenario is equally rare and causality is no less difficult to prove. A history of preceding SARS-CoV-2 infection and vaccination should be actively sought when patients present with otherwise unexplained AIN.

**Keywords:** acute interstitial nephritis, severe acute respiratory syndrome coronavirus 2, vaccination

## INTRODUCTION

Since the first descriptions of severe acute respiratory syndrome coronavirus 2 (SARS-CoV-2) causing coronavirus disease 2019 (COVID-19), nephrologists have discovered that several forms of renal disease may be linked to the virus [1]. Clinical reports on acute kidney injury (AKI) in patients with severe SARS-CoV-2 infection [2, 3] were rapidly followed by reports showing the virus in urine [4]. Viral presence in tubular cells [5] remains controversial but documented various glomerular lesions have been documented, most commonly collapsing glomerulopathy. More recently, SARS-CoV-2 vaccination has also received considerable attention with several reports describing new glomerular lesions

after vaccination; these reports are noteworthy for the variety of glomerular pathology described, ranging from minimal change disease to IgA nephropathy and crescentic lesions with or without antineutrophil cytoplasmic antibodies (ANCA). It has not yet been established how SARS-CoV-2 vaccination can trigger so many different lesions, and causality remains difficult to ascertain. In comparison, acute interstitial nephritis (AIN) is rare both in the context of SARS-CoV-2 infection and vaccination. In this issue of the Journal León-Román *et al.* [6] highlight AIN as a poorly understood renal lesion in SARS-CoV-2 infection. In this editorial, we aim to put their findings into perspective. We discuss reports of AIN in patients with SARS-CoV-2 infection and

Received: 17.5.2022; Editorial decision: 19.5.2022

© The Author(s) 2022. Published by Oxford University Press on behalf of the ERA. This is an Open Access article distributed under the terms of the Creative Commons Attribution-NonCommercial License (<https://creativecommons.org/licenses/by-nc/4.0/>), which permits non-commercial re-use, distribution, and reproduction in any medium, provided the original work is properly cited. For commercial re-use, please contact [journals.permissions@oup.com](mailto:journals.permissions@oup.com)

vaccination, speculate about underlying mechanisms and also emphasize important caveats and areas of uncertainty.

### AIN and SARS-CoV-2 infection

In this issue of the Journal, León-Román *et al.* [6] highlight AIN as an interesting and probably often overlooked, aspect of renal disease associated with SARS-CoV-2 infection. They describe five additional cases of AIN associated with SARS-CoV-2 infection [6] in different settings. Two of these cases occurred in patients diagnosed with AIN several years previously. In both cases, the cause of the AIN was secondary to immunological therapy for metastatic cancer. These patients then subsequently contracted SARS-CoV-2 and required hospital admission. Both cases had a good outcome and their clinical course is what one expects in similar immuno-suppressed patients acquiring COVID-19 infection. In two cases [6], the initial presenting feature was acute kidney injury (AKI) secondary to AIN caused by medications with a known association with AIN—namely ciprofloxacin and proton pump inhibitors (PPIs), respectively. Both patients developed SARS-CoV-2 infection in the hospital within days of their initial hospital admission. One patient unfortunately died, whilst the other made a good recovery. The final case, and probably the most interesting of the five, is a patient who presented with severe SARS-CoV-2, required intensive care admission and developed an AKI requiring continuous veno-venous haemofiltration. A kidney biopsy showed AIN that was felt to be due to COVID-19, although the patient also had exposure to ceftriaxone, tobramycin and linezolid. This patient was treated with steroids and had a good outcome.

Acute and chronic tubulointerstitial nephritis is one of the most common, but often overlooked, causes of AKI. Since patients with AIN frequently present with nonspecific clinical features, kidney biopsy plays an important role in establishing the diagnosis. Pathologic diagnosis of AIN is characterized by the presence of interstitial inflammation associated with tubulitis. When a cause of AIN can be determined, medications are the most common aetiology followed by autoimmune diseases (such as Sjogren's syndrome, IgG4-related disease and sarcoidosis), infection and other rare entities such as Tubulointerstitial Nephritis and Uveitis (TINU) syndrome. Infectious aetiologies of AIN are relatively uncommon, but have been described in association with various bacterial, viral and fungal microorganisms including cases with granuloma formation [7].

Virus-associated AIN is most frequently seen in transplanted patients and is most often caused by BK polyomavirus, JC polyomavirus, cytomegalovirus [8] and adenovirus [9]. When compared with other cases of AIN in which histology is often nonspecific, virus-associated AIN is unique, because kidney biopsy can often establish specific aetiology by demonstration of viral infection in the kidney using immunohistochemical stains. Consequently, direct infection of the kidney, together with the cytotoxic T-cell response directed against the viral compound, likely plays a role in the pathogenesis of some virus-associated AIN.

AKI is common amongst hospitalized patients with COVID-19 and a prevalence of up to 30% has been reported [10] although the exact figures remain disputed [11]. Although most do not undergo biopsy, COVID-19 is associated with a wide variety of kidney pathologies, most notably collapsing glomerulopathy in patients with high-risk APOL1 genotype and acute tubular injury in patients with severe COVID-19 [12–15]. However, only a few reports of AIN have been described in patients with COVID-19 [16–20].

The small number of cases of AIN following or during SARS-CoV-2 infection underscores the impression that AIN is an unusual complication. Furthermore, these reported cases highlight the difficulty and caution needed to establish COVID-19 as a possible cause or trigger of AIN from some other causes. For instance, a 12-year-old girl presented with a 3-week history of reduced appetite, weakness, weight loss and an AKI (creatinine 1.2 mg/dL) [20]. She was found to have SARS-CoV-2 IgG antibodies (titre 195 AU/mL, cut-off > 11.9 AU/mL) but tested negative for COVID-19 twice on routine swab testing, suggesting previous SARS-CoV-2 infection. She had tubular proteinuria. A kidney biopsy confirmed the presence of AIN with marked neutrophilic and lympho-plasma-cellular invasion of the interstitium. There were no immune deposits or virus-like particles seen on electron microscopy. She was treated with steroids and had complete resolution of kidney impairment [20]. In this case and in other reports, there was no convincing evidence of direct viral infection of the kidney parenchyma, in contrast to the typical cases of virus-associated AIN. Therefore, even in this previously healthy patient without exposure to medications, whether this patient's AIN is a direct result of SARS-CoV-2 infection or if the viral infection acted as a 'second-hit' to trigger AIN from other causes, such as TINU, one of the most common causes of AIN in the paediatric population, is not clear.

What does the report by León-Román *et al.* add to the literature? Their work reminds us to be mindful of AIN in patients with COVID-19 and highlights the existence of AIN and SARS-CoV-2 in different settings: (i) SARS-CoV-2 infection some years after initial diagnosis of AIN, (ii) AIN and SARS-CoV-2 infection in the same admission and (iii) severe SARS-CoV-2 and AIN possibly associated with SARS-CoV-2 itself. Furthermore, given the lack of convincing viral infection of the kidney in patients with AIN and COVID-19, their report highlights the need for nephrologists to be cautious when considering SARS-CoV-2 as a possible cause of AIN. In particular, nephrologists should carefully assess the timing of SARS-CoV-2 infection and onset of kidney injury, and exclude other causes of AIN before concluding that AIN is likely caused by SARS-CoV-2. In fact, as illustrated by León-Román *et al.* [6] in this issue, alternative causes for AIN are present in some cases, such as antibiotics administered for concurrent bacterial pneumonia or proton pump inhibitors (PPIs). Importantly, nephrologists should also be careful to exclude unusual causes of AIN in this setting, such as AIN caused by traditional or herbal medicines taken in an attempt to prevent SARS-CoV-2 [21].

It is also worth considering the possibility of whether any of the antiviral drugs used more recently in SARS-CoV-2 infection could potentially cause AIN, as other antivirals have been reported as possible triggers of AIN. Duque *et al.* described AIN associated with antiviral treatment for hepatitis C infection [22]. Famciclovir has also been reported in conjunction with AIN [23]. Whether or not antivirals used in the treatment of COVID-19 are capable of causing AIN is currently unknown although a case of AIN associated with lopinavir/ritonavir has been reported in a different context [24]. The topic of nephrotoxicity of antiviral drugs, in general, is reviewed elsewhere [25].

There are several possible reasons for the paucity of AIN reported in patients with COVID-19. One possibility is under-detection since most patients with AKI and COVID-19 do not undergo kidney biopsy. Alternatively, steroid therapy administered for COVID-19, especially in more severe diseases may result in recovery and under-reporting of AIN. Lastly, the paucity of AIN may be due to a lack of significant direct infection of kidney parenchyma, even among those with severe infection. This is in

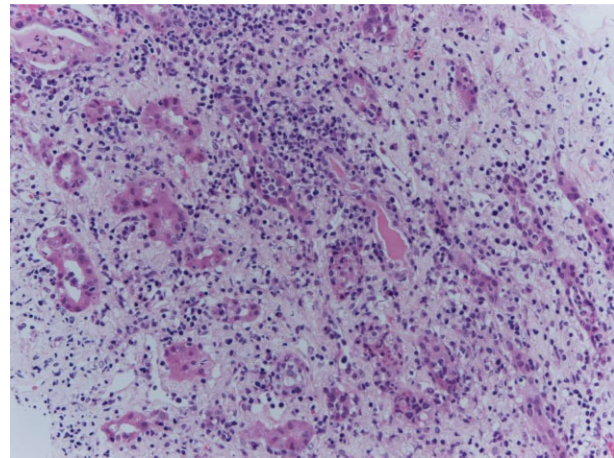
contrast to BK virus infection where high viral load consistently correlates with the presence of AIN. However, the possibility of the immune response against filtered viral proteins causing AIN in rare predisposed patients cannot entirely be ruled out.

Irrespective of the discussion of causality, AIN is often regarded as an under-recognized and thus under-reported disease [26]. Given that prompt treatment with either steroids or removal of the causative drug is likely to drastically improve outcomes for patients with AIN, it is important for clinicians to keep an open mind as to the cause of AKI in patients with COVID-19, particularly those that are not responding to conventional management. Where possible, correctly identifying the cause of AKI in patients with COVID-19 is important because it has been shown that the rate of kidney function decline post-discharge is significantly greater ( $-11.3\text{mL}/\text{min}/1.73\text{m}^2$  faster) in those patients with a diagnosis of COVID-19 compared with those without [27].

The small number of cases of AIN following or during SARS-CoV-2 infection underscores the impression that AIN is an unusual complication given the paucity of AIN in small and large series of biopsy and autopsy renal tissue obtained from SARS-CoV-2 patients. It is also possible that subtle presentations of AIN occur more frequently but that such cases recover spontaneously or do not undergo kidney biopsy. It is also worth remembering that subtle urinary abnormalities are surprisingly common in SARS-CoV-2 infection when compared with the incidence of AKI and to histological data. George *et al.* showed that SARS-CoV-2 spike protein is detectable in as many as 25% of patients and that many of them have albuminuria although the long-term implications of such findings remain unclear [28]. It is possible that mild and subtle cases of AIN are overlooked not least because quite a few of these patients are too unwell to undergo renal biopsy. Other patients may not undergo biopsy due to coagulopathy or because clinicians feel a biopsy is not warranted where meaningful immunosuppressive treatment would not be feasible anyway. Equally, one could speculate that steroid treatment is now so commonplace, especially across the more severe end of the spectrum of SARS-CoV-2 that some milder cases of AIN may recover and escape detection following steroid treatment.

Whilst reports of AIN as a cause for AKI in patients diagnosed with COVID-19 are few, there is a growing body of evidence to suggest that more subtle forms of tubulointerstitial injury are an important part of the pathophysiological response. In a study performed in France, 71 patients with COVID-19 were admitted to intensive care over a month-long period [29]. Of the 71 patients, 57 developed AKI and of these 10 required renal replacement therapy (RRT). Proteinuria was assessed with both protein:creatinine ratio (uPCR) and albumin:creatinine ratio (uACR). The median uPCR was significantly raised at 82 mg/mmol whereas the median uACR was normal at 0.23 mg/mmol. This discrepancy suggests a predominant tubulointerstitial injury which could indicate acute tubular injury or interstitial nephritis, or both. Interestingly, there was a low incidence of glycosuria pointing away from renal Fanconi syndrome. Another study has demonstrated that SARS-CoV-2 causes a proximal tubular dysfunction characterized by low molecular weight proteinuria, hypophosphataemia, hypouricaemia and neutral aminoaciduria [30].

Finally, one might wonder whether AIN is ever associated with SARS-CoV-2 infection in transplant patients. Westhoff *et al.* report the interesting case of a kidney-pancreas transplant recipient with AIN and SARS-CoV-2 RNA in tubular cells [31]. Overall AIN is believed to be rare in renal transplant recipients (and



**FIGURE 1:** Renal biopsy showing AIN in conjunction with SARS-CoV-2 vaccination. Haematoxylin-Eosin (HE) stain, x 200. There is interstitial oedema with mixed inflammatory infiltrate composed of lymphocytes, plasma cells, scattered eosinophils and neutrophils. From [41], with permission.

likely difficult to distinguish from T-cell mediated rejection) presumably due to the effect of the maintenance immunosuppressive medication [32].

#### AIN and COVID vaccination

A broad variety of glomerular lesions have been reported in conjunction with SARS-CoV-2 vaccination [33, 34]. Contemporary series report minimal change disease, IgA nephropathy, crescentic glomerulonephritis and collapsing glomerulopathy [13]. It is difficult to understand how a single trigger *i.e.* SARS-CoV-2 vaccination (although through different vaccines) could cause such a variety of lesions. It is conceivable that these vaccines act as a 'second hit' on a background of genetic vulnerability. Similar models of pathogenesis are being discussed for other glomerular diseases such as IgA nephropathy [35]. In comparison, AIN following SARS-CoV-2 vaccination is rare [36]. Prior to the pandemic, AIN had already been described in conjunction with other vaccines [37] such as influenza [38].

In June 2021, de la Flor described the first case of AIN in conjunction with the Pfizer-BioNTech COVID-19 vaccine [39]. Soon after Czerlau *et al.* reported on a case series of five patients with AIN associated with SARS-CoV-2 mRNA vaccination [40]. Interestingly, one of their patients had a pre-existent glomerular disease and the authors emphasized that patients with pre-existent kidney diseases can be affected as well [40]. Early evaluation for AIN and consideration of renal biopsy is, therefore, warranted in such patients *i.e.* if renal function worsens after vaccination with mRNA-based SARS-CoV-2 vaccines [40]. They also speculated about the pathogenic role of lipid or polyethylene glycol lipid component of the vaccine [40].

Our own first case of AIN associated with preceding SARS-CoV-2 vaccination [41] was a man in his mid-forties who presented with AKI requiring renal replacement therapy (RRT) only weeks after his second SARS-CoV-2 vaccination (AstraZeneca). Somewhat unexpectedly, kidney biopsy showed florid AIN (Fig. 1) for which there was no other obvious alternative explanation, although we acknowledged the possibility that we had missed clues in the history despite comprehensive assessment [41]. He recovered renal function with steroid treatment.

Table 1. Cases of acute interstitial nephritis following SARS-CoV-2 vaccination reported in the literature as of 4 May 2022

Author/Country of case report	Age (yrs)	Sex	Time to presentation from day of vaccination	Significant co-morbidities	New-onset or relapse	Vaccine brand	Vaccine dose	Baseline creatinine ( $\mu\text{mol/L}$ )	Presentation creatinine ( $\mu\text{mol/L}$ )	Kidney Biopsy	Treatment	Outcome
Choi J H et al./South Korea [45]	17	M	3 days		New-onset	Pfizer	Second	Not known	265	Interstitial infiltrates mainly mononuclear. Focal and moderate interstitial fibrosis and tubular atrophy in 20% of cortex. Negative IF. Findings consistent with AIN.	Supportive care	Discharged after 1 week
Choi J H et al./South Korea [45]	12	M	3 weeks		New-onset	Pfizer	Second	Not known	199	Tubules showed severe necrosis with heavy infiltration of neutrophils, eosinophils and mononuclear cells in the interstitium. Slight foot process effacement.	Oral steroids on day 10 of hospitalization	Recovery of renal function
Czerlau et al./Switzerland [40]	55	M	4 days	Hypertension, prostate cancer treated with prostatectomy	New-onset	Pfizer	Second	76.5	355	Lymphocytes, plasma cells, macrophages, eosinophilic granulocytes and some neutrophilic granulocytes, tubulitis and interstitial oedema	Steroid treatment—dose and length of treatment not specified	Serum creatinine following treatment is 88 $\mu\text{mol/L}$
Czerlau et al./Switzerland [40]	54	M	3 days	Myocardial infarction	New-onset	Moderna	Second	Not known	268	Lymphocytes, plasma cells, macrophages, and eosinophilic granulocytes, two granulomas, tubulitis + tubular destruction. Glomerular lesions in keeping with FSGS	Steroid treatment—dose and length of treatment not specified	Serum creatinine following treatment is 235 $\mu\text{mol/L}$
Czerlau et al./Switzerland [40]	58	M	'A few days'	FSGS refractory to treatment, with multiple relapses	New-onset	Moderna	Second	167	355	Lymphocytes, plasma cells, macrophages, with tubulitis and interstitial oedema	Steroid treatment—dose and length of treatment not specified	Serum creatinine following treatment is 210 $\mu\text{mol/L}$



Table 1. Continued

Author/Country of case report	Age (yrs)	Sex	Time to presentation from day of vaccination	Significant co-morbidities	New onset or relapse	Vaccine brand	Vaccine dose	Baseline Creatinine ( $\mu\text{mol/L}$ )	Presentation Creatinine ( $\mu\text{mol/L}$ )	Kidney Biopsy	Treatment	Outcome
Czerlau et al./Switzerland [40]	38	F	1 month	Ulcerative colitis—received ustekinumab previously for treatment	New-onset	Moderna	Second	76	86	Lymphocytes, plasma cells, macrophages, sporadic eosinophilic granulocytes and neutrophil granulocytes with tubulitis + interstitial oedema. EM shows mesangial IgA deposition.	Steroid treatment—dose and length of treatment not specified	Serum creatinine following treatment is 72 $\mu\text{mol/L}$
Czerlau et al./Switzerland [40]	35	F	Exact time not specified	Rheumatoid arthritis—on certolizumab treatment since 2016	New-onset	Pfizer	Second	49	100	Lymphocytes, plasma cells, macrophages, sporadic eosinophilic granulocytes and neutrophil granulocytes with tubulitis + interstitial oedema. EM shows mesangial IgA deposition.	Steroid treatment—dose and length of treatment not specified	Serum creatinine following treatment is 90 $\mu\text{mol/L}$
De la Flor et al./Spain [39]	78	M	3 weeks	Hypertension, type 2 diabetes mellitus	New-onset	Pfizer	First	150	475	Features of AIN along with glomerular sclerosis and other chronic changes	IV MP followed by oral steroids	Remained dialysis-dependent
Dheir H et al./Turkey [50]	44	F	48 hours		New-onset	Pfizer	First	Not known	186	Tubulointerstitial inflammatory infiltration containing eosinophils and lymphocytes and interstitial oedema	Haemodialysis. Oral steroids 1 mg/kg	Complete recovery of renal function
Fenoglio R et al./Italy [51]	F	78	52 days	Not stated	New-onset	Pfizer	First	Not stated	Not stated	Severe interstitial infiltration by mononuclear cells and polymorphonuclear leucocytes	Dialysis. Oral steroids	Dialysis discontinuation after 2 months
Fenoglio R et al./Italy [51]	F	57	82 days	Not stated	New-onset	Pfizer	Second	Not stated	Not stated	Severe interstitial infiltration by mono-nuclear cells and polymorphonuclear leucocytes.	Oral steroids	

Table 1. Continued

Author/Country of case report	Age (yrs)	Sex	Time to presentation from day of vaccination	Significant co-morbidities	New onset or relapse	Vaccine brand	Vaccine dose	Baseline Creatinine ( $\mu\text{mol/L}$ )	Presentation Creatinine ( $\mu\text{mol/L}$ )	Kidney Biopsy	Treatment	Outcome
Fenoglio R et al./Italy [51]	F	65	24 days	Not stated	New-onset	Oxford-AstraZeneca	Second	Not stated	Not stated	Severe interstitial infiltration by mononuclear cells and polymorphonuclear leucocytes	Dialysis Oral steroids	
Jongvilaikasem P and Rianthavorn P/Thailand [52]	14	M	5 days		New onset	Pfizer	First	Not known	177	Normal glomeruli with foot process effacement on EM. tubular injury and interstitial infiltrate	IV MP followed by oral steroids. Haemodialysis for 3 weeks	Improved creatinine to 47 $\mu\text{mol/L}$
Liew et al./United Kingdom [41]	53	M	3 days	Hypertension	New-onset	Oxford-AstraZeneca	Second	Not known	1034	Morphologically normal glomeruli with interstitial oedema and infiltrate of lymphocytes, plasma cells and neutrophils with tubulitis	Oral steroid treatment	Improvement of renal function. Dialysis-independent following discharge
Mira F S et al./Portugal [53]	45	F	8 days	Total thyroidectomy secondary to multinodular goitre	New-onset	Pfizer	Second	75	1626	Mild interstitial infiltrate with oedema and acute tubular necrosis. 20% IF-TA	Haemodialysis. MTP 500 mg daily for 3 days, followed by 50 mg prednisolone	Improvement of renal function-creatinine 168 $\mu\text{mol/L}$ 4 days post discharge.
Rieckmann S et al./Germany [54]	63	M	3 weeks		New-onset	Pfizer	First	Normal range (not specified)	1679	Acute tubular necrosis, interstitial oedema and lymphoplasmacellular infiltration with few eosinophil granulocytes	RRT on intensive care unit. Oral steroids 250 mg for 3 days then reduced to 80 mg daily.	Haemodialysis discontinued after 2 weeks.
Rieckmann S et al./Germany [54]	18	M	6 weeks		New-onset	Pfizer	Second	Not known	150	Lymphoplasmacellular infiltration + eosinophil granulocytes and diffuse acute tubular necrosis. Mesangial IgA	Oral steroids 50 mg per day.	Complete recovery of renal function within 2 weeks.

Table 1. Continued

Author/Country of case report	Age (yrs)	Sex	Time to presentation from day of vaccination	Significant co-morbidities	New onset or relapse	Vaccine brand	Vaccine dose	Baseline creatinine ( $\mu\text{mol/L}$ )	Presentation creatinine ( $\mu\text{mol/L}$ )	Kidney Biopsy	Treatment	Outcome
Rieckmann S et al./Germany [54]	25	F	3 weeks		New-onset	Pfizer	Third	Not known	1034	Severe, locally destructive interstitial nephritis with prominent diffuse acute tubular necrosis and slight eosinophilia	Oral steroids 250 mg per day for 3 days then reduced to 80 mg daily	Recovery of renal function within days.
Unver et al./Turkey [55]	67	F	3 weeks	Type 2 diabetes mellitus. Recent new-onset minimal change disease following first dose of CoronaVac	New-onset	CoronaVac	Second	Not known (serum creatinine was 53 $\mu\text{mol/L}$ )	371	Degeneration of proximal tubular cells and interstitial inflammation. Proteinaceous material was detected in many tubule lumens.	Pulsed IV MP followed by oral steroids. Patient was then commenced on cyclosporine treatment	Ongoing Proteinuria of 3g/day still apparent from last follow-up
Wu et al./United Kingdom [36]	69	F	5 days	Rheumatoid arthritis, Sjögren's syndrome, hypertension, hypothyroidism and anxiety	New-onset	Oxford-AstraZeneca	First	85	245	Florid interstitial infiltrate with prominent eosinophils, with no glomerular abnormalities and no chronic interstitial damage	Commenced on oral steroids. Discontinuation of regular medications such as ramipril, lansoprazole, methotrexate and paroxetine	Improved serum creatinine to 130 $\mu\text{mol/L}$ and resolved peripheral eosinophilia
Wu et al./United Kingdom [36]	60	F	2 weeks	Hypertension	New-onset	Oxford-AstraZeneca	Second	59	754	Widespread interstitial infiltrates in keeping with AIN	Single dose IV pulsed MP followed by oral steroids.	Full clinical recovery. Serum creatinine was 216 $\mu\text{mol/L}$ in last follow-up review

AIN, acute interstitial nephritis; EM, electron microscopy; FSGS, focal segmental glomerulosclerosis; IF, immunofluorescence; IFTA, interstitial fibrosis and tubular atrophy; M, male; MCD, minimal change disease; MP, methylprednisolone; IgA, immunoglobulin A; IV, intravenous.

As of late 2021, we reviewed 10 cases of AIN following SARS-CoV-2 vaccination which had been described in the literature [36] including one case with granulomatous lesions [17]. Since then, an additional case similar to our own first case was reported [42]. Lim et al. recently added two more cases, both with partial recovery after steroid treatment [43]. It is interesting to note that a case of relapse of IgG4-related interstitial disease following SARS-CoV-2 vaccination has also been reported [44]. More cases continue to emerge [45–47] although the overall number remains small, given how common SARS-CoV-2 vaccination is in the general population. Table 1 shows all cases of AIN in conjunction with SARS-CoV-2 vaccination as of the time of writing. So far as we can see, there does not seem to be a preponderance of any particular vaccine although mRNA-based vaccines seem to cause more allergic reactions overall [48].

Most cases reported so far recover to some degree with steroid treatment but it is important to appreciate that AIN associated with SARS-CoV-2 vaccination is not always benign. The case described by De la Flor et al. remained dialysis-dependent despite biopsy and steroid treatment [39].

All cases described in the literature have to be viewed with a degree of caution when it comes to causality. As part of the assessment, strong temporal association, lack of chronic lesions, absence of concomitant diseases and medication linked to AIN should all be considered [41]. It is quite possible that patients were too ill to remember alternative causes of AIN, such as the use of non-steroidal anti-inflammatory drugs (NSAIDs) or PPIs prior to the onset of kidney disease. Alternatively, they may have forgotten to mention the use of over-the-counter medication or they may be too embarrassed to report this. It is also the case that SARS-CoV-2 vaccination is such a common event in the general population that it is difficult to find any patient presenting with new-onset renal disease who has not had some form of SARS-CoV-2 vaccination in the recent past. We have ourselves encountered the occasional patient with pre-existing kidney disease who experienced worsening kidney function in conjunction with SARS-CoV-2 vaccination but where a biopsy was considered inappropriate or too risky and causality, therefore, remains difficult to assess. Again, it is difficult to completely exclude that these patients could have used NSAIDs or felt unwell overall with some degree of dehydration after vaccination. We emphasize the role of detailed history taking, as well as the fact, that all patients with otherwise unexplained AIN should be asked about prior SARS-CoV-2 vaccination.

## CONCLUSION

We now have a much greater understanding of the types of renal injury caused by both SARS-CoV-2 infection, and also vaccination, than we did at the onset of the pandemic. AIN, however, has received much less attention than glomerular disease and many questions remain unanswered. The link between SARS-CoV-2 infection and vaccination and AIN remains incompletely understood. In patients with AIN in conjunction with SARS-CoV-2 infection, there is a lack of robust evidence that the virus is incorporated into kidney tissue when techniques such as immunohistochemistry and *in-situ* hybridization are used. This is in contrast to other viral-associated AIN such as the BK virus. Secondly, AIN is rarely seen in biopsy and autopsy series of patients with SARS-CoV-2 infection. Finally, it is noted that there are potentially other causes for AIN in many of the reported cases of AIN in the context of SARS-CoV-2 infection (such as antibiotics, PPIs or NSAIDs) and, to a lesser degree, in patients where AIN occurs after SARS-CoV-2 vaccination. Causality is, therefore, dif-

icult to prove in many, if not most, cases. It is also worth keeping a sense of perspective: as of April 2022, the WHO reports a total of 509 531 232 cases of COVID-19 worldwide with 11 438 720 838 vaccine doses administered [49]. In the general population, preceding SARS-CoV-2 infection and vaccination are common in any patient's history. On the other hand, it seems possible that AIN is under-diagnosed, under-reported or both, in conjunction with COVID-19 and COVID vaccination. This could apply where clinicians assume that both the disease and vaccination are so ubiquitous that taking a detailed vaccination and COVID history isn't worth their while. We should use the work by León-Román [6] as a useful reminder that there may be more to renal disease associated with SARS-CoV-2 infection and vaccination than just glomerular disease. To ensure we are not missing AINything, we recommend vigilance and careful history taking, particularly in patients presenting with otherwise unexplained AIN.

## CONFLICT OF INTEREST STATEMENT

A.W. is member of the CKJ editorial board.

(See related article by León-Román et al. COVID-19 infection and renal injury: where is the place for acute interstitial nephritis disease? *Clin Kidney J* (2022) 15: 1698–1704.)

## REFERENCES

1. Ng JH, Bijol V, Sparks MA et al. Pathophysiology and pathology of acute kidney injury in patients with COVID-19. *Adv Chronic Kidney Dis* 2020; 27: 365–376
2. Larsen CP, Bourne TD, Wilson JD et al. Collapsing glomerulopathy in a patient with COVID-19. *Kidney Int Rep* 2020; 5: 935–939
3. Peleg Y, Kudose S, D'Agati V et al. Acute kidney injury due to collapsing glomerulopathy following COVID-19 infection. *Kidney Int Rep* 2020; 5: 940–945
4. Sun J, Zhu A, Li H et al. Isolation of infectious SARS-CoV-2 from urine of a COVID-19 patient. *Emerg Microbes & Infect* 2020; 9: 991–993
5. Diao B, Wang C, Wang R et al. Human kidney is a target for novel severe acute respiratory syndrome coronavirus 2 infection. *Nature Communications* 2021; 12: 2506
6. León-Román J, Agraz I, Vergara A et al. COVID-19 infection and renal injury: where is the place for acute interstitial nephritis disease? *Clin Kidney J* 2022; doi: 10.1093/ckj/sfac079
7. Aleckovic-Halilovic M, Nel D, Woywodt A. Granulomatous interstitial nephritis: a chameleon in a globalized world. *Clin Kidney J* 2015; 8: 511–515
8. Wong KM, Chan YH, Chan SK et al. Cytomegalovirus-induced tubulointerstitial nephritis in a renal allograft treated by fos-carnet therapy. *Am J Nephrol* 2000; 20: 222–224
9. Seralathan G, Kurien AA. Adenovirus interstitial nephritis: an unusual cause for early graft dysfunction. *Indian J Nephrol* 2018; 28: 385–388
10. Adamczak M, Surma S, Wiecek A. Acute kidney injury in patients with COVID-19: epidemiology, pathogenesis and treatment. *Adv Clin Exp Med* 2022; 31: 317–326
11. Rubin S, Orioux A, Prevel R et al. Characterisation of acute kidney injury in critically ill patients with severe coronavirus disease-2019 (COVID-19). *medRxiv* 2020; 13: 354–361
12. Ferlicot S, Jamme M, Gaillard F et al. The spectrum of kidney biopsies in hospitalized patients with COVID-19, acute



- kidney injury, and/or proteinuria. *Nephrol Dial Transplant* 2021; **36**: 1253–1262
13. Jeyalan V, Storrar J, Wu HHL et al. Native and transplant kidney histopathological manifestations in association with COVID-19 infection: a systematic review. *World J Transplant* 2021; **11**: 480–502
  14. Kudose S, Batal I, Santoriello D et al. Kidney biopsy findings in patients with COVID-19. *J Am Soc Nephrol* 2020; **31**: 1959
  15. Nasr SH, Alexander MP, Cornell LD et al. Kidney biopsy findings in patients with COVID-19, kidney injury, and proteinuria. *Am J Kidney Dis* 2021; **77**: 465–468
  16. Golmai P, Larsen CP, DeVita MV et al. Histopathologic and ultrastructural findings in postmortem kidney biopsy material in 12 patients with AKI and COVID-19. *J Am Soc Nephrol* 2020; **31**: 1944–1947
  17. Szajek K, Kajdi ME, Luyckx VA et al. Granulomatous interstitial nephritis in a patient with SARS-CoV-2 infection. *BMC Nephrology* 2021; **22**: 19
  18. Kudose S, Santoriello D, Bomback AS et al. Longitudinal outcomes of COVID-19-Associated collapsing glomerulopathy and other podocytopathies. *J Am Soc Nephrol* 2021; **32**: 2958–2969
  19. May RM, Cassol C, Hannoudi A et al. A multi-center retrospective cohort study defines the spectrum of kidney pathology in Coronavirus 2019 Disease (COVID-19). *Kidney Int* 2021; **100**: 1303–1315
  20. Serafinelli J, Mastrangelo A, Morello W et al. Kidney involvement and histological findings in two pediatric COVID-19 patients. *Pediatr Nephrol* 2021; **36**: 3789–3793
  21. Parthasarathy R, Mathew M, Koshy P et al. Traditional medicines prescribed for prevention of COVID-19: use with caution. *Nephrology* 2021; **26**: 961–964
  22. Duque JC, Dejman A, Venkat V et al. Acute interstitial nephritis following treatment with direct-acting antiviral agents in hepatitis C virus-infected patients: a case series. *Clin Nephrol* 2021; **95**: 22–27
  23. Crouch A, Le M, Rogers C et al. Evaluation of low dose famciclovir as herpes simplex virus and varicella zoster virus prophylaxis in cytomegalovirus low-risk solid organ transplant recipients. *Transpl Infect Dis* 2021; **23**: e13711
  24. Chughlay MF, Njuguna C, Cohen K et al. Acute interstitial nephritis caused by lopinavir/ritonavir in a surgeon receiving antiretroviral postexposure prophylaxis. *AIDS* 2015; **29**: 503–504
  25. Leowattana W. Antiviral drugs and acute kidney injury (AKI). *Infect Disord Drug Targets* 2019; **19**: 375–382
  26. Ng JH, Zaidan M, Jhaveri KD et al. Acute tubulointerstitial nephritis and COVID-19. *Clin Kidney J* 2021; **14**: 2151–2157
  27. Nugent J, Akhlu A, Yamamoto Y et al. Assessment of acute kidney injury and longitudinal kidney function after hospital discharge among patients with and without COVID-19. *JAMA Network Open* 2021; **4**: e211095
  28. George S, Pal AC, Gagnon J et al. Evidence for SARS-CoV-2 spike protein in the urine of COVID-19 patients. *Kidney360* 2021; **2**: 924–936
  29. Rubin S, Orioux A, Prevel R et al. Characterization of acute kidney injury in critically ill patients with severe coronavirus disease 2019. *Clin Kidney J* 2020; **13**: 354–361
  30. Werion A, Belkhir L, Perrot M et al. SARS-CoV-2 causes a specific dysfunction of the kidney proximal tubule. *Kidney Int* 2020; **98**: 1296–1307
  31. Westhoff TH, Seibert FS, Bauer F et al. Allograft infiltration and meningoencephalitis by SARS-CoV-2 in a pancreas-kidney transplant recipient. *Am J Transplant* 2020; **20**: 3216–3220
  32. Josephson MA, Chiu MY, Woodle ES et al. Drug-induced acute interstitial nephritis in renal allografts: histopathologic features and clinical course in six patients. *Am J Kidney Dis* 1999; **34**: 540–548
  33. Tan HZ, Tan RY, Choo JCJ et al. Is COVID-19 vaccination unmasking glomerulonephritis? *Kidney Int* 2021; **100**: 469–471
  34. Bomback AS, Kudose S, D'Agati VD. De novo and relapsing glomerular diseases after COVID-19 vaccination: what do we know so far? *Am J Kidney Dis* 2021; **78**: 477–480
  35. Hu X, Feng J, Zhou Q et al. Respiratory syncytial virus exacerbates kidney damages in IgA nephropathy mice via the C5a-C5aR1 axis orchestrating Th17 cell responses. *Front Cell Infect Microbiol* 2019; **9**: 151
  36. Wu HHL, Li JWC, Bow A et al. Acute interstitial nephritis following SARS-CoV-2 vaccination. *Clin Kidney J* 2022; **15**: 576–581
  37. Patel C, Shah HH. Vaccine-associated kidney diseases: a narrative review of the literature. *Saudi J Kidney Dis Transpl* 2019; **30**: 1002–1009
  38. Sokoda T, Sawai T, Iwai M et al. A case of acute tubulointerstitial nephritis possibly associated with influenza HA vaccine. *Nihon Shoni Jinzobyō Gakkai Zasshi* 2007; **20**: 55–59
  39. de la Flor J, Linares T, Alonso-Riaño M et al. A case of acute interstitial nephritis following the Pfizer-BioNTech COVID-19 vaccine. *Nefrologia (Engl Ed)* 2021; doi: 10.1016/j.nefro.2021.05.004
  40. Czerlau C, Bocchi F, Saganas C et al. Acute interstitial nephritis after messenger RNA-based vaccination. *Clin Kidney J* 2022; **15**: 174–176
  41. Liew SK, Nair B, So B et al. Acute interstitial nephritis following SARS-CoV-2 virus vaccination. *Clin Nephrol* 2022; **97**: 242–245
  42. Mira FS, Costa Carvalho J, de Almeida PA et al. A case of acute interstitial nephritis after two doses of the BNT162b2 SARS-CoV-2 vaccine. *Int J Nephrol Renovasc Dis* 2021; **14**: 421–426
  43. Lim JH, Kim MS, Kim YJ et al. New-onset kidney diseases after COVID-19 vaccination: a case series. *Vaccines (Basel)* 2022; **10**: 302
  44. Masset C, Kervella D, Kandel-Aznar C et al. Relapse of IgG4-related nephritis following mRNA COVID-19 vaccine. *Kidney Int* 2021; **100**: 465–466
  45. Choi JH, Kang KS, Han KH. Two adolescent cases of acute tubulointerstitial nephritis after second dose of COVID-19 mRNA vaccine. *Hum Vaccin Immunother* 2022; **1**–6
  46. Rieckmann S, Seibert FS, Hogeweg M et al. Acute interstitial nephritis after vaccination with BNT162b2. *J Nephrol* 2022; **35**: 779–782
  47. Schaubsluger T, Rajora N, Diep S et al. De novo or recurrent glomerulonephritis and acute tubulointerstitial nephritis after COVID-19 vaccination: a report of six cases from a single center. *Clin Nephrol* 2022; **97**: 289–297
  48. Chen M, Yuan Y, Zhou Y et al. Safety of SARS-CoV-2 vaccines: a systematic review and meta-analysis of randomized controlled trials. *Infect Dis Poverty* 2021; **10**: 94
  49. N.N. WHO COVID dashboard. <https://covid19.who.int/Last> (29 April 2022, date last accessed)
  50. Dheir H, Sipahi S, Cakar GC et al. Acute tubulointerstitial nephritis after COVID-19 m-RNA BNT162b2 vaccine. *Eur Rev Med Pharmacol Sci* 2021; **25**: 6171–6173

51. Fenoglio R, Lalloni S, Marchisio M et al. New onset biopsy-proven nephropathies after COVID vaccination. *Am J Nephrol* 2022; **53**: 325–330
52. Jongvilaikasem P, Rianthavorn P. Minimal change disease and acute interstitial nephritis following SARS-CoV-2 BNT162b2 vaccination. *Pediatr Nephrol* 2022; 1–3
53. Mira FS, Costa Carvalho J, de Almeida PA. et al. A case of acute interstitial nephritis after two doses of the BNT162b2 SARS-CoV-2 vaccine. *Int J Nephrol Renovasc Dis* 2021; **14**: 421–426
54. Rieckmann S, Seibert FS, Hogeweg M et al. Acute interstitial nephritis after vaccination with BNT162b2. *J Nephrol* 2022; **35**: 779–782
55. Unver S, Haholu A, Yildirim S. Nephrotic syndrome and acute kidney injury following CoronaVac anti-SARS-CoV-2 vaccine. *Clin Kidney J* 2021; **14**: 2608–2611