

were booked directly for surgery, again freeing up FTF clinic appointments. A small percentage (3.9%) was booked for teledermatology follow-up with repeat photos in 12 weeks to monitor lesion progression. Some of the variation in directing patients for FTF clinic versus surgery resulted from clinic setup, as some of our FTF clinics are also see-and-treat clinics. Therefore, patients were often booked in with the expectation of having a procedure that day.

Interestingly, we noted a high degree of concordance regarding discharges across all members of the consultant team, which we would suggest is a reliable indicator of a high-quality service. The British Association of Dermatologists (BAD) Quality Standards for Teledermatology<sup>6</sup> suggests that pigmented lesions should be referred via teledermatology as an alternative to FTF only when accompanied by teledermoscopy. We strongly believe the added value of high-resolution, professionally taken teledermoscopy images gives us the ability to confidently diagnose skin lesions in most cases. This allows us to appropriately discharge benign skin lesions and obviates the need for most patients to attend FTF, increasing clinic capacity for those who need it the most and freeing up clinician time. In our teledermatology clinics, 24 patients are reviewed per session, in keeping with BAD recommendations<sup>7</sup> and adjusted for Wales (each session lasting 3.75 h). This is double the number seen in a traditional FTF session and is presently nearly halved, due to social distancing from COVID-19. In a qualitative survey, patients reported a high degree of satisfaction with our teledermatology service, with 92.9% strongly agreeing they were satisfied overall.<sup>8</sup> A detailed cost comparison by our finance business intelligence team, of patients seen through medical illustration rather than FTF, demonstrated savings of £43/patient when seen by medical illustration, translating to financial savings of approximately £170 280 for 2019. Although this was not our original aim the resulting cost savings from an improved service are a bonus.

We see our teledermatology service as providing a local teledermoscopy test in a community setting, with the benefits of being capacity-releasing, cost-effective, efficient and accurate, reducing travel time for patients and resulting in a high degree of patient satisfaction.

## Acknowledgement

We thank C. Llewellyn, Department of Medical Illustration, Royal Gwent Hospital, Newport, Gwent, UK.

A. Lowe,<sup>1</sup>  A. Atwan<sup>1</sup> and C. Mills<sup>1</sup>

<sup>1</sup>Department of Dermatology, Royal Gwent Hospital, Newport, Gwent, UK

E-mail: ashimasarin4@gmail.com

Conflict of interest: the authors declare that they have no conflicts of interest.

Accepted for publication 23 July 2020

## References

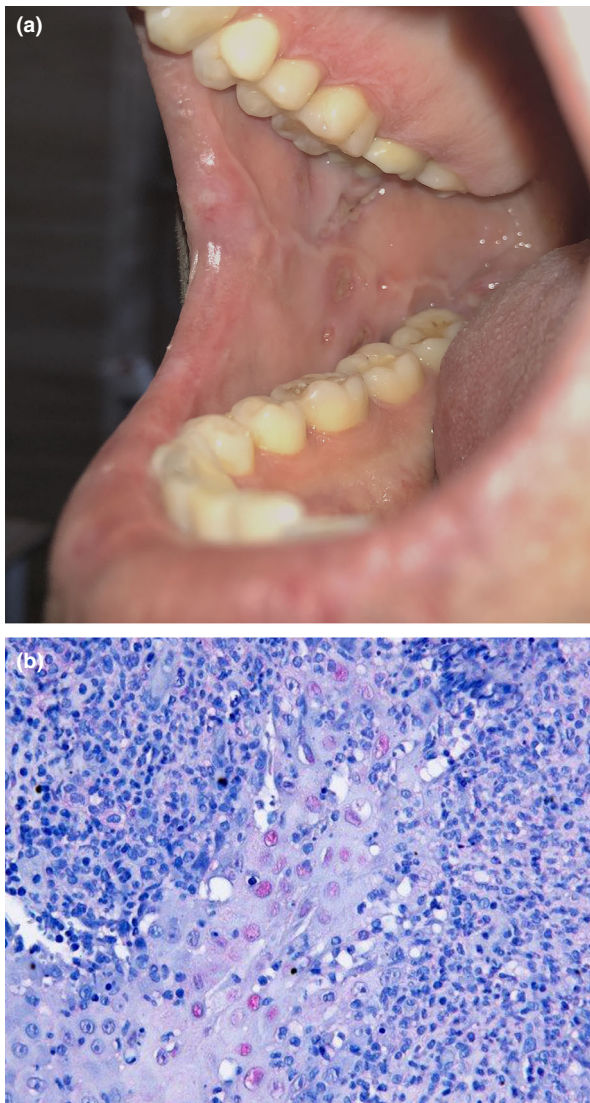
- 1 British Association of Dermatologists. Delivering care and training a sustainable multi-specialty and multi-professional workforce. An audit of UK dermatology outpatient departments against the 16 principles of the Royal College of Physicians' report 'Outpatients: the future – adding value through sustainability'. December 2019. Available at: <https://www.bad.org.uk/shared/get-file.ashx?id=6569&itemtype=document> (accessed 16 July 2020).
- 2 Ferrándiz L, Ojeda-Vila T, Corrales A *et al*. Internet-based skin cancer screening using clinical images alone or in conjunction with dermoscopic images: a randomized teledermoscopy trial. *J Am Acad Dermatol* 2017; **76**: 676–82.
- 3 Lee KJ, Finnane A, Soyer HP. Recent trends in teledermatology and teledermoscopy. *Dermatol Pract Concept* 2018; **8**: 214–23.
- 4 Dahlén Gyllencreutz J, Paoli J, Bjellerup M *et al*. Diagnostic agreement and interobserver concordance with teledermoscopy referrals. *J Eur Acad Dermatol Venereol* 2017; **31**: 898–903.
- 5 Arzberger E, Curiel-Lewandrowski C, Blum A *et al*. Teledermoscopy in high-risk melanoma patients: a comparative study of face-to-face and teledermatology visits. *Acta Derm Venereol* 2016; **96**: 779–83.
- 6 Primary Care Commissioning. Quality standards for teledermatology: using 'store and forward' images. 2013. Available at <https://www.bad.org.uk/shared/get-file.ashx?itemtype=document&id=794> (accessed 18 July 2020).
- 7 British Association of Dermatologists Clinical Services Committee. A guide to job planning for dermatologists. July 2018. Available at <https://www.bad.org.uk/shared/get-file.ashx?itemtype=document&id=6127> (accessed 19 July 2020).
- 8 Benedict S, Owen ED, Mills C. Teledermatology: an audit of patient and referring primary care physician satisfaction. *Br J Dermatol* 2015; **173**: 181. Abstract BTS01.

## COVID-19-associated herpetic gingivostomatitis

doi: 10.1111/ced.14402

A 46-year-old man with hypercholesterinaemia and coronary heart disease presented to the emergency department with a 3-day history of fatigue, dry cough and fever. He was febrile with a temperature of 39.5 °C and an oxygen saturation of 91% while breathing ambient air, with a respiratory rate of 16 breaths/min.

Laboratory tests showed elevated levels of C-reactive protein (13 mg/dL; normal < 0.5 mg/dL) and interleukin-6 (125 pg/mL; normal < 5.9 pg/mL). White blood cell count was normal, but he had eosinopenia (< 1%; normal range 1–4%). An oropharyngeal swab for COVID-19 testing was positive. Chest computed tomography showed bilateral ground-glass opacities.



**Figure 1** (a) Ulcerations in the right side of buccal mucosa; (b) multiple nuclei with herpes simplex virus 1/2 antibodies after immunohistochemical staining (original magnification  $\times 40$ ).

As he was showing increasing respiratory distress, the patient was admitted to the intensive care unit with severe acute respiratory syndrome, where invasive mechanical ventilation was conducted for 9 days. Empirical intravenous antibiotic therapy with meropenem and azithromycin was administered with improvement of the patient's condition.

Three days after extubation and recurrence of wellbeing, the patient reported painful ulcerations in his mouth. Dermatological examination revealed multiple sharply circumscribed ulcerations of the oral mucosa covered by yellow–grey membranes (Fig. 1a). Apart from submandibular lymphadenitis, no further skin changes or

pathologies were found. His medical history included recurrent herpes labialis infection.

As the patient was originally from the Middle East, genomic analysis was performed after informed consent was obtained. Analysis of human leucocyte antigen (HLA)-B\*51, B\*27 and B\*44 was negative.

A pathology test was performed on the middle of the right forearm with no pathological sign after 24 and 48 h; thus in the absence of genital ulcerations and non-follicular pustules the diagnosis of Behçet disease could be excluded.<sup>1</sup> Skin biopsy and dermatohistopathological examination showed central ulcerations with apoptotic keratinocytes and interface dermatitis. After immunohistochemical staining, multiple nuclei with herpes simplex virus (HSV)-1/2 antibodies were visible (Fig. 1b).

Buccal swabs revealed a normal oral microbiome, and HSV-1 DNA was detected by PCR. When we checked the initial serum sample taken before inpatient care, we detected anti-HSV-1 IgG, and in subsequent serum samples we also found anti-HSV-IgM, which was compatible with HSV-1 reactivation.

Based on the results and the patient's medical history, we diagnosed secondary herpetic gingivostomatitis (SHGS) in the context of COVID-19 infection. In contrast to primary herpetic gingivostomatitis, which represents the initial primoinfection with HSV in infants and adults, SHGS develops regularly in immunosuppressed adults and shows a more severe progression of disease with increasing age.<sup>2,3</sup>

Because of the patient's discomfort and the prolonged ICU treatment, oral aciclovir therapy 400 mg five times daily was administered, which resulted in rapid improvement of pain and ulcerations.<sup>4</sup> Given the patient's age and the rare secondary manifestation of HSV-1 in the oral cavity, we believe that the COVID-19 infection and prolonged inpatient care were causal factors of stress induction and immunosuppression, leading to the distinct oral manifestations.

## Acknowledgement

We thank the patient for his written informed consent to publication of his case details.

**T. Kämmerer,<sup>1</sup> J. Walch,<sup>1</sup> M. Flaig<sup>1</sup> and L. E. French<sup>1</sup>**

<sup>1</sup>Department of Dermatology and Allergology, University Hospital Munich, Munich, Germany

E-mail: till.kaemmerer@med.uni-muenchen.de

Conflict of interest: the authors declare that they have no conflicts of interest.

Accepted for publication 23 July 2020

## References

- Hatemi G, Christensen R, Bang D, *et al.* 2018 update of the EULAR recommendations for the management of Behçet's syndrome. *Ann Rheum Dis* 2018; **77**: 808–18.

- 2 Whitley RJ. Herpes simplex virus infection. *Semin Pediatr Infect Dis* 2002; **13**: 6–11.
- 3 Chauvin PJ, Ajar AH. Acute herpetic gingivostomatitis in adults: a review of 13 cases, including diagnosis and management. *J Can Dent Assoc* 2002; **68**: 247–51.
- 4 Nasser M, Fedorowicz Z, Khoshnevisan MH, Shahiri Tabarestani M. Acyclovir for treating primary herpetic gingivostomatitis. *Cochrane Database Syst Rev* 2008; (4): CD006700.

## Immune checkpoint inhibition in the era of COVID-19

doi: 10.1111/ced.14370

The worldwide coronavirus pandemic continues to result in significant morbidity and mortality, with almost 24 million confirmed cases to date. Approximately 80% of patients have mild disease and do not require hospitalization.<sup>1</sup> A key challenge facing the medical community is predicting which patients are at risk of developing severe disease, in order to initiate early supportive treatment and to facilitate enrolment into much needed prospective clinical trials, both crucial for developing and optimizing effective treatment strategies.

Patients with cancer have already been identified as having an increased risk of developing not only COVID-19 infection, but also severe disease, both of which are associated with poorer clinical outcomes.<sup>2</sup> Reassuringly, the increase in mortality from COVID-19 infection in patients with cancer may be primarily related to age, sex and comorbidities rather than to the cancer itself. Furthermore, there was no increased mortality in patients receiving and those not receiving anticancer therapy.<sup>3</sup>

Nevertheless, it is at least conceivable that the type of anticancer therapy may influence the risk and course of COVID-19 infection in patients with cancer. Given the increasing use of immune checkpoint inhibition in Dermatology (metastatic melanoma, Merkel cell carcinoma and squamous cell carcinoma) we reviewed the current literature to determine the extent to which immune checkpoint inhibition has been associated with COVID-19 infection.

We performed PubMed searches to 22 June 2020 using the search terms 'COVID-19' or 'SARS-CoV-2', and 'immune checkpoint', 'nivolumab', 'ipilimumab', 'pembrolizumab', 'avelumab', 'cemiplimab' or 'atezolizumab'. Only articles in English were included for further analysis.

We identified seven case reports and one case series of patients treated with immune checkpoint inhibitors who developed SARS-CoV-2 infections (Table 1), a total of 10 patients. An additional case of coronavirus HKU1 was reported.

Of the 10 patients with SARS-CoV-2, 30% were women and age range was 22–75 years. Half (50%) of the cases had an underlying urological tumour, 20% had metastatic melanoma, 20% had lung cancer and 10% had a haematological malignancy. Regarding treatment, 30% of the patients had received an anti-PD-L1 treatment (atezolizumab), 20% a combined anti-CTLA-4/anti-PD-1 treatment, 40% were treated with nivolumab (anti-PD-1) monotherapy and one patient (10%) received pembrolizumab (also anti-PD1). The effect of comorbidity, smoking status and ethnicity was difficult to ascertain as these were inconsistently recorded. Time from initiation of immune checkpoint inhibitor to the development of COVID-19 symptoms ranged from 48 h to > 1 year. The treatments for COVID-19 infection varied considerably, but 70% of cases received antibiotics, 20% antiviral medication and 30% received hydroxychloroquine (some patients received > 1 treatment). Three patients did not require specific therapy. The patient with coronavirus HKU1 received systemic corticosteroids for presumed checkpoint-mediated pneumonitis. In fact, the clinical and radiological presentation of immune checkpoint-related pneumonitis may be indistinguishable from that of SARS-CoV-2, making early SARS-CoV-2 PCR testing crucial. Three patients (30%) died due to coronavirus infection. Of the remaining patients, immune checkpoint therapy was recommenced or planned for four.

We found that only 10 patients with COVID-19 infection during immune checkpoint inhibition therapy have been reported. However, it is worth noting that 30% of the cases had a very mild clinical course and did not require hospitalization. Moreover, immune checkpoint therapy was safely recommenced in several patients. These points are extremely important given the fear and anxieties of patients with cancer regarding COVID-19 infection, which may lead some patients to unnecessarily delay or interrupt therapy.

Ultimately, the decision on whether to initiate and/or continue immune checkpoint therapy during the coronavirus pandemic must be based on a detailed consideration of several factors, including tumour burden and progression, comorbidities, existing immunosuppression, palliative vs. adjuvant treatment and alternative treatment options, and cannot be generalized.<sup>4</sup> Geographical coronavirus prevalence should also be considered. Irrespective of the final cancer treatment decision, the importance of facial coverings, social distancing, shielding and hand hygiene should also be emphasized.

Moving forward, there seems to be a strong case for a comprehensive and standardized prospective register of COVID infections during immune checkpoint inhibition therapy, at least at the local and national levels. This would provide vital information to determine how checkpoint inhibition influences the course of the disease,