





Submitted:
17.11.2021
Accepted:
03.01.2022
Published:
13.04.2022

The role of ABUS in the diagnosis of breast cancer

Elżbieta Łuczyńska¹ , Marta Pawlak² ,
Tadeusz Popiela³ , Wojciech Rudnicki¹ 

¹ Department of Electroradiology, Jagiellonian University Medical College, Cracow, Poland

² Diagnostic Imaging Unit, University Hospital in Cracow, Cracow, Poland

³ Chair of Radiology, Jagiellonian University Medical College, Cracow, Poland

Correspondence: Wojciech Rudnicki, Electroradiology Department, Jagiellonian University Medical College, Cracow, Poland; e-mail: wrudnicki@cmuj.pl

DOI: 10.15557/JoU.2022.0014

Keywords

breast cancer;
mammography;
MRI;
ABUS;
CEM

Abstract

Breast cancer, which is the most common cancer in women, is a major problem both in Poland and worldwide. Mammography remains the primary screening method. However, the sensitivity of mammographic screening is lower in women with dense glandular breasts due to tissue overlap and the effect of the glandular tissue obscuring the tumor and the fact that tumors and glandular tissue show similar X-ray absorption. Consequently, other methods are being sought to increase breast cancer detection rates. Currently, the most common and used methods are ultrasonography, magnetic resonance imaging and advanced mammographic methods (digital breast tomosynthesis and contrast-enhanced spectral mammography). Despite many advantages and superiority over mammography in dense breasts, they also have many disadvantages. Ultrasound is operator-dependent and the other techniques are expensive or not widely available. The Automated Breast Ultrasound Service (ABUS) technique appears to be a good option in terms of both effectiveness and lower cost.

Introduction

Breast cancer, which is the most common cancer in women, is a major problem both in Poland and worldwide⁽¹⁾. Mammography is the primary screening method for breast cancer, and according to the literature, mammographic screening has reduced mortality from this disease by up to 45%^(2,3).

Conventional full-field digital mammogram (FFDM)

Traditional 2D full-field digital mammography (FFDM) is a technique using ionizing radiation. After appropriate compression, two mammographic images in an oblique and a craniocaudal (CC) view of each breast are taken. A part of the axillary fossa is also included in the examination. Based on mammography, the American College of Radiology (ACR) Breast Imaging Reporting and Data

System (BI-RADS) classifies breast density from A (fatty breasts) to D (very dense breasts). Mammographic density (MD) depends on the proportion of epithelial, stromal and adipose tissue. Mammographic images are summation images, meaning that structures lying in the same plane overlap, producing a summation phenomenon, a likely cause of tumor obscuration by glandular tissue. A high percentage of adipose tissue, which poorly absorbs ionizing radiation, makes focal lesions more visible than the high percentage of glandular breast tissue, which results in the masking of focal lesions by this tissue on the summation image. In addition, denser breasts are more difficult to compress, as a result of which glandular and stromal tissues are poorly distinguishable, causing overlapping of structures. Due to these correlations, dense breast structure is associated with decreased mammographic sensitivity and specificity, and thus an increased risk of breast cancer^(4–6) (Fig. 1). Mammographic sensitivity is about 98% for entirely fatty breasts (ACR A), and about

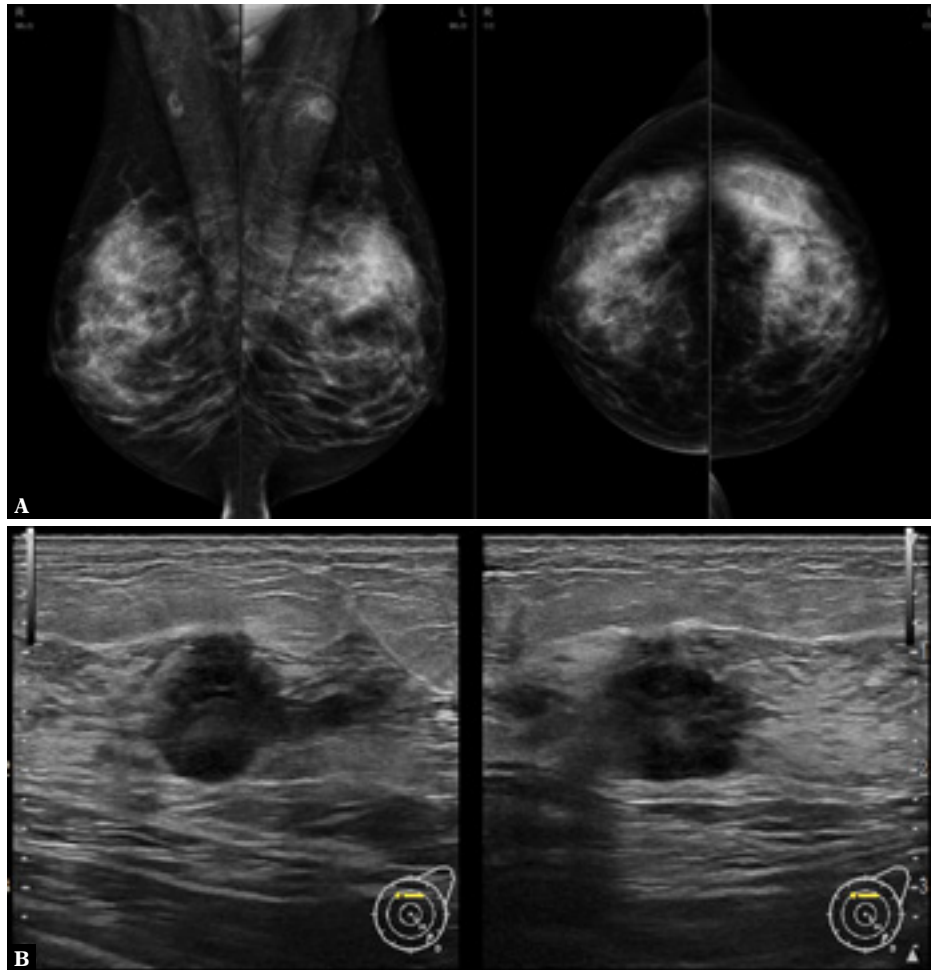


Fig. 1. A. Cancer not visible on mammography. B. Multiple suspicious lesions were visible on RUSG

48% for dense glandular breasts (ACR D)⁽⁷⁾. The group of patients with dense glandular breasts is large and includes young women, those on hormone replacement therapy and those with low BMI⁽⁸⁾.

In view of the above limitations of mammographic screening, the role of a personalized approach to breast cancer screening is currently being emphasized and the search for optimal complementary methods to detect more cancers, especially in dense breasts, continues.

Adjuncts to mammography

Ultrasonography

Hand-held ultrasonography (HHUS), performed by a radiologist or another specialty doctor skilled in breast examination, is one of the oldest, basic and currently most widely available methods. This method uses an ultrasound wave instead of ionizing radiation. Ultrasound used as a complementary tool in screening and everyday clinical practice has been shown to significantly improve cancer detection in breasts

with dense glandular structure⁽⁹⁾ – by 4–8% according to literature data⁽¹⁰⁾. Despite its wide availability, the method has many limitations. Difficult to eliminate disadvantages of HHUS, such as lack of standardization, operator-dependent interpretation, small field of view (FOV) and, finally, being a time-consuming procedure (the time of performing an examination significantly exceeds the time of interpreting the obtained images) have been identified. Ultrasound requires extensive knowledge and experience in breast examination, which is essential for the detection of pathology and differentiation between benign and malignant changes. The operator should be able to differentiate focal changes from anatomical structures and artifacts that mimic pathologies, which can be easily generated and misinterpreted by an inexperienced operator.

Ultrasonography allows for the assessment of vascularization of the lesion and the course of both internal and external vessels using power Doppler. Elastography is complementary to ultrasound examination and allows for the analysis of lesion stiffness and estimation of the probability of malignancy on this basis.

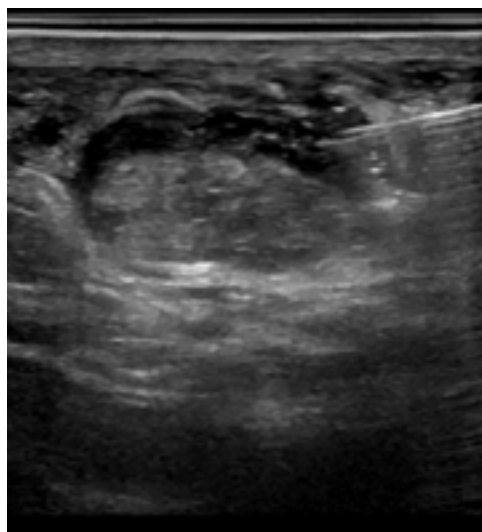


Fig. 2. *Ultrasound-guided fine needle biopsy*

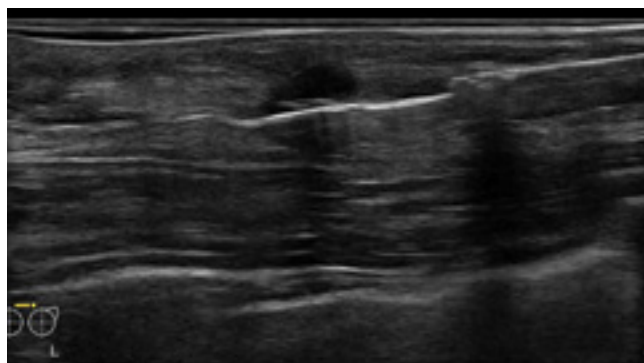


Fig. 3. *Thick-needle biopsy of one of the lesions in a patient from Fig. 1*

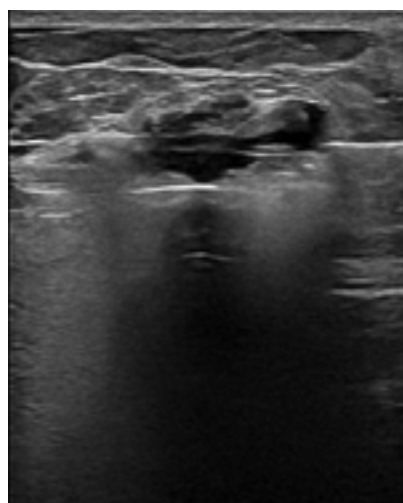


Fig. 4. *Vacuum-assisted thick-needle biopsy*

Targeted breast biopsy can easily be performed under ultrasound guidance: fine-needle aspiration (BAC) (Fig. 2), core needle biopsy (BGI) (Fig. 3), as well as vacuum assisted breast biopsy (VABB) (Fig. 4).

Magnetic resonance imaging

Considering the advantages and limitations of mammography and ultrasound, breast magnetic resonance imaging (BMRI)^(11–13) has been used to improve the diagnosis of breast cancer. Just like ultrasound, BMRI does not use ionizing radiation. An intravenous contrast agent is needed to evaluate breast lesions as this examination analyses the pathological vascularization of the tumor based on software-generated patterns of contrast enhancement curves. The scanning must be performed in the appropriate phase of the menstrual cycle, when the level of sex hormones does not cause too much excitation and contrast uptake by the background parenchymal enhancement (BPE) tissues. The lack of contrast agent does not allow an assessment of pathological foci of contrast enhancement in the breast, making the technique non-diagnostic for cancer. A special coil dedicated to breast examination is needed to perform BMRI. The examination is performed in a prone

position. Additionally, T2-weighted images are needed to determine the type of breast structure, and T1-weighted images must be taken to assess markers in the breast. Although BMRI is a very sensitive method, its specificity is lower. To improve it, diffusion-weighted imaging (DWI) and apparent diffusion coefficient (ADC) maps are also performed (Fig. 5). Due to the number of sequences performed, BMRI is a time-consuming and uncomfortable examination for the patient. Microcalcifications, characteristic of ductal carcinoma in situ (DCIS), are not visible in MRI, which may cause a false-negative result in the absence of neoangiogenesis in the focal lesion.

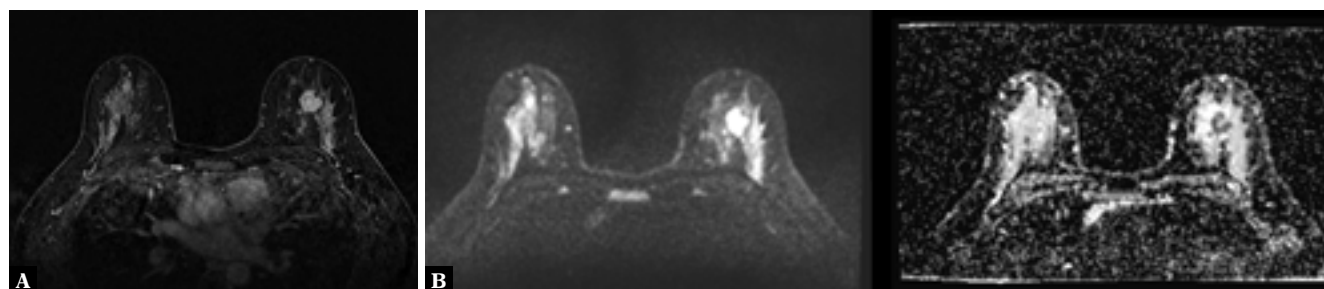


Fig. 5. *Cancer on BMRI in a patient from Fig. 1. A. Images after contrast administration. B. DWI/ADC*

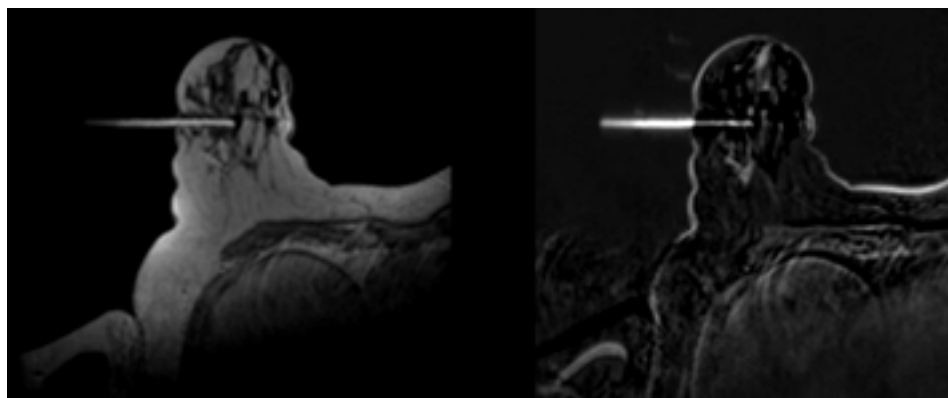


Fig. 6. MRI-guided biopsy. T1-weighted images after contrast administration with a visible biopsy needle

Specific indications for BMRI have been developed, such as: preoperative staging in patients with newly diagnosed breast cancer, monitoring breast cancer response in patients on neoadjuvant chemotherapy, postoperative assessment of residual tumor mass in patients with positive margins, search for primary lesion in patients with metastatic axillary lymph node, negative mammographic and ultrasound findings (including contrast enhanced spectral mammography (CEM); and digital breast tomosynthesis (DBT)), screening of women at high risk of breast cancer (known *BRCA1*, *BRCA2* mutations), evaluation of focal lesions that are ambiguous on other imaging examinations, and integrity of implants - in which case no contrast agent is necessary.

VABB can be performed under BMRI guidance (Fig. 6); however, due to the poor availability and the length of the procedure, only lesions that are not visible on RUSG and mammography qualify for this biopsy.

Tomosynthesis

Digital breast tomosynthesis (DBT) and contrast-enhanced spectral mammography (CESM) are novel methods based on mammography. Tomosynthesis is a type of mammography in which an x-ray tube with limited angular range moves in an arc over a compressed breast. In DBT, the reconstruction process creates planes parallel to the detector. If a lesion is located closer to a given plane, it becomes more visible in this plane and will not be missed by mammography (Fig. 7). Additionally, DBT can reduce the phenomenon of tissue summation mimicking a focal lesion, which is present in FFDM, and reduce the number of false positives. In computer reconstructions, thin layers (up to 1 mm thick) are produced, which allow an accurate assessment of focal lesions, as well as summation images up to 10 mm thick, the so-called slabs, which show microcalcifications in a more accurate way. Although DBT is currently not widely available, preliminary studies and

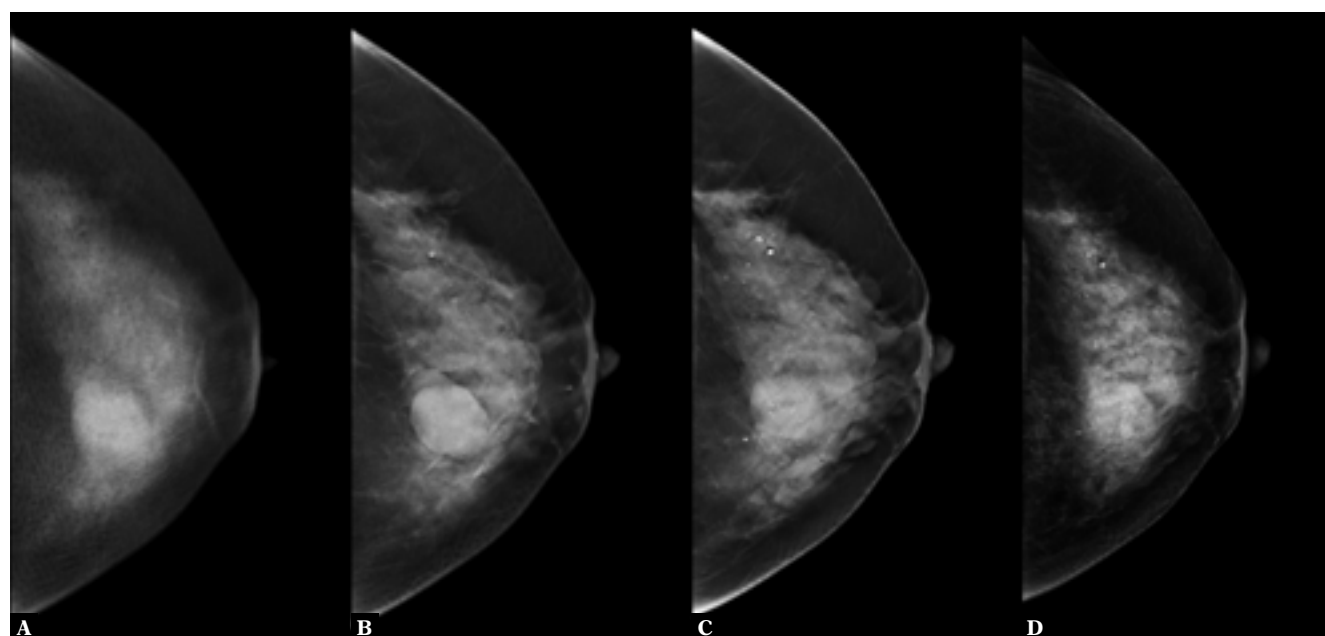


Fig. 7. Tomosynthesis planes in CC projection (A, B, C) and synthetic mammography resulting from reconstruction of the planes (D)

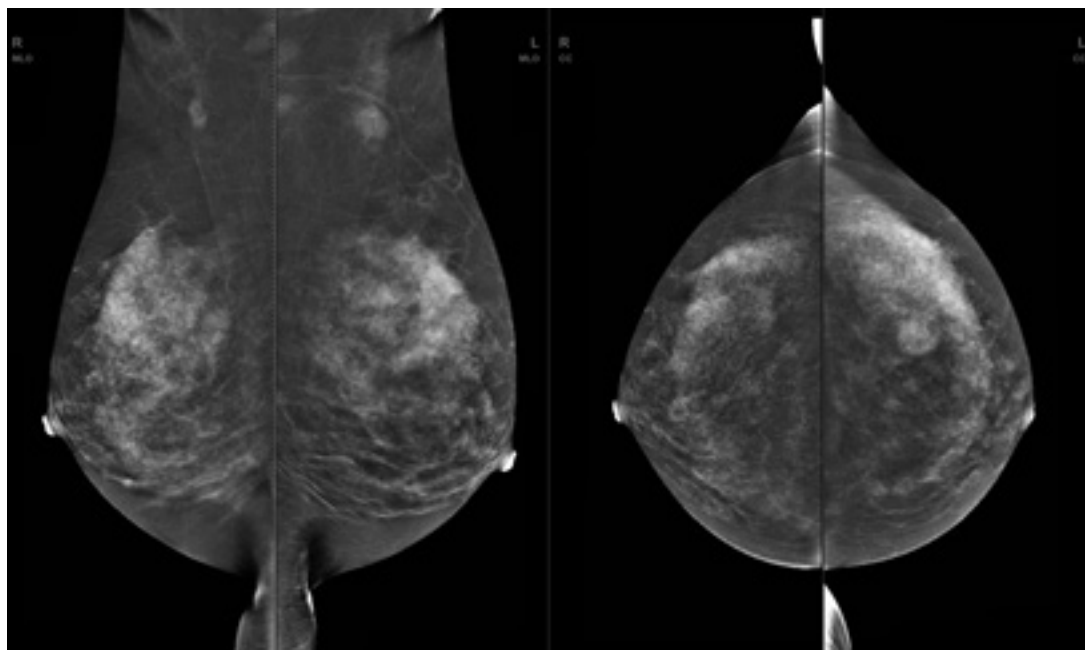


Fig. 8. CEM – images showing enhancement (subtractive). Scanning performed in a patient from Fig. 1

publications suggest that it contributes to cancer detection rates more than FFDM^(14–18). The dose of ionizing radiation per patient is the same as in 2D mammography. The indications for tomosynthesis include an evaluation of equivocal findings on FFDM, as well as search for focal lesions in both patients with dense breasts and symptomatic patients with negative FFDM. The fact that it is still a mammographic technique and some of the lesions (visible only on ultrasound or BMRI) may be elusive on DBT is a limitation of this modality. Its low availability is also a disadvantage.

Contrast-enhanced spectral mammography

Contrast-enhanced spectral mammography (CESM), which is performed after intravenous administration of iodine contrast agents^(19,20), is another FFDM-based method. The sensitivity and specificity of this technique are comparable to those of BMRI. CEM is performed using a special dual energy mammograph for low- and high-energy exposures. The examination is analogous to FFDM – each breast is imaged in two projections. Diagnostic stations produce low-energy images corresponding to FFDM and subtractive images, in which the glandular tissue is suppressed and only contrast-enhanced foci remain (Fig. 8). Contrast-enhanced spectral mammography is a method that combines mammography (thus enabling the assessment of the morphology of focal lesions, such as tumors, architectural abnormalities and microcalcifications) with functional imaging after the administration of a contrast agent, where areas of contrast enhancement showing the features of neovascularization in focal lesions are analyzed. Indications include a preoperative assessment of multifocal lesions

in patients with known breast cancer, search for focal lesions in symptomatic patients, negative ultrasonographic and FFDM findings, evaluation of equivocal findings on other imaging modalities, as well as screening of patients with dense breasts or at high risk for breast cancer. Slightly higher dose of ionizing radiation per patient than in mammography is a limitation of CEM. The need for contrast agent is an additional burden. This examination must be carefully performed as poor positioning in mammography can lead to lesions being missed out.

ABUS

Automated breast ultrasound (ABUS), a computer-assisted technique for assessing the whole breast using an automated linear 6–14 MHz transducer selected according to breast thickness, is a test that has been developed relatively recently and is now occasionally used. The transducer moves automatically over the breast in a manner similar to HHUS, obtaining transverse plane images in overlapping linear rows in the CC projection (Fig. 9).

Technique

During the examination, a sponge wedge is placed under the patient's arm in the supine position. This allows for an even distribution of breast tissue, with the nipple pointing towards the ceiling. Hypoallergenic fluid is distributed evenly over the breast, with an additional amount in the nipple area to ensure proper contact between the probe and the breast. During image acquisition, women must not move and should breathe quietly. Scanning by ABUS is continuous and automatic.

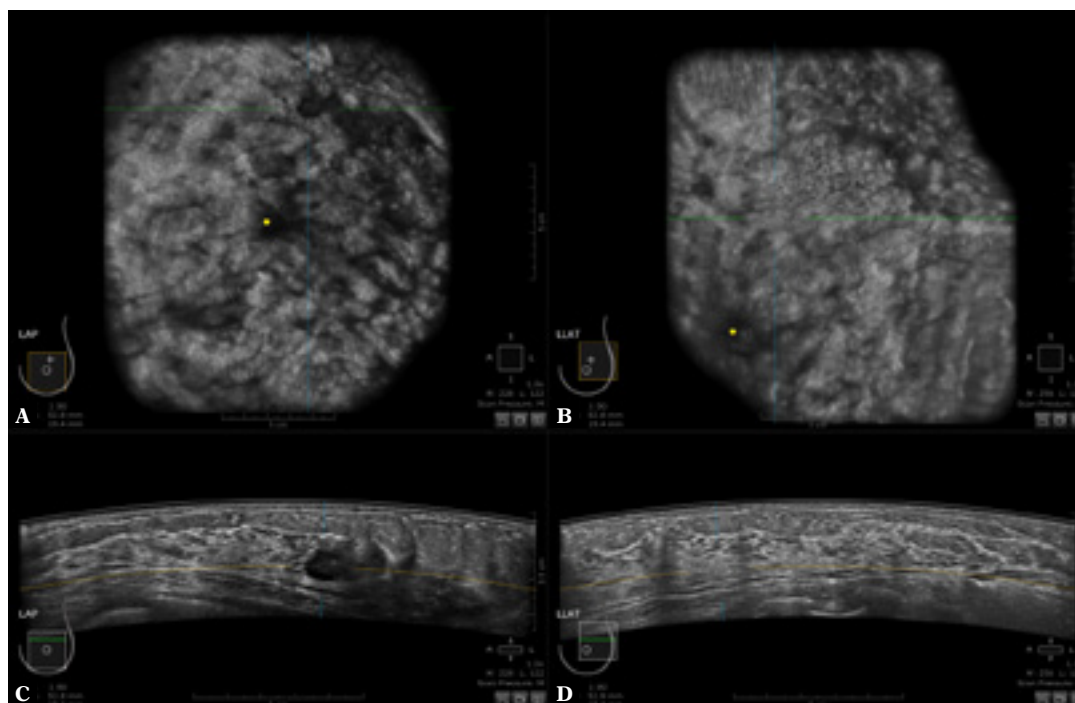


Fig. 9. ABUS projections in a patient from Fig. 1. Frontal plane showing the ductal system of the breast (A, B) and axial slices (C, D)

Female breasts are symmetrical organs with different sizes (a variable aspect in the population), shapes and densities. The receptor plate is not designed to fit all breasts, and peripheral areas may be missed out. In order to cover the entire breast, electroradiologists choose the most appropriate setting for each patient, depending on breast size.

ABUS images and reconstructions

During an ABUS examination, three volumes are obtained for each breast: frontal (anterior-posterior) with the nipple in the center of the image, lateral, which includes the upper outer part of the breast tissue with the nipple located in the lower-middle corner, and central, which includes the inner and lower part of the breast tissue. The technician also marks the nipple in the image, allowing a more accurate assessment of the breast. Additional views of the upper and lower parts of the breast are required for large breasts.

Each of the three projections is obtained in up to 300 2D images, which are then used for a multiplanar reconstruction of the entire breast, from the skin to the chest wall. In particular, the frontal plane, also known as the 'surgical plane', is essential in the review phase. In fact, the standardized revision process for quick navigation is based on the frontal plane.

During the scan, its depth should be assessed to ensure that both the deep and peripheral parts of the breast tissue are contained within the imaging field and should

range from 3.5 to 5 cm, depending on breast size for small, medium and large breasts respectively.

Normally, three 1-minute scans are sufficient to scan the whole breast excluding the axillary fossa. The average overall time for a full examination is approximately 15 minutes.

Once acquired by technicians, the data are saved and transferred to diagnostic stations, where radiologists can review them using both original and reconstructed scans at any time. Hence, because images can be reviewed retrospectively, ABUS increases reproducibility, as well as reduces operator dependence and physician time.

Advantages of ABUS

ABUS is a technique that separates the moment of image acquisition (performed in ABUS by an electro-radiology technician) from the moment of image interpretation (performed by a radiologist), thus reducing operator dependence as well as physician's time. The examination can be repeatedly reviewed by many physicians at different times, so the technique was developed to standardize breast ultrasound and eliminate some of the limitations of RUSG, such as operator dependence and examination time⁽²¹⁾. Compared to HHUS, the ABUS technique has a larger FOV and can produce multiplanar reconstructions, including 3D, which allows focal lesions to be assessed in different planes and characterized more accurately, as well as providing new diagnostic data.

One of the most significant conveniences of ABUS is the ability to obtain a frontal reconstruction – the breast is visible in this plane as on the operating table, which is why it is referred to as the “surgical plane”. This view improves the assessment of lesion margins. The frontal plane allows reconstruction of the ductal system of the whole breast, which facilitates the detection of ductal dilatation associated with intraductal papillary lesions and even ductal carcinoma in situ by detecting intraluminal echoes in dilated milk ducts. Benign lesions are often surrounded by a continuous hyperechoic border, whereas malignant lesions often have a discontinuous and irregular hyperechoic border that corresponds to a desmoplastic reaction. In this plane, the retraction phenomenon and the desmoplastic reaction are also more pronounced – characteristics of malignant lesions infiltrating the surroundings, which can be described as “black holes” in the reconstruction in the frontal plane (these phenomena are manifested by straight hyperechoic lines radiating from the center of the tumor). The retraction phenomenon has been shown to be associated with smaller tumor size, lower grade and positive receptor status.

ABUS provides accurate and reproducible data on breast lesion location, size and assessment of ultrasound features, which is invaluable for comparison with examinations of different modalities, as well as in clinical situations requiring follow-up imaging.

Limitations of ABUS

Peripherally located lesions may be missed out in ABUS. This technical drawback reduces the diagnostic performance of the method compared to HHUS, especially in large breasts, and may account for cancer misdiagnosis. The electroradiologist should be aware of this aspect and scan the whole breast, obtaining additional acquisitions from the upper and lower parts of the breast.

The main limitation of ABUS is the inability to assess the axillary region and the lack of data on the nodal status. In women with small breasts, only the base floor of the axillary fossa can be included in the examination.

Another disadvantage is the lack of tools to assess vascularization and elasticity of breast tissue. However, there is some progress in this area. Hendriks *et al.* proposed a method of quasi-static 3D ultrasound elastography on an ABUS-type device in a preclinical setting⁽²²⁾. Wang *et al.* tested a 3D motion tracking system that apparently can effectively track the displacement of lesions in three planes, thus providing information on their elasticity⁽²³⁾.

Additionally, the inability to perform invasive procedures is an important limitation, so lesions detected with ABUS and requiring further evaluation should be reassessed with RUSG. Although the effectiveness of ABUS has been demonstrated in many studies, artifacts may reduce diagnostic value.

Artifacts

Creasing (or rippling) is one of the most common artifacts. Since it is generated by respiratory movements, it is very important that the patient does not cough or talk during the examination. It is also crucial to ensure uniform compression and adequate positioning of the breast and to avoid insufficient gel application. Shadowing that occurs at the border of fat lobules due to the failure to implement the above measures is another important artifact.

Standard ultrasound gel is not used for ABUS due to potential artifacts that can be caused by small gas bubbles. To avoid this, a gel (liquid) specially developed for this purpose, which has the consistency of a homogeneous lotion, is used⁽²⁴⁾. If the lotion used is not evenly distributed and is missing in some regions, air enters between the transducer and the skin, sound waves are reflected by the air between the transducer membrane and the skin, causing shadowing, and visualization of the underlying glandular tissue becomes impossible.

If the transducer is not evenly and sufficiently pressed against the breast, air is introduced at the edges of image acquisition, making the analysis of glandular parenchyma at the periphery difficult. Insufficient compression may also cause artifacts caused by Cooper's ligaments, which may be reduced by adequate compression performed by the electroradiologist.

Research to date on ABUS

So far, ABUS has been shown to improve breast cancer screening detection rates and sensitivity when used as an adjunct tool to mammography compared to mammography alone.

Tabár *et al.* conducted an observational, multicenter study in 15,318 asymptomatic women with dense breasts and no increased risk of breast cancer to assess how ABUS, as an adjunct to screening mammography, improves breast cancer detection compared to mammography alone⁽²⁵⁾. Screening mammography and ABUS were performed in each patient, and a follow-up examination was performed after one year. Breast cancer was diagnosed in 112 participants, of which 82 cancers were diagnosed by mammography and further 30 were seen on ABUS alone. Of the cancers detected by mammography, 62.2% were found to be invasive forms, whereas up to 93.3% of the lesions seen in ABUS were assessed as invasive cancers. Seventeen cancers were visible only on mammography and 67.4% of them turned out to be DCIS. In contrast, DCIS accounted for only 6.7% of cancers detected by ABUS alone. These results suggest that mammography remains the primary method of detecting carcinomas in situ, and that the majority of lesions detected by ABUS are invasive cancers. The majority of cancers detected by ABUS were lower grade (66.7% – IA and IB). Supplementing mammography with ABUS increased cancer detection by

1.9 per 1000 patients compared with mammography alone and increased sensitivity by 26.7%, demonstrating that the additional use of ABUS increases the detection of silent cancer in women with dense breasts. However, there was a 13.4% decrease in specificity.

Wilczek *et al.* also conducted an observational study in a group of 1668 asymptomatic women with dense breasts (ACR3 and ACR4) at varying risk of breast cancer. They showed that supplementing screening mammography with ABUS increased cancer detection by 2.4 per 1000 patients and resulted in a 36.4% increase in sensitivity and a relatively small (0.7%) decrease in specificity⁽²⁶⁾.

Compared with HHUS, ABUS is still under investigation for various clinical aspects: detection rates and characteristics of breast lesions, diagnostic efficiency, sensitivity and specificity, inter-observer concordance, and use in preoperative diagnosis or *second-look* assessment. To date, several scientific studies comparing ABUS and HHUS have been conducted, some in moderately large groups of patients.

Vourtsis *et al.* conducted a prospective clinical study involving 1886 women with ACR C and D breast density⁽²⁷⁾. In patients over 40 years of age and younger with a positive family history of breast cancer, FFDM was performed, and the degree of breast density was assessed on this basis. In all participants, HHUS and ABUS were performed and breast density was determined from the FFDM image. In the absence of FFDM, the assessment was based on the presence of homogeneous or heterogeneous stromal echostructure in ultrasonography. ABUS was assessed according to a standardized protocol, according to which the anteroposterior projections were initially analyzed – as a reference projection for the assessment of the whole breast, followed by the transverse sections. The average interpretation time for the three projections for each breast in each patient was 3 min. Focal lesions in HHUS and ABUS were characterized by assessing the following features: shape, echogenicity, orientation of the lesion, contours, echogenicity of the lesion contour, the presence of acoustic shadow behind the lesion, calcifications and additional features; each was assessed with the BI-RADS scoring system. The score was also assigned on the basis of mammography. BI-RADS 4 and 5 lesions were further verified by coarse needle biopsy or surgery. The concordance between ABUS and HHUS was 99.8%. In a few cases, there was a surprising underestimation of lesions in HHUS relative to ABUS. In two situations, lesions were graded BI-RADS 1 in HHUS and BI-RADS 4 in ABUS – the lesions in both patients were verified by biopsy as a *radial scar*. In one case, HHUS was graded BI-RADS 2 and ABUS was graded BI-RADS 5 – histopathological verification of the lesion showed invasive lobular carcinoma. The majority of lesions graded BI-RADS 2 on mammography corresponded to BI-RADS 2 on ABUS. In 16 cases of BI-RADS 0 on mammography, ABUS was graded BI-RADS 4 – the lesions were verified as benign. Three cancers were graded BI-RADS 2 in mammography, BI-RADS 4 in ABUS, another two were also assigned

BI-RADS 2 in mammography and BI-RADS 5 in ABUS. On the other hand, in 12 cases ABUS was graded BI-RADS 2 and mammography was graded BI-RADS 4. Of these cases, 7 turned out to be DCIS, the rest were benign lesions. Of the 78 patients with palpable breast lesions, 48 had a “zigzag sign” – generated in the frontal plane due to scan interference, suggesting that this symptom should alert the interpreter to the possible presence of a palpable breast lesion. The above study showed comparable results of ABUS and HUSS, and even slight superiority of ABUS over HUSS, especially in the context of architectonic abnormalities of glandular parenchyma detected in the frontal planes and satellite foci. With regard to mammography, ABUS contributed to the detection of calcification-free cancers, especially those masked by dense glandular tissue. However, mammography has proven to be the best method for detecting DCIS due to the visualization of microcalcifications.

Depretto *et al.* conducted a retrospective study comparing ABUS and HUSS in a group of dense breast patients (ACR C and D) with a history of breast cancer, who were searched for the foci of recurrence and new ipsilateral or contralateral carcinomas at annual follow-up⁽²⁸⁾. The study included 154 patients after breast-conserving treatment who underwent HHUS and ABUS follow-up mammography. The study showed significant concordance between ABUS and HUSS, with all cancers found by HUSS also detected by ABUS (Fig. 10). The BI-RADS score in HHUS and ABUS differed in 20% of cases, but these were clinically insignificant results due to the additional detection of benign lesions that did not require verification. As shown in the above study, ABUS can play an important role in monitoring patients with dense breasts after breast cancer sparing treatment as an adjunct to mammography, which is the “gold standard.”

In their study including 213 patients, Wang *et al.* showed the sensitivity of ABUS compared to HHUS as 95.6% vs 90.3% and specificity of 80.5% vs 82.5%⁽²⁹⁾. Jeh *et al.* described a sensitivity of 88% vs 95.7% and specificity of 76.2% vs 49.4% in their study in 173 patients⁽³⁰⁾.

In their prospective clinical study, Hellgrena *et al.* compared the sensitivity and specificity of ABUS and HHUS in detecting breast cancer in women who had a mammogram performed⁽³¹⁾. The study included 113 patients with suspicious breast lesions on screening FFDM. This was followed by an additional HHUS and ABUS examination. The methods assessed each breast and each lesion separately, classifying them as: breasts with suspected malignancy on mammography and breasts with negative mammography. A total of 26 cancers were detected in 25 women. In the case of breasts with mammographic suspicion of cancer, the sensitivity was 88% for both ABUS and HHUS, and the specificity was 93.5% for HHUS and 89.2% for ABUS. The sensitivity was 100% for the two methods involving mammography-negative breasts, and the specificity was 100% for HHUS and 94.1% for ABUS. Therefore, ABUS appears to be a suitable method that can replace HHUS in women with

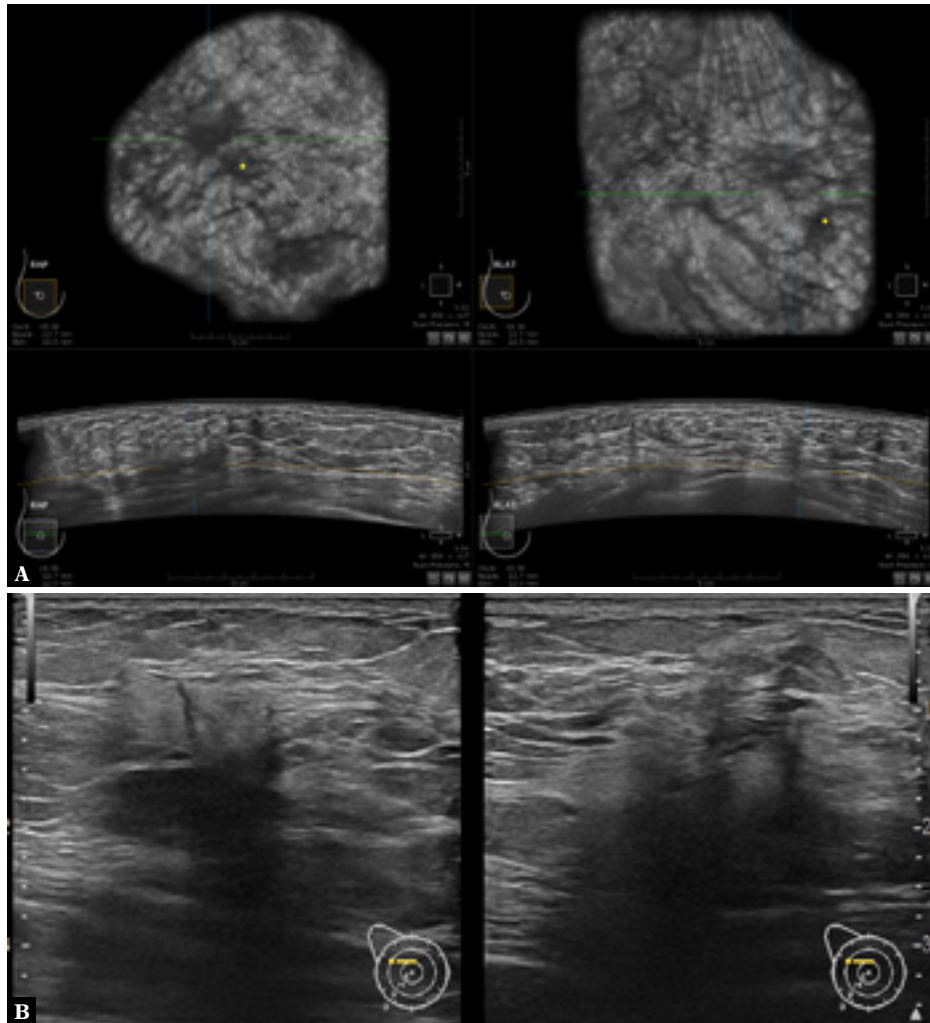


Fig. 10. Breast cancer. ABUS (A) vs RUSG (B)

a suspicious lesion found on screening mammography. An important aspect worth mentioning is that HHUS provides valuable information and allows better scanning of the suspicious region. Additionally, the experience and knowledge of the physician performing HHUS improves the quality of the diagnosis.

Some studies have looked at the effectiveness of ABUS compared with HHUS in the preoperative assessment of cancer. ABUS was more accurate than HHUS in assessing the extent of disease and the size of malignant lesions, with the estimated diameter and total volume being the most important parameters in the preoperative assessment of the true extent of the lesion⁽³²⁾.

Conclusions

Mammography is the primary screening method for breast cancer, with a proven contribution to reduced breast cancer mortality, and is considered the “gold standard”. There are

many methods that are valuable adjuncts to mammography, but ABUS, as an ultrasound technique overcoming many disadvantages of HHUS, is emerging as a promising tool to detect more cancers compared to mammography alone, especially in dense glandular breasts.

Conflict of interest

The authors do not report any financial or personal connections with other persons or organizations which might negatively affect the contents of this publication and/or claim authorship rights to this publication.

Author contributions

Original concept of study: EL. Writing of manuscript: EL, MP, WR. Analysis and interpretation of data: EL, MP. Final acceptance of manuscript: EL, TP, WR. Collection, recording and/or compilation of data: EL, MP. Critical review of manuscript: TP, WR.

References

- Sung H, Ferlay J, Siegel RL, Laversanne M, Soerjomataram I, Jemal A *et al.*: Global cancer statistics 2020: GLOBOCAN estimates of incidence and mortality worldwide for 36 cancers in 185 countries. *CA Cancer J Clin* 2021; 71: 209–249.
- Niell BL, Freer PE, Weinfurter RJ, Arleo EK, Drukteinis JS: Screening for breast cancer. *Radiol Clin North Am* 2017; 55: 1145–1162.
- Duffy SW, Tabár L, Chen HH, Holmqvist M, Yen M-F, Abdsalah S *et al.*: The impact of organized mammography service screening on breast carcinoma mortality in seven Swedish counties. *Cancer* 2002; 95: 458–469.
- Carney PA, Miglioretti DL, Yankaskas BC, Kerlikowske K, Rosenberg R, Rutter CM *et al.*: Individual and combined effects of age, breast density, and hormone replacement therapy use on the accuracy of screening mammography. *Ann Intern Med* 2003; 138: 168–175.
- Boyd NF, Guo H, Martin LJ, Sun L, Stone J, Fishell E *et al.*: Mammographic density and the risk and detection of breast cancer. *N Engl J Med* 2007; 356: 227–236.
- Harvey JA, Bovbjerg VE: Quantitative assessment of mammographic breast density: relationship with breast cancer. *Radiology* 2004; 230: 29–41.
- Freer PE: Mammographic breast density: impact on breast cancer risk and implications for screening. *Radiographics* 2015; 35: 302–315.
- Carmona-Sanchez E, Cuadros Lopez JL, Cuadros Celorrio AM, Perez-Roncero G, Gonzalez Ramirez AR, Fernandez Alonso AM: Assessment of mammographic density in postmenopausal women during long term hormone replacement therapy. *Gynecol Endocrinol* 2013; 29: 1067–1070.
- Yuan W-H, Hsu H-C, Chen Y-Y, Wu C-H: Supplemental breast cancer-screening ultrasonography in women with dense breasts: a systematic review and meta-analysis. *Br J Cancer* 2020; 123: 673–688.
- Berg WA, Blume JD, Cormack JB, Mendelson EB, Lehrer D, Böhm-Vélez M *et al.*: Combined screening with ultrasound and mammography vs mammography alone in women at elevated risk of breast cancer. *JAMA* 2008; 299: 2151–2163.
- Malur S, Wurdinger S, Moritz A, Michels W, Schneider A: Comparison of written reports of mammography, sonography and magnetic resonance mammography for preoperative evaluation of breast lesions, with special emphasis on magnetic resonance mammography. *Breast Cancer Res* 2001; 3: 55–60.
- Buchanan CL, Morris EA, Dorn PL, Borgen PI, Van Zee KJ: Utility of breast magnetic resonance imaging in patients with occult primary breast cancer. *Ann Surg Oncol* 2005; 12: 1045–1053.
- Argus A, Mahoney MC: Indications for breast MRI: case-based review. *Am J Roentgenol* 2011; 196: WS1–WS14.
- Michell MJ, Iqbal A, Wasan RK, Evans DR, Peacock C, Lawinski CP *et al.*: A comparison of the accuracy of film-screen mammography, full-field digital mammography, and digital breast tomosynthesis. *Clin Radiol* 2012; 67: 976–981.
- Poplack SP, Tosteson TD, Kogel CA, Nagy HM: Digital breast tomosynthesis: initial experience in 98 women with abnormal digital screening mammography. *Am J Roentgenol* 2007; 189: 616–623.
- Tagliafico A, Astengo D, Cavagnetto F, Rosasco R, Rescinito G, Monetti F *et al.*: One-to-one comparison between digital spot compression view and digital breast tomosynthesis. *Eur Radiol* 2012; 22: 539–544.
- Conant E, Barlow W, Herschorn SD, Weaver DL, Beaber EF, Tosteson ANA *et al.*: Association of digital breast tomosynthesis vs digital mammography with cancer detection and recall rates by age and breast density. *JAMA Oncol* 2019; 5: 635–642.
- Förnvik D, Zackrisson S, Ljungberg O, Svahn T, Timberg P, Tingberg A *et al.*: Breast tomosynthesis: accuracy of tumor measurement compared with digital mammography and ultrasonography. *Acta Radiol* 2010; 51: 240–247.
- Lewin JM, Isaacs PK, Vance V, Larke FJ: Dual-energy contrast-enhanced digital subtraction mammography: feasibility. *Radiology* 2003; 229: 261–268.
- Dromain C, Baileguier C, Muller S, Mathieu MC, Rochard F, Opolon P *et al.*: Evaluation of tumor angiogenesis of breast carcinoma using contrast-enhanced digital mammography. *Am J Roentgenol* 2006; 187: W528–W537.
- Kim SH, Kim HH, Moon WK: Automated breast ultrasound screening for dense breasts. *Korean J Radiol* 2020; 21: 15–24.
- Hendriks GAGM, Holländer B, Menssen J, Milkowski A, Hansen HHG, De Korte CL: Automated 3D ultrasound elastography of the breast: a phantom validation study. *Phys Med Biol* 2016; 61: 2665–2679.
- Wang Y, Nasief HG, Kohn S, Milkowski A, Clary T, Barnes S *et al.*: Three-dimensional ultrasound elasticity imaging on an automated breast volume scanning system. *Ultrason Imaging* 2017; 39: 369–392.
- van Zelst JCM, Mann RM: Automated three-dimensional breast US for screening: technique, artifacts, and lesion characterization. *Radiographics* 2018; 38: 663–683.
- Brem RF, Tabár L, Duffy SW, Inciardi MF, Guingrich JA, Hashimoto BE *et al.*: Assessing improvement in detection of breast cancer with three-dimensional automated breast US in women with dense breast tissue: the SonoInsight Study. *Radiology* 2015; 274: 663–673.
- Wilczek B, Wilczek HE, Rasouliyan L, Leifland K: Adding 3D automated breast ultrasound to mammography screening in women with heterogeneously and extremely dense breasts: report from a hospital-based, high-volume, single-center breast cancer screening program. *Eur J Radiol* 2016; 85: 1554–1563.
- Vourtsis A, Kachulis A: The performance of 3D ABUS versus HHUS in the visualisation and BI-RADS characterisation of breast lesions in a large cohort of 1,886 women. *Eur Radiol* 2018; 28: 592–601.
- Depretto C, Liguori A, Primolevo A, Di Cosimo S, Cartia F, Ferranti C *et al.*: Automated breast ultrasound compared to hand-held ultrasound in surveillance after breast-conserving surgery. *Tumori* 2021; 107: 132–138.
- Wang H-Y, Jiang Y-X, Zhu Q-L, Zhang J, Dai Q, Liu H *et al.*: Differentiation of benign and malignant breast lesions: a comparison between automatically generated breast volume scans and handheld ultrasound examinations. *Eur J Radiol* 2012; 81: 3190–3200.
- Jeh SK, Kim SH, Choi JJ, Jung SS, Choe BJ, Park S *et al.*: Comparison of automated breast ultrasonography to handheld ultrasonography in detecting and diagnosing breast lesions. *Acta Radiol* 2016; 57: 162–169.
- Hellgren R, Dickman P, Leifland K, Saracco A, Hall P, Celebioglu F: Comparison of handheld ultrasound and automated breast ultrasound in women recalled after mammography screening. *Acta Radiol* 2017; 58: 515–520.
- Chaoli X, Shuping W, Yingdong X, Xiaoxiang G, Bin Y: Three-dimensional assessment of automated breast volume scanner compared with handheld ultrasound in pre-operative breast invasive ductal carcinomas: a pilot study of 51 cases. *Ultrason Med Biol* 2016; 42: 2089–2096.