



Available online at www.sciencedirect.com

ScienceDirect

journal homepage: www.e-jds.com



Original Article

Comparison of virtual microscopy and real microscopy for learning oral histology laboratory course among dental students

Yu-Hsueh Wu ^{a,b}, Chun-Pin Chiang ^{c,d,e*}

^a Department of Stomatology, National Cheng Kung University Hospital, College of Medicine, National Cheng Kung University, Tainan, Taiwan

^b Institute of Oral Medicine, School of Dentistry, National Cheng Kung University, Tainan, Taiwan

^c Department of Dentistry, Hualien Tzu Chi Hospital, Buddhist Tzu Chi Medical Foundation, Hualien, Taiwan

^d Department of Dentistry, National Taiwan University Hospital, College of Medicine, National Taiwan University, Taipei, Taiwan

^e Graduate Institute of Oral Biology, School of Dentistry, National Taiwan University, Taipei, Taiwan

Received 8 April 2022

Available online 22 April 2022

KEYWORDS

Virtual microscopy;
Real light microscopy;
Oral histology;
Digitized virtual slide;
Traditional glass slide

Abstract *Background/purpose:* Virtual microscopy has been used for learning and teaching histology and pathology laboratory course for more than 10 years. This study aimed to compare the learning outcome of virtual microscopy with that of real light microscopy in oral histology laboratory course among dental students.

Materials and methods: The study included twenty-three undergraduate dental students who took the oral histology laboratory course. The evaluation methods of the study were divided into two parts: questionnaire survey (6 questions) and histological diagnosis ability assessment tests. The data were collected and analyzed statistically.

Results: Dental students showed a significantly higher acceptance rate of virtual microscopy than that of real light microscopy for learning oral histology laboratory course (all P -values < 0.01). Moreover, dental students using virtual microscopy with digitized virtual slides for learning oral histology laboratory course possessed significantly better histological diagnosis ability than those using real light microscopy with traditional glass slides for learning oral histology laboratory course ($P < 0.001$).

Conclusion: Virtual microscopy with digitized virtual slides seems to be a great method to learn oral histology laboratory course. Based on the results of our study, we believe that the virtual microscopy with digitized virtual slides may gradually replace the real light microscopy with traditional glass slides for learning and teaching oral histology laboratory course. We

* Corresponding author. Department of Dentistry, Hualien Tzu Chi Hospital, Buddhist Tzu Chi Medical Foundation, No. 707, Section 3, Chung-Yang Road, Hualien, 970, Taiwan.

E-mail address: cpchiang@ntu.edu.tw (C.-P. Chiang).

foresee that virtual microscopy with digitized microscopic images will be extensively applied in many fields in the near future.

© 2022 Association for Dental Sciences of the Republic of China. Publishing services by Elsevier B.V. This is an open access article under the CC BY-NC-ND license (<http://creativecommons.org/licenses/by-nc-nd/4.0/>).

Introduction

Virtual slides are digitized microscopic images of tissue sections, which can be stored and viewed in a web browser. The virtual microscopy with digitized virtual slides for teaching and learning of histology and pathology courses has been used for more than 10 years, and it might compensate or even replace traditional glass slides for their teaching purposes.¹ In addition to educational purposes in medical and dental schools, the virtual microscopy with digitized virtual slides has also been used in resident training programs and medical clinical routine use for diagnosis of diseases in general and oral histopathologic laboratories.²

As the digitized virtual slides are extensively applied in several fields. Virtual microscopy system has been introduced into the oral histology and oral pathology courses.^{3,4} Tauber et al.⁵ have already proved that students in both the dentistry and the general medicine courses preferred virtual histology slides compared to "classical" glass slides.⁵ For undergraduate dental students, oral histology is one of compulsory subjects and the main purpose of learning oral histology is to understand microanatomy of oral structures and further to discover the correlation between oral structures and their functions. Traditionally, oral histology course includes physical class room lectures and the study of glass slides of oral tissue sections by light microscopy.⁶ However, the real light microscope and traditional glass slides require a considerable cost in acquisition and maintenance. Color-fading of the stained tissue sections on the glass slides may occur a few years later and it needs to replace the old and color-fading glass slides after a certain period of time. In addition, viewing the glass slides with tissue sections under a light microscope should be carried out in the school laboratory room. Thus, the real light microscopy with traditional glass slides seems to have many limitations.

The purpose of this study was to compare the learning outcome of virtual microscopy using digitized virtual slides with that of real light microscopy using traditional glass slides for learning oral histology laboratory course among dental students. In addition, we tried to evaluate students' acceptance rates and their histological diagnosis abilities after finishing the teaching of oral histology laboratory course with either virtual or real microscopy system.

Materials and methods

Participants

A total of 23 undergraduate dental students who took the oral histology laboratory course in the School of Dentistry,

National Cheng Kung University in the first semester of the third year of the university were included in this study. They had taken the compulsory course entitled "histology" before they took the oral histology laboratory course. Therefore, they have equipped with the basic knowledge and skills to identify the anatomical structures under a microscope.

Teaching materials

The digitized virtual slides were incorporated into the oral histology laboratory course as the improved teaching materials. We selected tissue sections from vital oral structures with typical histological features for making the digitized virtual slides. The prepared glass slides could further be classified into categories such as oral mucosae, salivary glands, and dental hard tissues including teeth and jawbones. The glass slides of these cases were scanned and turned into digitized virtual slides, which were then stored in the hard discs of a computer. To get better images, the 40 × magnification was used for scanning the glass slides to make the digitized virtual slides. In addition, the collaborative virtual microscopy system was also introduced for viewing these digitized virtual slides on the screen of a computer.

Teaching process

Digitized virtual slides were incorporated into the framework of oral histology laboratory course. Tutorials for the use of virtual microscopy system was set for the students before the class. In the weekly practical classes, digitized virtual slides were presented with annotations. Detailed worksheets were provided, and students were fully instructed. The students' acceptance rates, learning effectiveness, and learning outcomes of using virtual microscopy with digitized virtual slides to learn oral histology laboratory course were compared with those of using light microscopy with traditional glass slides to learn general histology laboratory course after finishing the teaching of the whole oral histology laboratory course at the end of the semester.

Evaluation methods

The evaluation methods of the study were divided into two parts: questionnaire survey and histological diagnosis ability assessment. A questionnaire was distributed to all dental students. The questionnaire mainly focused on the students' acceptance rate, effectiveness, ease of use, and usefulness for promoting cooperative discussion using either the virtual or glass slides. The students were asked to

answer the following 6 questions regarding the learning of oral histology laboratory course using either the virtual or glass slides: Q1) The operation method is desirable; Q2) Navigation of the learning system doesn't cause too much of inconvenience; Q3) This type of microscope and slide is easy to view; Q4) This teaching method is efficient; Q5) This teaching method is very helpful for me to learn oral histology; Q6) This teaching method can stimulate my interest in learning oral histology. The ratings of the above questions were scored with a scale of 1–5 (1, strongly disagree; 2, disagree; 3, neutral; 4, agree; and 5, strongly agree).

In addition, there was a space provided for extra comments about how virtual slides are compared with glass slides. For assessment of histological diagnosis ability, we used virtual slides of different oral structures to test students' histological diagnosis ability.

Statistical analysis

All data collected were stored in excel files and used for statistical analysis. The differences in the mean acceptance rates of various investigated items were compared between the virtual and glass slide learning methods for the oral histology laboratory course by Student's *t*-test. Moreover, the mean scores of students' histological diagnosis ability test after finishing the oral histology class were also compared by Student's *t*-test. The result was considered to be significant if the *P*-value was less than 0.05.

Results

In the study, digitized virtual slides were prepared as the teaching slides set. Comparing with those of the traditional glass slides, we assessed the students' mean acceptance rates and mean scores of histological diagnosis ability test after finishing the teaching of the whole oral histology laboratory course at the end of the semester. According to our observations in class, students generally responded well

and had a high acceptance rate of virtual microscopy learning using digitized virtual slides.

The results of questionnaire survey are shown in Fig. 1 and Table 1. There were 84.78% (117/138) of students who accepted and agreed with the learning of oral histology laboratory course using virtual microscopy with digitized virtual slides, and among them 54.35% (75/138) of the students strongly agreed. In contrast, there were 34.06% (47/138) of students who accepted and agreed with the learning of oral histology laboratory course using real light microscopy with traditional glass slides, and among them 15.22% (21/138) of the students strongly agreed (Fig. 1). Most dental students preferred learning of oral histology laboratory course using digitized virtual slides rather than using traditional glass slides. Statistical analysis showed that the mean acceptance rates of 6 items in the questionnaire were all significantly higher in dental students using the digitized virtual slides than in dental students using the traditional glass slides (Student's *t*-test, all *P*-values < 0.01, Table 1).

The results of the final test of students' histological diagnosis ability are shown in Fig. 2 and Table 1. The test scores might represent students' learning outcomes after finishing the teaching of the whole oral histology laboratory course and their acquired histological diagnosis ability from the class. Regarding the learning of oral histology laboratory course using digitized virtual slides, all students in this study obtained A grade in the test scores. On the other hand, the learning of general histology laboratory course using traditional glass slides, there were 12 and 5 students who obtained A and B grades in the test scores, respectively. To further convert these grades into numerical scale, we found that the mean test score was significantly higher after virtual slide learning than that after the glass slide learning. The mean test scores were 4.12 ± 0.19 ($n = 23$) for virtual slide learning and 3.23 ± 1.08 ($n = 23$) for glass slide learning, respectively. Statistical analysis showed that the dental students using the virtual microscopy with digitized virtual slides obtained significantly better learning

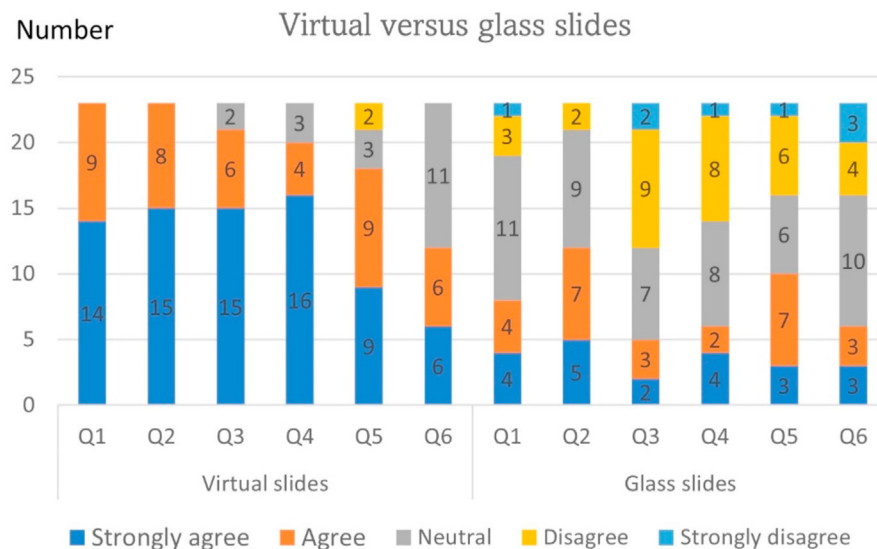


Figure 1 The number of students who answered to the 6 questions after finishing the learning of oral histology laboratory course using either digitized virtual slides or traditional glass slides.

Table 1 The mean acceptance rates of 6 questions regarding the learning of oral histology laboratory course using either virtual or glass slides and the mean scores of students' histological diagnosis ability test.

| | Mean \pm standard deviation | | P-value |
|-------------------------------|-------------------------------|-----------------|---------|
| | Virtual slides | Glass slides | |
| Q1 | 4.61 \pm 0.49 | 3.30 \pm 1.04 | <0.001 |
| Q2 | 4.65 \pm 0.48 | 3.65 \pm 0.91 | <0.001 |
| Q3 | 4.57 \pm 0.65 | 2.74 \pm 1.07 | <0.001 |
| Q4 | 4.57 \pm 0.71 | 3.00 \pm 1.14 | <0.001 |
| Q5 | 4.09 \pm 0.93 | 3.22 \pm 1.10 | <0.01 |
| Q6 | 3.78 \pm 0.83 | 2.96 \pm 1.16 | <0.01 |
| Mean scores (grade points) | 4.12 \pm 0.19 | 3.23 \pm 1.08 | <0.001 |

outcomes and significantly better histological diagnosis ability than the dental students using the real light microscope with traditional glass slides (Student's *t*-test, $P < 0.001$, Table 1).

In addition to the above-mentioned items, there were some extra comments given by the student on how virtual slides were compared with glass slides. They mentioned that synchronous sharing of the virtual images between the instructor and students makes the demonstration and feedback easily. They can also share these virtual images with other dental students in different dental schools. However, poor internet connections might sometimes slow down the connection speed and interrupt the teaching.

Discussion

Microscopic slides of oral tissue sections can help dental students to recognize the oral structures and further to link to their functions. The light microscopy with glass slide set were predominantly used in oral histology laboratory class

in the past. However, there are many shortcomings of the light microscopy, such as a considerable cost in acquisition and maintenance of microscopes. Color-fading of the stained tissue sections on the glass slides might have a bad effect on interpretations of microscopic structures. Besides, viewing the tissue sections under a light microscope with glass slides should be restricted to certain places such as the school laboratory room so that we cannot observe these glass slides everywhere and anytime we like. Due to the advancements in computer technology, the virtual microscopy system has been developed and utilized in many fields, including histology and pathology classes, resident training course, and clinical use in pathological department for routine diagnoses of surgical or biopsy specimens. There are several advantages of the virtual microscopy system, such as the improved quality of the images, the ease of handling the images for publication and for consultation, the effective use of virtual slides during the laboratory histopathological diagnosis practice, and the convenient access of the virtual slides at any places with a computer and the internet connection. All above-mentioned advantages seem to be able to overcome the shortcomings of real light microscopy with traditional glass slides.

In this study, we found that dental students showed a significantly higher acceptance rate of virtual microscopy than that of light microscopy in all six items (all P -values < 0.01), including whether the operation method is desirable, whether the navigation of the learning system causes any inconvenience, whether the type of microscope and slide is easy-to-view, whether the teaching method is efficient, whether this teaching method is helpful for learning oral histology, and whether this teaching method can stimulate the interest in learning oral histology. In addition, it was also discovered that dental students using virtual microscopy with digitized virtual slides often got significantly better histological diagnosis ability than those using light microscopy with traditional glass slides ($P < 0.001$). Similar results were also obtained by Szymas and Lundin,⁷ who conducted a 5-year research to evaluate the web-based

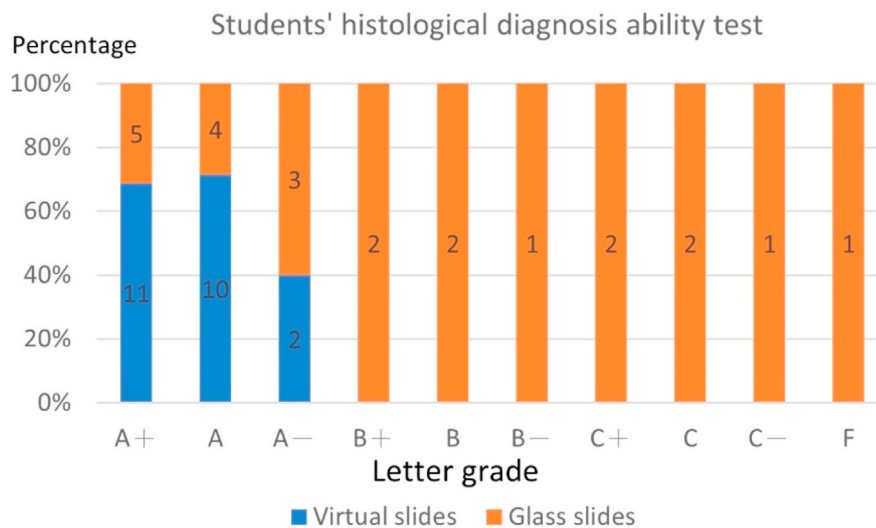


Figure 2 The scores of students' histological diagnosis ability test after finishing the learning of oral histology laboratory course using either virtual or glass slides.

virtual microscopy for teaching and learning basic and oral pathology among dental students. They recruited over 400 fully digitized virtual slides which covering 15 entities in basic and systemic pathology as well as 15 entities in oral pathology. The virtual microscopy as a didactic tool was rated over 8 on a 10-point scale for basic and systemic pathology and 9 for oral pathology especially. Besides, the quality of the images was rated as very good. An overwhelming majority of the students considered that the use of virtual slides is highly desirable and there is also a significant improvement.⁷ Kumar et al.¹ also employed virtual slides in the pathology lectures, tutorials, and practical class among 45–55 students. They then obtained questionnaires from 152 of 212 students and found overwhelmingly support of the introduction of virtual microscopy. Moreover, 124 of 152 students indicated that the virtual microscopy system solves problems they have experienced when using a binocular microscope. Detailed comments included that it doesn't hurt my eyes, it provides clear image always in focus, it is much better and faster to use, it is more efficient, it supplies less dizzy and less fussy images for quicker learning, it is more convenient to use, and it shows about same quality image if not better.¹

However, another research launched by Koch et al.² compared the diagnostic accuracy and acceptability of the digitized virtual slides with those of traditional glass slides in diagnosing dermatopathology disorders. Residents in dermatology and pathology training programs at 14 institutions were given a randomized combination of 20 virtual and traditional glass slides and were asked to give their impressions. The results showed that there is little difference in diagnosing dermatopathology disorders using virtual slides or glass slides ($P = 0.70$). Besides, some disadvantages of the virtual microscopy system have been proposed, including "fuzzy image" (31%), poor screen color (10%), freezing of the screen (9%), poor screen contrast (8%), problems starting imaging software (5%), unable to adjust the computer's monitor (3%), computer failure (2%), and power failure (1%).²

Furthermore, the worldwide outbreak of Covid-19 pandemic leads to the cancellation of face-to-face teaching in many school courses. Thus, the majority of the lectures in dental schools are switched to the online mode to keep on the learning progress of relevant courses for their dental students.⁸ The virtual microscopy system can be performed online to give the oral histology laboratory course, which also highlights its importance under the COVID-19 pandemic. Besides, Saverino and Zarcione⁹ pointed out that most students appreciate the digital equipment in laboratory exercises and the bidirectional communication about live transmissions of images simultaneously is considered to be useful by 97% of students.⁹

We conclude that the virtual microscopy seems to be beneficial to oral histology laboratory course. Although

there are still some problems existing, we believe that the virtual microscopy with digitized virtual slides plays a key role in teaching and learning oral histology laboratory course, especially under the COVID-19 pandemic. Based on the results of this study, it may be practical to integrate the virtual microscopic images into the framework of oral histology class. Advanced establishment of an online oral histology and oral pathology learning platform may be carried out in the future, which can even promote the interactions between different dental schools, enriching the resources of the oral histology teaching slides.

Declaration of competing interest

The authors have no conflicts of interest relevant to this article.

Acknowledgments

This study was supported by the grant (MOST 110-2314-B-006-059) of Ministry of Science and Technology, Taiwan.

References

1. Kumar RK, Velan GM, Korell SO, Kandara M, Dee FR, Wakefield D. Virtual microscopy for learning and assessment in pathology. *J Pathol* 2004;204:613–8.
2. Koch LH, Lampros JN, DeLong LK, Chen SC, Woosley JT, Hood AF. Randomized comparison of virtual microscopy and traditional glass microscopy in diagnostic accuracy among dermatology and pathology residents. *Hum Pathol* 2009;40:662–7.
3. Sharmin N, Chow AK, Dong AS, Milos NC. Histoscope: a web-based microscopy tool for oral histology education. *Healthc Inform Res* 2021;27:146–52.
4. Chang JYF, Lin TC, Wang LH, Cheng FC, Chiang CP. Comparison of virtual microscopy and real microscopy for learning oral pathology laboratory course among dental students. *J Dent Sci* 2021;16:840–5.
5. Tauber Z, Cizkova K, Lichnovska R, et al. Evaluation of the effectiveness of the presentation of virtual histology slides by students during classes. Are there any differences in approach between dentistry and general medicine students? *Eur J Dent Educ* 2019;23:119–26.
6. Nanci A. Structure of the oral tissues. In: Nanci A, ed. *Ten cate's oral histology*, 9th ed. St Louis: Elsevier, 2018:1–11.
7. Szymas J, Lundin M. Five years of experience teaching pathology to dental students using the web microscope. *Diagn Pathol* 2011;6:S13.
8. Caruso MC. Virtual microscopy and other technologies for teaching histology during Covid-19. *Anat Sci Educ* 2021;14:19–21.
9. Saverino D, Zarcione D. Keeping histology students under the microscope during Covid-19 lockdown: lessons learned from the University of Genoa. *Anat Sci Educ* 2022;15:86–8.