

New perspectives in the management of small cell lung cancer

Cristina Pangua, Jacobo Rogado, Gloria Serrano-Montero, José Belda-Sanchís, Beatriz Álvarez Rodríguez, Laura Torrado, Nuria Rodríguez De Dios, Xabier Mielgo-Rubio, Juan Carlos Trujillo, Felipe Couñago

Specialty type: Oncology

Provenance and peer review:

Invited article; Externally peer reviewed.

Peer-review model: Single blind

Peer-review report's scientific quality classification

Grade A (Excellent): 0

Grade B (Very good): 0

Grade C (Good): 0

Grade D (Fair): 0

Grade E (Poor): 0

P-Reviewer: Chen C, China

A-Editor: Ma L, China

Received: April 18, 2021

Peer-review started: April 18, 2021

First decision: July 16, 2021

Revised: September 5, 2021

Accepted: May 22, 2022

Article in press: May 22, 2022

Published online: June 24, 2022



Cristina Pangua, Jacobo Rogado, Gloria Serrano-Montero, Department of Medical Oncology, Hospital Universitario Infanta Leonor, Madrid 28031, Spain

José Belda-Sanchís, Department of Thoracic Surgery, Hospital de la Santa Creu i Sant Pau & Hospital de Mar, Universitat Autònoma de Barcelona, Barcelona 08041, Catalonia, Spain

Beatriz Álvarez Rodríguez, Department of Radiation Oncology, Hospital Universitario HM Sanchinarro, HM Hospitales, HM CIOCC Centro Integral Oncológico Clara Campal, Madrid 28050, Spain

Laura Torrado, Department of Radiation Oncology, Hospital Universitario Lucus Augusti & Instituto de Investigación Sanitaria Santiago de Compostela (IDIS), Lugo 27003, Spain

Nuria Rodríguez De Dios, Department of Radiation Oncology, Hospital Del Mar & Hospital Del Mar Medical Research Institute (IMIM) & Pompeu Fabra University, Barcelona 08003, Catalonia, Spain

Xabier Mielgo-Rubio, Department of Medical Oncology, Alcorcón Foundation University Hospital, Alcorcón 28922, Madrid, Spain

Juan Carlos Trujillo, Department of Thoracic Surgery, Hospital de la Santa Creu i Sant Pau, Barcelona 08029, Spain

Felipe Couñago, Department of Radiation Oncology, Hospital Universitario Quirónsalud Madrid, Hospital La Luz, Universidad Europea de Madrid, Madrid 28223, Spain

Corresponding author: Cristina Pangua, MD, Consultant Physician-Scientist, Department of Medical Oncology, Hospital Universitario Infanta Leonor, Av. Gran Vía del Este, 80, Madrid 28031, Spain. cristinapangua.2@gmail.com

Abstract

The treatment of small cell lung cancer (SCLC) is a challenge for all specialists involved. New treatments have been added to the therapeutic armamentarium in recent months, but efforts must continue to improve both survival and quality of life. Advances in surgery and radiotherapy have resulted in prolonged survival times and fewer complications, while more careful patient selection has led to increased staging accuracy. Developments in the field of systemic therapy have resulted in changes to clinical guidelines and the management of patients with advanced disease, mainly with the introduction of immunotherapy. In this article, we describe recent improvements in the management of patients with SCLC,

review current treatments, and discuss future lines of research.

Key Words: Small cell lung cancer; Whole-brain radiotherapy; Prophylactic cranial irradiation; Stereotactic body radiotherapy; Immunotherapy; Atezolizumab; Durvalumab

©The Author(s) 2022. Published by Baishideng Publishing Group Inc. All rights reserved.

Core Tip: The treatment of small cell lung cancer (SCLC) continues to be a challenge. Recent studies have described survival benefits achieved by new treatments or combinations of treatments that are both safe and effective. Immunotherapy has a new role in SCLC. Nevertheless, continued research efforts are needed. Here, we review the current management of SCLC and discuss recent improvements and future lines of research.

Citation: Pangua C, Rogado J, Serrano-Montero G, Belda-Sanchis J, Álvarez Rodríguez B, Torrado L, Rodríguez De Dios N, Mielgo-Rubio X, Trujillo JC, Couñago F. New perspectives in the management of small cell lung cancer. *World J Clin Oncol* 2022; 13(6): 429-447

URL: <https://www.wjgnet.com/2218-4333/full/v13/i6/429.htm>

DOI: <https://dx.doi.org/10.5306/wjco.v13.i6.429>

INTRODUCTION

Small cell lung cancer (SCLC) accounts for 14% of all lung cancers[1,2], and most cases are associated with tobacco use[3]. Although the global incidence of SCLC is falling, the ratio of male to female cases is currently 1:1[1,2]. SCLC is a fast-growing cancer, and most patients have extensive disease when diagnosed. In approximately one-third of cases, the cancer is limited to the thorax and can be treated with concurrent chemotherapy and radiotherapy. Just a small percentage of patients are amenable to surgery and adjuvant therapy. The goal of treatment in patients with extensive disease is to alleviate symptoms and prolong survival, although long-term survivorship in this setting is rare[4].

LIMITED-STAGE DISEASE

Surgical treatment of SCLC

Early-stage SCLC, stage I and IIA (T1-2N0M0) SCLC in the American Joint Committee on Cancer/International Union Against Cancer classification[5-7], accounts for 7% of all SCLCs and 0.29% of all lung cancers[8]. Numerous studies have shown excellent survival rates in patients with SCLC cT1-2N0M0 treated with surgery as part of a multimodal approach[6,9-28] (Table 1).

Surgical resection followed by adjuvant therapy is currently recommended by most clinical guidelines for operable stage I and IIA SCLC. Choice of adjuvant treatment varies according to pathologic tumor-node-metastasis stage: Chemotherapy for pN0, chemotherapy ± radiotherapy for pN1 and chemoradiotherapy for pN2[29-32] (Figure 1). The indications for the surgical treatment of SCLC can be summarized as follows: (1) Intraoperative diagnosis of a pulmonary SCLC nodule. Between 3% and 5% of SCLCs present as a pulmonary nodule. Multidisciplinary treatment involving surgical resection, systematic nodal dissection, and adjuvant chemotherapy or chemoradiotherapy can achieve survival rates comparable to those seen in non-SCLC[8]; (2) Diagnosis of stage I or IIA SCLC. Local or regional recurrence[33-39] (tumor and/or hilar-mediastinal lymph nodes) is the most common form of disease in patients who relapse after complete remission with chemoradiotherapy[40-45]. Surgery as part of a multimodal approach achieves better local disease control[46-50] than chemoradiotherapy[51-54]; (3) Mixed histology (SCLC with a non-SCLC component). Between 2% and 28% of patients have mixed SCLC/non-SCLC[55-59]. Recurrence or failure to respond to first-line chemotherapy is likely to be due to the non-SCLC component; and (4) Salvage surgery for local chemo-resistant SCLC or exclusively local recurrence after response to chemoradiotherapy. Selected patients in this setting might benefit from surgical resection[60-62].

Lobectomy is the preferred procedure for surgical resection, as it is associated with significantly better survival than sublobar resection[40,45,49,54,63]. The significant discrepancies observed between clinical and pathologic stages (mainly due to undetected lymph node metastasis before surgery) highlight the importance of accurate clinical nodal staging and systematic lymph node dissection[47, 64]. The recommendations for ruling out hilar and mediastinal lymph node involvement are very similar across the different guidelines. Ideally, clinical staging should be performed using semi-invasive

Table 1 Surgical and survival rates for patients with small cell lung cancer (period time revised 1999-2020) - (dash), lack of information or details

Ref.	Study type & time period. LoE	Inclusion criteria	Number of patients	Neoadjuvant/adjvant treatments	PCI	Survival data
Jin <i>et al</i> [9], 2018	RS; SEER 2004-2013; 3A	cI-II	n = 2129; S: 387; RT 1032; S + RT: 154; No S or RT: 556	-	-	5-yr OS T1N0: 46.0% S vs 23.8% RT; 5-yr OS T2N0: 42.6% S vs 24.7% RT; T3N0 or T1-2N1 (stage IIB) patients treated with S did not have higher 5-yr OS rates than those treated with RT
Yang <i>et al</i> [10], 2018	RS; NCDB 2003-2011; Propensity score match S + AC vs CRT; 3A	cT1-2N0M0	S + AC: 501; CRT: 501	S + AC: 501	-	5-yr OS: 47.6% S + AC vs 29.8% CRT (P < 0.01)
Ahmed <i>et al</i> [11], 2017	RS; SEER 2007-2013; 3A	Stage I SCLC	n = 1902; S: 427; S + RT: 115	-	-	MST: 50 mo (S); MST: 60 + mo (S + RT)
Wakeam <i>et al</i> [12], 2017	RS; NCDB 2004-2013; 3A	cT1-2N0M0	n = 5079	-	-	MST: 25.3 mo
Wakeam <i>et al</i> [13], 2017	RS; NCDB 2004-2013; Stage-specific propensity score match S vs NST; 3A	cI-III	n = 2619	No AD treatment 24% NC or NR 4%; AC 27%; AR 1%; ACR 32%; NC or NR and AC or AR 2%; Other 10%	-	MST cI 38.6 vs 22.9 mo S vs NST; MST cII 23.4 vs 20.7 mo S vs NST; MST cIIIA 21.7 vs 16.0 mo S vs NST
Combs <i>et al</i> [14], 2015	RS; NCDB 1998-2011; 3A	cT1-3N0-2 SCLC	n = 2476; S 841 cIA, 168 cIB	All; S: 68%	-	5-yr OS: 54% (cIA); 36% (cIB)
Ogawa <i>et al</i> [15], 2012	RS; Institutional 1995-2008; 4	cI-III; pI-III SCLC	n = 28 (23 SCLC before S); S 21 cI, 5 cII, 7 cIII2	NC 8; AC 19, ACR 2	-	5-yr OS 47%
Ju <i>et al</i> [16], 2012	RS; Institutional 1990-2009; 4	pI-III	n = 34	NC 3; AC 1, AR 19, 10 CRT	-	5-yr OS 66%
Vallières <i>et al</i> [6], 2009	RS; IASLC 1990-2000; 3A	Resected SCLC	n = 349 (68 pIA, 91 pIB)	-	-	5-yr OS: 53% (pIA); 44% (pIB)
Lim <i>et al</i> [17], 2008	RS; Institutional 1980-2007; 4	cI-cIIIB	n = 59	AC 13; AR 2; ACR 1	-	5-yr OS for all patients 52%; No difference in 5-yr survival across; cI and cN categories; No difference in 5-yr survival across; cI to cIII stages
Wang <i>et al</i> [18], 2007	RS; Institutional; 4	pI-III	n = 122	QT & CRT (not specified)	-	MST 50 mo; 5-yr OS 66%
Veronesi <i>et al</i> [19], 2007	RS; Institutional; 4	cI-IIIA	n = 23	AC all	-	MST 24 mo
Tsuchiya <i>et al</i> [20], 2005	Prospective phase II trial; 1991-1996; 2B	cI-IIIA	n = 62	AC 42 (69%)	-	MST not reached in pI; MST 449 d for pII; MST 712 d for pIIIA; 3-yr OS 61%; 3-yr survival rate cI, cII, cIIIA 68%, 56% and 13% respectively
Brock <i>et al</i> [21], 2005	RS; Institutional 1976-2002; 4	Resected SCLC	n = 82 (24 stage I, S + AC)	AC 55%	23%	5-yr OS: 86% (platinum AC); 42% (non-platinum AC)
Nakamura <i>et al</i> [22], 2004	RS; Institutional; 4	cI-III SCLC	n = 69	S 37, NC 32, AC 41, ACR 7	-	5-yr survival 48.9% cI, 33.3% cII, 20.2% cIIIA, 0% cIIIB
Badzio <i>et al</i> [23], 2004	Comparative RS; Institutional 1984-1996; 4	cI-III balanced in both, S and NST groups	n = 134	S 67 (all AC); NST 67 (all QT)	34% only S group	MST 22 mo (S); MST 11 mo (NST); 5-yr OS S 27%, NST 4%
Lewiński <i>et al</i> [24], 2001	R; Institutional 1976-2002; 4	cI-IIIA SCLC	n = 75	NC all	If CR to NC	MST N0+1 25 mo; MST N2 14 mo; MST resected 18 mo; 5-yr OS resected 29%
Cataldo <i>et al</i> [25], 2000	RS; Institutional 1982-1992; 4	cI-III SCLC	n = 60	AC 88%; pII AR (11%); pIII AR (21%)	41%	5-yr survival rate 40% pI, 36% pII and 15% pIII

Inoue <i>et al</i> [26], 2000	RS; Institutional 1975-1994; 4	Resected SCLC	n = 91 (32 cIA, 30 cIB)	All 78%	5.5%	MST 53 mo, 5-yr OS 49% (cIA); MST 25 mo, 5-yr OS 47% (cIB)
Kobayashi <i>et al</i> [27], 2000	RS; Institutional 1982-1992; 4	cI-III SCLC	n = 59	NC 71%	-	5-yr survival rate 55% pI, 33% pII, 23% pIII
Eberhardt <i>et al</i> [28], 1999	Prospective phase II trial; Institutional 1991-1995; 2B	cIB-cIIIB	n = 46	IB/IIA had NC + S; IIB/IIIA had NCR + S	-	MST all patients 36 mo; MST R0 patients 68 mo; 5-yr survival rate all patients 46%; 5-yr survival rate R0 patients 63%

ACR: Adjuvant chemoradiotherapy; AD: Adjuvant; AC: Adjuvant chemotherapy; cIA: Clinical stage IA; cIB: Clinical stage IB; CR: Complete response; CRT: Chemoradiotherapy; IASLC: International Association for the Study of Lung Cancer; ISC-LCSG: The Lung Cancer Study Group of the International Society of Chemotherapy; LoE: Level of evidence; MST: Median survival time; NC: Neoadjuvant chemotherapy; NST: Non-surgical treatment; NCDB: National Cancer Data Base; OS: Overall survival; PCI: Prophylactic cranial irradiation; pIA: Pathologic stage IA; pIB: Pathologic stage IB; pII: Pathologic stage II; pIIIA: Pathologic stage IIIA; pIIIB: Pathologic stage IIIB; QT: Chemotherapy; R0: Complete resection; RS: Retrospective study; RT: Radiotherapy; S: Surgery; SCLC: Small cell lung cancer; SEER: Surveillance, Epidemiology, and End Results database.

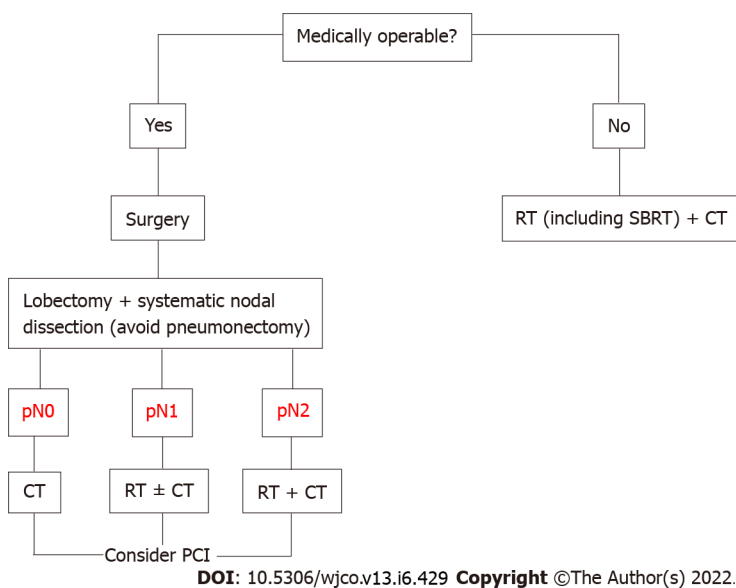


Figure 1 Proposed algorithm for the treatment of early-stage small cell lung cancer focused on surgical treatment. CT: Chemotherapy; PCI: Prophylactic cranial irradiation; RT: Radiotherapy; SBRT: Stereotactic body radiation therapy.

techniques that enable biopsy and the pathologic study of lymph nodes (e.g., transbronchial ultrasound and esophageal echoendoscopy) and invasive techniques such as video mediastinoscopy, anterior mediastinotomy, and videothoracoscopy.

Radiotherapy in limited-stage SCLC

Thoracic radiotherapy and stereotactic body radiotherapy in early-stage SCLC: SCLC is usually classified as limited-stage (LS) or extensive-stage (ES) disease[65]. With adequate treatment, overall survival (OS) is 16-22 mo in patients with LS-SCLC and 8-13 mo in those with ES-SCLC. The corresponding 5-year survival rates are < 20% and < 2%[66]. Radiotherapy is associated with better OS when given in the first few weeks after the start of chemotherapy (ideally during cycle 1 and never later than cycle 3), and the shorter the duration the better[67].

Hypofractionated radiotherapy is well tolerated and produces similar response rates to standard fractionation. Proposed schedules include 40 Gy in 16 fractions with chemotherapy and prophylactic cranial irradiation (PCI)[68] and 55 Gy in 25 once-daily fractions, also with chemotherapy and PCI[69]. Higher complete response rates and longer OS have been observed for hyperfractionated *vs* hypofractionated radiotherapy (45 Gy in 30 fractions twice daily *vs* 42 Gy in 15 fractions twice daily), but the differences were not statistically significant[70].

Treatment must be individualized. Some clinical guidelines recommend surgery and adjuvant chemotherapy for stage I and IIA disease[30,71]. This combination has achieved OS rates of 50%-70%[20, 21,72,73]. Nonetheless, stereotactic body radiotherapy (SBRT) should be considered in patients who are unfit for or refuse surgery, as it is not inferior to conventional treatment and has an acceptable safety

profile (toxicity < grade 3)[74-80]. Although the evidence is based on small series, SBRT can achieve local control rates > 85%. No clear benefit, however, has been observed for OS (63%-83% at 1 year, 35%-76% at 2 years, and 21%-26% at 3 years) (Table 2). This could have several explanations. First, SCLC is a fast-spreading tumor (associated with distant metastases in 50% of cases), requiring clinicians to consider neoadjuvant or adjuvant chemotherapy (preferably adjuvant in the case of SBRT due to its short treatment time), particularly in the case of tumors > 2 cm[77-81]. Adjuvant chemotherapy can improve OS by up to 25%[82]. Second, the disease may have been initially understaged. Thus, staging with positron emission tomography-computed tomography (CT) and mediastinoscopy/endobronchial ultrasound is recommended before proposing surgery or SBRT. SBRT should be planned using intensity-modulated techniques (*e.g.*, intensity-modulated radiotherapy, volumetric modulated arc therapy) and delivered with image-guided inter- and/or intrafraction monitoring (*e.g.*, Conebeam, ExacTrac) and respiratory control (*e.g.*, four-dimensional CT, deep inspiration breath hold, active breathing control, gating). The number of fractions can vary, but a biologically effective dose of >100 Gy must be delivered to the isocenter of the tumor. Because SCLC is highly radiosensitive, some groups have suggested using a lower dose, particularly in patients with ultracentral tumors[83].

PCI

Patients with SCLC are at high risk of brain metastases (BM)[84,85]. Research into the potential of PCI began in the late 1970s[86]. Brain magnetic resonance imaging (MRI) should be performed after chemoradiotherapy or systemic therapy[87], as 21.8%-32.5% of patients who achieve complete response subsequently develop BM[88,89]. A meta-analysis published by Aupérin *et al*[90] in 1999 showed that PCI was associated with a reduced incidence of BM at 3 years (59% *vs* 33%) and a 5.4% increase in OS. Subsequent meta-analyses have shown similarly favorable results for PCI in patients who had responded to treatment[91-94]. Most of these studies, however, were published before the introduction of restaging with brain MRI, and therefore the true benefit of PCI in LS-SCLC is not so clear[95,96]. Nonetheless, retrospective studies have described beneficial effects for PCI in patients with a previous negative brain MRI scan[97,98]. Patients who have undergone complete resection should benefit from PCI, except patients with stage I disease, who have a low risk of BM[99-101]. There is a growing interest in the use of brain MRI and stereotactic irradiation rather than PCI in patients with LS-SCLC[102], but prospective randomized trials are needed.

Concomitant treatment in locally advanced disease

Radical treatment with chemotherapy and concomitant radiotherapy are recommended for patients with stage IIB-III disease in good general health[4,103]. Eighty percent of patients with mediastinal involvement treated exclusively with chemotherapy experience local recurrence[104], but the addition of radiotherapy lowers this rate and increases survival[104,105]. The CONVERT trial, which compared fractionated and unfractionated radiotherapy in patients treated with cisplatin-etoposide, reported an overall response rate (ORR) of 70%-90%, an OS of 24-30 mo, and a 5-year OS rate of 25%-30%[106]. Another two trials investigated the combination of bevacizumab, an angiogenic, with conventional chemoradiotherapy, but had to be discontinued because of a relatively high incidence of severe adverse events (tracheoesophageal fistulae)[107].

Perspectives for radiotherapy in LS-SCLC

Radiotherapy with immunotherapy in LS-SCLC: Three trials are currently analyzing the combined use of radiotherapy and immunotherapy in LS-SCLC: The NRG Oncology and Alliance trial (ClinicalTrials.gov Identifier: NCT03811002) investigating chemoradiotherapy with and without atezolizumab; the phase II STIMULI trial (NCT02046733) analyzing nivolumab and ipilimumab after chemoradiotherapy and PCI; and the phase III ADRIATIC trial (NCT03703297) comparing durvalumab, durvalumab plus tremelimumab, and placebo in patients without progression after chemoradiotherapy.

Hippocampal avoidance to reduce the neurotoxicity of PCI: The role of PCI with hippocampal avoidance (HA) in patients with LS- or ES-SCLC without BM is being investigated in three phase III trials: The Dutch NKI/AVL trial (NCT01780675), the NRG Oncology CC003 trial (NCT02635009), and the Spanish PREMIER-TRIAL (NCT02397733)[108]. The Dutch group found no significant differences in recall assessed using the revised version of the Hopkins Verbal Learning Test between patients who received PCI and those who received HA-PCI[109]. Using the Free and Cued Selecting Reminding Test, the Spanish group found a significant decline in 3-mo delayed recall [22.22% *vs* 5.08%; odds ratio (OR) = 5.33; 95% confidence interval (CI): 1.44-19.65; *P* = 0.006] and total recall (20.63% *vs* 6.78%; OR = 3.57; 95%CI: 1.09-11.68; *P* = 0.02] in the PCI *vs* HA-PCI group[110]. Another potentially interesting line of research is the use of Alzheimer disease drugs to preserve cognition in patients treated with PCI[111].

Proton beam radiation therapy: In non-SCLC, proton therapy has been used to reduce doses to the heart while maintaining high doses to the tumor[112]. Proton beam radiation therapy (PBRT) is potentially beneficial in SCLC, as patients tend to have bulky central disease at diagnosis. In a study of 30 patients at the University of Pennsylvania, PBRT at a median dose of 63.9 cobalt Gy equivalents achieved a promising median OS of 28.2 mo with low toxicity[113]. These results need to be validated in

Table 2 Thoracic radiotherapy and stereotactic body radiotherapy in early-stage small cell lung cancer

Ref.	Sample size	Fractionation	QT	Prophylactic cranial irradiation	Local control	Overall survival	Disease-free survival
Videtic <i>et al</i> [76], 2013	n = 6	60 Gy (3 fx); 50 Gy (5 fx); 30 Gy (1 fx)	4/6	4/6	100% (1 yr)	63% (1 yr)	75% (1 yr)
Shioyama <i>et al</i> [77], 2015	n = 64	48 Gy (4 fx)	36/64	10/64	89% (2 yr)	76% (2 yr)	
Stahl <i>et al</i> [79], 2017	n = 285	48-60 Gy (3-5 fx)	130/285		35% (3 yr), 21.5% (5 yr)		
Verma <i>et al</i> [75], 2017	n = 74	50 Gy (5 fx)	45/74	17/74	96% (3 yr)		
Shioyama <i>et al</i> [78], 2018	n = 43	36-60 Gy (3-10 fx)	8/43	8/43	80.2% (2 yr)	72.3% (2 yr)	44.6% (2 yr)
Verma <i>et al</i> [74], 2019	n = 149	45-60 Gy (3-8 fx)	149/149		83.8% (29.2 mo)		
Newman <i>et al</i> [81], 2019	n = 239	BED > 100 Gy (max 8 fx)	84/239		27% (5 yr); 36% (5 yr, with QT)		
Singh <i>et al</i> [80], 2019	n = 21	BED 105.6 Gy (3-5 fx)	4/21		100% (1, 2, 3 yr)	73.1% (1 yr); 36.6% (2 yr)	85.7% (1 yr); 42.9% (2 yr)

BED: Biologically equivalent dose; fx: Fraction; QT: Chemotherapy.

further studies.

ES SCLC

Initial management

Chemotherapy with platinum compounds and etoposide has been the standard treatment for ES-SCLC for many decades. The COCIS meta-analysis showed that cisplatin- and carboplatin-based chemotherapy produced comparable results in terms of OS (9.6 *vs* 9.4 mo), progression free survival (PFS) (5.5 *vs* 5.3 mo), and ORR (67% *vs* 66% mo)[114]. Other strategies attempted, including maintenance treatments and combinations with antiangiogenics, have produced disappointing results[115-117]. The recently published results of the IMpower 133[118] and CASPIAN[119] trials comparing combinations of chemotherapy and immunotherapy followed by immunotherapy with standard platinum and etoposide chemotherapy in ES-SCLC have shown that the combined use of chemotherapy and immunotherapy prolongs OS.

IMpower133 is a phase III trial in which patients received four cycles of carboplatin and etoposide and either atezolizumab or placebo followed by maintenance atezolizumab[118]. The response rates in both arms were similar, but patients in the atezolizumab arm survived for a median of 2.3 mo longer [hazard ratio (HR) = 0.7; 95%CI: 0.54-0.91; *P* = 0.007]. The updated trial data presented at the 2019 European Society for Medical Oncology congress showed an increase in OS at both 12 mo (39% to 51.9%) and 18 mo (21% to 34%)[120,121].

The phase III CASPIAN trial has three treatment arms. Treatment with durvalumab plus chemotherapy (4-6 cycles of cisplatin or carboplatin plus etoposide) followed by durvalumab maintenance achieved an OS of 12.9 mo (*vs* 10.5 mo for standard chemotherapy) (HR = 0.75; 95%CI: 0.62-0.9; *P* = 0.0032), a 2-year PFS of 11% (*vs* 2.9%), and a 2-year response rate of 13.5% (*vs* 3.9%)[119, 122]. In the third arm, tremelimumab plus durvalumab *vs* chemotherapy showed no benefit in antitumor activity and was associated with increased toxicity[123].

Results from other studies evaluating combinations of anti-programmed death 1 (PD-1) antibodies have been disappointing. While the combined use of pembrolizumab and chemotherapy increased PFS, it did not provide any significant improvements in OS[124]. In the phase II ECOG-ACRIN EA5161 trial, chemotherapy plus nivolumab followed by maintenance treatment achieved a non-significant improvement in PFS (5.5 *vs* 4.7 mo) and OS (11.3 *vs* 8.5 mo)[125] (Table 3). A systematic review and two meta-analyses published in 2020 concluded that a combination of chemotherapy with atezolizumab or durvalumab was the best first-line treatment for ES-SCLC[126,127]. Other options that have been explored include combinations of ipilimumab and chemotherapy (no benefit and greater toxicity)[128, 129] and combinations of different chemotherapy agents, such as irinotecan plus etoposide and cisplatin plus irinotecan (also without benefits)[130-132].

Table 3 Combined first-line immunotherapy options for extensive-stage small cell lung cancer

Study	n	Design	Treatment	RR	PFS	OS
NCT01450761	1132	Phase III; Randomized, double-blind; Drug: Ipilimumab	Arm A: PE × 4C + ipilimumab × 4C; Control: PE × 4C + placebo × 4C	PR 62% <i>vs</i> 62%; SD 26% <i>vs</i> 27%; PD 6% <i>vs</i> 9%	4.6 <i>vs</i> 4.4 mo; HR = 0.85, <i>P</i> = 0.0161	11.0 <i>vs</i> 10.9 mo; HR = 0.94, <i>P</i> = 0.3775
Impower 133	403	Phase III. Randomized, double-blind; Drug: Atezolizumab	Arm A: PE + atezolizumab × 4C/atezolizumab; Control: PE + placebo × 4C/placebo	60% <i>vs</i> 64%	5.2 <i>vs</i> 4.3 mo; HR = 0.77, <i>P</i> = 0.02	12.3 <i>vs</i> 10.3 mo; HR = 0.70, <i>P</i> = 0.007
CASPIAN	805	Phase III. Randomized, open-label; Drug: Durvalumab	Arm B (<i>n</i> = 268): Durvalumab + PE × 4C/durvalumab; Control: PE × 4C	68% <i>vs</i> 58%	5.1 <i>vs</i> 5.4 mo; HR = 0.78, <i>P</i> not tested	13.0 <i>vs</i> 10.3 mo; HR = 0.73, <i>P</i> = 0.0047
CASPIAN	805	Phase III. Randomized, open-label; Drug: Durvalumab + tremelimumab	Arm A (<i>n</i> = 268): Durvalumab + tremelimumab + PE × 4C/durvalumab + tremelimumab. Control: PE × 4C	58% both arms	4.9 <i>vs</i> 5.4 mo; HR = 0.84	10.4 <i>vs</i> 10.5 mo; HR = 0.82, <i>P</i> = 0.045
KEYNOTE 604	453	Phase III; Randomized, double-blind; Drug: Pembrolizumab	Arm A: Pembrolizumab + PE; Control: PE + placebo	71% <i>vs</i> 62%	4.5 <i>vs</i> 4.3 mo; HR = 0.75, <i>P</i> = 0.0023	10.8 <i>vs</i> 9.7 mo; HR = 0.80, <i>P</i> = 0.0164
ECOG-ACRIN	160	Phase I. Randomized, open-label; Drug: Nivolumab	Arm A: PE + nivolumab × 4C/nivolumab; Control: PE × 4C	52.29% <i>vs</i> 47.71%	5.5 <i>vs</i> 4.6 mo; HR = 0.65, <i>P</i> = 0.012	11.3 <i>vs</i> 8.5 mo; HR = 0.67, <i>P</i> = 0.038

4C: 4 cycles; OS: Overall survival; PD: Progressive disease; PE: Platinum and etoposide; PFS: Progression free survival; PR: Partial response; RR: Response rate; SD: Stable disease.

PCI in ES-SCLC

The results of the first randomized trial to demonstrate a reduction in the risk of symptomatic BM (14.6% *vs* 40.4% at 1 year) and an improvement in OS (27.1% *vs* 13.3%) in chemotherapy responders who underwent PCI were published in 2007[133]. The results are supported by data from several meta-analyses[134-136], although as a shortcoming of the trial, pre-PCI brain imaging was not performed [133]. The results of a randomized trial conducted in Japan comparing PCI with close MRI follow-up in patients with ES-SCLC who had responded to chemotherapy and had a negative brain MRI were published in 2017. While they did not show an increase in OS (11.6 mo for PCI *vs* 13.7 mo for MRI follow-up; HR = 1.27; 95%CI: 0.96-1.68; *P* = 0.094), they did show a significant decrease in the incidence of BM[137].

A recent meta-analysis showed that PCI was only associated with prolonged OS in studies where brain imaging was not performed between chemotherapy and irradiation (HR = 0.70; 95%CI: 0.57-0.85). In other words, PCI did not offer any significant benefits when preceded by MRI or CT to test for BM (HR = 0.94; 95%CI: 0.74-1.18)[138]. Considering the above results and the neurotoxic effects of PCI[139], it would seem reasonable to consider periodic MRI examination as an alternative to PCI in patients with ES-SCLC. In such cases, a joint evaluation should be made by the medical and radiation oncologists[30]. The recommended dose for PCI is 25 Gy in 10 fractions, as higher doses do not appear to reduce the incidence of BM at 2 years and are associated with higher mortality and chronic neurotoxicity[140].

Treatment of refractory and relapsed SCLC

Relapsed SCLC tends to be resistant to treatment and is associated with an OS of 4-5 mo. Response to second-line treatment varies according to PFS and is 10% in patients with a PFS < 3 mo (refractory SCLC) and 25% in those with a PFS of 3-6 mo (sensitive SCLC)[141-143].

Relapse after PFS > 3 mo: Rechallenge treatment with combinations of platinum-based chemotherapy has been investigated in patients with sensitive SCLC. Patients treated with carboplatin and etoposide had a longer PFS than those treated with topotecan, and the greatest benefits were observed for those who relapsed after 6 mo[144,145].

Relapse after PFS of < 3 mo: Until recently, topotecan was the only drug authorized by the US and Food and Drug Administration (FDA) to treat relapsed SCLC. In the 2006 phase III trial that led to its approval, it significantly improved survival compared with best supportive care only[146]. Another phase III trial comparing topotecan and CAV (cyclophosphamide, doxorubicin, and vincristine) reported similar survival and response rates for the two treatments, but found topotecan to be associated with better symptom control and lower toxicity[147]. An additional study evaluating topotecan plus aflibercept, an antiangiogenic, reported an OS of 5 mo[148].

One recent advance in this setting is the recent approval by the FDA of lurbinectedin as a second-line treatment for SCLC. In a study of patients with SCLC without BM, lurbinectedin achieved an ORR of 35%, and a median response duration of 5.1 mo (> 6 mo in 25% of patients)[149]. The combination of

lurbinectedin and doxorubicin was investigated in two cohorts in a phase I trial and showed disease control rates of 81% and 70% and a median response duration of 4.5 and 5.2 mo[150]. These findings led to the design of the phase III ATLANTIS trial comparing lurbinectedin plus doxorubicin with topotecan and with CAV; a press release, however, announced no improvement in OS[151] (Figure 2).

Amrubicin is available for the treatment of relapsed SCLC in Japan, but it has not been approved by the FDA. A phase III trial comparing amrubicin with topotecan showed superior symptom control for topotecan but no significant differences in OS[152]. Immune checkpoint inhibitors have also been tested. The CheckMate 032 trial comparing nivolumab alone with nivolumab plus ipilimumab in recurrent SCLC reported improved ORR and OS in both treatment arms regardless of prior treatment or PD-L1 expression[153,154]. With these data, the FDA approved nivolumab for use in previously treated patients.

The phase III CheckMate 331 trial showed similar OS for nivolumab *vs* standard chemotherapy in the second-line treatment of SCLC[155]. Pembrolizumab has also been tested in SCLC. A pooled analysis of the KEYNOTE-028 (phase Ib)[156] and KEYNOTE-158 (II)[157,158] trials found an ORR of 19.3%, leading to FDA approval. Atezolizumab was also tested in a phase II trial, but the primary endpoint was not met[159]. Paclitaxel every 3 wk for 6 cycles plus pembrolizumab after the second cycle until disease progression achieved a disease control rate of 80% and a median OS of 9.2 mo[160]. Other drugs tested in the setting of relapsed SCLC are temozolomide[161,162], irinotecan[163], paclitaxel[164,165], docetaxel[166], gemcitabine[167,168], and vinorelbine[169]. Finally, a recent phase IIb study showed that belotecan was associated with better OS and disease control than topotecan in patients with sensitive SCLC[170].

Recent advances in systemic therapy

New drugs linked to targets with a role in cell proliferation have been developed. These include poly (ADP-ribose) polymerase (PARP) inhibitors, delta-like ligand 3 inhibitors (DLL3), and drugs that selectively inhibit oncogenic transcription. The expression of DNA damage response proteins [especially PARP1/checkpoint kinase 1 (CHK1)] is elevated in SCLC, and *in vitro* studies have shown an antitumor effect for PARP inhibitors[171]. Monotherapy with PARP inhibitors has also been investigated in different clinical trials, but the results have been disappointing. In an early study, talazoparib showed an ORR of 8.7%[172]. No benefit was observed for maintenance treatment with olaparib after first-line chemotherapy with cisplatin and etoposide[173] or for the addition of veliparib *vs* placebo to first-line cisplatin and etoposide, with findings showing no significant differences in PFS (6.1 *vs* 5.5 mo) or OS (10.3 *vs* 8.9 mo)[174,175].

Discordant results have been reported for combinations of chemotherapy and PARP inhibitors in successive treatment lines. No significant differences were found for PFS or OS in a study comparing temozolomide plus veliparib *vs* temozolomide only[176]. Temozolomide combined with olaparib, however, was associated with a response rate of 41.7%, a PFS of 4.2 mo, and an OS of 8.5 mo in a phase I/II clinical trial[177]. No benefits have been observed for the combined use of PARP inhibitors and immunotherapy (durvalumab with olaparib, among others)[178]. Future actions targeting this actionable molecular pathway in SCLC will probably involve combinations of PARP inhibitors and chemotherapy agents and immunotherapy, or new molecules. Promising results have been reported for CHK1 (SRA737) combined with low-dose gemcitabine and anti-PD-1/programmed death ligand 1 (PD-L1) immune checkpoint inhibitors[179] and for PARP inhibitors combined with WEE1 inhibitors, which act at the cell-cycle level[180].

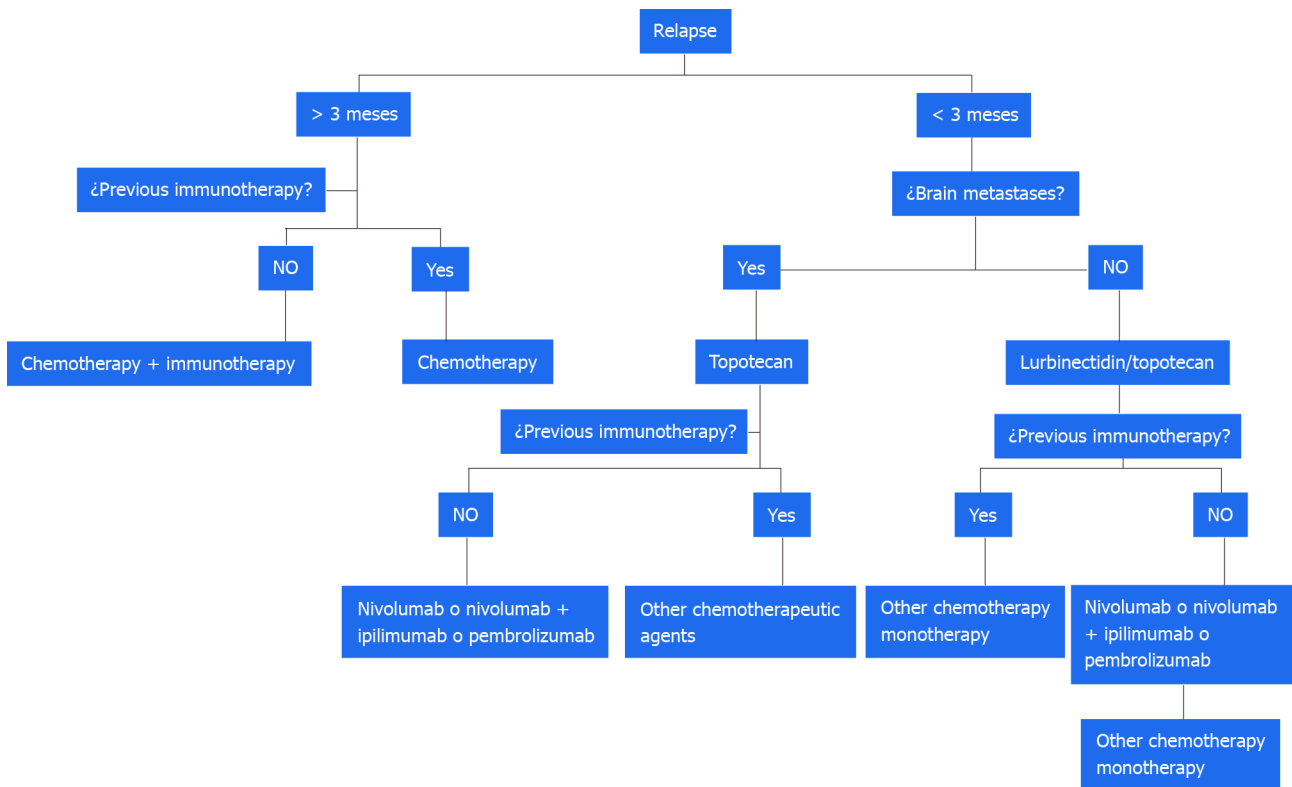
Other treatments have also yielded positive results. Lurbinectedin, a selective oncogenic transcription inhibitor, was recently evaluated in combination with irinotecan in pretreated patients in a phase Ib/II basket trial. The results for the SCLC cohort showed an ORR of 62%, a clinical benefit rate of 81%, a disease control rate of 90%, and a PFS of 6.1 mo[181]. Other new molecules with different ligands under investigation include DLL3 inhibitors, such as rovalpituzumab-tesirine. This is a promising drug in pretreated patients expressing DLL3, although recent reports have described greater toxicity and little benefit compared with topotecan[182-184]. AMG 757, a half-life extended DLL3 bispecific T-cell engager, has also shown promising results in pretreated patients in an ongoing phase I trial, with an ORR of 14%, a disease control rate of 37%, and a very promising median duration of 6.2 mo[185].

Perspectives for radiotherapy in ES-SCLC

Numerous questions remain to be answered regarding the role of radiotherapy in ES-SCLC.

Consolidation radiotherapy in extensive SCLC: What is the optimal radiation dose or indication for patients with complete thoracic response or partial distant response? The Chinese phase III trial (NCT02675088) is comparing 45 Gy at 3 Gy/d in 15 fractions *vs* 10 fractions (CREST trial schedule) with a primary endpoint of OS at 2 years[186]. How can radiotherapy be best combined with immunotherapy? The RAPTOR phase II/III trial (NCT04402788) is evaluating the use of radiotherapy to the chest and distant lesions after 4-6 cycles of carboplatin and etoposide plus atezolizumab.

Stereotactic radiosurgery to treat BM: Stereotactic radiosurgery has not traditionally been investigated in SCLC due to the high incidence of BM and poor prognosis. Nonetheless, there is growing evidence



DOI: 10.5306/wjco.v13.i6.429 Copyright ©The Author(s) 2022.

Figure 2 Proposed algorithm for the treatment of relapsed small cell lung cancer.

that it may be appropriate[187]. ENCEPHALON, a phase II trial (NCT03297788) is currently comparing stereotactic radiosurgery with whole-brain radiotherapy in patients with SCLC and 1-10 BM.

CONCLUSION

The treatment of SCLC will continue to be a challenge. Immunotherapy has a new role lung cancer and will be the future treatment standard alone or in combination, as well as the new radiotherapy techniques. As has been occurred in non-SCLC, the future of treatments in both early and advanced stages is through immunotherapy and targeted treatments. Furthermore, the use of different combinations of chemoimmunotherapy in recent months has improved the prognosis of patients with advanced SCLC. Nevertheless, continued research efforts are needed. Different lines of investigation are open and we hope that their findings will continue to improve prognosis and quality of life in this setting.

FOOTNOTES

Author contributions: Pangua C, Rogado J, Serrano-Montero G, Belda-Sanchis J, Álvarez Rodríguez B, Torrado L, and Rodríguez De Dios N performed the research and wrote the paper; Mielgo-Rubio X, Trujillo JC, and Couñago F contributed to the critical review of the manuscript for important intellectual content.

Conflict-of-interest statement: Mielgo-Rubio X declares the following conflicts of interest: Advisory role; Boehringer-Ingelheim, Astra Zeneca, Bristol Myers Squibb. Speakers' bureau; Roche, Astra Zeneca, Bristol Myers Squibb, MSD, Abbott. Research funding; Bristol Myers Squibb. The other authors have no conflicts of interest to declare.

Open-Access: This article is an open-access article that was selected by an in-house editor and fully peer-reviewed by external reviewers. It is distributed in accordance with the Creative Commons Attribution NonCommercial (CC BY-NC 4.0) license, which permits others to distribute, remix, adapt, build upon this work non-commercially, and license their derivative works on different terms, provided the original work is properly cited and the use is non-commercial. See: <https://creativecommons.org/licenses/by-nc/4.0/>

Country/Territory of origin: Spain

ORCID number: Cristina Pangua 0000-0001-6303-525X; Jacobo Rogado 0000-0002-9795-8762; Gloria Serrano-Montero 0000-0001-9162-5038; José Belda-Sanchís 0000-0002-0657-9231; Beatriz Álvarez Rodríguez 0000-0003-2244-801X; Laura Torrado 0000-0003-1079-7036; Nuria Rodríguez De Dios 0000-0002-2766-5972; Xabier Mielgo-Rubio 0000-0002-0985-6150; Juan Carlos Trujillo 0000-0002-3370-0860; Felipe Couñago 0000-0001-7233-0234.

S-Editor: Wang JJ

L-Editor: Filipodia

P-Editor: Wang JJ

REFERENCES

- 1 **National Cancer Institute.** SEER Cancer Statistics Review, 1975-2017. [cited 20 January 2021]. Available from: https://seer.cancer.gov/archive/csr/1975_2017/
- 2 **Govindan R,** Page N, Morgensztern D, Read W, Tierney R, Vlahiotis A, Spitznagel EL, Piccirillo J. Changing epidemiology of small-cell lung cancer in the United States over the last 30 years: analysis of the surveillance, epidemiologic, and end results database. *J Clin Oncol* 2006; **24**: 4539-4544 [PMID: 17008692 DOI: 10.1200/JCO.2005.04.4859]
- 3 **Pesch B,** Kendzia B, Gustavsson P, Jöckel KH, Johnen G, Pohlabein H, Olsson A, Ahrens W, Gross IM, Brüske I, Wichmann HE, Merletti F, Richiardi L, Simonato L, Fortes C, Siemiatycki J, Parent ME, Consonni D, Landi MT, Caporaso N, Zaridze D, Cassidy A, Szeszenia-Dabrowska N, Rudnai P, Lissowska J, Stücker I, Fabianova E, Dumitru RS, Bencko V, Foretova L, Janout V, Rudin CM, Brennan P, Boffetta P, Straif K, Brüning T. Cigarette smoking and lung cancer--relative risk estimates for the major histological types from a pooled analysis of case-control studies. *Int J Cancer* 2012; **131**: 1210-1219 [PMID: 22052329 DOI: 10.1002/ijc.27339]
- 4 **Jett JR,** Schild SE, Kesler KA, Kalemkerian GP. Treatment of small cell lung cancer: Diagnosis and management of lung cancer, 3rd ed: American College of Chest Physicians evidence-based clinical practice guidelines. *Chest* 2013; **143**: e400S-e419S [PMID: 23649448 DOI: 10.1378/chest.12-2363]
- 5 **Detterbeck FC.** The eighth edition TNM stage classification for lung cancer: What does it mean on main street? *J Thorac Cardiovasc Surg* 2018; **155**: 356-359 [PMID: 29061464 DOI: 10.1016/j.jtcvs.2017.08.138]
- 6 **Vallières E,** Shepherd FA, Crowley J, Van Houtte P, Postmus PE, Carney D, Chansky K, Shaikh Z, Goldstraw P; International Association for the Study of Lung Cancer International Staging Committee and Participating Institutions. The IASLC Lung Cancer Staging Project: proposals regarding the relevance of TNM in the pathologic staging of small cell lung cancer in the forthcoming (seventh) edition of the TNM classification for lung cancer. *J Thorac Oncol* 2009; **4**: 1049-1059 [PMID: 19652623 DOI: 10.1097/JTO.0b013e3181b27799]
- 7 **Amin MB,** Edge SB, Greene FL, Byrd DR, Brookland RK, Mary Kay Washington, Gershenwald JE, Compton CC, Hess KR, Sullivan DC, Jessup JM, Brierley JD, Gaspar LE, Schilsky RL, Balch CM, Winchester DP, Asare EA, Madera M, Gress DM, Meyer LR: TNM classification of malignant tumours / Description: Eighth edition. | Oxford, United Kingdom; Hoboken, NJ: John Wiley & Sons, Inc., 2017
- 8 **Varlotto JM,** Recht A, Flickinger JC, Medford-Davis LN, Dyer AM, DeCamp MM. Lobectomy leads to optimal survival in early-stage small cell lung cancer: a retrospective analysis. *J Thorac Cardiovasc Surg* 2011; **142**: 538-546 [PMID: 21684554 DOI: 10.1016/j.jtcvs.2010.11.062]
- 9 **Jin K,** Zhang K, Zhou F, Dai J, Zhang P, Jiang G. Selection of candidates for surgery as local therapy among early-stage small cell lung cancer patients: a population-based analysis. *Cancer Commun (Lond)* 2018; **38**: 5 [PMID: 29764484 DOI: 10.1186/s40880-018-0272-5]
- 10 **Yang CJ,** Chan DY, Shah SA, Yerokun BA, Wang XF, D'Amico TA, Berry MF, Harpole DH Jr. Long-term Survival After Surgery Compared With Concurrent Chemoradiation for Node-negative Small Cell Lung Cancer. *Ann Surg* 2018; **268**: 1105-1112 [PMID: 28475559 DOI: 10.1097/SLA.0000000000002287]
- 11 **Ahmed Z,** Kujtan L, Kennedy KF, Davis JR, Subramanian J. Disparities in the Management of Patients With Stage I Small Cell Lung Carcinoma (SCLC): A Surveillance, Epidemiology and End Results (SEER) Analysis. *Clin Lung Cancer* 2017; **18**: e315-e325 [PMID: 28438510 DOI: 10.1016/j.clc.2017.03.003]
- 12 **Wakeam E,** Byrne JP, Darling GE, Varghese TK Jr. Surgical Treatment for Early Small Cell Lung Cancer: Variability in Practice and Impact on Survival. *Ann Thorac Surg* 2017; **104**: 1872-1880 [PMID: 29106886 DOI: 10.1016/j.athoracsur.2017.07.009]
- 13 **Wakeam E,** Acuna SA, Leighl NB, Giuliani ME, Finlayson SRG, Varghese TK, Darling GE. Surgery Versus Chemotherapy and Radiotherapy For Early and Locally Advanced Small Cell Lung Cancer: A Propensity-Matched Analysis of Survival. *Lung Cancer* 2017; **109**: 78-88 [PMID: 28577955 DOI: 10.1016/j.lungcan.2017.04.021]
- 14 **Combs SE,** Hancock JG, Boffa DJ, Decker RH, Detterbeck FC, Kim AW. Bolstering the case for lobectomy in stages I, II, and IIIA small-cell lung cancer using the National Cancer Data Base. *J Thorac Oncol* 2015; **10**: 316-323 [PMID: 25319182 DOI: 10.1097/JTO.0000000000000402]
- 15 **Ogawa S,** Horio Y, Yatabe Y, Fukui T, Ito S, Hasegawa Y, Mitsudomi T, Hida T. Patterns of recurrence and outcome in patients with surgically resected small cell lung cancer. *Int J Clin Oncol* 2012; **17**: 218-224 [PMID: 21713603 DOI: 10.1007/s10147-011-0277-4]
- 16 **Ju MH,** Kim HR, Kim JB, Kim YH, Kim DK, Park SI. Surgical outcomes in small cell lung cancer. *Korean J Thorac Cardiovasc Surg* 2012; **45**: 40-44 [PMID: 22363907 DOI: 10.5090/kjtcs.2012.45.1.40]
- 17 **Lim E,** Belcher E, Yap YK, Nicholson AG, Goldstraw P. The role of surgery in the treatment of limited disease small cell

- lung cancer: time to reevaluate. *J Thorac Oncol* 2008; **3**: 1267-1271 [PMID: 18978561 DOI: 10.1097/JTO.0b013e318189a860]
- 18 **Wang HJ**, Sun KL, Zhang XR, Sun Y, Shi YK. [Combined modality therapy for small cell lung cancer patient with limited stage disease]. *Zhonghua Zhong Liu Za Zhi* 2007; **29**: 701-703 [PMID: 18246803]
 - 19 **Veronesi G**, Scanagatta P, Leo F, De Pas T, Pelosi G, Catalano G, Gandini S, De Braud F, Spaggiari L. Adjuvant surgery after carboplatin and VP16 in resectable small cell lung cancer. *J Thorac Oncol* 2007; **2**: 131-134 [PMID: 17410028]
 - 20 **Tsuchiya R**, Suzuki K, Ichinose Y, Watanabe Y, Yasumitsu T, Ishizuka N, Kato H. Phase II trial of postoperative adjuvant cisplatin and etoposide in patients with completely resected stage I-IIIa small cell lung cancer: the Japan Clinical Oncology Lung Cancer Study Group Trial (JCOG9101). *J Thorac Cardiovasc Surg* 2005; **129**: 977-983 [PMID: 15867769 DOI: 10.1016/j.jtcvs.2004.05.030]
 - 21 **Brock MV**, Hooker CM, Syphard JE, Westra W, Xu L, Alberg AJ, Mason D, Baylin SB, Herman JG, Yung RC, Brahmer J, Rudin CM, Ettinger DS, Yang SC. Surgical resection of limited disease small cell lung cancer in the new era of platinum chemotherapy: Its time has come. *J Thorac Cardiovasc Surg* 2005; **129**: 64-72 [PMID: 15632826 DOI: 10.1016/j.jtcvs.2004.08.022]
 - 22 **Nakamura H**, Kato Y, Kato H. Outcome of surgery for small cell lung cancer -- response to induction chemotherapy predicts survival. *Thorac Cardiovasc Surg* 2004; **52**: 206-210 [PMID: 15293157 DOI: 10.1055/s-2004-821075]
 - 23 **Badzio A**, Kurowski K, Karnicka-Mlodkowska H, Jassem J. A retrospective comparative study of surgery followed by chemotherapy vs. non-surgical management in limited-disease small cell lung cancer. *Eur J Cardiothorac Surg* 2004; **26**: 183-188 [PMID: 15200999 DOI: 10.1016/j.ejcts.2004.04.012]
 - 24 **Lewiński T**, Zuławski M, Turski C, Pietraszek A. Small cell lung cancer I-III A: cytoreductive chemotherapy followed by resection with continuation of chemotherapy. *Eur J Cardiothorac Surg* 2001; **20**: 391-398 [PMID: 11463563 DOI: 10.1016/s1010-7940(01)00787-4]
 - 25 **Cataldo I**, Bidoli P, BregaMassone PP, Conti B, Lequaglie C. Long term survival for resectable small cell lung cancer. *Lung Cancer (Amsterdam, Netherlands)* 2000; **29**: 130 [DOI: 10.1016/S0169-5002(00)80429-8]
 - 26 **Inoue M**, Miyoshi S, Yasumitsu T, Mori T, Iuchi K, Maeda H, Matsuda H. Surgical results for small cell lung cancer based on the new TNM staging system. Thoracic Surgery Study Group of Osaka University, Osaka, Japan. *Ann Thorac Surg* 2000; **70**: 1615-1619 [PMID: 11093496 DOI: 10.1016/s0003-4975(00)01401-6]
 - 27 **Kobayashi S**, Okada S, Hasumi T, Sato N, Fujimura S. The significance of surgery for bulky N2 small-cell lung cancer: a clinical and in vitro analysis of long-term survivors. *Surg Today* 2000; **30**: 978-986 [PMID: 11110391 DOI: 10.1007/s005950070017]
 - 28 **Eberhardt W**, Stamatis G, Stuschke M, Wilke H, Müller MR, Kolks S, Flasshove M, Schütte J, Stahl M, Schlenger L, Budach V, Greschuchna D, Stüben G, Teschler H, Sack H, Seeber S. Prognostically orientated multimodality treatment including surgery for selected patients of small-cell lung cancer patients stages IB to IIIB: long-term results of a phase II trial. *Br J Cancer* 1999; **81**: 1206-1212 [PMID: 10584883 DOI: 10.1038/sj.bjc.6690830]
 - 29 **Ganti AKP**, Loo BW, Bassetti M, Blakely C, Chiang A, D'Amico TA, D'Avella C, Dowlati A, Downey RJ, Edelman M, Florsheim C, Gold KA, Goldman JW, Grecula JC, Hann C, Jams W, Iyengar P, Kelly K, Khalil M, Koczywas M, Merritt RE, Mohindra N, Molina J, Moran C, Pokharel S, Puri S, Qin A, Rusthoven C, Sands J, Santana-Davila R, Shafique M, Waqar SN, Gregory KM, Hughes M. Small Cell Lung Cancer, Version 2.2022, NCCN Clinical Practice Guidelines in Oncology. *J Natl Compr Canc Netw* 2021; **19**: 1441-1464 [PMID: 34902832 DOI: 10.6004/jnccn.2021.0058]
 - 30 **Simone CB 2nd**, Bogart JA, Cabrera AR, Daly ME, DeNunzio NJ, Detterbeck F, Faivre-Finn C, Gatschet N, Gore E, Jabbour SK, Kruser TJ, Schneider BJ, Slotman B, Turrisi A, Wu AJ, Zeng J, Rosenzweig KE. Radiation Therapy for Small Cell Lung Cancer: An ASTRO Clinical Practice Guideline. *Pract Radiat Oncol* 2020; **10**: 158-173 [PMID: 3222430 DOI: 10.1016/j.pro.2020.02.009]
 - 31 **Rudin CM**, Giaccone G, Ismaila N. Treatment of Small-Cell Lung Cancer: American Society of Clinical Oncology Endorsement of the American College of Chest Physicians Guideline. *J Oncol Pract* 2016; **12**: 83-86 [PMID: 29424581 DOI: 10.1200/JOP.2015.008201]
 - 32 **Früh M**, De Ruyscher D, Papat S, Crinò L, Peters S, Felip E; ESMO Guidelines Working Group. Small-cell lung cancer (SCLC): ESMO Clinical Practice Guidelines for diagnosis, treatment and follow-up. *Ann Oncol* 2013; **24** Suppl 6: vi99-v105 [PMID: 23813929 DOI: 10.1093/annonc/mdt178]
 - 33 **Shepherd FA**, Ginsberg RJ, Feld R, Evans WK, Johansen E. Surgical treatment for limited small-cell lung cancer. The University of Toronto Lung Oncology Group experience. *J Thorac Cardiovasc Surg* 1991; **101**: 385-393 [PMID: 1847981]
 - 34 **Rea F**, Callegaro D, Favaretto A, Loy M, Paccagnella A, Fantoni U, Festi G, Sartori F. Long term results of surgery and chemotherapy in small cell lung cancer. *Eur J Cardiothorac Surg* 1998; **14**: 398-402 [PMID: 9845145 DOI: 10.1016/s1010-7940(98)00203-6]
 - 35 **Stish BJ**, Hallemeier CL, Olivier KR, Harmsen WS, Allen MS, Garces YI. Long-Term Outcomes and Patterns of Failure After Surgical Resection of Small-Cell Lung Cancer. *Clin Lung Cancer* 2015; **16**: e67-e73 [PMID: 25823413 DOI: 10.1016/j.clcc.2015.02.004]
 - 36 **Xu L**, Zhang G, Song S, Zheng Z. Surgery for small cell lung cancer: A Surveillance, Epidemiology, and End Results (SEER) Survey from 2010 to 2015. *Medicine (Baltimore)* 2019; **98**: e17214 [PMID: 31577711 DOI: 10.1097/MD.00000000000017214]
 - 37 **Lüchtenborg M**, Riaz SP, Lim E, Page R, Baldwin DR, Jakobsen E, Vedsted P, Lind M, Peake MD, Mellemegaard A, Spicer J, Lang-Lazdunski L, Møller H. Survival of patients with small cell lung cancer undergoing lung resection in England, 1998-2009. *Thorax* 2014; **69**: 269-273 [PMID: 24172710 DOI: 10.1136/thoraxjnl-2013-203884]
 - 38 **Takei H**, Kondo H, Miyaoka E, Asamura H, Yoshino I, Date H, Okumura M, Tada H, Fujii Y, Nakanishi Y, Eguchi K, Dosaka-Akita H, Kobayashi H, Sawabata N, Yokoi K; Japanese Joint Committee of Lung Cancer Registry. Surgery for small cell lung cancer: a retrospective analysis of 243 patients from Japanese Lung Cancer Registry in 2004. *J Thorac Oncol* 2014; **9**: 1140-1145 [PMID: 25157766 DOI: 10.1097/JTO.0000000000000226]
 - 39 **Weksler B**, Nason KS, Shende M, Landreneau RJ, Pennathur A. Surgical resection should be considered for stage I and II

- small cell carcinoma of the lung. *Ann Thorac Surg* 2012; **94**: 889-893 [PMID: 22429675 DOI: 10.1016/j.athoracsur.2012.01.015]
- 40 **Yu JB**, Decker RH, Detterbeck FC, Wilson LD. Surveillance epidemiology and end results evaluation of the role of surgery for stage I small cell lung cancer. *J Thorac Oncol* 2010; **5**: 215-219 [PMID: 20101146 DOI: 10.1097/JTO.0b013e3181cd3208]
- 41 **Liu T**, Chen Z, Dang J, Li G. The role of surgery in stage I to III small cell lung cancer: A systematic review and meta-analysis. *PLoS One* 2018; **13**: e0210001 [PMID: 30596754 DOI: 10.1371/journal.pone.0210001]
- 42 **Hou SZ**, Cheng ZM, Wu YB, Sun Y, Liu B, Yuan MX, Wang XD. Evaluation of short-term and long-term efficacy of surgical and non-surgical treatment in patients with early-stage small cell lung cancer: A comparative study. *Cancer Biomark* 2017; **19**: 249-256 [PMID: 28453459 DOI: 10.3233/CBM-160332]
- 43 **Lucchi M**, Mussi A, Chella A, Janni A, Ribecchini A, Menconi GF, Angeletti CA. Surgery in the management of small cell lung cancer. *Eur J Cardiothorac Surg* 1997; **12**: 689-693 [PMID: 9458136 DOI: 10.1016/s1010-7940(97)00161-9]
- 44 **Engelhardt KE**, Coughlin JM, DeCamp MM, Denlinger CE, Meyerson SL, Bharat A, Odell DD. Survival after adjuvant radiation therapy in localized small cell lung cancer treated with complete resection. *J Thorac Cardiovasc Surg* 2019; **158**: 1665-1677.e2 [PMID: 31627955 DOI: 10.1016/j.jtcvs.2019.08.031]
- 45 **Iwata T**, Nishiyama N, Nagano K, Izumi N, Mizuguchi S, Tsukioka T, Morita R, Chung K, Hanada S, Inoue K. Role of pulmonary resection in the diagnosis and treatment of limited-stage small cell lung cancer: revision of clinical diagnosis based on findings of resected specimen and its influence on survival. *Gen Thorac Cardiovasc Surg* 2012; **60**: 43-52 [PMID: 22237738 DOI: 10.1007/s11748-011-0847-4]
- 46 **Schneider BJ**, Saxena A, Downey RJ. Surgery for early-stage small cell lung cancer. *J Natl Compr Canc Netw* 2011; **9**: 1132-1139 [PMID: 21975913 DOI: 10.6004/jnccn.2011.0094]
- 47 **Thomas CR Jr**, Giroux DJ, Janaki LM, Turrisi AT 3rd, Crowley JJ, Taylor SA, McCracken JD, Shankir Giri PG, Gordon W Jr, Livingston RB, Gandara DR. Ten-year follow-up of Southwest Oncology Group 8269: a phase II trial of concomitant cisplatin-etoposide and daily thoracic radiotherapy in limited small-cell lung cancer. *Lung Cancer* 2001; **33**: 213-219 [PMID: 11551416 DOI: 10.1016/s0169-5002(01)00181-7]
- 48 **Takenaka T**, Takenoyama M, Inamasu E, Yoshida T, Toyokawa G, Nosaki K, Hirai F, Yamaguchi M, Shimokawa M, Seto T, Ichinose Y. Role of surgical resection for patients with limited disease-small cell lung cancer. *Lung Cancer* 2015; **88**: 52-56 [PMID: 25662387 DOI: 10.1016/j.lungcan.2015.01.010]
- 49 **Schreiber D**, Rineer J, Weedon J, Vongtama D, Wortham A, Kim A, Han P, Choi K, Rotman M. Survival outcomes with the use of surgery in limited-stage small cell lung cancer: should its role be re-evaluated? *Cancer* 2010; **116**: 1350-1357 [PMID: 20082453 DOI: 10.1002/ncr.24853]
- 50 **Zhong L**, Suo J, Wang Y, Han J, Zhou H, Wei H, Zhu J. Prognosis of limited-stage small cell lung cancer with comprehensive treatment including radical resection. *World J Surg Oncol* 2020; **18**: 27 [PMID: 32013993 DOI: 10.1186/s12957-020-1807-1]
- 51 **Shepherd FA**, Ginsberg RJ, Evans WK, Feld R, Cooper JD, Ilves R, Todd TR, Pearson FG, Waters PF, Baker MA. Reduction in local recurrence and improved survival in surgically treated patients with small cell lung cancer. *J Thorac Cardiovasc Surg* 1983; **86**: 498-506 [PMID: 6312199]
- 52 **Granetzny A**, Boseila A, Wagner W, Krukemeyer G, Vogt U, Hecker E, Koch OM, Klink F. Surgery in the tri-modality treatment of small cell lung cancer. Stage-dependent survival. *Eur J Cardiothorac Surg* 2006; **30**: 212-216 [PMID: 16829087 DOI: 10.1016/j.ejcts.2006.05.002]
- 53 **Yin K**, Song D, Zhang H, Cai F, Chen J, Dang J. Efficacy of surgery and prophylactic cranial irradiation in stage II and III small cell lung cancer. *J Cancer* 2018; **9**: 3500-3506 [PMID: 30310506 DOI: 10.7150/jca.26157]
- 54 **Che K**, Shen H, Qu X, Pang Z, Jiang Y, Liu S, Yang X, Du J. Survival Outcomes for Patients with Surgical and Non-Surgical Treatments in Stages I-III Small-Cell Lung Cancer. *J Cancer* 2018; **9**: 1421-1429 [PMID: 29721052 DOI: 10.7150/jca.23583]
- 55 **Babakoohi S**, Fu P, Yang M, Linden PA, Dowlati A. Combined SCLC clinical and pathologic characteristics. *Clin Lung Cancer* 2013; **14**: 113-119 [PMID: 23010092 DOI: 10.1016/j.clcc.2012.07.002]
- 56 **Zhang C**, Yang H, Zhao H, Lang B, Yu X, Xiao P, Zhang X. Clinical outcomes of surgically resected combined small cell lung cancer: a two-institutional experience. *J Thorac Dis* 2017; **9**: 151-158 [PMID: 28203418 DOI: 10.21037/jtd.2017.01.07]
- 57 **Lei Y**, Feng H, Qiang H, Shang Z, Chang Q, Qian J, Zhang Y, Zhong R, Fan X, Chu T. Clinical characteristics and prognostic factors of surgically resected combined small cell lung cancer: a retrospective study. *Lung Cancer* 2020; **146**: 244-251 [PMID: 32592985 DOI: 10.1016/j.lungcan.2020.06.021]
- 58 **Mangum MD**, Greco FA, Hainsworth JD, Hande KR, Johnson DH. Combined small-cell and non-small-cell lung cancer. *J Clin Oncol* 1989; **7**: 607-612 [PMID: 2540288 DOI: 10.1200/JCO.1989.7.5.607]
- 59 **Men Y**, Hui Z, Liang J, Feng Q, Chen D, Zhang H, Xiao Z, Zhou Z, Yin W, Wang L. Further understanding of an uncommon disease of combined small cell lung cancer: clinical features and prognostic factors of 114 cases. *Chin J Cancer Res* 2016; **28**: 486-494 [PMID: 27877007 DOI: 10.21147/j.issn.1000-9604.2016.05.03]
- 60 **Shepherd FA**, Ginsberg R, Patterson GA, Feld R, Goss PE, Pearson FG, Todd TJ, Winton T, Rubinger M, Johansen E. Is there ever a role for salvage operations in limited small-cell lung cancer? *J Thorac Cardiovasc Surg* 1991; **101**: 196-200 [PMID: 1846927]
- 61 **Yamada K**, Saijo N, Kojima A, Ohe Y, Tamura T, Sasaki Y, Eguchi K, Shinkai T, Goya T, Kondou H. A retrospective analysis of patients receiving surgery after chemotherapy for small cell lung cancer. *Jpn J Clin Oncol* 1991; **21**: 39-45 [PMID: 1648633]
- 62 **Nakanishi K**, Mizuno T, Sakakura N, Kuroda H, Shimizu J, Hida T, Yatabe Y, Sakao Y. Salvage surgery for small cell lung cancer after chemoradiotherapy. *Jpn J Clin Oncol* 2019; **49**: 389-392 [PMID: 30753585 DOI: 10.1093/jcco/hyz010]
- 63 **Du X**, Tian D, Liu L, Tang Z, Xiao J, Liu W, Yuan S, Cao X, Zhou H, Zhang J. Surgery in patients with small cell lung cancer: A period propensity score matching analysis of the Seer database, 2010-2015. *Oncol Lett* 2019; **18**: 4865-4881 [PMID: 31611997 DOI: 10.3892/ol.2019.10792]

- 64 **Yang H**, Xu J, Yao F, Liang S, Zhao H. Analysis of unexpected small cell lung cancer following surgery as the primary treatment. *J Cancer Res Clin Oncol* 2018; **144**: 2441-2447 [PMID: 30341687 DOI: 10.1007/s00432-018-2766-6]
- 65 **Micke P**, Faldum A, Metz T, Beeh KM, Bittinger F, Hengstler JG, Buhl R. Staging small cell lung cancer: Veterans Administration Lung Study Group versus International Association for the Study of Lung Cancer--what limits limited disease? *Lung Cancer* 2002; **37**: 271-276 [PMID: 12234695 DOI: 10.1016/s0169-5002(02)00072-7]
- 66 **de Castro Carpeño J**, Dols MC, Gomez MD, Gracia PR, Crama L, Campelo MRG. Survival outcomes in stage IV small-cell lung cancer (IV-SCLC): Analysis from SEER database. *Ann Oncol* 2019; **30**: xi30 [DOI: 10.1093/annonc/mdz449.038]
- 67 **De Ruyscher D**, Lueza B, Le Péchoux C, Johnson DH, O'Brien M, Murray N, Spiro S, Wang X, Takada M, Lebeau B, Blackstock W, Skarlos D, Baas P, Choy H, Price A, Seymour L, Arriagada R, Pignon JP; RTT-SCLC Collaborative Group. Impact of thoracic radiotherapy timing in limited-stage small-cell lung cancer: usefulness of the individual patient data meta-analysis. *Ann Oncol* 2016; **27**: 1818-1828 [PMID: 27436850 DOI: 10.1093/annonc/mdw263]
- 68 **Turgeon GA**, Souhami L, Kopec N, Hirsh V, Ofiara L, Faria SL. Thoracic irradiation in 3weeks for limited-stage small cell lung cancer: Is twice a day fractionation really needed? *Cancer Radiother* 2017; **21**: 89-98 [PMID: 28325618 DOI: 10.1016/j.camrad.2016.09.015]
- 69 **Xia B**, Hong LZ, Cai XW, Zhu ZF, Liu Q, Zhao KL, Fan M, Mao JF, Yang HJ, Wu KL, Fu XL. Phase 2 study of accelerated hypofractionated thoracic radiation therapy and concurrent chemotherapy in patients with limited-stage small-cell lung cancer. *Int J Radiat Oncol Biol Phys* 2015; **91**: 517-523 [PMID: 25481679 DOI: 10.1016/j.ijrobp.2014.09.042]
- 70 **Grønberg BH**, Halvorsen TO, Fløtten Ø, Brustugun OT, Brunsvig PF, Aasebø U, Bremnes RM, Tollåli T, Hornslien K, Aksnessæther BY, Liaaen ED, Sundstrøm S; Norwegian Lung Cancer Study Group. Randomized phase II trial comparing twice daily hyperfractionated with once daily hypofractionated thoracic radiotherapy in limited disease small cell lung cancer. *Acta Oncol* 2016; **55**: 591-597 [PMID: 26494411 DOI: 10.3109/0284186X.2015.1092584]
- 71 **Johnson BE**, Crawford J, Downey RJ, Ettinger DS, Fossella F, Grecula JC, Jahan T, Kalemkerian GP, Kessinger A, Koczywas M, Langer CJ, Martins R, Marymont MH, Niell HB, Ramnath N, Robert F, Williams CC Jr; National Comprehensive Cancer Network (NCCN). Small cell lung cancer clinical practice guidelines in oncology. *J Natl Compr Canc Netw* 2006; **4**: 602-622 [PMID: 16813728 DOI: 10.6004/jnccn.2006.0050]
- 72 **Davis S**, Crino L, Tonato M, Darwish S, Pelicci PG, Grignani F. A prospective analysis of chemotherapy following surgical resection of clinical stage I-II small-cell lung cancer. *Am J Clin Oncol* 1993; **16**: 93-95 [PMID: 8383917 DOI: 10.1097/00000421-199304000-00001]
- 73 **Yang CF**, Chan DY, Speicher PJ, Gulack BC, Wang X, Hartwig MG, Onaitis MW, Tong BC, D'Amico TA, Berry MF, Harpole DH. Role of Adjuvant Therapy in a Population-Based Cohort of Patients With Early-Stage Small-Cell Lung Cancer. *J Clin Oncol* 2016; **34**: 1057-1064 [PMID: 26786925 DOI: 10.1200/JCO.2015.63.8171]
- 74 **Verma V**, Hasan S, Wegner RE, Abel S, Colonias A. Stereotactic ablative radiation therapy versus conventionally fractionated radiation therapy for stage I small cell lung cancer. *Radiother Oncol* 2019; **131**: 145-149 [PMID: 30773182 DOI: 10.1016/j.radonc.2018.12.006]
- 75 **Verma V**, Simone CB 2nd, Allen PK, Gajjar SR, Shah C, Zhen W, Harkenrider MM, Hallemeier CL, Jabbour SK, Matthiesen CL, Braunstein SE, Lee P, Dilling TJ, Allen BG, Nichols EM, Attia A, Zeng J, Biswas T, Paximadis P, Wang F, Walker JM, Stahl JM, Daly ME, Decker RH, Hales RK, Willers H, Videtic GM, Mehta MP, Lin SH. Multi-Institutional Experience of Stereotactic Ablative Radiation Therapy for Stage I Small Cell Lung Cancer. *Int J Radiat Oncol Biol Phys* 2017; **97**: 362-371 [PMID: 28011047 DOI: 10.1016/j.ijrobp.2016.10.041]
- 76 **Videtic GM**, Stephans KL, Woody NM, Pennell NA, Shapiro M, Reddy CA, Djemil T. Stereotactic body radiation therapy-based treatment model for stage I medically inoperable small cell lung cancer. *Pract Radiat Oncol* 2013; **3**: 301-306 [PMID: 24674402 DOI: 10.1016/j.pro.2012.10.003]
- 77 **Shioyama Y**, Nagata Y, Komiyama T, Takayama K, Shibamoto Y, Ueki N, Yamada K, Kozuka T, Kimura T, Matsuo Y. Multi-institutional Retrospective study of Stereotactic Body Radiation Therapy for stage I Small Cell Lung Cancer: Japan Radiation Oncology Study Group (JROSG). *Int J Radiat Oncol Biol Phys* 2015; **93**: S101 [DOI: 10.1016/j.ijrobp.2015.07.243]
- 78 **Shioyama Y**, Onishi H, Takayama K, Matsuo Y, Takeda A, Yamashita H, Miyakawa A, Murakami N, Aoki M, Matsushita H, Matsumoto Y, Shibamoto Y; Japanese Radiological Society Multi-Institutional SBRT Study Group (JRS-SBRTSG). Clinical Outcomes of Stereotactic Body Radiotherapy for Patients With Stage I Small-Cell Lung Cancer: Analysis of a Subset of the Japanese Radiological Society Multi-Institutional SBRT Study Group Database. *Technol Cancer Res Treat* 2018; **17**: 1533033818783904 [PMID: 29983096 DOI: 10.1177/1533033818783904]
- 79 **Stahl JM**, Corso CD, Verma V, Park HS, Nath SK, Husain ZA, Simone CB 2nd, Kim AW, Decker RH. Trends in stereotactic body radiation therapy for stage I small cell lung cancer. *Lung Cancer* 2017; **103**: 11-16 [PMID: 28024690 DOI: 10.1016/j.lungcan.2016.11.009]
- 80 **Singh R**, Ansinelli H, Sharma D, Jenkins J, Davis J, Vargo JA, Sharma S. Clinical Outcomes Following Stereotactic Body Radiation Therapy (SBRT) for Stage I Medically Inoperable Small Cell Lung Carcinoma: A Multi-Institutional Analysis From the RSearch Patient Registry. *Am J Clin Oncol* 2019; **42**: 602-606 [PMID: 31232723 DOI: 10.1097/COC.0000000000000561]
- 81 **Newman NB**, Sherry AD, Byrne DW, Osmundson EC. Stereotactic body radiotherapy versus conventional radiotherapy for early-stage small cell lung cancer. *J Radiat Oncol* 2019; **8**: 239-248 [PMID: 31402969 DOI: 10.1007/s13566-019-00395-x]
- 82 **Verma V**, Simone CB 2nd, Allen PK, Lin SH. Outcomes of Stereotactic Body Radiotherapy for T1-T2N0 Small Cell Carcinoma According to Addition of Chemotherapy and Prophylactic Cranial Irradiation: A Multicenter Analysis. *Clin Lung Cancer* 2017; **18**: 675-681.e1 [PMID: 28408183 DOI: 10.1016/j.clcc.2017.03.009]
- 83 **Onishi H**, Araki T, Shirato H, Nagata Y, Hiraoka M, Gomi K, Yamashita T, Niibe Y, Karasawa K, Hayakawa K, Takai Y, Kimura T, Hirokawa Y, Takeda A, Ouchi A, Hareyama M, Kokubo M, Hara R, Itami J, Yamada K. Stereotactic hypofractionated high-dose irradiation for stage I nonsmall cell lung carcinoma: clinical outcomes in 245 subjects in a Japanese multiinstitutional study. *Cancer* 2004; **101**: 1623-1631 [PMID: 15378503 DOI: 10.1002/cncr.20539]

- 84 **Ichinose Y**, Hara N, Ohta M, Motohiro A, Hata K, Yagawa K. Brain metastases in patients with limited small cell lung cancer achieving complete remission. Correlation with TNM staging. *Chest* 1989; **96**: 1332-1335 [PMID: [2555114](#) DOI: [10.1378/chest.96.6.1332](#)]
- 85 **Arriagada R**, Le Chevalier T, Rivière A, Chomy P, Monnet I, Bardet E, Santos-Miranda JA, Le Péhoux C, Tarayre M, Benhamou S, Laplanche A. Patterns of failure after prophylactic cranial irradiation in small-cell lung cancer: analysis of 505 randomized patients. *Ann Oncol* 2002; **13**: 748-754 [PMID: [12075744](#) DOI: [10.1093/annonc/mdf123](#)]
- 86 **Arriagada R**, Le Chevalier T, Borie F, Rivière A, Chomy P, Monnet I, Tardivon A, Viader F, Tarayre M, Benhamou S. Prophylactic cranial irradiation for patients with small-cell lung cancer in complete remission. *J Natl Cancer Inst* 1995; **87**: 183-190 [PMID: [7707405](#) DOI: [10.1093/jnci/87.3.183](#)]
- 87 **Seute T**, Leffers P, ten Velde GP, Twijnstra A. Detection of brain metastases from small cell lung cancer: consequences of changing imaging techniques (CT versus MRI). *Cancer* 2008; **112**: 1827-1834 [PMID: [18311784](#) DOI: [10.1002/ncr.23361](#)]
- 88 **Manapov F**, Klautke G, Fietkau R. Prevalence of brain metastases immediately before prophylactic cranial irradiation in limited disease small cell lung cancer patients with complete remission to chemoradiotherapy: a single institution experience. *J Thorac Oncol* 2008; **3**: 652-655 [PMID: [18520807](#) DOI: [10.1097/JTO.0b013e3181757a76](#)]
- 89 **Chu X**, Li S, Xia B, Chu L, Yang X, Ni J, Zou L, Li Y, Xie C, Lin J, Zhu Z. Patterns of brain metastasis immediately before prophylactic cranial irradiation (PCI): implications for PCI optimization in limited-stage small cell lung cancer. *Radiat Oncol* 2019; **14**: 171 [PMID: [31533763](#) DOI: [10.1186/s13014-019-1371-4](#)]
- 90 **Aupérin A**, Arriagada R, Pignon JP, Le Péhoux C, Gregor A, Stephens RJ, Kristjansen PE, Johnson BE, Ueoka H, Wagner H, Aisner J. Prophylactic cranial irradiation for patients with small-cell lung cancer in complete remission. Prophylactic Cranial Irradiation Overview Collaborative Group. *N Engl J Med* 1999; **341**: 476-484 [PMID: [10441603](#) DOI: [10.1056/NEJM199908123410703](#)]
- 91 **Meert AP**, Paesmans M, Berghmans T, Martin B, Mascaux C, Vallot F, Verdebout JM, Lafitte JJ, Sculier JP. Prophylactic cranial irradiation in small cell lung cancer: a systematic review of the literature with meta-analysis. *BMC Cancer* 2001; **1**: 5 [PMID: [11432756](#) DOI: [10.1186/1471-2407-1-5](#)]
- 92 **Viani GA**, Boin AC, Ikeda VY, Vianna BS, Silva RS, Santanella F. Thirty years of prophylactic cranial irradiation in patients with small cell lung cancer: a meta-analysis of randomized clinical trials. *J Bras Pneumol* 2012; **38**: 372-381 [PMID: [22782608](#) DOI: [10.1590/s1806-37132012000300013](#)]
- 93 **Zhang W**, Jiang W, Luan L, Wang L, Zheng X, Wang G. Prophylactic cranial irradiation for patients with small-cell lung cancer: a systematic review of the literature with meta-analysis. *BMC Cancer* 2014; **14**: 793 [PMID: [25361811](#) DOI: [10.1186/1471-2407-14-793](#)]
- 94 **Yang Y**, Zhang D, Zhou X, Bao W, Ji Y, Sheng L, Cheng L, Chen Y, Du X, Qiu G. Prophylactic cranial irradiation in resected small cell lung cancer: A systematic review with meta-analysis. *J Cancer* 2018; **9**: 433-439 [PMID: [29344290](#) DOI: [10.7150/jca.21465](#)]
- 95 **Mamesaya N**, Wakuda K, Omae K, Miyawaki E, Kotake M, Fujiwara T, Kawamura T, Kobayashi H, Nakashima K, Omori S, Ono A, Kenmotsu H, Naito T, Murakami H, Mori K, Harada H, Endo M, Nakajima T, Takahashi T. Efficacy of prophylactic cranial irradiation in patients with limited-disease small-cell lung cancer who were confirmed to have no brain metastasis *via* magnetic resonance imaging after initial chemoradiotherapy. *Oncotarget* 2018; **9**: 17664-17674 [PMID: [29707139](#) DOI: [10.18632/oncotarget.24830](#)]
- 96 **Farris MK**, Wheless WH, Hughes RT, Soike MH, Masters AH, Helis CA, Chan MD, Cramer CK, Ruiz J, Lycan T, Petty WJ, Ahmed T, Leyrer CM, Blackstock AW. Limited-Stage Small Cell Lung Cancer: Is Prophylactic Cranial Irradiation Necessary? *Pract Radiat Oncol* 2019; **9**: e599-e607 [PMID: [31271904](#) DOI: [10.1016/j.pro.2019.06.014](#)]
- 97 **Qiu G**, DU X, Zhou X, Bao W, Chen L, Chen J, Ji Y, Wang S. Prophylactic cranial irradiation in 399 patients with limited-stage small cell lung cancer. *Oncol Lett* 2016; **11**: 2654-2660 [PMID: [27073534](#) DOI: [10.3892/ol.2016.4231](#)]
- 98 **Eze C**, Roengvoraphoj O, Niyazi M, Hildebrandt G, Fietkau R, Belka C, Manapov F. Treatment Response and Prophylactic Cranial Irradiation Are Prognostic Factors in a Real-life Limited-disease Small-cell Lung Cancer Patient Cohort Comprehensively Staged With Cranial Magnetic Resonance Imaging. *Clin Lung Cancer* 2017; **18**: e243-e249 [PMID: [28065620](#) DOI: [10.1016/j.clc.2016.11.005](#)]
- 99 **Le Péhoux C**, Al Mohkles H, Dhermain F. Place actuelle de l'irradiation prophylactique cérébrale [Present role of prophylactic cranial irradiation]. *Bull Cancer* 2013; **100**: 35-43 [PMID: [23306141](#) DOI: [10.1684/bdc.2012.1678](#)]
- 100 **Wu AJ**, Gillis A, Foster A, Woo K, Zhang Z, Gelblum DY, Downey RJ, Rosenzweig KE, Ong L, Perez CA, Pietanza MC, Krug L, Rudin CM, Rimmer A. Patterns of failure in limited-stage small cell lung cancer: Implications of TNM stage for prophylactic cranial irradiation. *Radiother Oncol* 2017; **125**: 130-135 [PMID: [28778345](#) DOI: [10.1016/j.radonc.2017.07.019](#)]
- 101 **Lou Y**, Zhong R, Xu J, Qiao R, Teng J, Zhang Y, Zhang X, Chu T, Zhong H, Han B. Does surgically resected small-cell lung cancer without lymph node involvement benefit from prophylactic cranial irradiation? *Thorac Cancer* 2020; **11**: 1239-1244 [PMID: [32142599](#) DOI: [10.1111/1759-7714.13381](#)]
- 102 **Ozawa Y**, Omae M, Fujii M, Matsui T, Kato M, Sagisaka S, Asada K, Karayama M, Shirai T, Yasuda K, Nakamura Y, Inui N, Yamada K, Yokomura K, Suda T. Management of brain metastasis with magnetic resonance imaging and stereotactic irradiation attenuated benefits of prophylactic cranial irradiation in patients with limited-stage small cell lung cancer. *BMC Cancer* 2015; **15**: 589 [PMID: [26275617](#) DOI: [10.1186/s12885-015-1593-2](#)]
- 103 **Warde P**, Payne D. Does thoracic irradiation improve survival and local control in limited-stage small-cell carcinoma of the lung? *J Clin Oncol* 1992; **10**: 890-895 [PMID: [1316951](#) DOI: [10.1200/JCO.1992.10.6.890](#)]
- 104 **Cohen MH**, Ihde DC, Bunn PA Jr, Fossieck BE Jr, Matthews MJ, Shackney SE, Johnston-Early A, Makuch R, Minna JD. Cyclic alternating combination chemotherapy for small cell bronchogenic carcinoma. *Cancer Treat Rep* 1979; **63**: 163-170 [PMID: [221114](#)]
- 105 **Pignon JP**, Arriagada R, Ihde DC, Johnson DH, Perry MC, Souhami RL, Brodin O, Joss RA, Kies MS, Lebeau B. A meta-analysis of thoracic radiotherapy for small-cell lung cancer. *N Engl J Med* 1992; **327**: 1618-1624 [PMID: [1331787](#) DOI: [10.1056/NEJM199212033272302](#)]

- 106 **Faivre-Finn C**, Snee M, Ashcroft L, Appel W, Barlesi F, Bhatnagar A, Bezjak A, Cardenal F, Fournel P, Harden S, Le Pechoux C, McMenemin R, Mohammed N, O'Brien M, Pantarotto J, Surmont V, Van Meerbeeck JP, Woll PJ, Lorigan P, Blackhall F; CONVERT Study Team. Concurrent once-daily versus twice-daily chemoradiotherapy in patients with limited-stage small-cell lung cancer (CONVERT): an open-label, phase 3, randomised, superiority trial. *Lancet Oncol* 2017; **18**: 1116-1125 [PMID: 28642008 DOI: 10.1016/S1470-2045(17)30318-2]
- 107 **Spigel DR**, Hainsworth JD, Yardley DA, Raefsky E, Patton J, Peacock N, Farley C, Burris HA 3rd, Greco FA. Tracheoesophageal fistula formation in patients with lung cancer treated with chemoradiation and bevacizumab. *J Clin Oncol* 2010; **28**: 43-48 [PMID: 19901100 DOI: 10.1200/JCO.2009.24.7353]
- 108 **Rodríguez de Dios N**, Couñago F, López JL, Calvo P, Murcia M, Rico M, Vallejo C, Luna J, Trueba I, Cigarral C, Farre N, Manero RM, Durán X, Samper P. Treatment Design and Rationale for a Randomized Trial of Prophylactic Cranial Irradiation With or Without Hippocampal Avoidance for SCLC: PREMER Trial on Behalf of the Oncologic Group for the Study of Lung Cancer/Spanish Radiation Oncology Group-Radiation Oncology Clinical Research Group. *Clin Lung Cancer* 2018; **19**: e693-e697 [PMID: 29891263 DOI: 10.1016/j.clcc.2018.05.003]
- 109 **Belderbos JSA**, De Ruyscher DKM, De Jaeger K, Koppe F, Lambrecht MLF, Lievens YN, Dieleman EMT, Jaspers JPM, Van Meerbeeck JP, Ubbels F, Kwint MH, Kuenen MA, Deprez S, De Ruyter MB, Boogerd W, Sikorska K, Van Tinteren H, Schagen SB. Phase 3 Randomized Trial of Prophylactic Cranial Irradiation With or Without Hippocampus Avoidance in SCLC (NCT01780675). *J Thorac Oncol* 2021; **16**: 840-849 [PMID: 33545387 DOI: 10.1016/j.jtho.2020.12.024]
- 110 **Rodríguez de Dios N**, Murcia M, Couñago F, López JL, Rico M, Samper PM, Vallejo C, Luna FJ, Trueba I, Cigarral CC, Sotoca A, Gispert JD, Farré N, Manero RM, Capellades J, Jiménez M, Durán X, Ordoñez C, Rognoni T, Blanco M, Bacaicoa MC, Torrente M, Montero M, Alonso A, Escribano J, Martínez J, Calvo PP. Phase III trial of prophylactic cranial irradiation with or without hippocampal avoidance for small-cell lung cancer on behalf of GOECP/SEOR-GICOR. *Int J Radiat Oncol Biol Phys* 2019; **105**: S35-S36 [DOI: 10.1016/j.ijrobp.2019.06.451]
- 111 **Brown PD**, Gondi V, Pugh S, Tome WA, Wefel JS, Armstrong TS, Bovi JA, Robinson C, Konski A, Khuntia D, Grosshans D, Benzinger TLS, Bruner D, Gilbert MR, Roberge D, Kundapur V, Devisetty K, Shah S, Usuki K, Anderson BM, Stea B, Yoon H, Li J, Laack NN, Kruser TJ, Chmura SJ, Shi W, Deshmukh S, Mehta MP, Kachnic LA; for NRG Oncology. Hippocampal Avoidance During Whole-Brain Radiotherapy Plus Memantine for Patients With Brain Metastases: Phase III Trial NRG Oncology CC001. *J Clin Oncol* 2020; **38**: 1019-1029 [PMID: 32058845 DOI: 10.1200/JCO.19.02767]
- 112 **Liao Z**, Lee JJ, Komaki R, Gomez DR, O'Reilly MS, Fossella FV, Blumenschein GR Jr, Heymach JV, Vaporciyan AA, Swisher SG, Allen PK, Choi NC, DeLaney TF, Hahn SM, Cox JD, Lu CS, Mohan R. Bayesian Adaptive Randomization Trial of Passive Scattering Proton Therapy and Intensity-Modulated Photon Radiotherapy for Locally Advanced Non-Small-Cell Lung Cancer. *J Clin Oncol* 2018; **36**: 1813-1822 [PMID: 29293386 DOI: 10.1200/JCO.2017.74.0720]
- 113 **Rwigema JM**, Verma V, Lin L, Berman AT, Levin WP, Evans TL, Aggarwal C, Rengan R, Langer C, Cohen RB, Simone CB 2nd. Prospective study of proton-beam radiation therapy for limited-stage small cell lung cancer. *Cancer* 2017; **123**: 4244-4251 [PMID: 28678434 DOI: 10.1002/encr.30870]
- 114 **Rossi A**, Di Maio M, Chiodini P, Rudd RM, Okamoto H, Skarlos DV, Früh M, Qian W, Tamura T, Samantas E, Shibata T, Perrone F, Gallo C, Gridelli C, Martelli O, Lee SM. Carboplatin- or cisplatin-based chemotherapy in first-line treatment of small-cell lung cancer: the COCIS meta-analysis of individual patient data. *J Clin Oncol* 2012; **30**: 1692-1698 [PMID: 22473169 DOI: 10.1200/JCO.2011.40.4905]
- 115 **Rossi A**, Garassino MC, Cinquini M, Sburlati P, Di Maio M, Farina G, Gridelli C, Torri V. Maintenance or consolidation therapy in small-cell lung cancer: a systematic review and meta-analysis. *Lung Cancer* 2010; **70**: 119-128 [PMID: 20188431 DOI: 10.1016/j.lungcan.2010.02.001]
- 116 **Tiseo M**, Boni L, Ambrosio F, Camerini A, Baldini E, Cinieri S, Brighenti M, Zanelli F, Defraia E, Chiari R, Dazzi C, Tibaldi C, Turolla GM, D'Alessandro V, Zilembo N, Trolese AR, Grossi F, Riccardi F, Ardizzoni A. Italian, Multicenter, Phase III, Randomized Study of Cisplatin Plus Etoposide With or Without Bevacizumab as First-Line Treatment in Extensive-Disease Small-Cell Lung Cancer: The GOIRC-AIFA FARM6PMFJM Trial. *J Clin Oncol* 2017; **35**: 1281-1287 [PMID: 28135143 DOI: 10.1200/JCO.2016.69.4844]
- 117 **Pujol JL**, Lavole A, Quoix E, Molinier O, Souquet PJ, Barlesi F, Le Caer H, Moro-Sibilot D, Fournel P, Oster JP, Chatellain P, Barre P, Jeannin G, Mourlanette P, Derollez M, Herman D, Renault A, Dayen C, Lamy PJ, Langlais A, Morin F, Zalzman G; French Cooperative Thoracic Intergroup (IFCT). Randomized phase II-III study of bevacizumab in combination with chemotherapy in previously untreated extensive small-cell lung cancer: results from the IFCT-0802 trial†. *Ann Oncol* 2015; **26**: 908-914 [PMID: 25688059 DOI: 10.1093/annonc/mdv065]
- 118 **Horn L**, Mansfield AS, Szczęśna A, Havel L, Krzakowski M, Hochmair MJ, Huemer F, Losonczy G, Johnson ML, Nishio M, Reck M, Mok T, Lam S, Shames DS, Liu J, Ding B, Lopez-Chavez A, Kabbinarav F, Lin W, Sandler A, Liu SV; Impower133 Study Group. First-Line Atezolizumab plus Chemotherapy in Extensive-Stage Small-Cell Lung Cancer. *N Engl J Med* 2018; **379**: 2220-2229 [PMID: 30280641 DOI: 10.1056/NEJMoa1809064]
- 119 **Paz-Ares L**, Dvorkin M, Chen Y, Reinmuth N, Hotta K, Trukhin D, Statsenko G, Hochmair MJ, Özgüroğlu M, Ji JH, Voitko O, Poltoratskiy A, Ponce S, Verderame F, Havel L, Bondarenko I, Kazarnowicz A, Losonczy G, Conev NV, Armstrong J, Byrne N, Shire N, Jiang H, Goldman JW; CASPIAN investigators. Durvalumab plus platinum-etoposide versus platinum-etoposide in first-line treatment of extensive-stage small-cell lung cancer (CASPIAN): a randomised, controlled, open-label, phase 3 trial. *Lancet* 2019; **394**: 1929-1939 [PMID: 31590988 DOI: 10.1016/S0140-6736(19)32222-6]
- 120 **Reck M**, Liu SV, Mansfield AS, Mok TSK, Scherpereel A, Reinmuth N, Garassino MC, CastroDe Carpeno J, Califano R, Nishio M, Orlandi F, Alatorre Alexander AJ, Leal TA, Cheng Y, Lee JS, Lam S, McClelland M, Deng Y, Phan S, Horn L. Impower133: updated overall survival (OS) analysis of first-line (1L) atezolizumab (atezo) + carboplatin + etoposide in extensive-stage SCLC (ES-SCLC). *Ann Oncol* 2019; **30** Suppl 9: v710-v717 [DOI: 10.1093/annonc/mdz264]
- 121 **Ortega-Franco A**, Ackermann C, Paz-Ares L, Califano R. First-line immune checkpoint inhibitors for extensive stage small-cell lung cancer: clinical developments and future directions. *ESMO Open* 2021; **6**: 100003 [PMID: 33450659 DOI: 10.1016/j.esmoop.2021.100003]

- 10.1016/j.esmoop.2020.100003]
- 122 **Paz-Ares LG**, Dvorkin M, Chen Y, Reinmuth N, Hotta K, Trukhin D, Statsenko G, Hochmair M, Özgüroğlu M, Ji JH, Voitko O, Poltoratskiy A, Verderame F, Havel L, Bondarenko I, Armstrong J, Byrne N, Jiang H, Wade Goldman J. Durvalumab ± tremelimumab + platinum-etoposide in first-line extensive-stage SCLC (ES-SCLC): Updated Results from the phase III CASPIAN study. *J Clin Oncol* 2020; **38**: 9002
- 123 **Goldman JW**, Dvorkin M, Chen Y, Reinmuth N, Hotta K, Trukhin D, Statsenko G, Hochmair MJ, Özgüroğlu M, Ji JH, Garassino MC, Voitko O, Poltoratskiy A, Ponce S, Verderame F, Havel L, Bondarenko I, Kazarnowicz A, Losonczy G, Conev NV, Armstrong J, Byrne N, Thiagarajah P, Jiang H, Paz-Ares L; CASPIAN investigators. Durvalumab, with or without tremelimumab, plus platinum-etoposide versus platinum-etoposide alone in first-line treatment of extensive-stage small-cell lung cancer (CASPIAN): updated results from a randomised, controlled, open-label, phase 3 trial. *Lancet Oncol* 2021; **22**: 51-65 [PMID: 33285097 DOI: 10.1016/S1470-2045(20)30539-8]
- 124 **Rudin CM**, Awad MM, Navarro A, Gottfried M, Peters S, Csószti T, Cheema PK, Rodriguez-Abreu D, Wollner M, Yang JC, Mazieres J, Orlandi FJ, Luft A, Gümüş M, Kato T, Kalemkerian GP, Luo Y, Ebiana V, Pietanza MC, Kim HR; KEYNOTE-604 Investigators. Pembrolizumab or Placebo Plus Etoposide and Platinum as First-Line Therapy for Extensive-Stage Small-Cell Lung Cancer: Randomized, Double-Blind, Phase III KEYNOTE-604 Study. *J Clin Oncol* 2020; **38**: 2369-2379 [PMID: 32468956 DOI: 10.1200/JCO.20.00793]
- 125 **Leal T**, Wang Y, Dowlati A, Andrew Lewis D, Chen Y, Ramesh Mohindra A, Razaq M, Ahuja HG, Liu J, King DM, Sumey CJ, Ramalingam SS. Randomized phase II clinical trial of cisplatin/carboplatin and etoposide (CE) alone or in combination with nivolumab as frontline therapy for extensive-stage small cell lung cancer (ES-SCLC): ECOG-ACRIN EA5161. *J Clin Oncol* 2020; **38**: 9000 [DOI: 10.1200/JCO.2020.38.15_suppl.9000]
- 126 **Zhou T**, Zhang Z, Luo F, Zhao Y, Hou X, Liu T, Wang K, Zhao H, Huang Y, Zhang L. Comparison of First-Line Treatments for Patients With Extensive-Stage Small Cell Lung Cancer: A Systematic Review and Network Meta-analysis. *JAMA Netw Open* 2020; **3**: e2015748 [PMID: 33074323 DOI: 10.1001/jamanetworkopen.2020.15748]
- 127 **Facchinetti F**, Di Maio M, Tiseo M. Adding PD-1/PD-L1 Inhibitors to Chemotherapy for the First-Line Treatment of Extensive Stage Small Cell Lung Cancer (SCLC): A Meta-Analysis of Randomized Trials. *Cancers (Basel)* 2020; **12** [PMID: 32947924 DOI: 10.3390/cancers12092645]
- 128 **Reck M**, Bondarenko I, Luft A, Serwatowski P, Barlesi F, Chacko R, Sebastian M, Lu H, Cuillerot JM, Lynch TJ. Ipilimumab in combination with paclitaxel and carboplatin as first-line therapy in extensive-disease-small-cell lung cancer: results from a randomized, double-blind, multicenter phase 2 trial. *Ann Oncol* 2013; **24**: 75-83 [PMID: 22858559 DOI: 10.1093/annonc/mds213]
- 129 **Reck M**, Luft A, Szczesna A, Havel L, Kim SW, Akerley W, Pietanza MC, Wu YL, Zielinski C, Thomas M, Felip E, Gold K, Horn L, Aerts J, Nakagawa K, Lorigan P, Pieters A, Kong Sanchez T, Fairchild J, Spigel D. Phase III Randomized Trial of Ipilimumab Plus Etoposide and Platinum Versus Placebo Plus Etoposide and Platinum in Extensive-Stage Small-Cell Lung Cancer. *J Clin Oncol* 2016; **34**: 3740-3748 [PMID: 27458307 DOI: 10.1200/JCO.2016.67.6601]
- 130 **Zatloukal P**, Cardenal F, Szczesna A, Gorbunova V, Moiseyenko V, Zhang X, Cisar L, Soria JC, Domine M, Thomas M. A multicenter international randomized phase III study comparing cisplatin in combination with irinotecan or etoposide in previously untreated small-cell lung cancer patients with extensive disease. *Ann Oncol* 2010; **21**: 1810-1816 [PMID: 20231298 DOI: 10.1093/annonc/mdq036]
- 131 **Lara PN Jr**, Natale R, Crowley J, Lenz HJ, Redman MW, Carleton JE, Jett J, Langer CJ, Kuebler JP, Dakhil SR, Chansky K, Gandara DR. Phase III trial of irinotecan/cisplatin compared with etoposide/cisplatin in extensive-stage small-cell lung cancer: clinical and pharmacogenomic results from SWOG S0124. *J Clin Oncol* 2009; **27**: 2530-2535 [PMID: 19349543 DOI: 10.1200/JCO.2008.20.1061]
- 132 **Hanna N**, Bunn PA Jr, Langer C, Einhorn L, Guthrie T Jr, Beck T, Ansari R, Ellis P, Byrne M, Morrison M, Hariharan S, Wang B, Sandler A. Randomized phase III trial comparing irinotecan/cisplatin with etoposide/cisplatin in patients with previously untreated extensive-stage disease small-cell lung cancer. *J Clin Oncol* 2006; **24**: 2038-2043 [PMID: 16648503 DOI: 10.1200/JCO.2005.04.8595]
- 133 **Slotman B**, Faivre-Finn C, Kramer G, Rankin E, Snee M, Hatton M, Postmus P, Collette L, Musat E, Senan S; EORTC Radiation Oncology Group and Lung Cancer Group. Prophylactic cranial irradiation in extensive small-cell lung cancer. *N Engl J Med* 2007; **357**: 664-672 [PMID: 17699816 DOI: 10.1056/NEJMoa071780]
- 134 **Rule WG**, Foster NR, Meyers JP, Ashman JB, Vora SA, Kozelsky TF, Garces YI, Urbanic JJ, Salama JK, Schild SE. Prophylactic cranial irradiation in elderly patients with small cell lung cancer: findings from a North Central Cancer Treatment Group pooled analysis. *J Geriatr Oncol* 2015; **6**: 119-126 [PMID: 25482023 DOI: 10.1016/j.jgo.2014.11.002]
- 135 **Ge W**, Xu H, Yan Y, Cao D. The effects of prophylactic cranial irradiation versus control on survival of patients with extensive-stage small-cell lung cancer: a meta-analysis of 14 trials. *Radiat Oncol* 2018; **13**: 155 [PMID: 30139360 DOI: 10.1186/s13014-018-1101-3]
- 136 **Wen P**, Wang TF, Li M, Yu Y, Zhou YL, Wu CL. Meta-analysis of prophylactic cranial irradiation or not in treatment of extensive-stage small-cell lung cancer: The dilemma remains. *Cancer Radiother* 2020; **24**: 44-52 [PMID: 32044160 DOI: 10.1016/j.canrad.2019.10.001]
- 137 **Takahashi T**, Yamanaka T, Seto T, Harada H, Nokihara H, Saka H, Nishio M, Kaneda H, Takayama K, Ishimoto O, Takeda K, Yoshioka H, Tachihara M, Sakai H, Goto K, Yamamoto N. Prophylactic cranial irradiation versus observation in patients with extensive-disease small-cell lung cancer: a multicentre, randomised, open-label, phase 3 trial. *Lancet Oncol* 2017; **18**: 663-671 [PMID: 28343976 DOI: 10.1016/S1470-2045(17)30230-9]
- 138 **Yin X**, Yan D, Qiu M, Huang L, Yan SX. Prophylactic cranial irradiation in small cell lung cancer: a systematic review and meta-analysis. *BMC Cancer* 2019; **19**: 95 [PMID: 30665432 DOI: 10.1186/s12885-018-5251-3]
- 139 **Gondi V**, Paulus R, Bruner DW, Meyers CA, Gore EM, Wolfson A, Werner-Wasik M, Sun AY, Choy H, Movsas B. Decline in tested and self-reported cognitive functioning after prophylactic cranial irradiation for lung cancer: pooled secondary analysis of Radiation Therapy Oncology Group randomized trials 0212 and 0214. *Int J Radiat Oncol Biol Phys* 2013; **86**: 656-664 [PMID: 23597420 DOI: 10.1016/j.ijrobp.2013.02.033]
- 140 **Le Péchoux C**, Dunant A, Senan S, Wolfson A, Quoix E, Faivre-Finn C, Ciuleanu T, Arriagada R, Jones R, Wanders R,

- Lerouge D, Laplanche A; Prophylactic Cranial Irradiation (PCI) Collaborative Group. Standard-dose versus higher-dose prophylactic cranial irradiation (PCI) in patients with limited-stage small-cell lung cancer in complete remission after chemotherapy and thoracic radiotherapy (PCI 99-01, EORTC 22003-08004, RTOG 0212, and IFCT 99-01): a randomised clinical trial. *Lancet Oncol* 2009; **10**: 467-474 [PMID: 19386548 DOI: 10.1016/S1470-2045(09)70101-9]
- 141 **Hurwitz JL**, McCoy F, Scullin P, Fennell DA. New advances in the second-line treatment of small cell lung cancer. *Oncologist* 2009; **14**: 986-994 [PMID: 19819917 DOI: 10.1634/theoncologist.2009-0026]
- 142 **Schneider BJ**. Management of recurrent small cell lung cancer. *J Natl Compr Canc Netw* 2008; **6**: 323-331 [PMID: 18377850 DOI: 10.6004/jnccn.2008.0027]
- 143 **Owonikoko TK**, Behera M, Chen Z, Bhimani C, Curran WJ, Khuri FR, Ramalingam SS. A systematic analysis of efficacy of second-line chemotherapy in sensitive and refractory small-cell lung cancer. *J Thorac Oncol* 2012; **7**: 866-872 [PMID: 22722788 DOI: 10.1097/JTO.0b013e31824c7f4b]
- 144 **Baize N**, Monnet I, Greillier L, Geier M, Lena H, Janicot H, Vergnenegre A, Crequit J, Lamy R, Auliac JB, Letret J, Le Caer H, Gervais R, Dansin E, Madroszyk A, Renault PA, Le Garff G, Falchero L, Berard H, Schott R, Saulnier P, Chouaid C; Groupe Français de Pneumo-Cancérologie 01–13 investigators. Carboplatin plus etoposide versus topotecan as second-line treatment for patients with sensitive relapsed small-cell lung cancer: an open-label, multicentre, randomised, phase 3 trial. *Lancet Oncol* 2020; **21**: 1224-1233 [PMID: 32888454 DOI: 10.1016/S1470-2045(20)30461-7]
- 145 **Naito Y**, Yamada K, Imamura Y, Ishii H, Matsuo N, Tokito T, Kinoshita T, Azuma K, Hoshino T. Rechallenge treatment with a platinum-based regimen in patients with sensitive relapsed small-cell lung cancer. *Med Oncol* 2018; **35**: 61 [PMID: 29610997 DOI: 10.1007/s12032-018-1123-6]
- 146 **O'Brien ME**, Ciuleanu TE, Tsekov H, Shparyk Y, Cuceviá B, Juhasz G, Thatcher N, Ross GA, Dane GC, Crofts T. Phase III trial comparing supportive care alone with supportive care with oral topotecan in patients with relapsed small-cell lung cancer. *J Clin Oncol* 2006; **24**: 5441-5447 [PMID: 17135646 DOI: 10.1200/JCO.2006.06.5821]
- 147 **von Pawel J**, Schiller JH, Shepherd FA, Fields SZ, Kleisbauer JP, Chrysson NG, Stewart DJ, Clark PI, Palmer MC, Depierre A, Carmichael J, Krebs JB, Ross G, Lane SR, Gralla R. Topotecan versus cyclophosphamide, doxorubicin, and vincristine for the treatment of recurrent small-cell lung cancer. *J Clin Oncol* 1999; **17**: 658-667 [PMID: 10080612 DOI: 10.1200/JCO.1999.17.2.658]
- 148 **Allen JW**, Moon J, Redman M, Gadgeel SM, Kelly K, Mack PC, Saba HM, Mohamed MK, Jahanzeb M, Gandara DR. Southwest Oncology Group S0802: a randomized, phase II trial of weekly topotecan with and without ziv-aflibercept in patients with platinum-treated small-cell lung cancer. *J Clin Oncol* 2014; **32**: 2463-2470 [PMID: 25002722 DOI: 10.1200/JCO.2013.51.4109]
- 149 **Trigo J**, Subbiah V, Besse B, Moreno V, López R, Sala MA, Peters S, Ponce S, Fernández C, Alfaro V, Gómez J, Kahatt C, Zeaiter A, Zaman K, Boni V, Arrondeau J, Martínez M, Delord JP, Awada A, Kristeleit R, Olmedo ME, Wannesson L, Valdivia J, Rubio MJ, Anton A, Sarantopoulos J, Chawla SP, Mosquera-Martinez J, D'Arcangelo M, Santoro A, Villalobos VM, Sands J, Paz-Ares L. Lurbinectedin as second-line treatment for patients with small-cell lung cancer: a single-arm, open-label, phase 2 basket trial. *Lancet Oncol* 2020; **21**: 645-654 [PMID: 32224306 DOI: 10.1016/S1470-2045(20)30068-1]
- 150 **Calvo E**, Moreno V, Flynn M, Holgado E, Olmedo ME, Lopez Criado MP, Kahatt C, Lopez-Vilarino JA, Siguero M, Fernandez-Teruel C, Cullell-Young M, Soto Matos-Pita A, Forster M. Antitumor activity of lurbinectedin (PM01183) and doxorubicin in relapsed small-cell lung cancer: results from a phase I study. *Ann Oncol* 2017; **28**: 2559-2566 [PMID: 28961837 DOI: 10.1093/annonc/mdx357]
- 151 **Farago AF**, Drapkin BJ, Lopez-Vilarino de Ramos JA, Galmarini CM, Núñez R, Kahatt C, Paz-Ares L. ATLANTIS: a Phase III study of lurbinectedin/doxorubicin versus topotecan or cyclophosphamide/doxorubicin/vincristine in patients with small-cell lung cancer who have failed one prior platinum-containing line. *Future Oncol* 2019; **15**: 231-239 [PMID: 30362375 DOI: 10.2217/fon-2018-0597]
- 152 **von Pawel J**, Jotte R, Spigel DR, O'Brien ME, Socinski MA, Mezger J, Steins M, Bosquée L, Bubis J, Nackaerts K, Trigo JM, Clingan P, Schütte W, Lorigan P, Reck M, Domine M, Shepherd FA, Li S, Renschler MF. Randomized phase III trial of amrubicin versus topotecan as second-line treatment for patients with small-cell lung cancer. *J Clin Oncol* 2014; **32**: 4012-4019 [PMID: 25385727 DOI: 10.1200/JCO.2013.54.5392]
- 153 **Antonia SJ**, López-Martin JA, Bendell J, Ott PA, Taylor M, Eder JP, Jäger D, Pietanza MC, Le DT, de Braud F, Morse MA, Ascierto PA, Horn L, Amin A, Pillai RN, Evans J, Chau I, Bono P, Atmaca A, Sharma P, Harbison CT, Lin CS, Christensen O, Calvo E. Nivolumab alone and nivolumab plus ipilimumab in recurrent small-cell lung cancer (CheckMate 032): a multicentre, open-label, phase 1/2 trial. *Lancet Oncol* 2016; **17**: 883-895 [PMID: 27269741 DOI: 10.1016/S1470-2045(16)30098-5]
- 154 **Ready NE**, Ott PA, Hellmann MD, Zugazagoitia J, Hann CL, de Braud F, Antonia SJ, Ascierto PA, Moreno V, Atmaca A, Salvagni S, Taylor M, Amin A, Camidge DR, Horn L, Calvo E, Li A, Lin WH, Callahan MK, Spigel DR. Nivolumab Monotherapy and Nivolumab Plus Ipilimumab in Recurrent Small Cell Lung Cancer: Results From the CheckMate 032 Randomized Cohort. *J Thorac Oncol* 2020; **15**: 426-435 [PMID: 31629915 DOI: 10.1016/j.jtho.2019.10.004]
- 155 **Spigel DR**, Vicente D, Ciuleanu TE, Gettinger S, Peters S, Horn L, Audigier-Valette C, Pardo Aranda N, Juan-Vidal O, Cheng Y, Zhang H, Shi M, Luft A, Wolf J, Antonia S, Nakagawa K, Fairchild J, Baudelet C, Pandya D, Doshi P, Chang H, Reck M. Second-line nivolumab in relapsed small-cell lung cancer: CheckMate 331*. *Ann Oncol* 2021; **32**: 631-641 [PMID: 33539946 DOI: 10.1016/j.annonc.2021.01.071]
- 156 **Ott PA**, Elez E, Hirt S, Kim DW, Morosky A, Saraf S, Piperdi B, Mehnert JM. Pembrolizumab in Patients With Extensive-Stage Small-Cell Lung Cancer: Results From the Phase Ib KEYNOTE-028 Study. *J Clin Oncol* 2017; **35**: 3823-3829 [PMID: 28813164 DOI: 10.1200/JCO.2017.72.5069]
- 157 **Chung HC**, Lopez-Martin JA, Kao SC, Miller WH, Ros W, Gao B, Marabelle A, Gottfried M, Zer A, Delord JP, Penel N, Jalal SI, Xu L, Zeigenfuss S, Pruitt SK, Piha-Paul SA. Phase 2 study of pembrolizumab in advanced small-cell lung cancer (SCLC): KEYNOTE-158. *J Clin Oncol* 2018; **36**: 8506-8506 [DOI: 10.1200/JCO.2018.36.15_suppl.8506]
- 158 **Chung HC**, Piha-Paul SA, Lopez-Martin J. -Pembrolizumab after two or more lines of prior therapy in patients with advanced small-cell lung cancer (SCLC). Proceedings of the AACR Annual Meeting; 2019; Leeds, GA. Atlanta 2019:

Abstract CT073

- 159 **Pujol JL**, Greillier L, Audigier-Valette C, Moro-Sibilot D, Uwer L, Hureau J, Guisier F, Carmier D, Madelaine J, Otto J, Gounant V, Merle P, Mourlanette P, Molinier O, Renault A, Rabeau A, Antoine M, Denis MG, Bommart S, Langlais A, Morin F, Souquet PJ. A Randomized Non-Comparative Phase II Study of Anti-Programmed Cell Death-Ligand 1 Atezolizumab or Chemotherapy as Second-Line Therapy in Patients With Small Cell Lung Cancer: Results From the IFCT-1603 Trial. *J Thorac Oncol* 2019; **14**: 903-913 [PMID: 30664989 DOI: 10.1016/j.jtho.2019.01.008]
- 160 **Kim YJ**, Keam B, Ock CY, Song S, Kim M, Kim SH, Kim KH, Kim JS, Kim TM, Kim DW, Lee JS, Heo DS. A phase II study of pembrolizumab and paclitaxel in patients with relapsed or refractory small-cell lung cancer. *Lung Cancer* 2019; **136**: 122-128 [PMID: 31494530 DOI: 10.1016/j.lungcan.2019.08.031]
- 161 **Pietanza MC**, Kadota K, Huberman K, Sima CS, Fiore JJ, Sumner DK, Travis WD, Heguy A, Ginsberg MS, Holodny AI, Chan TA, Rizvi NA, Azzoli CG, Riely GJ, Kris MG, Krug LM. Phase II trial of temozolomide in patients with relapsed sensitive or refractory small cell lung cancer, with assessment of methylguanine-DNA methyltransferase as a potential biomarker. *Clin Cancer Res* 2012; **18**: 1138-1145 [PMID: 22228633 DOI: 10.1158/1078-0432.CCR-11-2059]
- 162 **Zauderer MG**, Drilon A, Kadota K, Huberman K, Sima CS, Bergagnini I, Sumner DK, Travis WD, Heguy A, Ginsberg MS, Holodny AI, Riely GJ, Kris MG, Krug LM, Pietanza MC. Trial of a 5-day dosing regimen of temozolomide in patients with relapsed small cell lung cancers with assessment of methylguanine-DNA methyltransferase. *Lung Cancer* 2014; **86**: 237-240 [PMID: 25194640 DOI: 10.1016/j.lungcan.2014.08.007]
- 163 **Masuda N**, Fukuoka M, Kusunoki Y, Matsui K, Takifuji N, Kudoh S, Negoro S, Nishioka M, Nakagawa K, Takada M. CPT-11: a new derivative of camptothecin for the treatment of refractory or relapsed small-cell lung cancer. *J Clin Oncol* 1992; **10**: 1225-1229 [PMID: 1321891 DOI: 10.1200/JCO.1992.10.8.1225]
- 164 **Yamamoto N**, Tsurutani J, Yoshimura N, Asai G, Moriyama A, Nakagawa K, Kudoh S, Takada M, Minato Y, Fukuoka M. Phase II study of weekly paclitaxel for relapsed and refractory small cell lung cancer. *Anticancer Res* 2006; **26**: 777-781 [PMID: 16739353]
- 165 **Smit EF**, Fokkema E, Biesma B, Groen HJ, Snoek W, Postmus PE. A phase II study of paclitaxel in heavily pretreated patients with small-cell lung cancer. *Br J Cancer* 1998; **77**: 347-351 [PMID: 9461009 DOI: 10.1038/bjc.1998.54]
- 166 **Smyth JF**, Smith IE, Sessa C, Schoffski P, Wanders J, Franklin H, Kaye SB. Activity of docetaxel (Taxotere) in small cell lung cancer. The Early Clinical Trials Group of the EORTC. *Eur J Cancer* 1994; **30A**: 1058-1060 [PMID: 7654428 DOI: 10.1016/0959-8049(94)90455-3]
- 167 **Masters GA**, Declerck L, Blanke C, Sandler A, DeVore R, Miller K, Johnson D; Eastern Cooperative Oncology Group. Phase II trial of gemcitabine in refractory or relapsed small-cell lung cancer: Eastern Cooperative Oncology Group Trial 1597. *J Clin Oncol* 2003; **21**: 1550-1555 [PMID: 12697880 DOI: 10.1200/JCO.2003.09.130]
- 168 **Hoang T**, Kim K, Jaslowski A, Koch P, Beatty P, McGovern J, Quisumbing M, Shapiro G, Witte R, Schiller JH. Phase II study of second-line gemcitabine in sensitive or refractory small cell lung cancer. *Lung Cancer* 2003; **42**: 97-102 [PMID: 14512193 DOI: 10.1016/s0169-5002(03)00273-3]
- 169 **Furuse K**, Kubota K, Kawahara M, Takada M, Kimura I, Fujii M, Ohta M, Hasegawa K, Yoshida K, Nakajima S, Ogura T, Niitani H. Phase II study of vinorelbine in heavily previously treated small cell lung cancer. Japan Lung Cancer Vinorelbine Study Group. *Oncology* 1996; **53**: 169-172 [PMID: 8604245 DOI: 10.1159/000227555]
- 170 **Kang JH**, Lee KH, Kim DW, Kim SW, Kim HR, Kim JH, Choi JH, An HJ, Kim JS, Jang JS, Kim BS, Kim HT. A randomised phase 2b study comparing the efficacy and safety of belotecan vs. topotecan as monotherapy for sensitive-relapsed small-cell lung cancer. *Br J Cancer* 2021; **124**: 713-720 [PMID: 33191408 DOI: 10.1038/s41416-020-01055-5]
- 171 **Byers LA**, Wang J, Nilsson MB, Fujimoto J, Saintigny P, Yordy J, Giri U, Peyton M, Fan YH, Diao L, Masrorpour F, Shen L, Liu W, Duchemann B, Tumula P, Bhardwaj V, Welsh J, Weber S, Glisson BS, Kalhor N, Wistuba II, Girard L, Lippman SM, Mills GB, Coombes KR, Weinstein JN, Minna JD, Heymach JV. Proteomic profiling identifies dysregulated pathways in small cell lung cancer and novel therapeutic targets including PARP1. *Cancer Discov* 2012; **2**: 798-811 [PMID: 22961666 DOI: 10.1158/2159-8290.CD-12-0112]
- 172 **de Bono J**, Ramanathan RK, Mina L, Chugh R, Glaspy J, Raffi S, Kaye S, Sachdev J, Heymach J, Smith DC, Henshaw JW, Herriott A, Patterson M, Curtin NJ, Byers LA, Wainberg ZA. Phase I, Dose-Escalation, Two-Part Trial of the PARP Inhibitor Talazoparib in Patients with Advanced Germline *BRCAl/2* Mutations and Selected Sporadic Cancers. *Cancer Discov* 2017; **7**: 620-629 [PMID: 28242752 DOI: 10.1158/2159-8290.CD-16-1250]
- 173 **Penella W**, Gaunt P, Steele N, Ahmed S, Mulatero C, Shah R, Danson S, Hodgkinson E, James K, Watkins B, Fletcher P, Billingham L. P1.07-015 STOMP: A UK National Cancer Research Network Randomised, Double Blind, Multicentre Phase II Trial of Olaparib as Maintenance Therapy in SCLC. *J Thorac Oncol* 2017; **12**: S704-S705 [DOI: 10.1016/j.jtho.2016.11.926]
- 174 **Owonikoko TK**, Dahlberg SE, Sica GL, Wagner LI, Wade JL 3rd, Srkalovic G, Lash BW, Leach JW, Leal TB, Aggarwal C, Ramalingam SS. Randomized Phase II Trial of Cisplatin and Etoposide in Combination With Veliparib or Placebo for Extensive-Stage Small-Cell Lung Cancer: ECOG-ACRIN 2511 Study. *J Clin Oncol* 2019; **37**: 222-229 [PMID: 30523756 DOI: 10.1200/JCO.18.00264]
- 175 **Poirier JT**, George J, Owonikoko TK, Berns A, Brambilla E, Byers LA, Carbone D, Chen HJ, Christensen CL, Dive C, Farago AF, Govindan R, Hann C, Hellmann MD, Horn L, Johnson JE, Ju YS, Kang S, Krasnow M, Lee J, Lee SH, Lehman J, Lok B, Lovly C, MacPherson D, McFadden D, Minna J, Oser M, Park K, Park KS, Pommier Y, Quaranta V, Ready N, Sage J, Scagliotti G, Sos ML, Sutherland KD, Travis WD, Vakoc CR, Wait SJ, Wistuba I, Wong KK, Zhang H, Daigneault J, Wiens J, Rudin CM, Oliver TG. New Approaches to SCLC Therapy: From the Laboratory to the Clinic. *J Thorac Oncol* 2020; **15**: 520-540 [PMID: 32018053 DOI: 10.1016/j.jtho.2020.01.016]
- 176 **Pietanza MC**, Waqar SN, Krug LM, Dowlati A, Hann CL, Chiappori A, Owonikoko TK, Woo KM, Cardnell RJ, Fujimoto J, Long L, Diao L, Wang J, Bensman Y, Hurtado B, de Groot P, Sulman EP, Wistuba II, Chen A, Fleisher M, Heymach JV, Kris MG, Rudin CM, Byers LA. Randomized, Double-Blind, Phase II Study of Temozolomide in Combination With Either Veliparib or Placebo in Patients With Relapsed-Sensitive or Refractory Small-Cell Lung Cancer. *J Clin Oncol* 2018; **36**: 2386-2394 [PMID: 29906251 DOI: 10.1200/JCO.2018.77.7672]
- 177 **Farago AF**, Yeap BY, Stanzione M, Hung YP, Heist RS, Marcoux JP, Zhong J, Rangachari D, Barbie DA, Phat S, Myers

- DT, Morris R, Kem M, Dubash TD, Kennedy EA, Digumarthy SR, Sequist LV, Hata AN, Maheswaran S, Haber DA, Lawrence MS, Shaw AT, Mino-Kenudson M, Dyson NJ, Drapkin BJ. Combination Olaparib and Temozolomide in Relapsed Small-Cell Lung Cancer. *Cancer Discov* 2019; **9**: 1372-1387 [PMID: [31416802](#) DOI: [10.1158/2159-8290.CD-19-0582](#)]
- 178 **Thomas A**, Vilimas R, Trindade C, Erwin-Cohen R, Roper N, Xi L, Krishnasamy V, Levy E, Mammen A, Nichols S, Chen Y, Velcheti V, Yin F, Szabo E, Pommier Y, Steinberg SM, Trepel JB, Raffeld M, Young HA, Khan J, Hewitt S, Lee JM. Durvalumab in Combination with Olaparib in Patients with Relapsed SCLC: Results from a Phase II Study. *J Thorac Oncol* 2019; **14**: 1447-1457 [PMID: [31063862](#) DOI: [10.1016/j.jtho.2019.04.026](#)]
- 179 **Sen T**, Della Corte CM, Milutinovic S, Cardnell RJ, Diao L, Ramkumar K, Gay CM, Stewart CA, Fan Y, Shen L, Hansen RJ, Strouse B, Hedrick MP, Hassig CA, Heymach JV, Wang J, Byers LA. Combination Treatment of the Oral CHK1 Inhibitor, SRA737, and Low-Dose Gemcitabine Enhances the Effect of Programmed Death Ligand 1 Blockade by Modulating the Immune Microenvironment in SCLC. *J Thorac Oncol* 2019; **14**: 2152-2163 [PMID: [31470128](#) DOI: [10.1016/j.jtho.2019.08.009](#)]
- 180 **Lallo A**, Frese KK, Morrow CJ, Sloane R, Gulati S, Schenk MW, Trapani F, Simms N, Galvin M, Brown S, Hodgkinson CL, Priest L, Hughes A, Lai Z, Cadogan E, Khandelwal G, Simpson KL, Miller C, Blackhall F, O'Connor MJ, Dive C. The Combination of the PARP Inhibitor Olaparib and the WEE1 Inhibitor AZD1775 as a New Therapeutic Option for Small Cell Lung Cancer. *Clin Cancer Res* 2018; **24**: 5153-5164 [PMID: [29941481](#) DOI: [10.1158/1078-0432.CCR-17-2805](#)]
- 181 **Ponce S**, Coté GM, Falcon A, Jimenez-Aguilar E. Efficacy and safety profile of lurbinectedin-irinotecan in patients with relapsed SCLC. Results from a phase Ib/II trial. Proceedings of the 2020 World Conference on Lung Cancer; 2021 Jan 28-31; Leeds, Singapore
- 182 **Rudin CM**, Pietanza MC, Bauer TM, Ready N, Morgensztern D, Glisson BS, Byers LA, Johnson ML, Burris HA 3rd, Robert F, Han TH, Bheddah S, Theiss N, Watson S, Mathur D, Vennapusa B, Zayed H, Lally S, Strickland DK, Govindan R, Dylla SJ, Peng SL, Spigel DR; SCRX16-001 investigators. Rovalpituzumab tesirine, a DLL3-targeted antibody-drug conjugate, in recurrent small-cell lung cancer: a first-in-human, first-in-class, open-label, phase 1 study. *Lancet Oncol* 2017; **18**: 42-51 [PMID: [27932068](#) DOI: [10.1016/S1470-2045\(16\)30565-4](#)]
- 183 **Morgensztern D**, Besse B, Greillier L, Santana-Davila R, Ready N, Hann CL, Glisson BS, Farago AF, Dowlati A, Rudin CM, Le Moulec S, Lally S, Yalamanchili S, Wolf J, Govindan R, Carbone DP. Efficacy and Safety of Rovalpituzumab Tesirine in Third-Line and Beyond Patients with DLL3-Expressing, Relapsed/Refractory Small-Cell Lung Cancer: Results From the Phase II TRINITY Study. *Clin Cancer Res* 2019; **25**: 6958-6966 [PMID: [31506387](#) DOI: [10.1158/1078-0432.CCR-19-1133](#)]
- 184 **Blackhall F**, Jao K, Greillier L, Cho BC, Penkov K, Reguart N, Majem M, Nackaerts K, Syrigos K, Hansen K, Schuette W, Cetnar J, Cappuzzo F, Okamoto I, Erman M, Langer SW, Kato T, Groen H, Sun Z, Luo Y, Tanwani P, Caffrey L, Komarnitsky P, Reinmuth N. Efficacy and Safety of Rovalpituzumab Tesirine Compared With Topotecan as Second-Line Therapy in DLL3-High SCLC: Results From the Phase 3 TAHOE Study. *J Thorac Oncol* 2021; **16**: 1547-1558 [PMID: [33607312](#) DOI: [10.1016/j.jtho.2021.02.009](#)]
- 185 **Giffin MJ**, Cooke K, Lobenhofer EK, Estrada J, Zhan J, Deegen P, Thomas M, Murawsky CM, Werner J, Liu S, Lee F, Homann O, Friedrich M, Pearson JT, Raum T, Yang Y, Caenepeel S, Stevens J, Beltran PJ, Canon J, Coxon A, Bailis JM, Hughes PE. AMG 757, a Half-Life Extended, DLL3-Targeted Bispecific T-Cell Engager, Shows High Potency and Sensitivity in Preclinical Models of Small-Cell Lung Cancer. *Clin Cancer Res* 2021; **27**: 1526-1537 [PMID: [33203642](#) DOI: [10.1158/1078-0432.CCR-20-2845](#)]
- 186 **Slotman BJ**, van Tinteren H, Praag JO, Kneijens JL, El Sharouni SY, Hatton M, Keijsers A, Faivre-Finn C, Senan S. Use of thoracic radiotherapy for extensive stage small-cell lung cancer: a phase 3 randomised controlled trial. *Lancet* 2015; **385**: 36-42 [PMID: [25230595](#) DOI: [10.1016/S0140-6736\(14\)61085-0](#)]
- 187 **Rusthoven CG**, Yamamoto M, Bernhardt D, Smith DE, Gao D, Serizawa T, Yomo S, Aiyama H, Higuchi Y, Shuto T, Akabane A, Sato Y, Niranjana A, Faramand AM, Lunsford LD, McNerney J, Tuanquin LC, Zacharia BE, Chiang V, Singh C, Yu JB, Braunstein S, Mathieu D, Touchette CJ, Lee CC, Yang HC, Aizer AA, Cagney DN, Chan MD, Kondziolka D, Bernstein K, Silverman JS, Grills IS, Siddiqui ZA, Yuan JC, Sheehan JP, Cordeiro D, Nosaki K, Seto T, Deibert CP, Verma V, Day S, Halasz LM, Warnick RE, Trifiletti DM, Palmer JD, Attia A, Li B, Cifarelli CP, Brown PD, Vargo JA, Combs SE, Kessel KA, Rieken S, Patel S, Guckenberger M, Andratschke N, Kavanagh BD, Robin TP. Evaluation of First-line Radiosurgery vs Whole-Brain Radiotherapy for Small Cell Lung Cancer Brain Metastases: The FIRE-SCLC Cohort Study. *JAMA Oncol* 2020; **6**: 1028-1037 [PMID: [32496550](#) DOI: [10.1001/jamaoncol.2020.1271](#)]



Published by **Baishideng Publishing Group Inc**
7041 Koll Center Parkway, Suite 160, Pleasanton, CA 94566, USA
Telephone: +1-925-3991568
E-mail: bpgoffice@wjgnet.com
Help Desk: <https://www.f6publishing.com/helpdesk>
<https://www.wjgnet.com>

