















A New Universal Follicular Unit Excision Classification System for Hair Transplantation Difficulty and Patient Outcome

Sanusi Umar ¹⁻³, Paul Shitabata ^{2,4}, Paul Rose ⁵, Marissa J Carter ⁶, Rattapon Thuangtong ⁷⁻⁹, Boudine Lohlun ¹⁰, Hind Benhiba ¹¹, Tayfun Oguzoglu ¹², Maria Marta Zollinger ¹³, Juan Maldonado ¹⁴, Alejandro Gonzalez ¹⁵, Myroslava Novosilska ¹⁶, Alba Gómez Zubiaur ¹⁷, Miguel Marti ¹⁸

¹Department of Medicine, Dermatology Division, University of California, Los Angeles, CA, USA; ²Division of Dermatology, Harbor-UCLA Medical Center, Torrance, CA, USA; ³Dr. U Hair and Skin Clinic, Manhattan Beach, CA, USA; ⁴Dermatopathology Institute, Torrance, CA, USA; ⁵Miami Skin and Hair Institute, Coral Gables, FL, USA; ⁶Strategic Solutions, Inc., Bozeman, MT, USA; ⁷Department of Dermatology, Faculty of Medicine, Siriraj Hospital, Bangkok, Thailand; ⁸Department of Medicine, Division of Dermatology, Mahidol University, Bangkok, Thailand; ⁹Hairderma Clinic, Bangkok, Thailand; ¹⁰HairFront Clinic, Cape Town, South Africa; ¹¹Dermatologic Private Practice, Rabat, Morocco; ¹²Dr. T Hair Transplant, Istanbul, Turkey; ¹³Instituto Capilar Marta Zollinger, Salvador, BA, Brazil; ¹⁴Hair Evolution by Robotics, Medellín, Colombia; ¹⁵Mxcapilar Clinic, Chulavista, Sonora, Mexico; ¹⁶Department of Dermatology and Oncology, Aesthetic Medical Clinic Myroslava Novosilska, Lviv, Ukraine; ¹⁷Trichology Unit, Ricart Medical Institute, Madrid, Spain; ¹⁸Dr. Marti Hair and Scalp Diseases Group, Buenos Aires, Argentina

Correspondence: Sanusi Umar, Dr. U Hair and Skin Clinic, 2121 N. Sepulveda Boulevard, Suite 200, Manhattan Beach, CA, 90266, USA, Tel +1-310-318-1500, Fax +1-310-318-1590, Email drumar@dru.com



Introduction: The difficulty of the follicular unit excision (FUE) hair transplantation procedure is currently attributed to hair curliness and subsurface angulation. Patients possessing the curliest hair shafts are considered the most challenging. Consequently, patients with these features are often denied FUE. However, this practice does not consider inpatient variation in the graft attrition rate and the rates themselves, which are frequently low in very curly hair where the skin firmness/thickness is average. To better aid practitioners in predicting FUE performance, we have developed a new scoring system (the Sanusi FUE Score Scale [SFS Scale]) based on two major donor variables (hair and skin characteristics).

Material and Method: The scale assigns scores to each of three hair subtypes (straight-wavy, curly, and coily-kinky) and each of three skin subtypes (thick/firm, soft/thin, and medium thickness/firmness). The scores were weighted based on the assessment of 13 experienced FUE practitioners from around the globe, who were asked to score each of the three skin and hair characteristics for their contribution to FUE difficulty.

Results: On the contribution of skin characteristics to FUE difficulty, 12/13 (92%) practitioners assigned the highest (most difficult) score to thick/firm skin, with medium skin thickness/firmness being the least challenging. The same percentage of practitioners gave the highest difficulty score to coiled-kinky hair subtypes regarding the contribution of hair characteristics to FUE difficulty. All agreed that straight-wavy hair presents the least challenge to FUE performance. Tallying the scores of the skin and hair variables generates a final score range of 2–9, which is associated with five grades/classes of challenge in the FUE procedure, influencing the need for a specialized skill/nuanced approach or equipment.

Conclusion: We developed a universal FUE donor scoring scale that accounts for the diversity of human hair and skin types. Further evaluation to determine the validity of this new classification system in predicting and grading FUE difficulty and patient outcomes is warranted.

Keywords: follicular unit extraction, hair transplant, scoring, scale, grading, hair type, skin type, African hair, curly hair, coiled hair, kinky hair, straight hair, wavy hair, dermis, epidermis



Plain Language Summary

A classification system is absent for predicting or grading the difficulty level of the follicular unit excision (FUE) method of hair transplantation. Practitioners have often resorted to informally qualifying candidates as either curly, Afro (difficult), or non-curly, non-Afro (easy). We developed a presurgical FUE donor scoring scale to aid in predicting FUE difficulty with implications for patient outcomes.

Introduction

The difficulty of follicular unit excision (FUE), formerly called follicular unit extraction, poses varying levels of difficulty to hair transplant practitioners.¹ This difficulty has traditionally been attributed to the degree of hair curliness. As a result, difficult FUE hair transplant donor zones exhibiting curlier hairs (eg, African hair type and body hair) are considered the most challenging to transplant.^{1–6} In the early days of FUE, a surgical scoring scale (the FOX test) required test extractions of 5–10 grafts using punches restricted to superficial dermal depths. Based on the biopsy of extracted grafts, a score of 1–5 was assigned. A score of 1 was given when all of the follicular units were extracted intact; a score of 2 reflected grafts that were extracted with most of the anatomy intact but with significant loss of the surrounding fat around the lower part of the follicle or some degree of amputation (<20%) of the lower portion of the follicle. Only patients with FOX 1–2 scores were recommended for FUE.⁷

The main factors considered relevant to the variability in graft attrition using the FUE tools of that era were the hair caliber and dermal characteristics. Nevertheless, FUE practitioners have subsequently come to associate challenging FUE donors with hair curliness,¹ especially in patients of African descent.^{2–6} However, the following observations support that the viscoelastic character of the skin (with firmness and thickness as proxies) is a significant contributor to FUE difficulty and graft attrition rate.

1. Inpatient variation in the graft attrition rate occurs in the same individual during graft extraction from the mid-posterior occipital zone compared to the mid-parietal areas, even though the hair caliber, angulation, and shape remain unchanged and the operator is using the same device.^{7–9}
2. The graft attrition rate is minimal in patients of African descent with very curly hair—those with relatively average skin thickness and firmness.
3. Graft attrition rates are very high in those with somewhat thicker, firmer scalp skin even when their hair shafts are less curly.⁸
4. Certain patients with straight hair have very high transection rates because of skin characteristics.^{7,8}

To date, no standard scoring scale predicts scalp FUE difficulty or performance; instead, scalp FUE is commonly classified as either Afro or non-Afro^{2–6} based on the assumption that Afro hair connotes increased curliness and difficulty. The result is that many patients of African descent are often denied FUE and are typically considered to have a FOX score of 4 (surrounding fat avulsed with a significant number of distal follicles amputated) or 5 (damage in virtually all of the grafts) without further evaluation.

We propose a new pre-surgical FUE donor classification system that considers both the curliness of the follicular unit and the skin characteristics in grading or predicting FUE difficulty. The Sanusi FUE Score Scale (SFS Scale) recognizes the mixture of skin and hair traits in the diversity of human scalps and their varying level of influence on FUE performance. Thus, the SFS scale potentially serves as a universal scoring system by assigning scores to recognizable skin and hair traits/parameters, each of which variably contributes to the FUE difficulty level.

Materials and Methods

Ethics Statements

All procedures performed were in accordance with the Declaration of Helsinki (as was revised in 2013). Institutional Review Board approval was not required as this report was not a prospective or systematic investigation of FUE treatment but describes general principles for routine FUE practice. All FUE patients provided written informed consent, including consent for publication, as part of receiving their clinical treatment.

The Sanusi FUE Scale

The SFS Scale assigns a difficulty score to each of the three skin subtypes (Thick/firm, soft/thin, and medium) and another to each of the three hair subtypes (straight-wavy; curly, and coily-kinky). To determine the weight of each of the variables (score) in its contribution to FUE difficulty relative to its counterparts of the same group (skin or hair type), a questionnaire ([Supplemental Table 1](#)) was given to 13 experienced FUE practitioners. The practitioners were asked to assign a score of 1–6 per variable, indicating their opinion on the degree to which that variable (hair or skin subtypes) contributes to FUE difficulty relative to the other variables in its group. The 13 FUE practitioners were drawn from across the globe. On the contribution of skin characteristics to FUE difficulty ([Supplemental Table 1](#)), 12/13 (92%) assigned the highest score to thick-firm skin. Soft-thin skin received the highest or second-highest score (11/13 [85%]). Therefore, the SFS scale assigned skin donor scores ([Table 1](#)) in the order of difficulty starting with thick/firm skin as the highest contributor, followed by soft/thin friable skin. Medium skin thickness/firmness was assigned the lowest score in the SFS based on a consensus from the survey that found it to be the least challenging FUE skin donor ([Supplemental Table 1](#)).

On hair type contribution to FUE difficulty ([Supplemental Table 1](#)); 12/13 (92%) gave the highest difficulty score to coiled-kinky hair shape (type 4). In contrast, all practitioners gave the second-highest difficulty score to the curly hair shape (type 3). The consensus was that straight-wavy hairs (types 1 and 2) present the least challenge in FUE. Thus the SFS assigned the highest score to coily-kinky hair, the second highest to the curly hair, and the least to the straight-wavy hair subtype ([Table 1](#)).

Based on the above results, a 2-tiered SFS Scale was constructed by first assigning a score of between 1 and 6 to each of the three subtypes of skin and hair ([Table 1](#)). The scores were weighted consistent with the trend established by the 13 FUE practitioner responses ([Supplemental Table 1](#)). To finally grade the donor area, the score chosen for the skin subtype (x) is added to that of the hair subtype (y) - [Table 1](#). The total score is classified/graded and interpreted using [Table 2](#), with a higher total score (range, 2–9) reflecting a more challenging FUE procedure.

Scalp Skin Firmness/Thickness Assessment

- Thick/firm: Exhibits one or more of the following ([Figure 1](#); Patients 1–4)::
 - Hair bunching/bouquet hair ([Figures 1 and 2](#)).
 - Pitting or hooding of the hair exit points ([Figures 1,2 and 3](#)).
 - Turgid, hard to pinch.
 - *Peau d'orange* appearance ([Figures 2 and 3](#)).
 - Slippery Surface (Tendency of punch to slip or bounce off the scalp skin surface).
 - Acne keloidalis nuchae ([Figure 3](#)).

Table 1 Donor Skin and Hair Type Scoring

Skin and Hair Parameters	Score	Score Selection
Skin Parameter		
Thick/ firm	6	x
Soft/thin	4	
Medium firmness/thickness	1	
Hair Parameter		
Straight-wavy (types 1 and 2a, b, and c)	1	y
Curly (types 3a, b, and c)	2	
Coiled-kinky (types 4a, 4b, and 4c)	3	
Total Score (SFS)		x+y

Abbreviations: SFS, Sanusi FUE Score; FUE, follicular unit excision.

Table 2 Interpretation of the Sanusi FUE Score Scale

SFS	SFS Grade/Class	FUE Challenge if the Procedure is Not Nuanced
2–3	I	No difficulty; very low graft attrition rate
4	II	Low-to-moderate difficulty; low-moderate graft attrition rate
5–6	III	Moderate difficulty; susceptible to decapping of the graft
7–8 (7a)*	IV	Moderate-to-high difficulty; moderate-high graft attrition rate (often in North African or Middle Eastern descent)
9	V	High difficulty; high-very high graft attrition rate (typically African descent)

Note: *7a: A combination of very soft skin and tightly curled/kinky hair shafts (rare in nature).

Abbreviations: SFS, Sanusi FUE Score; FUE, follicular unit excision.

- Resistance to punch penetration.
- Resistance to penetration of a hypodermic needle (27 gauge or less), eg, during local anesthesia injection (Figure 4).
- Soft/thin: Does not meet criteria for thick/firm skin, and exhibits two or more of the following: (Figure 5; Patient 5):
 - Punch penetration is easy with little to no resistance and a tendency to tear the top layer.
 - Tendency for decapping.
 - Very lax, folds easy when pinching.
 - Very thin/fine hair caliber ± high hair density (Figure 6).
- Medium thickness/firmness: Does not meet criteria for either thick/firm or soft/thin scalp skin. These features are typically encountered in most FUE cases (Figures 6 and 7; patients 6–8):
 - Average pinch response.
 - Average punch penetration.

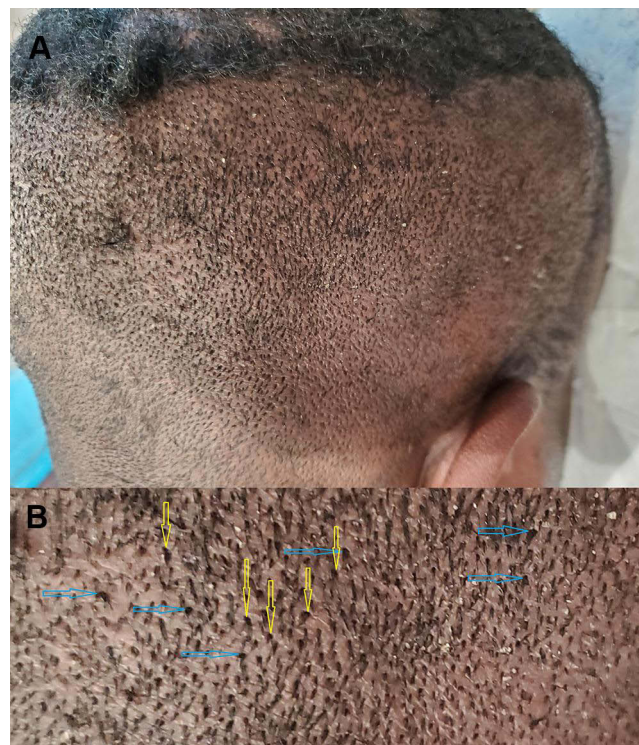


Figure 1 Example of thick/firm scalp. Patient 1 - a male patient of African descent. Right posterior oblique view of the scalp: Thick firm scalp manifesting (A) closer up view showing hair bunching/bouquet hair (yellow arrows), with hooding of hair exit points (blue arrows) (B).

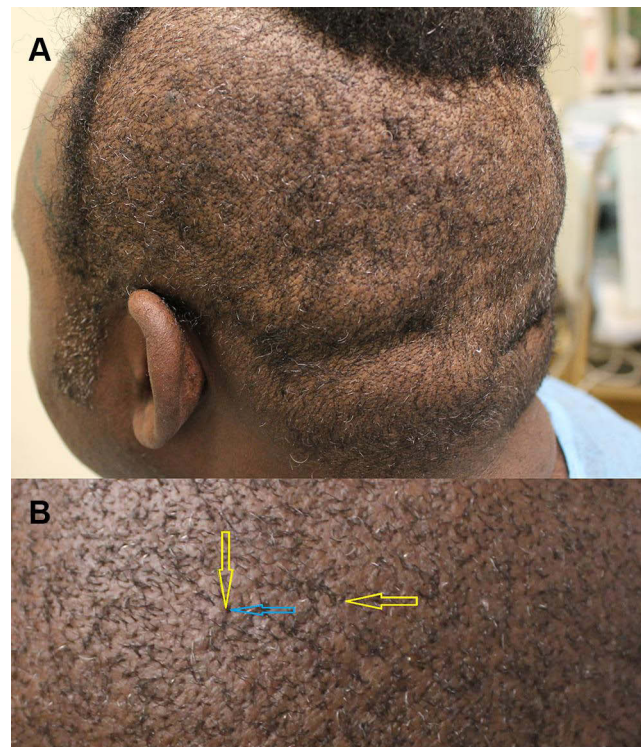


Figure 2 Example of thick/firm scalp. Patient 2 male patients of African descent. Left posterior oblique view showing thick firm scalp (**A**). Closer up view of thick firm scalp, showing peau d'Orange surface, hairs exiting from craters (pits) with hoods (yellow arrows), and bunched/bouquet hair (blue arrow). Chaotic hair directions (asynchrony) are evident (**B**).

Hair Type

Three broad subdivisions of hair shapes were used based on groupings from the widely used hair type chart (Figure 8).

- Straight-wavy hair (types 1 and 2): Hair is either straight or wavy (Figures 6, 7A, 9, and 10; Patients 6, 7 and 9), and hairs in any given anatomic portion of the scalp donor (parietal or occipital zones) follow a single pattern of hair angulation and direction that is obvious upon close shaving to 2–5 mm (Figures 6, 8 and 10B). Follicular units pursue a straight course into the skin (Figures 8 and 11).
- Curly hair (type 3): Surface hair is gently curled (Figures 8 and 12 - Patient 10). There is a clear pattern in hair direction or angulation upon shaving to 2–5 mm; the waves may show variations in general directions of groups of hairs, with minimal or no individual hair direction asynchrony (Figures 8 and 13A). Follicular units pursue a straight or very gentle curve into the skin (Figures 8 and 13B).
- Coiled-kinky hair (type 4): Surface hair grown long is substantially curly (Figures 8, 14A and B; Patient 11, and 2). There is no clear pattern of hair direction or angulation in any significant section of the scalp upon shaving to 2–5 mm (Figures 2 and 8); there is a high degree of individual hair direction asynchrony (ie, chaos in hair direction). Upon shaving to 2–5 mm, the hair tip may exit the skin at an acute angle, or abut the skin or indent the skin (Figures 2 and 8). Follicular units pursue a curved course into the skin (Figures 8, 15A and B).

Of note, in many patients, the nape area, when compared with the rest of the scalp, typically show fewer curly hairs, more synchrony in the direction of flow upon shaving (Figure 16A), and grafts that pursue a straighter course into the skin. (Figure 16B).

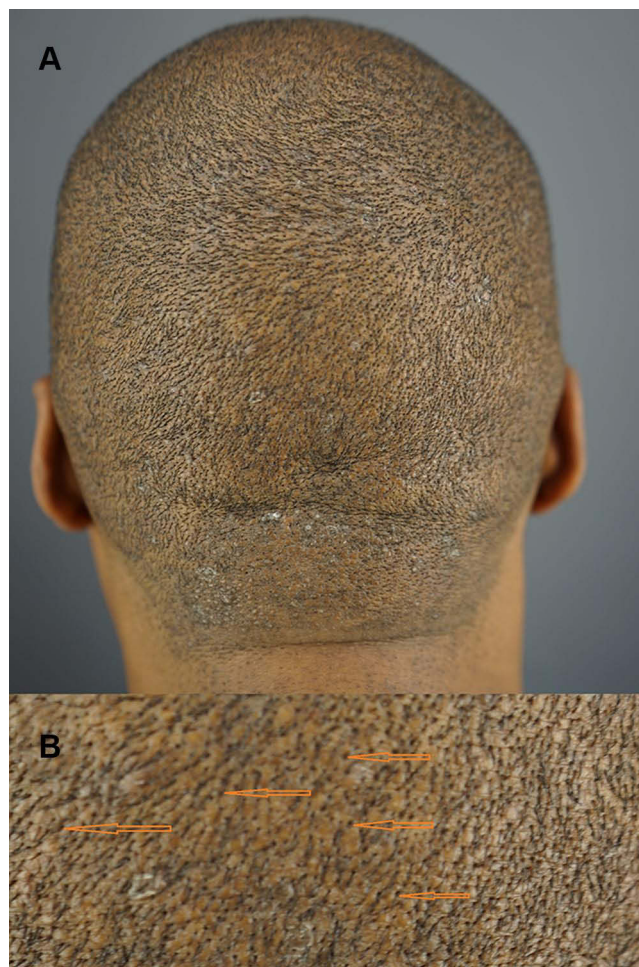


Figure 3 Example of thick/firm scalp. Patient 3 male patients of African descent. Posterior view of the scalp. Manifests features of thick-firm scalp with peau d'Orange surface and acne keloidalis nuchae – like papules in the nape area (A): close up view of a thick firm scalp showing a peau d'Orange surface with recessed (pitted) hair exit points (orange arrows) (B).

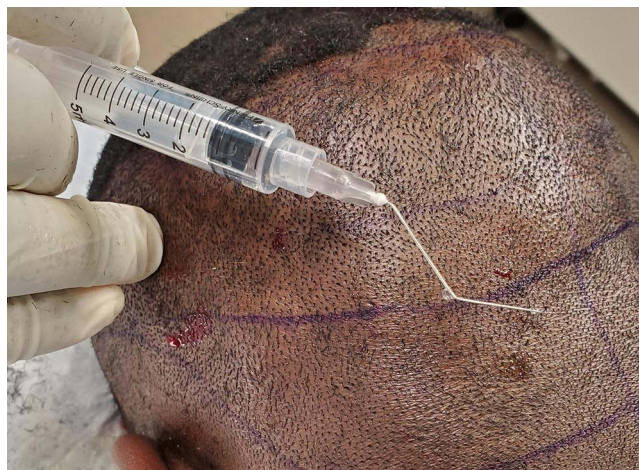

Figure 4 Example of thick/firm scalp. Patient 4 male patients of African descent. Left posterior oblique view showing thick firm scalp manifested by difficulty in penetrating scalp with a 27-gauge hypodermic needle that is bent during anesthesia injection.

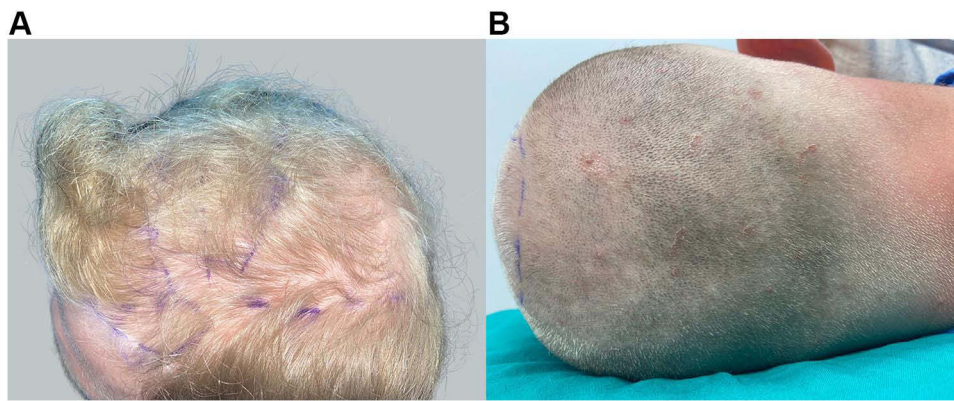


Figure 5 Example of soft/thin scalps. Top view of patient 5 (man of North European descent) possessing soft/thin scalp, showing fine hair (A). Posterior view of patient 5, after shaving in preparation for FUE, manifesting high hair density (B).




Figure 6 Close-up view of the right parietal scalp after shaving depicting medium thickness-firmness scalps with straight hair types. Patient #6 - Hispanic (A); patient #7 European descent (B): Both show an absence of bunched/bouquet hair, pea d'Orange, and pitting/hooding. Also shows uniform hair direction/flow.

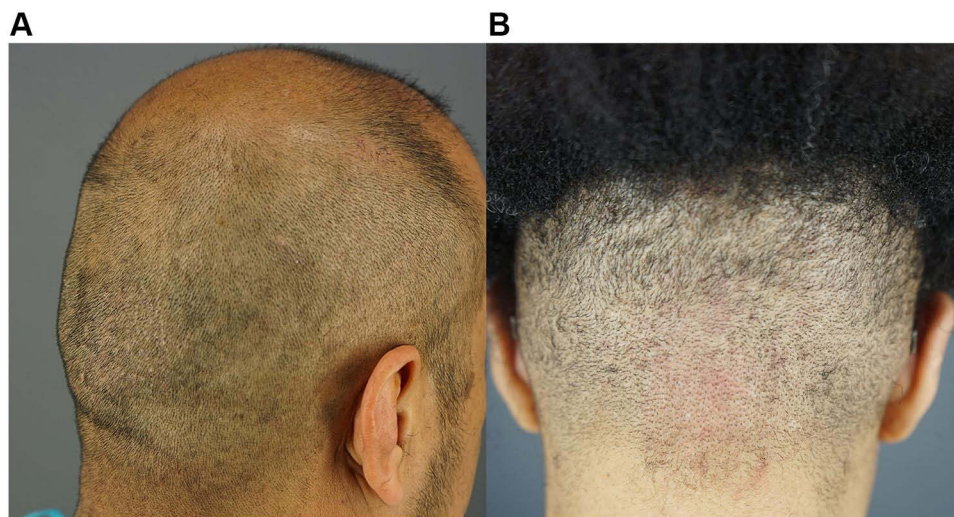


Figure 7 Examples of medium thickness/firmness scalps. Right posterior oblique view of patient 6 (Hispanic man) with medium scalp thickness/firmness (A). Posterior view of patient 8 (woman of African descent) with medium scalp thickness/firmness and curly hair (B).

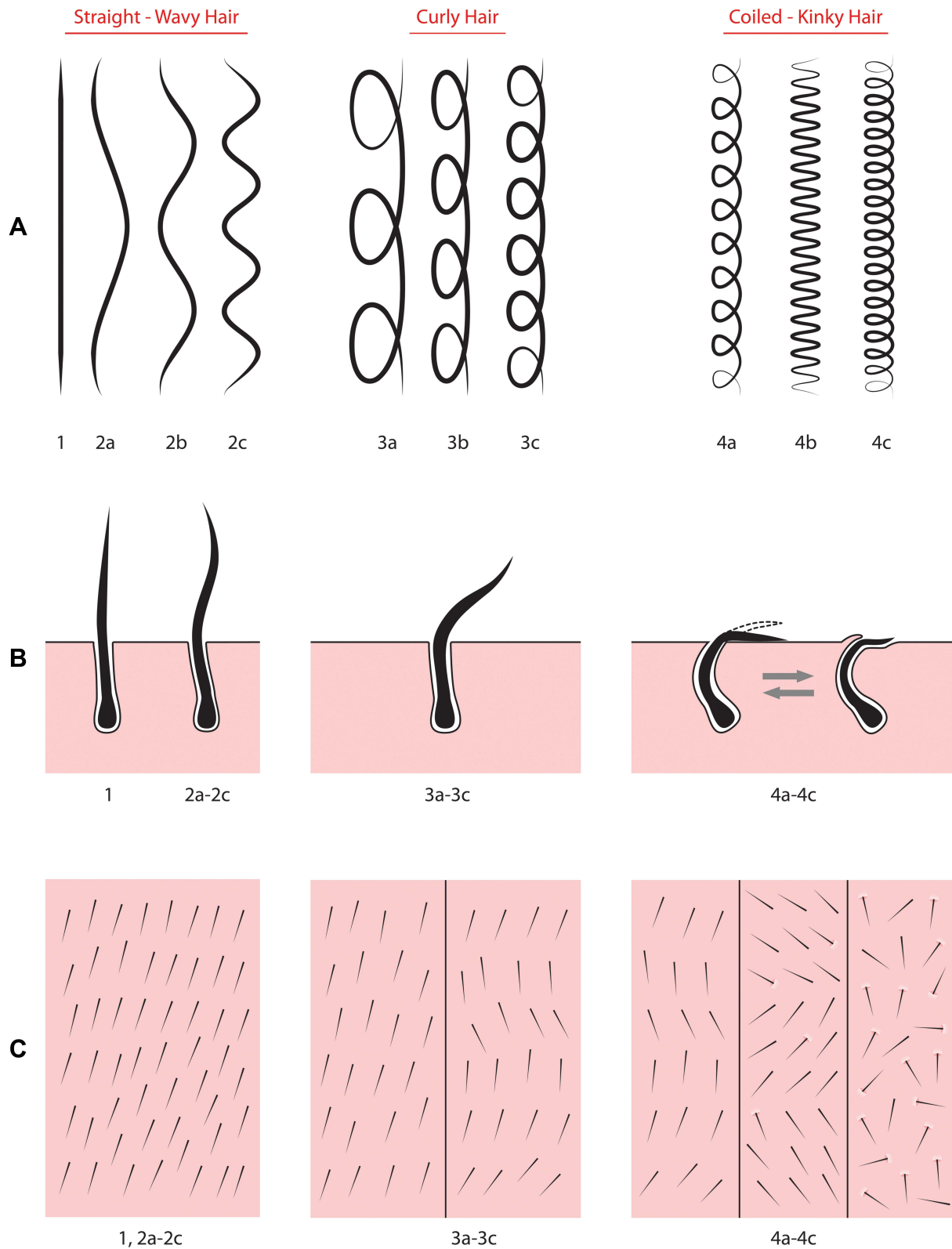


Figure 8 Drawing showing the different hair types by long hair shafts (row **A**), the subcutaneous shapes of follicular units (row **B**), and appearance from the surface after shaving to 2–3 mm (row **C**).

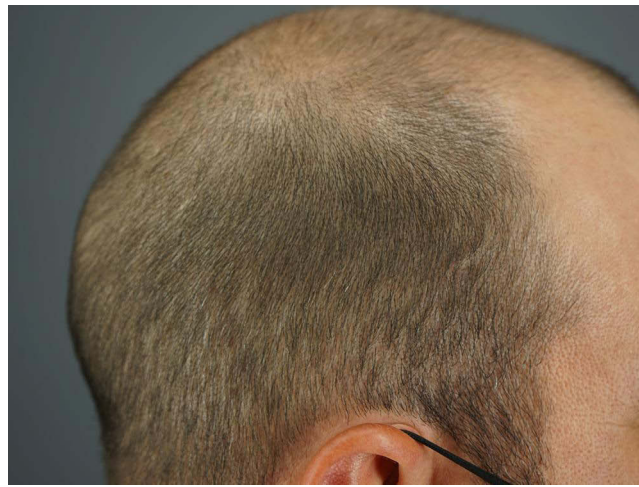

Figure 9 Examples of medium thickness/firmness and straight hair type. The right scalp of patient 7 (Caucasian man) with medium scalp thickness/firmness before his head shaving showing straight hair.

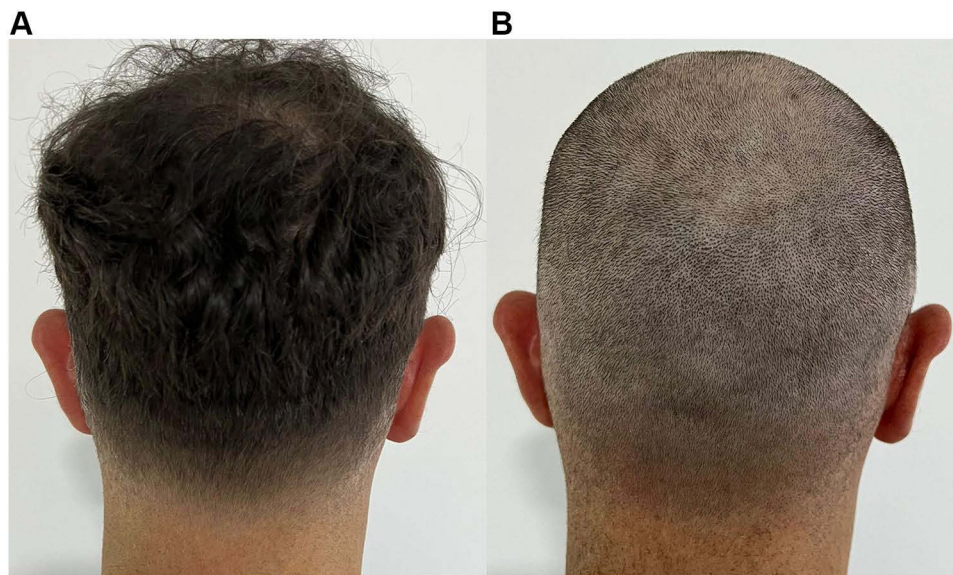


Figure 10 Photographs of patient 9 showing the back of his head before shaving (A) and after shaving, which shows thick, uniform hair flow (B).

Results

When individual scores are computed using the SFS Scale (Table 1), the difficulty and challenges posed by the FUE donor can be better established (Table 2). Five classes or grades emerged from an ascending score. The least challenging FUE scenario was an SFS score of 2 or 3 (SFS Class I), achieved when straight/wavy or gently curled hair combines with medium skin thickness/firmness. An SFS Scale score of 4 (SFS Class II) includes a combination of coiled-kinky hair with medium-thick/firm skin to indicate a low-to-moderate FUE difficulty. An SFS Scale score of 5 or 6 (SFS Class III) represents a combination of either straight/wavy hair or gently curled hair with soft/thin skin, suggesting a moderate challenge to FUE due to an increased tendency for decapping and transection of grafts. An SFS Scale score of 7 or 8 (SFS Class IV) includes either straight/wavy hair or gently curled hair with a thick/firm scalp skin, indicating a moderate-to-high FUE challenge, with a subvariant score (7a) that combines soft, thin skin with coiled-kinky hair that is considered an atypical combination. Finally, the highest score of 9 (SFS Class V) includes coiled-kinky hair and a thick/firm scalp, which predicts the highest FUE challenge, resulting in very high graft attrition rates unless specialized equipment or skillsets are implemented.



Figure 11 Extracted grafts derived from a straight-haired patient.

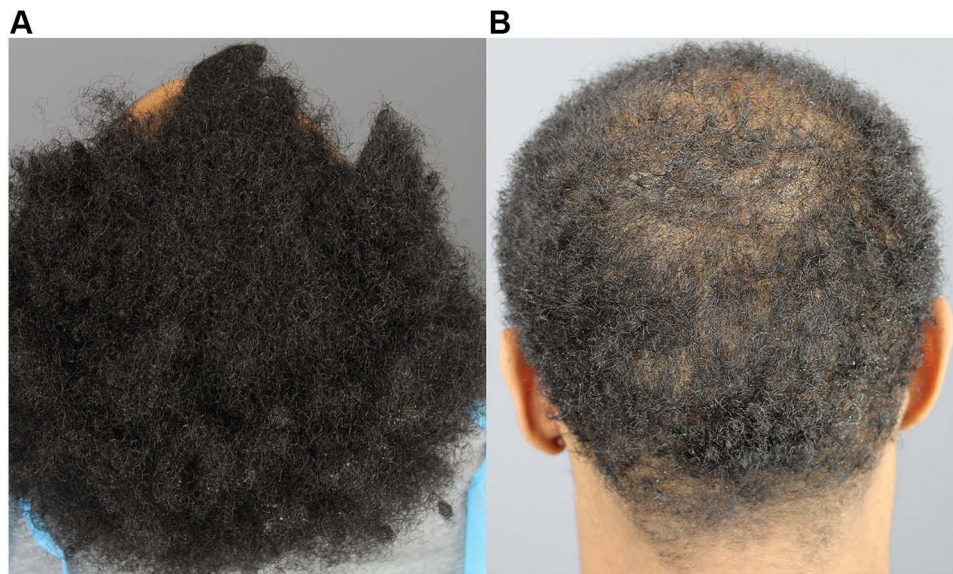

Figure 12 Photographs of patient 10 with type 3 hair grown out long (A) and cut shorter (B).

Discussion

Evolutionary changes in human hair and skin phenotypes have occurred over hundreds of thousands of years, primarily to enable adaptations to local geographic environments.^{10,11} Thus, specific racial groups/geographic demographics appear to have a preponderance of particular hair types. For example, Africans have the curliest hair, Northern Europeans have straight thin hair, and Asians have straight, thick hair). For skin phenotypes, Africans generally have the firmest and thickest dermis, whereas Northern Europeans have the softest/thinnest dermis.^{12–14} These adaptations have occurred primarily to temperature and ultraviolet exposure levels.^{10,11} If humans had remained isolated in the regions in which they evolved, a classification system based on race and geographic location would have seemed rational. However, given that the history of human population dynamics involved constant movement and intermingling of genes as the norm

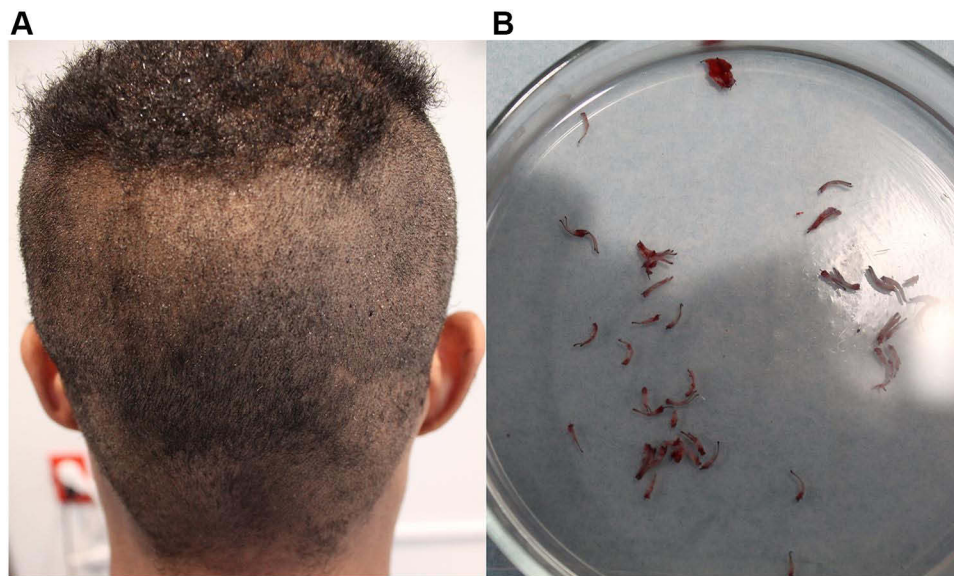


Figure 13 Posterior view of patient 10 after shaving with a guardless caliber shows a discernible hair flow direction but with varying synchronized directions (A). His grafts show a mix of straight and gently curved grafts (B).

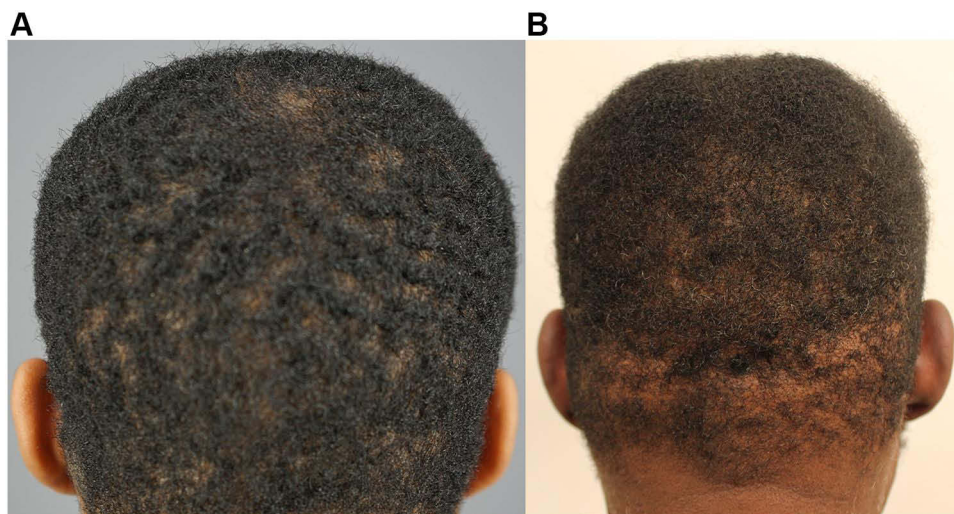


Figure 14 Posterior views of the scalps of patient 11 (A) and patient 2 (B) before shaving showing types 4a–b and 4c hair types, respectively.

rather than the exception, it is not surprising that the mixing of hair and skin traits has taken on a mixed dimension.^{10,11} Even societies presently perceived as “homogeneous” result from the complete blending of a diversity of phenotypic traits that were once disparate in the past. As humans have become increasingly mobile thanks to advancements in travel technology of the past 200 years, this level and rate of admixing have significantly increased.

Studies have shown that race correlates with structural changes in the stratum corneum of the epidermis, and the dermis could affect FUE dynamics. For instance, the finding that African skin, on average, possesses a more compact stratum corneum than Caucasian skin,^{12–14} may have implications on the amount of resistance to the skin-piercing power of the FUE punch, as well as its ability to penetrate the skin rather than bounce off a more slippery surface. This finding is consistent with our histological analysis of transected graft elements of a patient of African descent (Patient #13) who had a lower transection rate in FUE performed in the mid-occipital zone compared with transection rates in the parietal

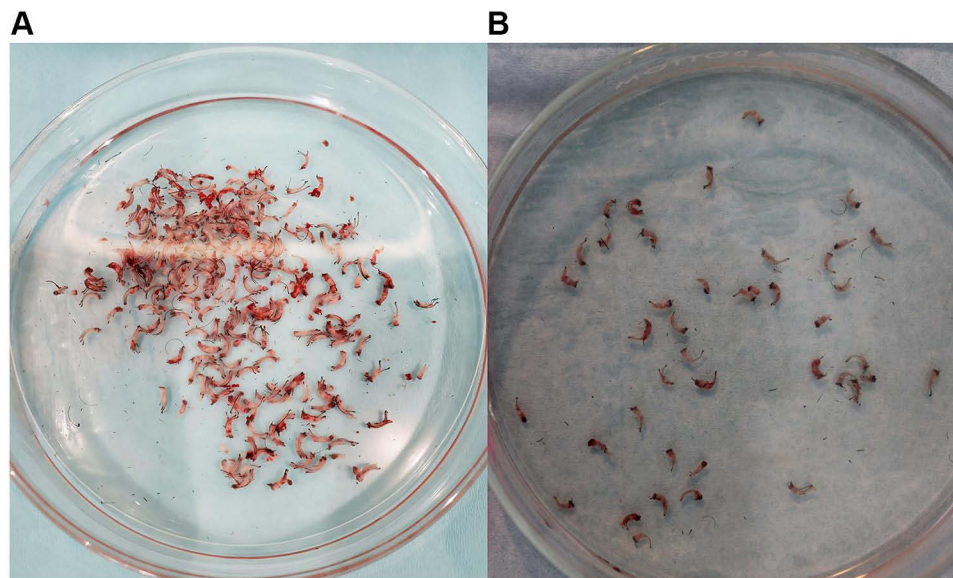


Figure 15 Grafts derived from patient 11 show varying curliness degrees (no straight grafts are seen) (A). Grafts derived from patient 2 are all curled or tightly curled (B).




Figure 16 Photograph of the back of the head of patient 12 (African descent) showing short hair with directional synchrony in the nape area (A). The grafts are straight (B).

area that resulted from the same practitioner using the same instrumentation and technique. The histology showed that the epidermal component of the transected graft debris in the parietal area was twice as thick as the epidermis of the transected graft in the occipital zone. Additionally, the epidermis in the parietal region showed more compact orthokeratosis in the stratum corneum than in the occipital zone (Figure 17A and B).

In the dermis, studies have shown that facial dermal tissue is thicker in Africans than in Caucasians.^{15,16} The papillary dermis of Africans is not as clearly delineated from the reticular dermis; it possesses smaller but more closely packed, better-aligned collagen fibers; the interstices contain more widespread glycoprotein ground substance and show the presence of collagen fiber fragments interspersing the ground substance throughout the dermis compared to white skin. In addition, there is less elastic tissue anchoring the hair follicles. However, black skin has more oxytalan and elaunin, specifically on the scalp. This has led to speculation that the collagen-ground substance interaction is likely a significant

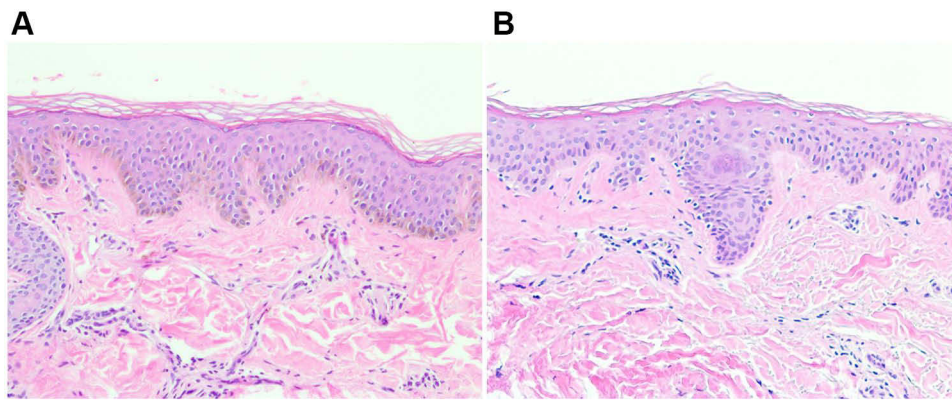


Figure 17 Hematoxylin and eosin stain ($\times 10$ magnification) of the scalp of patient 13 (African descent) showing normal orthokeratosis in the occipital area (A) compared with compact orthokeratosis of a thicker epidermis in the parietal scalp (B).

factor explaining the higher firmness/turgor of black skin relative to white skin, with implications for FUE punch dynamics. These findings correlate well with anecdotal scalp biopsy observations of a preponderance of thicker dermal sheaths surrounding hair follicles and less elastic fibers in patients that are more likely to have higher FUE graft transection rates when compared to those with lower transection rates.⁷ This is consistent with histological findings of transected graft debris of patient #13, whose FUE in the parietal zone had a higher transection rate, with a significantly thicker perifollicular fibroblast sheath than the occipital zone grafts (Figure 18A and B). The importance of dermal fibroblasts in influencing structures of the epidermis and hair follicles has been established.¹⁷ Thus, the correlation between perifollicular and dermal fibroblasts and FUE difficulty via the effect of hair curliness and epidermal characteristics may be areas worth studying in the future.

Generally, the curlier a hair shaft is, the more it is associated with a firmer/thicker skin. Conversely, straighter hairs are associated with thin-to-medium skin thickness and firmness. Although many skin and hair types have initially evolved in different parts of the world as an adaptive measure to protect the individual against environmental factors (eg, sun exposure, temperature),^{10,11} hybridizations from migration over thousands of years have caused heterogeneity from the mixing of these characteristics and traits. The result is the presentation of hair and skin phenotypes that may no longer reflect particular geographic localizations or ethnic stereotypes. Our scoring system accounts for this. For example, patient #8 (Figure 4B), although of African descent, combined a coily hair (SFS 1) that is typical of African heritage with a medium thickness/firmness (SFS 3) scalp skin that is typically associated with other Caucasian/Asian demographics. Consequently, instead of being classified by tradition into “challenging FUE,” a total SFS score of 4 (SFS Class II) more objectively predicts a low to moderate FUE difficulty. In contrast, Patient #1, another African American with coily hair

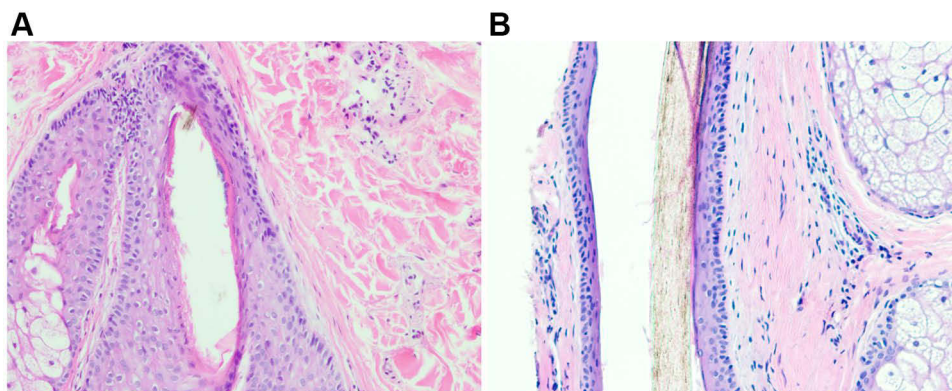


Figure 18 Hematoxylin and eosin stain ($\times 10$ magnification) of the scalp of patient 13 (African descent) showing perifollicular fibroblast arrangement in the occipital area, which is thin (A), compared with a thicker appearance in the parietal region (B).

(SFS 3) and Thick/frim scalp (SFS 6), returns a total SFS score of 9 (SFS Class V), predicting high FUE difficulty, which calls for the use of specialized techniques and skills.

Additionally, the SFS scoring is adaptable to the observation by many FUE practitioners of variations in scalp skin characteristics between genders and changes that occur with age, whereby the skin in the lower scalp areas becomes softer with age. Consequently, the SFS Classification of the individual may change with time.

Another source of validation for recognizing both hair curliness and skin characteristics in assessing FUE performance is FUE instrumentation. Previously, FUE device designs did not consider the contribution of skin characteristics and performed inconsistently across varying FUE scenarios (eg, various degrees of hair curliness, race, body, and head hair locations). Some devices perform excellently in one type of harvest but not in others.^{4,18,19} Therefore, practitioners often acquire various devices hoping that one of them might suit the diversity of patients they encounter since no single device suits all situations.¹⁸ Relatedly, some practitioners have advocated specialized skills for using conventional FUE tools to address some challenging FUE scenarios.¹ We recently published details of a single FUE device employing a single punch design and punch driver that performed across all FUE scenarios based on its ability to compensate for subsurface hair shaft curl variations and its adaptability to changing skin thickness and firmness.⁸

Although our proposed scoring scale specifically applies to scalp FUE procedures, it may apply to beard and body hair FUE. The SFS classification system for FUE difficulty awaits validation, including its ability to predict patient outcomes.

Conclusions

In summary we developed a universal FUE donor scoring scale that accounts for the diversity of human hair and skin types. Further evaluation to determine the validity of this new classification system in predicting and grading FUE difficulty and patient outcomes is warranted.

Data Sharing Statement

In addition to photographs and data that appear in the manuscript, complete medical records of the patients are stored in the treating clinics, in line with the standard of care.

Ethics Approval and Informed Consent

All procedures were in accordance with the Declaration of Helsinki (as was revised in 2013). Institutional Review Board approval was not required as this report was not a prospective or systematic investigation of FUE treatment but described general principles for routine FUE practice. All FUE patients provided written informed consent, including consent for publication, as part of receiving their clinical treatment.

Acknowledgments

We are grateful to our patients and those who participated in our hair transplantation work.

Funding

This study received no funding.

Disclosure

Dr. Umar owns shares, patents, and patent applications covering FUE technology issued to Dr. U Devices Inc and reports no other potential conflicts of interest for this work. Dr Marissa J Carter reports personal fees from Dr. U Hair and Skin Clinic, outside the submitted work. Dr Rattapon Thuangtong received fees for product advisory from L'oreal company, during the conduct of the study; for product advisory from L'oreal, outside the submitted work. The remaining authors have no conflicts of interest for this work to declare.

References

1. Rose PT, Canales M, Zontos G. Internal angle of hair growth versus the exit angle as it relates to FUE/FIT. *Hair Trans Forum Int.* 2017;27:1.
2. Rogers NE, Callender VD. Advances and challenges in hair restoration of curly Afrocentric hair. *Dermatol Clin.* 2014;32:163–171. doi:10.1016/j.det.2013.12.004
3. Singh MK, Avram MR. Technical considerations for follicular unit extraction in African-American hair. *Dermatol Surg.* 2013;39:1282–1824. doi:10.1111/dsu.12229
4. Umar S. Comparative study of a novel tool for follicular unit extraction for individuals with Afro-textured hair. *Plast Reconstr Surg Glob Open.* 2016;4:e1069. doi:10.1097/GOX.0000000000001069
5. Rose PT. Hair restoration surgery: challenges and solutions. *Clin Cosmet Investig Dermatol.* 2015;8:361–370. doi:10.2147/CCID.S53980
6. Saxena K, Savant SS. Body to scalp: evolving trends in body hair transplantation. *Indian Dermatol Online J.* 2017;8:167–175. doi:10.4103/idoj.IDOJ_283_16
7. Rassman WR, Bernstein RM, McClellan R, Jones R, Worton E, Uyttendaele H. Follicular unit extraction: minimally invasive surgery for hair transplantation. *Dermatol Surg.* 2002;28:720–728. doi:10.1046/j.1524-4725.2002.01320.x
8. Umar S, Lohlun B, Ogozugu T, Carter MJ. A novel follicular unit excision device for all-purpose hair graft harvesting. *Clin Cosmet Investig Dermatol.* 2021;14:1657–1674. doi:10.2147/CCID.S33353
9. Mohmand MH, Ahmad M. Transection rate at different areas of scalp during follicular unit extraction/excision (FUE). *J Cosmet Dermatol.* 2020;19:1705–1708. doi:10.1111/jocd.13191
10. Genes and me, Hair curl [website]. GB HealthWatch; 2022. Available from: <https://www.gbhealthwatch.com/Trait-Hair-Curl.php>. Accessed April 8, 2022.
11. Westgate GE, Botchkareva NV, Tobin DJ. The biology of hair diversity. *Int J Cosmet Sci.* 2013;35:329–336. doi:10.1111/ics.12041
12. Schillica H. *(De)Tangled: An Exploration of the Hierarchies in the Natural Hair Community* [thesis]. Georgia State University; 2015.
13. Weigand DA, Haygood C, Gaylor JR. Cell layers and density of Negro and Caucasian stratum corneum. *J Invest Dermatol.* 1974;62:563–568. doi:10.1111/1523-1747.ep12679412
14. Richards GM, Oresajo CO, Halder RM. Structure and function of ethnic skin and hair. *Dermatol Clin.* 2003;21:595–600. doi:10.1016/S0733-8635(03)00081-0
15. Montagna W, Protta G, Kenney JA. The structure of black skin. In: *Black Skin Structure and Function*. San Diego: Academic Press. 1993:37–49.
16. Montagna W, Carlisle K. The architecture of black and white facial skin. *J Am Acad Dermatol.* 1991;24:929–937. doi:10.1016/0190-9622(91)70148-U
17. Rinn JL, Wang JK, Liu H, Montgomery K, van de Rijn M, Chang HY. A systems biology approach to anatomic diversity of skin. *J Invest Dermatol.* 2008;128:776–782. doi:10.1038/sj.jid.5700986
18. Gupta AK, Bruce A, Trivellini R, et al. Innovations hair restoration surgeons have made to adapt to the challenges of follicular unit excision. *J Cosmet Dermatol.* 2020;19:1883–1891. doi:10.1111/jocd.13506
19. Gupta AK, Love RP, True RH, Harris JA. Follicular unit excision punches and devices. *Dermatol Surg.* 2020;46:1705–1711. doi:10.1097/DSS.0000000000002490

Clinical, Cosmetic and Investigational Dermatology

Dovepress

Publish your work in this journal

Clinical, Cosmetic and Investigational Dermatology is an international, peer-reviewed, open access, online journal that focuses on the latest clinical and experimental research in all aspects of skin disease and cosmetic interventions. This journal is indexed on CAS. The manuscript management system is completely online and includes a very quick and fair peer-review system, which is all easy to use. Visit <http://www.dovepress.com/testimonials.php> to read real quotes from published authors.

Submit your manuscript here: <https://www.dovepress.com/clinical-cosmetic-and-investigational-dermatology-journal>