

Toripalimab combined with targeted therapy and chemotherapy achieves pathologic complete response in gastric carcinoma: A case report

Rui Liu, Xia Wang, Zhi Ji, Ting Deng, Hong-Li Li, Yan-Hui Zhang, Yu-Chong Yang, Shao-Hua Ge, Le Zhang, Ming Bai, Tao Ning, Yi Ba

Specialty type: Medicine, research and experimental

Provenance and peer review:

Unsolicited article; Externally peer reviewed.

Peer-review model: Single blind

Peer-review report's scientific quality classification

Grade A (Excellent): 0
Grade B (Very good): 0
Grade C (Good): C, C
Grade D (Fair): 0
Grade E (Poor): E

P-Reviewer: Arigami T, Japan; Lal A, United States; Marickar F, India

Received: November 5, 2021

Peer-review started: November 5, 2021

First decision: February 14, 2022

Revised: February 28, 2022

Accepted: April 22, 2022

Article in press: April 22, 2022

Published online: June 26, 2022



Rui Liu, Xia Wang, Zhi Ji, Ting Deng, Hong-Li Li, Yan-Hui Zhang, Yu-Chong Yang, Shao-Hua Ge, Le Zhang, Ming Bai, Tao Ning, Yi Ba, National Clinical Research Center for Cancer, Key Laboratory of Cancer Prevention and Therapy, Tianjin's Clinical Research Center for Cancer, Tianjin Medical University Cancer Institute and Hospital, Tianjin 300000, China

Corresponding author: Rui Liu, Doctor, Chief Doctor, National Clinical Research Center for Cancer, Key Laboratory of Cancer Prevention and Therapy, Tianjin's Clinical Research Center for Cancer, Tianjin Medical University Cancer Institute and Hospital, North Huanhu West Road, Sports Institute, Hexi District, Tianjin 300000, China. ruiliu688@126.com

Abstract

BACKGROUND

Neoadjuvant or perioperative chemotherapy combined with surgery can reduce postoperative recurrence and improve the long-term survival rate of patients with locally advanced resectable gastric carcinoma. Nivolumab combined with chemotherapy has been recommended by the National Comprehensive Cancer Network guidelines as a first-line therapy for advanced gastric carcinoma/adenocarcinoma of the gastroesophageal junction and serves as the basis for immunotherapy combined with chemotherapy to become a neoadjuvant therapy. Herein, we report a case in which pathologic complete response was achieved by neoadjuvant administration of toripalimab, Herceptin, and docetaxel, oxaliplatin, calcium folinate, and fluorouracil (FLOT) chemotherapy followed by surgery for human epidermal growth factor receptor 2 (HER2)- and programmed death-ligand 1 (PD-L1)-positive locally advanced gastric carcinoma. We hope that this case will shed some light on neoadjuvant therapy for gastric carcinoma.

CASE SUMMARY

The patient was diagnosed with locally advanced adenocarcinoma of the cardia. Immunohistochemistry of the baseline tissues suggested that the tissues were HER2- (fluorescent *in situ* hybridization) and PD-L1-positive (combined positive score = 1). The patient underwent surgery following a four-cycle neoadjuvant therapy comprising Herceptin, toripalimab, and FLOT chemotherapy. The postoperative pathological findings showed mild atypical hyperplasia of the local glands with chronic mucosal inflammation (proximal stomach), no clear residual tumor (tumor regression grade 0), no regional lymph node metastasis, and

negative upper and lower cut ends. The levels of tumor markers were reduced to normal levels after re-examination. With good postoperative recovery, the four-cycle preoperative chemotherapy was continued at the same dosage as that previously administered. After the treatment, the patient was monitored every 3 mo with a follow-up of 12 mo (4 times). As of February 27, 2022, he was in a good condition without disease progression. The clinical trial registration number is E2019401.

CONCLUSION

There are many ongoing studies on neoadjuvant immunotherapy combined with chemotherapy or radiotherapy; however, most of these studies are phase II studies with small cohorts. According to the results of some current studies, these combined regimens have shown promising results in terms of efficacy and safety. However, the clinical efficacy and safety of the neoadjuvant therapies used in these combined regimens need to be confirmed by additional prospective phase III clinical trials, and further exploration of molecular markers for effective populations is required.

Key Words: Toripalimab; Targeted therapy; Chemotherapy; Perioperative management; Gastric carcinoma; Case report

©The Author(s) 2022. Published by Baishideng Publishing Group Inc. All rights reserved.

Core Tip: We report a case in which pathologic complete response was achieved by neoadjuvant administration of toripalimab, Herceptin, and docetaxel, oxaliplatin, calcium folinate, and fluorouracil chemotherapy followed by surgery for human epidermal growth factor receptor 2- and programmed death-ligand 1-positive locally advanced gastric carcinoma. We hope that this case will shed some light on neoadjuvant therapy for gastric carcinoma.

Citation: Liu R, Wang X, Ji Z, Deng T, Li HL, Zhang YH, Yang YC, Ge SH, Zhang L, Bai M, Ning T, Ba Y. Toripalimab combined with targeted therapy and chemotherapy achieves pathologic complete response in gastric carcinoma: A case report. *World J Clin Cases* 2022; 10(18): 6184-6191

URL: <https://www.wjgnet.com/2307-8960/full/v10/i18/6184.htm>

DOI: <https://dx.doi.org/10.12998/wjcc.v10.i18.6184>

INTRODUCTION

Gastric carcinoma has a high incidence in China. Surgery might be a radical cure for gastric carcinoma; however, it is limited to only early-stage gastric carcinoma (stage I). The 5-year survival rate of patients with locally advanced gastric carcinoma (late stage) is 30%–50% [1], even with an extended area of resection and lymph node dissection. Many studies have confirmed that the combination of adjuvant/neoadjuvant chemotherapy/chemoradiotherapy can improve patients' prognosis, enhance R0 resection rates, reduce distant metastases and recurrence rates, and improve survival rates through tumor downstaging [2-4]. In the European randomized controlled phase III AIO-fluorouracil (FLOT)-4 trial, resectable gastric carcinoma patients received either the FLOT (docetaxel, oxaliplatin, calcium folinate, and fluorouracil) or epirubicin, cisplatin, and fluorouracil (ECF) regimen before and after surgery. The results showed that the FLOT regimen had better efficacy, higher R0 resection rate, better disease-free survival (DFS), and better overall survival (OS) than the ECF regimen, which laid the foundation for the FLOT regimen to become a new standard perioperative therapy for advanced gastric carcinoma. Therefore, a regimen that combines surgery with neoadjuvant or perioperative chemotherapy has been recommended by the guidelines of the Chinese Society of Clinical Oncology, the European Society for Medical Oncology, and the National Comprehensive Cancer Network (NCCN).

The KEYNOTE-059 [5] and ATTRACTION-02 [6] trials have suggested that programmed death-1 (PD-1) inhibitors are effective for advanced gastric carcinoma/adenocarcinoma of the gastroesophageal junction. The United States Food and Drug Administration (FDA) and the National Medical Products Administration have approved the indications for pembrolizumab in patients with a programmed death-ligand 1 (PD-L1) combined positive score (CPS) ≥ 1 and nivolumab in the third-line and posterior-line treatment of advanced gastric carcinoma. The CheckMate-649 [7] and ATTRACTION-04 [8] trials have revealed that nivolumab plus chemotherapy has significantly better efficacy than chemotherapy alone in the first-line treatment of advanced gastric carcinoma/adenocarcinoma. In China, as the first approved immunotherapy targeting PD-1, toripalimab (JS001) induces the endocytosis of PD-1, reduces the expression of PD-1 on the membrane surface, and relieves the immunosuppression of T cells, thereby achieving strong antitumor effects. In 2020, the American Society of Clinical Oncology reported

the clinical response and biomarker analysis of first-line toripalimab combined with standard chemotherapy for solid tumors in a phase II cohort study[9]. The study found that the objective response rate (ORR) was 54.5%, the disease control rate was 84.8%, and the duration of response was 8.3 mo. Moreover, in the randomized controlled phase III KEYNOTE-585[10] trial, which is currently enrolling patients, therapy-naïve patients with locally advanced gastric carcinoma/adenocarcinoma of the gastroesophageal junction in the experimental group will receive pembrolizumab combined with neoadjuvant chemotherapy before surgery and pembrolizumab combined with adjuvant chemotherapy after surgery, whereas those in the control group will receive placebo combined with chemotherapy.

Human epidermal growth factor receptor 2 (HER2), also known as erythroblastic oncogene B2 (ERBB2), is a proto-oncogenic protein encoded by the *ERBB2* gene on human chromosome 17. Tyrosine kinase receptor that binds to the membrane is a protein product of this gene. This receptor can promote cell proliferation and inhibit apoptosis, leading to neoplasm formation[11]. *HER2* overexpression or amplification is found in 13%–22% of patients with gastric carcinoma or adenocarcinoma of the esophagogastric junction[12]. Immunohistochemistry (IHC) staining and fluorescent *in situ* hybridization (FISH) are recommended by the guidelines for the detection of *HER2* overexpression in patients with advanced gastric adenocarcinoma. In 2010, trastuzumab was approved by the FDA as a first-line drug in combination chemotherapy for *HER2*-positive gastric carcinoma. In another study[13], preliminary results were obtained for combined immunotherapy, trastuzumab, and chemotherapy for gastric carcinoma/esophageal cancer/adenocarcinoma of the esophagogastric junction. The study found that the 6-mo progression-free survival (PFS) rate was 75%, the ORR was 91%, the median PFS was 13 mo, and the median OS was 27.3 mo. The above data were better than the previous data for *HER2*-positive advanced gastric carcinoma.

In this study, we report a case in which pathologic complete response (pCR) was achieved by neoadjuvant toripalimab, Herceptin, and FLOT chemotherapy followed by surgery for *HER2*- and PD-L1-positive locally advanced gastric carcinoma. We hope to provide more evidence for neoadjuvant therapies in gastric carcinoma patients by reporting this case.

CASE PRESENTATION

Chief complaints

A 63-year-old male patient experienced dysphagia, poor appetite, night sweats, and fatigue on July 2, 2020, and sought medical attention at the Hulunbuir People's Hospital in Inner Mongolia, China.

History of present illness

On July 22, 2020, gastroscopy revealed protuberant lesions in the cardia and fundus; bite biopsy revealed adenocarcinoma of the cardia (Figure 1A); IHC revealed *HER2* positivity (2+, FISH was recommended); *in situ* hybridization revealed *EBER* (–); and FISH revealed *HER2* positivity (Figure 1B).

History of past illness

The patient has been suffering from hepatitis B virus (HBV) infection for more than 30 years, without history of hypertension, coronary heart disease, diabetes, or tuberculosis.

Personal and family history

The patient's family history is not applicable.

Physical examination

The tissues obtained from the bite biopsy were tested for PD-1, revealing CPS positivity (CPS = 1) (Figure 1C) and TPS negativity.

Laboratory examinations

On July 22, 2020, gastroscopy revealed protuberant lesions in the cardia and fundus; bite biopsy revealed adenocarcinoma of the cardia; IHC revealed *HER2* positivity (2+, FISH was recommended); *in situ* hybridization revealed *EBER* (–); and FISH revealed *HER2* positivity. Next-generation sequencing (NGS) revealed tumor protein p53 (*TP53*) c.329G>C p.Arg110Pro (abundance 33.82%), and *ERBB2* copy number amplification ($n = 4.5$).

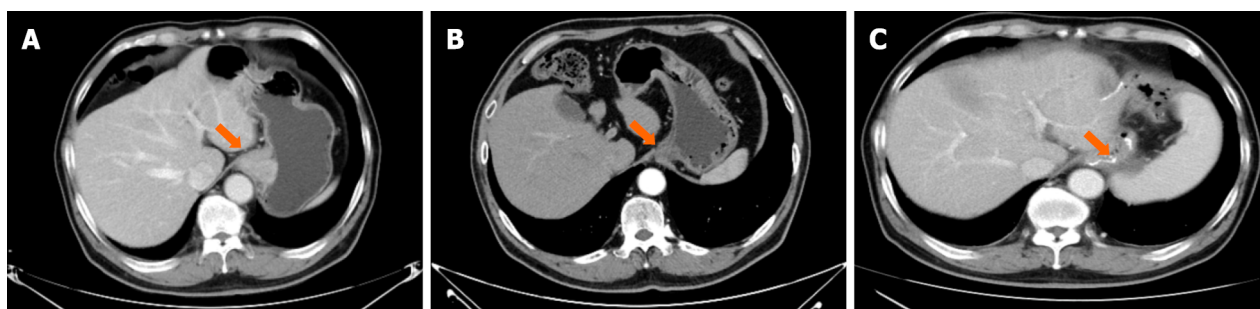
Imaging examinations

On July 30, 2020, a computed tomography (CT) scan was performed (Figure 2A).



DOI: 10.12998/wjcc.v10.i18.6184 Copyright ©The Author(s) 2022.

Figure 1 Histology and immunohistochemistry images. A: Histology; B: Positivity for programmed death-ligand 1 (combined positive score = 1); C: Positivity for human epidermal growth factor receptor 2.



DOI: 10.12998/wjcc.v10.i18.6184 Copyright ©The Author(s) 2022.

Figure 2 Computed tomography images. A: Baseline; B: After neo-adjuvant therapy; C: After surgery.

FINAL DIAGNOSIS

(1) Thickened wall of the cardia and adjacent lesser curvature of the stomach, suggestive of carcinoma of the cardia, and invaded fundus and multiple lymph nodes in the hepatogastric ligament region, for which clinical and endoscopic examination needed to be performed; (2) Multiple cysts in the liver; (3) Cyst of the right kidney; (4) Slightly thickened left adrenal gland, with follow-up visits recommended; (5) Prostatic calcification; (6) Subpleural ground-glass opacity in the right lung and scattered nodules and granules on the pleura of both lungs and under the interlobar pleura, with follow-up visits recommended; and (7) A dot-like compact shadow on the 5th right rib, for which follow-up visits were recommended.

TREATMENT

From July 30, 2020 to September 2020, four-cycle targeted therapy, chemotherapy, and immunotherapy were administered. The specific regimen was as follows: Trastuzumab: 420 mg in the first cycle and 280 mg in the second cycle; docetaxel: 90 mg, ivd, d1; oxaliplatin: 150 mg, ivd, d1; calcium folinate: 700 mg, ivd, d1; fluorouracil: 4800, civ, 46 h; and toripalimab: 240 mg, ivd, d2; Q2W. Grade I gastrointestinal reaction occurred and improved after symptomatic treatment.

The imaging findings (CT on October 15, 2020, compared with that on July 30, 2020) after the four cycles of therapy were as follows (Figure 2B): The wall thickness of the cardia and adjacent lesser curvature was less than that before therapy; lymph nodes in the hepatogastric ligament region were reduced in size; and subpleural infiltration in the right lower lobe was more absorbed. No other significant changes were noted. Upper gastrointestinal tract radiography revealed carcinoma of the cardia.

Under general anesthesia, the patient underwent laparoscopic radical D2 gastrectomy for gastric carcinoma on October 23, 2020. Surgical findings revealed a neoplasm at the fundus of the stomach from the cardia, which presented as a 4 cm × 2 cm ulcer with local serosal invasion. No significantly enlarged lymph nodes were found around the stomach. The lesions presented post-chemotherapy scar-like changes. Multiple small lymph nodes were noted around the stomach, most of which were post-chemotherapy changes. The postoperative pathological findings revealed focal (proximal stomach) mild atypical glandular hyperplasia with chronic mucosal inflammation, no clear residual tumor (tumor

regression grade 0), no regional lymph node metastasis, and negative upper and lower cut ends. The grading was as follows: Station 1 0/9, Station 2 0/6, Station 3A 0/12, Station 3B 0/2, Station 4SA soft tissue (-), Station 4SB 0/1 and soft tissue (-), Station 4D 0/2, Station 5 soft tissue (-), Station 6 0/1, Station 7 soft tissue (-), Station 8 soft tissue (-), Station 9 0/4, Station 12A soft tissue (-), Station 19 0/1, and Station 20 0/2. No circulating tumor microemboli or circulating tumor cells were detected. A retest of tumor markers showed a return to normal levels.

OUTCOME AND FOLLOW-UP

With good postoperative recovery, the postoperative CT film (performed on November 16, 2020, [Figure 2C](#)) was stored, and the four-cycle chemotherapy regimen was continued at the same dosage as that administered previously. Until February 27, 2022, the patient was examined quarterly for 12 mo (4 times), and he was in a good condition without disease progression. The timeline of this case report is indicated in [Figure 3](#).

DISCUSSION

In a study of combined immunotherapy and trastuzumab treatment for HER2-positive gastric carcinoma[13], 25 patients received immunotherapy and targeted therapy as the initial treatment and chemotherapy in the second cycle, whereas 12 patients received immunotherapy, targeted therapy, and chemotherapy as the initial treatment. In the initial treatment, no significant difference was observed in PFS and 12-mo OS between the 25-patient and 12-patient groups. While in our case, the patient did not receive chemotherapy in the initial treatment; more specifically, the patient received Herceptin and toripalimab in the first cycle and chemotherapy in the second cycle. Previous studies have found no difference in survival between groups receiving chemotherapy and groups not receiving chemotherapy in the initial treatment. Our study suggested that, for HER2-positive gastric carcinoma patients, it is worthy to further evaluate whether the first-line “de-chemotherapy” can be carried out with a large cohort sample.

It is believed that the basis for immunotherapy to benefit HER2-positive patients is that trastuzumab induces antibody-dependent cell-mediated cytotoxicity, improves the presentation of tumor antigens, and paves the way for immune reaction of tumors[14]. Clinical data also show that HER2-positive breast cancer has more types of tumor-infiltrating lymphocytes than average, which demonstrates the importance of trastuzumab in immunity induction[15]. In addition, studies have confirmed that trastuzumab can increase the expression level of PD-L1 in immune cells of patients with breast cancer [16]. Combined with the encouraging clinical outcome of this patient, it is promising to investigate the systemic immune responses in depth, for instance, the lymphocyte infiltration, immune marker dynamics, and functional cytokine secretion. Moreover, this patient has been infected with HBV for many years, which may have an impact on his immune system. Large cohorts are necessary to draw conclusions regarding this aspect if feasible.

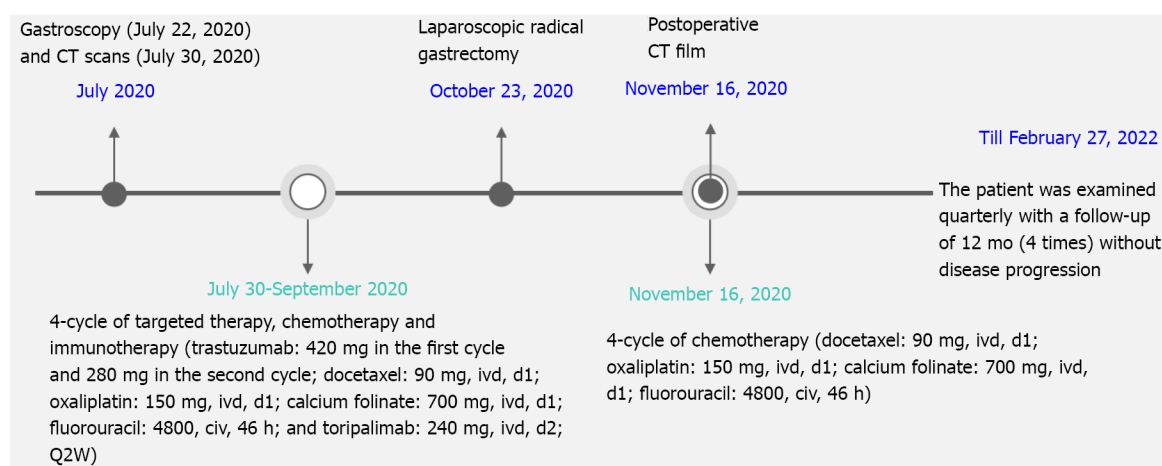
There are many ongoing studies of neoadjuvant immunotherapy combined with chemotherapy or radiotherapy; however, most of these studies are phase II studies with small cohorts. According to some of the results reported thus far, these combined regimens have shown promising efficacy and safety[17-19] ([Table 1](#)). Many studies have shown that chemotherapy can: (1) Boost the release of damage-associated molecular patterns from tumor cells and improve tumor cell immunogenicity; and (2) Elevate the levels of major histocompatibility complex molecules and enhance tumor antigen presentation[20]. Additionally, chemotherapy promotes the expression of PD-1/PD-L1 through a variety of signaling pathways. Therefore, in this case, chemotherapy and immunotherapy were applied for the patient before the surgical removal. For gastric carcinoma, first-line immunotherapy combined with chemotherapy is recommended by NCCN guidelines for patients with a PD-L1 CPS ≥ 5 . However, the CheckMate 649 study[7] suggested that nivolumab combined with chemotherapy improves the OS and DFS of all patients, including those with a CPS ≥ 5 and CPS ≥ 1 . In line with this, our patient's IHC results revealed PD-L1 with a CPS of 1. More prospective cohort studies are needed to determine the selection of biomarkers in neoadjuvant therapies involving immunotherapy and chemotherapy.

Apart from the above aspects, *TP53* is a crucial tumor suppressor gene, and *TP53* mutation occurs at an incidence of approximately 45% in gastric carcinoma[21]. The efficacy of immunotherapy varies with the *TP53* mutation. According to the retrospective meta-analysis mentioned above, *TP53* mutation was negatively correlated with the patients' OS with either colon cancer or gastric carcinoma who received immunotherapy but was positively correlated with the efficacy of immunotherapy for lung cancer[21]. In this study, *TP53* c.329G>C p.Arg110Pro mutation was detected using NGS in the baseline tissues of the patient. Therefore, additional prospective cohort studies are required to conclude and explore the correlation between *TP53* mutation and the efficacy of immunotherapy for gastric carcinoma.

Table 1 Summary of neoadjuvant immunotherapies for gastric carcinoma

Regimen	Neoplasm	Number of participants	pCR rate	MPR	Ref.
Camrelizumab plus FOLFOX	Locally advanced gastric carcinoma and adenocarcinoma of the esophagogastric junction	26	2 (9%)	8 (36%)	[17]
Sintilimab plus FLOT	Gastric and adenocarcinoma of the esophagogastric junction	17	3/17 (17.6%)	10/17 (58.8%)	[18]
Sintilimab plus CapeOX	Locally advanced resectable gastric/adenocarcinoma of the esophagogastric junction	26	6/26 (23.1%)	14/26 (53.8%)	[19]

MPR: Mannose 6-phosphate receptors; pCR: Pathologic complete response.



DOI: 10.12998/wjcc.v10.i18.6184 Copyright ©The Author(s) 2022.

Figure 3 Timeline of this case report. CT: Computed tomography.

CONCLUSION

Here, we demonstrated that in a patient with HER2-positive locally advanced gastric carcinoma, there was scope for resection; therefore, a regimen composed of Herceptin, chemotherapy, and immunotherapy was carefully selected to achieve higher efficacy and better surgical resection. The patient was administered with the perioperative regimen comprising Herceptin, FLOT, and toripalimab. The postoperative pathological findings revealed that this regimen led to complete tumor response and the levels of tumor biomarkers returned to normal. Furthermore, no circulating tumor cell was detected and no significant immune-related adverse effects were noted, demonstrating that this regimen had sufficient efficacy and safety. The four-cycle chemotherapy was continued postoperatively and completed in the patient, in line with the principle of "effective treatment should be continued if the symptoms are relieved". This patient is currently in the quarterly follow-up period. A previous study suggested that the ability to achieve postoperative pCR in patients with neoadjuvant therapy is positively correlated with longer durations of survival[22]. Thus far, all tumors have been removed from this patient using this regimen, and we hope that this regimen will lead to long-time survival benefits.

FOOTNOTES

Author contributions: Liu R designed the experiments, processed the data, applied for fund support, and wrote the first draft; Wang X performed the data collection; Ji Z, Deng T, Li HL, Zhang YH, Yang YC, Ge SH, Zhang L, Bai M and Ning T performed the data analysis; Ba Y modified the article.

Supported by Chinese Research Hospital Association, No. Y2019FH-DTCC-SC3.

Informed consent statement: Informed written consent was obtained from the patient for the publication of this report and any accompanying images.

Conflict-of-interest statement: Nothing to disclose.

CARE Checklist (2016) statement: The authors have read the CARE Checklist (2016), and the manuscript was prepared and revised according to the CARE Checklist (2016).

Open-Access: This article is an open-access article that was selected by an in-house editor and fully peer-reviewed by external reviewers. It is distributed in accordance with the Creative Commons Attribution NonCommercial (CC BY-NC 4.0) license, which permits others to distribute, remix, adapt, build upon this work non-commercially, and license their derivative works on different terms, provided the original work is properly cited and the use is non-commercial. See: <https://creativecommons.org/licenses/by-nc/4.0/>

Country/Territory of origin: China

ORCID number: Rui Liu 0000-0003-1287-2589; Xia Wang 0000-0002-2935-0691; Zhi Ji 0000-0002-2935-0692; Ting Deng 0001-0002-2935-0694; Hong-Li Li 0000-0002-8476-0936; Yan-Hui Zhang 0002-0002-3546-0876; Yu-Chong Yang 0000-0002-2935-0698; Shao-Hua Ge 0001-0002-2935-7642; Le Zhang 0001-0002-2935-0699; Ming Bai 0000-0002-2935-0666; Tao Ning 0000-0002-2935-0654; Yi Ba 0000-0002-2935-0634.

S-Editor: Fan JR

L-Editor: Wang TQ

P-Editor: Fan JR

REFERENCES

- 1 **Sehdev A, Catenacci DV.** Perioperative therapy for locally advanced gastroesophageal cancer: current controversies and consensus of care. *J Hematol Oncol* 2013; **6**: 66 [PMID: 24010946 DOI: 10.1186/1756-8722-6-66]
- 2 **Cunningham D, Allum WH, Stenning SP, Thompson JN, Van de Velde CJ, Nicolson M, Scarffe JH, Lofts FJ, Falk SJ, Iveson TJ, Smith DB, Langley RE, Verma M, Weeden S, Chua YJ, MAGIC Trial Participants.** Perioperative chemotherapy vs surgery alone for resectable gastroesophageal cancer. *N Engl J Med* 2006; **355**: 11-20 [PMID: 16822992 DOI: 10.1056/NEJMoa055531]
- 3 **Ychou M, Boige V, Pignon JP, Conroy T, Bouché O, Lerebret G, Ducourtieux M, Bedenne L, Fabre JM, Saint-Aubert B, Genève J, Lasser P, Rougier P.** Perioperative chemotherapy compared with surgery alone for resectable gastroesophageal adenocarcinoma: an FNCLCC and FFCO multicenter phase III trial. *J Clin Oncol* 2011; **29**: 1715-1721 [PMID: 21444866 DOI: 10.1200/JCO.2010.33.0597]
- 4 **Schuhmacher C, Gretschel S, Lordick F, Reichardt P, Hohenberger W, Eisenberger CF, Haag C, Mauer ME, Hasan B, Welch J, Ott K, Hoelscher A, Schneider PM, Bechstein W, Wilke H, Lutz MP, Nordlinger B, Van Cutsem E, Siewert JR, Schlag PM.** Neoadjuvant chemotherapy compared with surgery alone for locally advanced cancer of the stomach and cardia: European Organisation for Research and Treatment of Cancer randomized trial 40954. *J Clin Oncol* 2010; **28**: 5210-5218 [PMID: 21060024 DOI: 10.1200/JCO.2009.26.6114]
- 5 **Fuchs CS, Doi T, Jang RW, Muro K, Satoh T, Machado M, Sun W, Jalal SI, Shah MA, Metges JP, Garrido M, Golan T, Mandala M, Wainberg ZA, Catenacci DV, Ohtsu A, Shitara K, Geva R, Bleeker J, Ko AH, Ku G, Philip P, Enzinger PC, Bang YJ, Levitan D, Wang J, Rosales M, Dalal RP, Yoon HH.** Safety and Efficacy of Pembrolizumab Monotherapy in Patients With Previously Treated Advanced Gastric and Gastroesophageal Junction Cancer: Phase 2 Clinical KEYNOTE-059 Trial. *JAMA Oncol* 2018; **4**: e180013 [PMID: 29543932 DOI: 10.1001/jamaoncol.2018.0013]
- 6 **Kang YK, Boku N, Satoh T, Ryu MH, Chao Y, Kato K, Chung HC, Chen JS, Muro K, Kang WK, Yeh KH, Yoshikawa T, Oh SC, Bai LY, Tamura T, Lee KW, Hamamoto Y, Kim JG, Chin K, Oh DY, Minashi K, Cho JY, Tsuda M, Chen LT.** Nivolumab in patients with advanced gastric or gastro-oesophageal junction cancer refractory to, or intolerant of, at least two previous chemotherapy regimens (ONO-4538-12, ATTRACTION-2): a randomised, double-blind, placebo-controlled, phase 3 trial. *Lancet* 2017; **390**: 2461-2471 [PMID: 28993052 DOI: 10.1016/S0140-6736(17)31827-5]
- 7 **Janjigian YY, Shitara K, Moehler M, Garrido M, Salman P, Shen L, Wyrwicz L, Yamaguchi K, Skoczylas T, Campos Bragagnoli A, Liu T, Schenker M, Yanez P, Tehfe M, Kowalyszyn R, Karamouzis MV, Bruges R, Zander T, Pazo-Cid R, Hitre E, Feeney K, Cleary JM, Poulart V, Cullen D, Lei M, Xiao H, Kondo K, Li M, Ajani JA.** First-line nivolumab plus chemotherapy vs chemotherapy alone for advanced gastric, gastro-oesophageal junction, and oesophageal adenocarcinoma (CheckMate 649): a randomised, open-label, phase 3 trial. *Lancet* 2021; **398**: 27-40 [PMID: 34102137 DOI: 10.1016/S0140-6736(21)00797-2]
- 8 **Kang YK, Chen LT, Ryu MH, Oh DY, Oh SC, Chung HC, Lee KW, Omori T, Shitara K, Sakuramoto S, Chung JJ, Yamaguchi K, Kato K, Sym SJ, Kadowaki S, Tsuji K, Chen JS, Bai LY, Oh SY, Choda Y, Yasui H, Takeuchi K, Hirashima Y, Hagihara S, Boku N.** Nivolumab plus chemotherapy vs placebo plus chemotherapy in patients with HER2-negative, untreated, unresectable advanced or recurrent gastric or gastro-oesophageal junction cancer (ATTRACTION-4): a randomised, multicentre, double-blind, placebo-controlled, phase 3 trial. *Lancet Oncol* 2022; **23**: 234-247 [PMID: 35030335 DOI: 10.1016/S1470-2045(21)00692-6]
- 9 **Ren C, Wei XL, Xu N, Shen L, Dai GH, Yuan XL, Chen Y, Yang SJ, Shi JH, Hu XC, Lin XY, Zhang QY, Feng JF, Ba Y, Liu YP, Liu W, Shu YQ, Xu RH, Shanghai Junshi Biosciences.** Clinical response and biomarker analysis of a phase II basket trial of toripalimab, a PD-1 mAb in combination with standard chemotherapy as a first-line treatment for patients with solid tumors. *2020 ASCO Annual Meeting 1* 2020; **38**: 15 [DOI: 10.1200/JCO.2020.38.15_suppl.e15083]
- 10 **Bang YJ, Van Cutsem E, Fuchs CS, Ohtsu A, Tabernero J, Ilson DH, Hyung WJ, Strong VE, Goetze TO, Yoshikawa T,**

- Tang LH, Hwang PMT, Webb N, Adelberg D, Shitara K. KEYNOTE-585: Phase III study of perioperative chemotherapy with or without pembrolizumab for gastric cancer. *Future Oncol* 2019; **15**: 943-952 [PMID: 30777447 DOI: 10.2217/fon-2018-0581]
- 11 **Ménard S**, Pupa SM, Campiglio M, Tagliabue E. Biologic and therapeutic role of HER2 in cancer. *Oncogene* 2003; **22**: 6570-6578 [PMID: 14528282 DOI: 10.1038/sj.onc.1206779]
 - 12 **Grillo F**, Fassan M, Sarocchi F, Fiocca R, Mastracci L. HER2 heterogeneity in gastric/gastroesophageal cancers: From benchside to practice. *World J Gastroenterol* 2016; **22**: 5879-5887 [PMID: 27468182 DOI: 10.3748/wjg.v22.i26.5879]
 - 13 **Janjigian YY**, Maron SB, Chatila WK, Millang B, Chavan SS, Alterman C, Chou JF, Segal MF, Simmons MZ, Momtaz P, Shcherba M, Ku GY, Zervoudakis A, Won ES, Kelsen DP, Ilson DH, Nagy RJ, Lanman RB, Ptashkin RN, Donoghue MTA, Capanu M, Taylor BS, Solit DB, Schultz N, Hechtman JF. First-line pembrolizumab and trastuzumab in HER2-positive oesophageal, gastric, or gastro-oesophageal junction cancer: an open-label, single-arm, phase 2 trial. *Lancet Oncol* 2020; **21**: 821-831 [PMID: 32437664 DOI: 10.1016/S1470-2045(20)30169-8]
 - 14 **Melero I**, Berman DM, Aznar MA, Korman AJ, Pérez Gracia JL, Haanen J. Evolving synergistic combinations of targeted immunotherapies to combat cancer. *Nat Rev Cancer* 2015; **15**: 457-472 [PMID: 26205340 DOI: 10.1038/nrc3973]
 - 15 **Savas P**, Loi S. Investigating the positive relationship between tumor-infiltrating lymphocytes and trastuzumab therapy. *Immunotherapy* 2014; **6**: 803-805 [PMID: 25290412 DOI: 10.2217/imt.14.60]
 - 16 **Chaganty BKR**, Qiu S, Gest A, Lu Y, Ivan C, Calin GA, Weiner LM, Fan Z. Trastuzumab upregulates PD-L1 as a potential mechanism of trastuzumab resistance through engagement of immune effector cells and stimulation of IFN γ secretion. *Cancer Lett* 2018; **430**: 47-56 [PMID: 29746929 DOI: 10.1016/j.canlet.2018.05.009]
 - 17 **Liu Y**, Han G, Li H. Camrelizumab combined with FOLFOX as neoadjuvant therapy for resectable locally advanced gastric and gastroesophageal junction adenocarcinoma. *J Clin Oncol* 2020; **38** suppl 15: 4536
 - 18 **Li N**, Li Z, Fu Q, Zhang B, Luo S. Phase II study of sintilimab combined with FLOT regimen for neoadjuvant treatment of gastric or gastroesophageal junction (GEJ) adenocarcinoma. *J Clin Oncol* 2021; **39** suppl 3: 216 [DOI: 10.1200/JCO.2021.39.3_suppl.216]
 - 19 **Jiang H**, Yu X, Kong M, Ma Z, Zhou D, Wang W, Wang H, Li N, He K. Sintilimab plus oxaliplatin/capecitabine (CapeOx) as neoadjuvant therapy in patients with locally advanced, resectable gastric (G)/esophagogastric junction (GEJ) adenocarcinoma. *J Clin Oncol* 2021; **39** suppl 3: 211 [DOI: 10.1200/JCO.2021.39.3_suppl.211]
 - 20 **Heinhuis KM**, Ros W, Kok M, Steeghs N, Beijnen JH, Schellens JHM. Enhancing antitumor response by combining immune checkpoint inhibitors with chemotherapy in solid tumors. *Ann Oncol* 2019; **30**: 219-235 [PMID: 30608567 DOI: 10.1093/annonc/mdy551]
 - 21 **Li L**, Li M, Wang X. Cancer type-dependent correlations between TP53 mutations and antitumor immunity. *DNA Repair (Amst)* 2020; **88**: 102785 [PMID: 32007736 DOI: 10.1016/j.dnarep.2020.102785]
 - 22 **Topalian SL**, Taube JM, Pardoll DM. Neoadjuvant checkpoint blockade for cancer immunotherapy. *Science* 2020; **367** [PMID: 32001626 DOI: 10.1126/science.aax0182]



Published by **Baishideng Publishing Group Inc**
7041 Koll Center Parkway, Suite 160, Pleasanton, CA 94566, USA
Telephone: +1-925-3991568
E-mail: bpgoffice@wjgnet.com
Help Desk: <https://www.f6publishing.com/helpdesk>
<https://www.wjgnet.com>

