

ORIGINAL ARTICLE

ARHGEF9 gene variant leads to developmental and epileptic encephalopathy: Genotypic phenotype analysis and treatment exploration

Haiyan Yang¹  | Hongmei Liao¹ | Siyi Gan¹ | Ting Xiao² | Liwen Wu¹

¹Department of Neurology, Hunan Children's Hospital, Changsha, P.R. China

²Department of Pediatrics, Xiangya Hospital, Central South University, Changsha, P.R. China

Correspondence

Liwen Wu, Department of Neurology, Hunan Children's Hospital, Ziyuan Road 86th, Changsha 410007, Hunan, P.R. China.
Email: 271417152@qq.com

Funding information

Huxiang Youth Talent Support Program, Grant/Award Number: 2021RC3117; National Natural Science Foundation of China, Grant/Award Number: 82171453 and 81671297; Natural Science Foundation of Hunan Province, Grant/Award Number: 2021JJ30393

Abstract

Background: The *ARHGEF9* gene variants have phenotypic heterogeneity, the number of reported clinical cases are limited and the genotype–phenotype relationship is still unpredictable.

Methods: Clinical data of the patients and their family members were gathered in a retrospective study. The exome sequencing that was performed on peripheral blood samples was applied for genetic analysis. We used the *ARHGEF9* gene as a key word to search the PubMed database for cases of *ARHGEF9* gene variants that have previously been reported and summarized the reported *ARHGEF9* gene variant sites, their corresponding clinical phenotypes, and effective treatment.

Results: We described five patients with developmental and epileptic encephalopathy caused by *ARHGEF9* gene variants. Among them, the antiepileptic treatment of valproic acid and levetiracetam was effective in two cases individually. The exome sequencing results showed five children with point mutations in the *ARHGEF9* gene: p.R365H, p.M388V, p.D213E, and p.R63H. So far, a total of 40 children with *ARHGEF9* gene variants have been reported. Their main clinical phenotypes include developmental delay, epilepsy, epileptic encephalopathy, and autism spectrum disorders. The variants reported in the literature, including 22 de novo variants, nine maternal variants, and one unknown variant. There were 20 variants associated with epileptic phenotypes, of which six variants are effective for valproic acid treatment.

Conclusion: The genotypes and phenotypes of *ARHGEF9* gene variants represent a wide spectrum, and the clinical phenotype of epilepsy is often refractory and the prognosis is poor. The p.R365H, p.M388V, p.D213E, and p.R63H variants have not been reported in the current literature, and our study has expanded the genotype spectrum of *ARHGEF9* gene. Our findings indicate that levetiracetam and valproic acid can effectively control seizures in children with epileptic phenotype caused by *ARGHEF9* gene variations. These findings will help clinicians improve the level of diagnosis and treatment of the genetic disease.

This is an open access article under the terms of the [Creative Commons Attribution-NonCommercial-NoDerivs](https://creativecommons.org/licenses/by-nc-nd/4.0/) License, which permits use and distribution in any medium, provided the original work is properly cited, the use is non-commercial and no modifications or adaptations are made.

© 2022 The Authors. *Molecular Genetics & Genomic Medicine* published by Wiley Periodicals LLC.

KEYWORDS*ARHGEF9* gene, child, developmental delay, epilepsy, treatment

1 | BACKGROUND

The *ARHGEF9* gene (OMIM: 300429) encodes collybistin, which belongs to the Rho-like GTPases family, which acts as a molecular switch by cycling from an active GTP-bound state to an inactive GTP-bound state, playing a pivotal role in the formation of postsynaptic glycine and inhibitory gamma-aminobutyric acid receptor clusters and is involved in the regulation of neural excitability and the pathogenesis of epilepsy (Scala, Nishikawa, et al., 2021; Shimojima et al., 2011). *ARHGEF9* gene is associated with an X-linked developmental-epileptic encephalopathy and extensive clinical phenotype, including hyperactivity; impulsivity, hypotonia, and autism spectrum disorder (Alber et al., 2017; Harvey et al., 2004). The *ARHGEF9* gene has obvious clinical heterogeneity, and the relationship between its genotype and clinical phenotype is still unclear, and there is a lack of systematic research. Here, we report five patients with developmental and epileptic encephalopathy caused by *ARHGEF9* gene variant, and summarize the previously reported literature on *ARHGEF9* gene, analyze their genotypes and phenotypes, and explore potentially effective treatments.

2 | METHODS

2.1 | Patient

Five patients were included in the study. The patients were managed at the Department of Neurology, Hunan Children's Hospital. The parents of the patients provided written informed consent.

2.2 | Exome sequencing of peripheral blood

The exome sequencing method was performed according to our previous research methods (Yang et al., 2020). In brief, genomic DNA was fragmented into ~200bp and captured by gene panel target capture kit, then DNA library was sequenced on Illumina platform. After removing adapters and low quality reads, paired-End clean reads were mapped to the human reference genome (GRCh37/hg19) by BWA. Sequence variants were annotated using population and literature databases, including 1000 Genomes, dbSNP, GnomAD, Clinvar, HGMD, and

OMIM. Variant interpretation was performed according to the American College of Medical Genetics (ACMG) guidelines (Richards et al., 2015). The exome sequencing was performed simultaneously on samples from the patients and their parents.

2.3 | Literature review

We used the *ARHGEF9* gene as a key word to search the PubMed database for cases of *ARHGEF9* gene variants that have previously been reported and summarized the reported *ARHGEF9* gene variants, their corresponding clinical phenotypes and effective treatment.

3 | RESULTS

3.1 | Case report

Case 1 was a 4-year-old male child who presented with recurrent seizures at the age 2 months. The seizure types were generalized tonic-clonic seizure and thermosensitive epilepsy. The electroencephalogram (EEG) showed normal background, widespread spikes, and spikes slow waves. The Gesell child development scale showed severe developmental delay. According to the child's clinical manifestations and EEG characteristics, the child was diagnosed with developmental and epileptic encephalopathy. After the diagnosis of developmental and epileptic encephalopathy was confirmed, the child was treated with valproic acid for antiepileptic treatment. The child's seizures were gradually controlled. At present, the child has no seizures, but still has severe developmental delay, which is characterized by being unable to walk independently at the age of 4 years.

Case 2 was a 10-year-old male child who presented with recurrent seizures and hyperarousal to noise at the age of 6 months. The seizure types were generalized tonic-clonic seizure, myoclonus, seizure status, and thermosensitive epilepsy. The EEG showed slow wave background, widespread spikes, and spikes slow waves. The Gesell child development scale showed severe developmental delay. According to the child's clinical manifestations and EEG characteristics, the child was diagnosed with developmental and epileptic encephalopathy. After the diagnosis of developmental and epileptic encephalopathy was confirmed, the child was treated with levetiracetam,

topiramate, oxcarbazepine, and ketogenic diet for antiepileptic treatment successively, and the control of seizures was ineffective. At present, the child still has generalized tonic-clonic seizure and severe developmental delay, which is manifested as that he still cannot walk independently and cannot speak at the age of 10 years.

Case 3 was a 3 years and 7 months old male child who presented with recurrent febrile seizures at the age of 1 year and 4 months. After 2-year-old, the patient presented with nonfebrile seizures, and the seizure types included generalized tonic-clonic seizure, myoclonus, autonomic seizure, seizure status, and thermosensitive epilepsy. The EEG showed slow wave background, widespread spikes, spikes slow waves, obvious in frontal area. The Gesell child development scale showed severe developmental delay. According to the child's clinical manifestations and EEG characteristics, the child was eventually diagnosed with developmental and epileptic encephalopathy. After the diagnosis of developmental and epileptic encephalopathy was confirmed, the child was treated with levetiracetam for antiepileptic treatment. The child's seizures were gradually controlled. At present, the child has no seizures, but has severe developmental delay, which is manifested as that he can only speak at the age of 2 years and 3 months, and still cannot walk independently at the age of 3 years and 7 months.

Case 4 was a 2 years and 9 months old male child who presented with recurrent seizures at the age 6 months. The seizure types included focal secondary generalized tonic-clonic seizure and cluster seizures. The EEG revealed that normal background, spikes waves, spikes slow waves in bilateral occipital area during sleep. The Gesell child development scale showed developmental delay. According to the child's clinical manifestations and EEG characteristics, the child was eventually diagnosed with developmental and epileptic encephalopathy. After the diagnosis of developmental and epileptic encephalopathy was confirmed, the child was treated with levetiracetam for antiepileptic treatment. The child's seizures were gradually controlled. At present, the child has no seizures but has moderate developmental delay, which is manifested as that he can walk independently at the age of 2 years, and only speak at the age of 2 years and 4 months.

Case 5 was a 2 years and 4 months old male child who presented recurrent seizures at the age 11 months. The seizure types included focal secondary generalized tonic-clonic seizure and thermosensitive epilepsy. The EEG showed slow wave background, spikes waves, spikes slow waves in occipital and posterior temporal area. The Gesell child development scale showed mild developmental delay. According to the child's clinical manifestations and EEG characteristics, the child was diagnosed with developmental and epileptic encephalopathy. After the diagnosis

of epilepsy was confirmed, the child was treated with valproic acid for antiepileptic treatment. The child's seizures were gradually controlled. At present, the child has no seizures, but still has mild developmental delay, which is characterized by being able to walk independently at the age of 1 years and 3 months, and being unable to speak at the age of 2 years and 4 months. See [Table 1](#) for details.

3.2 | Genetic evaluation

The onset age of epilepsy in the five children was infantile, considering the possibility of genetic etiology, and the exome sequencing was performed for family verification in their peripheral blood. Case 1 had an *ARHGEF9* c.1094G>A (p.R365H) hemizygous variant, which was inherited from the mother. According to the ACMG variation classification guidelines, this variation was analyzed as likely pathogenic. Case 2 had *ARHGEF9* c.1162A>G (p.M388V) homozygous variant which was inherited from the mother. According to the ACMG variation classification guidelines, this variation was analyzed as variant of uncertain significance (VUS). In addition, case 2 was also combined with *SCN1A* c.4261A>G (p.K1421E) heterozygous variant, the sequencing data showed that his parents did not carry the variant, which could be a de novo variant. According to the ACMG variation classification guidelines, this variation was analyzed as likely pathogenic. Case 3 had an *ARHGEF9* c.639C>G (p.D213E) hemizygous variant, which was inherited from the mother. According to the ACMG variation classification guidelines, this variation was analyzed as VUS. Case 4 had an *ARHGEF9* c.188G>A (p.R63H) hemizygous variant, the sequencing data showed that his parents did not carry the variant, which could be a de novo variant. According to the ACMG variation classification guidelines, this variation was analyzed as likely pathogenic. Case 5 had an *ARHGEF9* c.1094G>A (p.R365H) hemizygous variant, the sequencing data showed that his parents did not carry the variant, which could be a de novo variant. According to the ACMG variation classification guidelines, this variation was analyzed as likely pathogenic. See [Table 1](#) for details.

3.3 | Summary of the reported *ARHGEF9* cases

So far, a total of 40 children with *ARHGEF9* gene variants have been reported ([Table 2](#)). Their clinical phenotypes include developmental delay, epilepsy, brain atrophy in the cerebral cortex and cerebellar vermis, hyperarousal to noise, hyperactivity, impulsivity, shyness, motor incoordination,

TABLE 1 Genotype and phenotype analyses of the five patients with *ARHGEF9* mutation

	Patient 1	Patient 2	Patient 3	Patient 4	Patient 5
Sex	M	M	M	M	M
Age	4y	10y	3y 7m	2y 9m	2y 4m
Clinical feature	Epilepsy; severe developmental delay	Epilepsy; hyperarousal to noise; severe developmental delay	Recurrent febrile seizures; epilepsy; severe developmental delay	Epilepsy; moderate developmental delay	Epilepsy; mild developmental delay
Seizure types	Generalized tonic-clonic seizure; thermosensitive epilepsy	Generalized tonic-clonic seizure; myoclonus; seizure status; thermosensitive epilepsy	Generalized tonic-clonic seizure; myoclonus; autonomic seizure; seizure status; thermosensitive epilepsy	Focal secondary generalized tonic-clonic seizure; cluster seizures	Focal secondary generalized tonic-clonic seizure; thermosensitive epilepsy
EEG	Normal background, widespread spikes, slow waves	Slow wave background, widespread spikes, slow waves	Slow wave background, widespread spikes, slow waves, obvious in frontal area	Normal background, spikes waves, spikes slow waves in bilateral occipital area during sleep	Slow wave background, spikes waves, spikes slow waves in occipital, and posterior temporal area
Mutation	<i>ARHGEF9</i> : NM_015185.2:exon8: c.1094G>A (p.R365H)	<i>ARHGEF9</i> : NM_015185.2:exon8: c.1162A>G (p.M388V) <i>SCN1A</i> : NM_006920: exon22: c.4261A>G (p.K1421E)	<i>ARHGEF9</i> : NM_0011734: 79.1:exon5: c.639C>G (p.D213E)	<i>ARHGEF9</i> : NM_0011734: 79:exon2: c.188G>A (p.R63H)	<i>ARHGEF9</i> : NM_015185.3:exon8: c.1094G>A (p.R365H)
Inheritance	Maternal	Maternal; de novo	Maternal	De novo	De novo
SIFT	Damaging; 0.001	Tolerated; 1	Damaging; 0.04	Damaging; 0.001	Damaging; 0.001
LRT	Deleterious; 0	Deleterious; 0	Deleterious; 0	Deleterious; 0	Deleterious; 0
PhyloP100way (conservation score)	7.376	3.722	2.535	7.161	7.376
ACMG classification	LP	VUS; LP	VUS	LP	LP
Effective treatment	Valproic	Refractory	Levetiracetam	Levetiracetam	Valproic
Outcome	Seizure free; severe developmental delay	Seizure ineffective; severe developmental delay	Seizure free; severe developmental delay	Seizure free; moderate developmental delay	Seizure free; mild developmental delay

Abbreviations: ACMG, American College of Medical Genetics; F, female; LP, likely pathogenic; LRT, likelihood ratio test; MRI, magnetic resonance imaging; M, male; N/A, not available; P, pathogenic; SIFT, sorting intolerant from tolerant; VUS, variant of unknown significance; y, year.

TABLE 2 Genotype and phenotype analysis of the *ARHGEF9* gene reported in literature

Reference	Mutation	Case (n)	Inheritance (n)	Sex (n)	Age (m)	Clinical feature	Effective treatment
Harvey et al. (2004)	p.G55A	1	De novo	Male (1)	Died at age 4.4 y	Developmental delay; epilepsy; brain atrophy in the cerebral cortex and cerebellar vermis; hyperarousal to noise	Refractory
Marco et al. (2008)	46,X,inv(X)(q11.1q27.3)	1	N/A	Female (1)	15 y	Developmental delay; hyperactivity; impulsivity, shyness; motor incoordination	N/A
Alber et al. (2017)	46,X,t(X;20)(q12;p13)	1	De novo (1)	Female (1)	10 y	Severe intellectual disability; autistic features; hyperactivity; epilepsy	CBZ, PB, TPM, LEV, OXC
Alber et al. (2017)	46,X,t(X;18)(q11.1;q11.21)	1	De novo (1)	Female (1)	15 y	Severe intellectual disability; hyperactivity; epilepsy	VPA
Alber et al. (2017)	Xq11.1deletion: arrXq11.1(62838630-62865334)	1	De novo (1)	Female (1)	9 y	Moderate intellectual disability; hyperactivity; hypotonia	N/A
Alber et al. (2017)	Xq11.1deletion: arrXq11.1(62854862-62862403)	1	De novo (1)	Female (1)	4 y	Moderate intellectual disability; epilepsy	Refractory
Alber et al. (2017)	46,X,inv(X)(q11.1q27.3)	1	De novo (1)	Female (1)	25 y	Moderate intellectual disability; hyperarousal to noise	N/A
Alber et al. (2017)	Xq11.1deletion: arrXq11.1(61848414-63138698)	1	De novo (1)	Male (1)	11 y	Severe intellectual disability; hyperactivity; epilepsy	CBZ, PB, TPM, LEV, OXC
Alber et al. (2017)	Xq11.1deletion: arrXq11.1(62321746-63058548)	1	De novo (1)	Male (1)	5 y	Severe intellectual disability; epilepsy	VPA
Alber et al. (2017)	p.Q2 ^a	1	Maternal (1)	Male (1)	5 y	Severe intellectual disability; epilepsy	Refractory
Alber et al. (2017)	p.S317W	2	Maternal (2)	Male (2)	27 y	Severe intellectual disability; epilepsy	CBZ, CLB
Alber et al. (2017)	p.L177P	1	De novo (1)	Male (1)	4 y	Severe intellectual disability; epilepsy; autistic features	VPA, LEV, LTG
Alber et al. (2017)	p.R104Q	1	De novo (1)	Male (1)	15 y	Severe intellectual disability; epilepsy; autistic features; hyperactivity	Refractory
Alber et al. (2017)	p.R290H	1	De novo (1)	Male (1)	57 y	Moderate intellectual disability; epilepsy	Refractory
Alber et al. (2017)	p.R338W	1	Maternal (1)	Male (1)	26 y	Moderate intellectual disability; epilepsy	N/A
Alber et al. (2017)	p.E400K	1	De novo (1)	Male (1)	2 y	Moderate intellectual disability	N/A
Alber et al. (2017)	p. ? Exon skipping	1	De novo (1)	Male (1)	3 y	Moderate intellectual disability	N/A
Alber et al. (2017)	p.R356Q	1	Maternal	Male (1)	28 y	Mild intellectual disability	N/A
Marco et al. (2008)	46,X,inv(X)(q11.1q27.3)	1	De novo (1)	Female (1)	15 y	Moderate intellectual disability; hypereplexia	N/A

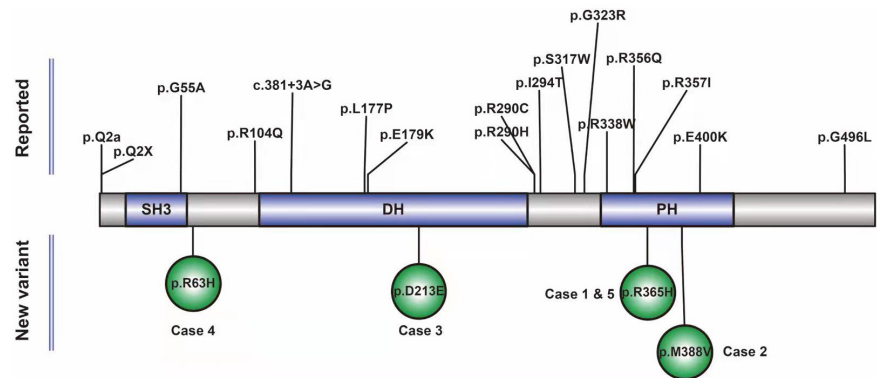
(Continues)

TABLE 2 (Continued)

Reference	Mutation	Case (n)	Inheritance (n)	Sex (n)	Age (m)	Clinical feature	Effective treatment
Wang et al. (2018)	p.R290C	4	De novo (4)	Male (4)	10 y	Intellectual disability; epileptic encephalopathy	Refractory
Aarabi et al. (2019)	Xq11.11deletion:arrXq11.1(62874590-62900823)	2	De novo (2)	Female (2)	23 y	Autism spectrum disorders; developmental delay	N/A
Yao et al. (2020)	c.381+3A>G	1	Maternal (1)	Male (1)	1.8 y	Developmental delay and epilepsy	N/A
Yao et al. (2020)	p.I294T	1	Maternal (1)	Male (1)	15 y	Developmental delay and epilepsy	N/A
Yao et al. (2020)	p.R357I	1	Maternal (1)	Male (1)	8 y	Developmental delay and epilepsy	N/A
Scala et al. (2020)	p.R104Q	1	De novo (1)	Female (1)	5 y	Severe intellectual disability; epilepsy; hypotonia; dysmorphic features; corpus callosum hypoplasia	OXC, VPA
Scala et al. (2021)	p.E179K	1	De novo (1)	Female (1)	25 y	Moderate intellectual disability; hypotonia; dysmorphism; autism spectrum disorders; psychotic episode	N/A
Lesca et al. (2011)	Xq11.11deletion:arrXq11.1(61848414-63138698)	1	De novo (1)	Male (1)	6 y	Developmental delay; epilepsy, macrosomia; dysmorphic features	OXC, LEV
Freri et al. (2020)	p.G496L	1	De novo (1)	Male (1)	16 y	Epilepsy; intellectual disability	Refractory
Shimojima et al. (2011)	Xq11.11deletion:arrXq11.1(62321746-63058548)	1	De novo (1)	Male (1)	5 y	Developmental delay; epilepsy	VPA
Shimojima et al. (2011)	p.Q2X	1	Maternal (1)	Male (1)	5.5 y	Developmental delay; epilepsy	Refractory
Klein et al. (2017)	p.G323R	4	Maternal	Male (4)	21 y	Intellectual disability; focal epilepsy; febrile seizures	VPA, CBZ, perampanel
Bhat et al. (2016)	Xq11.1-Xq11.2 deletion:arrXq11.1-Xq11.2(62970571-63052696)	1	De novo (1)	Female	8 y	Autism spectrum disorder	N/A

Abbreviations: a, lifted over from Hg18 to Hg19; CBZ, clobazam; LEV, levetiracetam; LTC, lamotrigine; m, median; n, number; N/A, not available; OXC, oxcarbazepine; PB, phenobarbital; TPM, topiramate; VPA, valproic acid; y, year.

FIGURE 1 A schematic figure recapitulating novel and previously reported *ARHGEF9* single nucleotide variants



autistic features, hypotonia, hyperekplexia, epileptic encephalopathy, autism spectrum disorders, dysmorphic features; corpus callosum hypoplasia, dysmorphism, psychotic episode, macrosomia, and febrile seizures (Aarabi et al., 2019; Alber et al., 2017; Bhat et al., 2016; Freri et al., 2020; Kalscheuer et al., 2009; Klein et al., 2017; Lesca et al., 2011; Marco et al., 2008; Scala, Zonneveld-Huijssoon, et al., 2021; Striano & Zara, 2017; Wang et al., 2018; Yao et al., 2020). The variants reported in the literature (Aarabi et al., 2019; Alber et al., 2017; Bhat et al., 2016; Freri et al., 2020; Kalscheuer et al., 2009; Klein et al., 2017; Lesca et al., 2011; Marco et al., 2008; Scala, Zonneveld-Huijssoon, et al., 2021; Striano & Zara, 2017; Wang et al., 2018; Yao et al., 2020), including 22 de novo variants, nine maternal variants, and one unknown variant. There were 20 variants associated with epileptic phenotypes, of which six variants are effective for valproic acid treatment. There were three variants associated with autism spectrum disorders, seeing Table 2 for details. The novel and previously reported *ARHGEF9* single nucleotide variants are shown in Figure 1.

4 | DISCUSSION

On the one hand, with the development and widespread application of genomics, more and more genetic diseases have been diagnosed early. On the other hand, more and more genes are found to have clinical heterogeneity and lack of specific genotype–phenotype correlations, making accurate diagnosis of the disease challenging (Scala et al., 2020; Wang et al., 2018). Therefore, this study summarizes and analyzes the clinical phenotype and genotype of the *ARHGEF9* gene with strong clinical heterogeneity, with the hope that clinicians will improve the understanding of the disease and its early diagnosis and improve the prognosis of the disease, which has important clinical significance. The *ARHGEF9* gene is a gene with strong clinical heterogeneity, and different variants correspond to different clinical phenotypes (Wang et al., 2018). According to current literature reports, the main clinical manifestations reported for *ARGHEF9* gene variants are

epilepsy, developmental delay, intellectual disability, hyperarousal to noise, hyperactivity, and autism spectrum disorders (Aarabi et al., 2019; Alber et al., 2017; Bhat et al., 2016; Freri et al., 2020; Kalscheuer et al., 2009; Klein et al., 2017; Lesca et al., 2011; Marco et al., 2008; Scala, Zonneveld-Huijssoon, et al., 2021; Striano & Zara, 2017; Wang et al., 2018; Yao et al., 2020). The seizure types reported in previous literature included focal seizures and generalized tonic–clonic seizures. In this study, five children with *ARHGEF9* gene variant were reported, all of whom were male, and their clinical manifestations included developmental and epileptic encephalopathy and febrile seizures, the types of seizures included focal seizures, generalized tonic–clonic seizures, myoclonus, and thermosensitive epilepsy which were consistent with the clinical phenotypes of children with *ARHGEF9* gene variant reported in previous literatures.

The *ARHGEF9* gene variants reported in the literature include chromosomal variants and point mutations, among which chromosomal variants include chromosomal translocations, insertions, and deletions (Aarabi et al., 2019; Alber et al., 2017; Bhat et al., 2016; Freri et al., 2020; Kalscheuer et al., 2009; Klein et al., 2017; Lesca et al., 2011; Marco et al., 2008; Scala, Zonneveld-Huijssoon, et al., 2021; Striano & Zara, 2017; Wang et al., 2018; Yao et al., 2020). The inheritance of this gene variation has been reported in the current literature as maternal and de novo inheritance (Alber et al., 2017). Our review revealed that the *ARHGEF9* disease was not uniform and varies with the gene variant and likely other genetic and extragenetic factors. Therefore, the diagnostic approach in candidate patients still requires chromosomal microarray testing as the first-line genetic testing because of the substantial diagnostic yield and low relative cost, followed by a gene panel or exome sequencing approach as second tier. There are differences in clinical manifestations caused by different variants of this gene. Among the *ARHGEF9* gene variants reported in the literature, 20 showed epilepsy clinical phenotypes (Alber et al., 2017; Freri et al., 2020; Harvey et al., 2004; Klein et al., 2017; Lesca et al., 2011; Scala, Zonneveld-Huijssoon, et al., 2021;

Shimajima et al., 2011; Wang et al., 2018; Yao et al., 2020), and three showed autism spectrum clinical phenotypes (Aarabi et al., 2019; Bhat et al., 2016; Scala, Zonneveld-Huijssoon, et al., 2021). The details of the variants are shown in Table 2. In this study, we reported five children with *ARHGEF9* variants presenting with epileptic encephalopathy. They were p.R365H, p.M388V, p.D213E, and p.R63H, of which two children had variants at the same gene site, one of which was maternal inheritance and the other was de novo variant. Considering that the genetic mode of this gene is XR, it is possible that there may be maternal inheritance or de novo variant in different patients at the same gene site. All of them have not been reported in the current literature, and our study has expanded the genotype spectrum of *ARHGEF9* gene.

Epilepsy is a very common clinical phenotype of *ARHGEF9* gene variants (Alber et al., 2017; Freri et al., 2020; Harvey et al., 2004; Klein et al., 2017; Lesca et al., 2011; Scala, Zonneveld-Huijssoon, et al., 2021; Shimajima et al., 2011; Wang et al., 2018; Yao et al., 2020). Antiepileptic drugs are the first choice for the treatment of epilepsy (Harvey et al., 2004). At present, the pathogenesis of epilepsy phenotype caused by *ARHGEF9* gene variations is still unclear. Our review showed that *ARHGEF9* gene variations caused seizures were often difficult to control, and antiepileptic drugs were not effective, which often required combined treatment with several antiepileptic drugs, with poor prognosis and often left behind varying degrees of developmental delay (Harvey et al., 2004). Among the five children in our study, the antiepileptic treatment of valproic acid was effective in two cases, and the antiepileptic treatment of levetiracetam was effective in two cases, and the seizures were controlled. At present, none of the four children had recurrent seizures. Analysis of the effective reason for seizures control in children may be that the *ARHGEF9* coding protein collybistin plays a key role in the formation of postsynaptic glycine and inhibitory γ -aminobutyric acid receptor clusters. Disruption of collybistin results in an imbalance of inhibitory and excitatory neurotransmitters (Neuray et al., 2020). Valproic acid can lead to the increase of γ -aminobutyric acid level in vivo, and both levetiracetam and valproic acid can inhibit neuronal excitability. Further confirmation requires animal and cellular functional studies. One child was successively given levetiracetam, topiramate, oxazepam, and ketogenic diet in combination with antiepileptic treatment, but the seizures of the child were still not controlled. In this case, the child had *ARHGEF9* c.1162A>G (p.M388V) homozygous variant, which was analyzed as variant of VUS by the ACMG variation classification guidelines. The child also combined with *SCN1A* c.4261A>G (p.K1421E) heterozygous variant, which was analyzed as likely pathogenic by the ACMG variation classification guidelines. It is likely

that the refractory epileptic phenotype of the child is related to the variation of *SCN1A* gene, but the clinical phenotype of the child also has hyperarousal to noise, which cannot be completely explained by the *SCN1A* gene variant. Although the pathogenicity of *ARHGEF9* c.1162A>G (p.M388V) is defined as VUS, but there is a lack of relevant literature reports at present. With more and more literature reports in the future, the pathogenicity rating may also be reevaluated. So we still believe that the *SCN1A* and *ARHGEF9* variants have a synergistic effect on clinical phenotypes in the child.

In conclusion, the genotypes and phenotypes of *ARHGEF9* gene variants represent a wide spectrum, and the clinical phenotype of epilepsy is often refractory and the prognosis is poor. The p.R365H, p.M388V, p.D213E, and p.R63H variants have not been reported in the current literature, and our study has expanded the genotype spectrum of *ARHGEF9* gene. Our findings indicate that levetiracetam and valproic acid can effectively control seizures in children with epileptic phenotype caused by *ARHGEF9* gene variations. These findings will help clinicians improve the level of diagnosis and treatment of the genetic disease, use effective antiepileptic drugs as soon as possible to control seizures, and help improve the prognosis of children.

ACKNOWLEDGMENTS

The authors wish to thank the patients and their families for their participation in this study.

CONFLICT OF INTEREST

The authors declare that they have no competing interests.

AUTHOR CONTRIBUTIONS

HY conducted the literature review and drafted the manuscript. HL, SG and TX made substantial contributions to the conception and interpretation of data. LW were responsible for revising the manuscript critically and gave final approval of the version to be published. All authors read and approved the manuscript.

DATA AVAILABILITY STATEMENT

The datasets used and/or analyzed during the present study are available from the corresponding author on reasonable request.

ETHICAL COMPLIANCE

This study was approved by the Medical Ethics Committee of Hunan Children's Hospital.

ORCID

Haiyan Yang  <https://orcid.org/0000-0003-1164-8788>

REFERENCES

- Aarabi, M., Kessler, E., Madan-Khetarpal, S., Surti, U., Bellissimo, D., Rajkovic, A., & Yatsenko, S. A. (2019). Autism spectrum disorder in females with ARHGEF9 alterations and a random pattern of X chromosome inactivation. *European Journal of Medical Genetics*, *62*(4), 239–242.
- Alber, M., Kalscheuer, V. M., Marco, E., Sherr, E., Lesca, G., Till, M., Gradek, G., Wiesener, A., Korenke, C., Mercier, S., Becker, F., Yamamoto, T., Scherer, S. W., Marshall, C. R., Walker, S., Dutta, U. R., Dalal, A. B., Suckow, V., Jamali, P., ... Minassian, B. A. (2017). ARHGEF9 disease: Phenotype clarification and genotype-phenotype correlation. *Neurology Genetics*, *3*(3), e148.
- Bhat, G., LaGrave, D., Millson, A., Herriges, J., Lamb, A. N., & Matalon, R. (2016). Xq11.1-11.2 deletion involving ARHGEF9 in a girl with autism spectrum disorder. *European Journal of Medical Genetics*, *59*(9), 470–473.
- Freri, E., Castellotti, B., Didato, G., DiFrancesco, J. C., & Granata, T. (2020). Epilepsy and NREM-parasomnia caused by novel hemizygous ARHGEF9 mutation. *Sleep Medicine*, *76*, 158–159.
- Harvey, K., Duguid, I. C., Alldred, M. J., Beatty, S. E., Ward, H., Keep, N. H., Lingenfelter, S. E., Pearce, B. R., Lundgren, J., Owen, M. J., Smart, T. G., Lüscher, B., Rees, M. I., & Harvey, R. J. (2004). The GDP-GTP exchange factor collybistin: an essential determinant of neuronal gephyrin clustering. *The Journal of Neuroscience*, *24*(25), 5816–5826.
- Kalscheuer, V. M., Musante, L., Fang, C., Hoffmann, K., Fuchs, C., Carta, E., Deas, E., Venkateswarlu, K., Menzel, C., Ullmann, R., Tommerup, N., Dalprà, L., Tzschach, A., Selicorni, A., Lüscher, B., Ropers, H. H., Harvey, K., & Harvey, R. J. (2009). A balanced chromosomal translocation disrupting ARHGEF9 is associated with epilepsy, anxiety, aggression, and mental retardation. *Human Mutation*, *30*(1), 61–68.
- Klein, K. M., Pendziwiat, M., Eilam, A., Gilad, R., Blatt, I., Rosenow, F., Kanaan, M., Helbig, I., Afawi, Z., & Israeli-Palestinian Epilepsy Family Consortium. (2017). The phenotypic spectrum of ARHGEF9 includes intellectual disability, focal epilepsy and febrile seizures. *Journal of Neurology*, *264*(7), 1421–1425.
- Lesca, G., Till, M., Labalme, A., Vallee, D., Hugononq, C., Philip, N., Ederly, P., & Sanlaville, D. (2011). De novo Xq11.11 microdeletion including ARHGEF9 in a boy with mental retardation, epilepsy, macrosomia, and dysmorphic features. *American Journal of Medical Genetics. Part A*, *155A*(7), 1706–1711.
- Marco, E. J., Abidi, F. E., Bristow, J., Dean, W. B., Cotter, P., Jeremy, R. J., Schwartz, C. E., & Sherr, E. H. (2008). ARHGEF9 disruption in a female patient is associated with X linked mental retardation and sensory hyperarousal. *Journal of Medical Genetics*, *45*(2), 100–105.
- Neuray, C., Maroofian, R., Scala, M., Sultan, T., Pai, G. S., Mojarrad, M., Khashab, H. E., deHoll, L., Yue, W., Alsaif, H. S., Zanetti, M. N., Bello, O., Person, R., Eslahi, A., Khazaei, Z., Feizabadi, M. H., Efthymiou, S., SYNAPS Study Group, Groppa, S., ... Houlden, H. (2020). Early-infantile onset epilepsy and developmental delay caused by bi-allelic GAD1 variants. *Brain*, *143*(8), 2388–2397.
- Richards, S., Aziz, N., Bale, S., Bick, D., Das, S., Gastier-Foster, J., Grody, W. W., Hegde, M., Lyon, E., Spector, E., Voelkerding, K., Rehm, H. L., & ACMG Laboratory Quality Assurance Committee. (2015). Standards and guidelines for the interpretation of sequence variants: a joint consensus recommendation of the American College of Medical Genetics and Genomics and the Association for Molecular Pathology. *Genetics in Medicine*, *17*(5), 405–424.
- Scala, M., Bianchi, A., Bisulli, F., Coppola, A., Elia, M., Trivisano, M., Pruna, D., Pippucci, T., Canafoglia, L., Lattanzi, S., Franceschetti, S., Nobile, C., Gambardella, A., Michelucci, R., Zara, F., & Striano, P. (2020). Advances in genetic testing and optimization of clinical management in children and adults with epilepsy. *Expert Review of Neurotherapeutics*, *20*(3), 251–269.
- Scala, M., Nishikawa, M., Nagata, K. I., & Striano, P. (2021). Pathophysiological mechanisms in neurodevelopmental disorders caused by Rac GTPases dysregulation: what's behind neuro-RACopathies. *Cell*, *10*(12), 3395.
- Scala, M., Zonneveld-Huijssoon, E., Brienza, M., Mecarelli, O., van der Hout, A. H., Zambrelli, E., Turner, K., Zara, F., Peron, A., Vignoli, A., & Striano, P. (2021). De novo ARHGEF9 missense variants associated with neurodevelopmental disorder in females: expanding the genotypic and phenotypic spectrum of ARHGEF9 disease in females. *Neurogenetics*, *22*(1), 87–94.
- Shimajima, K., Sugawara, M., Shichiji, M., Mukaida, S., Takayama, R., Imai, K., & Yamamoto, T. (2011). Loss-of-function mutation of collybistin is responsible for X-linked mental retardation associated with epilepsy. *Journal of Human Genetics*, *56*(8), 561–565.
- Striano, P., & Zara, F. (2017). ARHGEF9 mutations cause a specific recognizable X-linked intellectual disability syndrome. *Neurology Genetics*, *3*(3), e159.
- Wang, J. Y., Zhou, P., Wang, J., Tang, B., Su, T., Liu, X. R., Li, B. M., Meng, H., Shi, Y. W., Yi, Y. H., He, N., & Liao, W. P. (2018). ARHGEF9 mutations in epileptic encephalopathy/intellectual disability: toward understanding the mechanism underlying phenotypic variation. *Neurogenetics*, *19*(1), 9–16.
- Yang, H., Yin, F., Gan, S., Pan, Z., Xiao, T., Kessi, M., Yang, Z., Zhang, V. W., & Wu, L. (2020). The study of genetic susceptibility and mitochondrial dysfunction in mesial temporal lobe epilepsy. *Molecular Neurobiology*, *57*(9), 3920–3930.
- Yao, R., Zhang, Y., Liu, J., Wang, J., Xu, Y., Li, N., Wang, J., & Yu, T. (2020). Clinical and molecular characterization of three novel ARHGEF9 mutations in patients with developmental delay and epilepsy. *Journal of Molecular Neuroscience*, *70*(6), 908–915.

How to cite this article: Yang, H., Liao, H., Gan, S., Xiao, T. & Wu, L. (2022). ARHGEF9 gene variant leads to developmental and epileptic encephalopathy: Genotypic phenotype analysis and treatment exploration. *Molecular Genetics & Genomic Medicine*, *10*, e1967. <https://doi.org/10.1002/mgg3.1967>