




RESEARCH ARTICLE

Novel heterozygous variants of *SLC12A6* in Japanese families with Charcot–Marie–Tooth disease

Masahiro Ando¹ , Yujiro Higuchi¹, Junhui Yuan¹, Akiko Yoshimura¹, Takaki Taniguchi^{1,2}, Jun Takei¹, Mika Takeuchi¹, Yu Hiramatsu¹, Fumitaka Shimizu³ , Masaya Kubota⁴, Akari Takeshima⁵, Takehiro Ueda⁶, Kishin Koh⁷ , Utako Nagaoka⁸, Takashi Tokashiki⁹, Setsu Sawai¹⁰, Yusuke Sakiyama¹, Akihiro Hashiguchi¹, Ryota Sato³, Takashi Kanda³, Yuji Okamoto^{1,11} & Hiroshi Takashima¹

¹Department of Neurology and Geriatrics, Kagoshima University Graduate School of Medical and Dental Sciences, Kagoshima, Japan

²Department of Neurology, Imakiire General Hospital, Kagoshima, Japan

³Department of Neurology and Clinical Neuroscience, Yamaguchi University Graduate School of Medicine, Yamaguchi, Japan

⁴Division of Neurology, National Center for Child Health and Development, Tokyo, Japan

⁵Department of Neurology, Brain Research Institute Niigata University, Niigata, Japan

⁶Division of Neurology, Kobe University Graduate School of Medicine, Kobe, Japan

⁷Department of Neurology, Graduate School of Medical Sciences, University of Yamanashi, Yamanashi, Japan

⁸Department of Neurology, Tokyo Metropolitan Neurological Hospital, Tokyo, Japan

⁹Department of Neurology, National Hospital Organization Okinawa National Hospital, Okinawa, Japan

¹⁰Department of Neurology, Graduate School of Medicine, Chiba University, Chiba, Japan

¹¹Department of Physical Therapy, School of Health Sciences, Faculty of Medicine, Kagoshima University, Kagoshima, Japan

Correspondence

Hiroshi Takashima, Department of Neurology and Geriatrics, Kagoshima University Graduate School of Medical and Dental Sciences, 8-35-1 Sakuragaoka, Kagoshima City, Kagoshima, Japan. Tel: 81-99-275-5332; Fax: 81-99-265-7164; E-mail: thiroshi@m3.kufm.kagoshima-u.ac.jp

Funding Information

This work was supported by Grants-in-Aid from the Research Committee of Ataxia, Health Labour Sciences Research Grant, the Ministry of Health, Labour and Welfare, Japan (201610002B). This research is also supported by the Research program for conquering intractable disease from Japan Agency for Medical Research and Development (AMED) (201442014A, 201442071A, 17929553) and JSPS KAKENHI Grant Numbers JP18H02742, JP20K16604, JP21K15702, JP21H02842.

Received: 21 March 2022; Revised: 3 May 2022; Accepted: 26 May 2022

Annals of Clinical and Translational Neurology 2022; 9(7): 902–911

doi: 10.1002/acn3.51603

Abstract

Background: Recessive mutations in *SLC12A6* have been linked to hereditary motor sensory neuropathy with agenesis of the corpus callosum. Patients with early-onset peripheral neuropathy associated with *SLC12A6* heterozygous variants were reported in 2016. Only five families and three variants have been reported to date, and the spectrum is unclear. Here, we aim to describe the clinical and mutation spectra of *SLC12A6*-related Charcot–Marie–Tooth (CMT) disease in Japanese patients. **Methods:** We extracted *SLC12A6* variants from our DNA microarray and targeted resequencing data obtained from 2598 patients with clinically suspected CMT who were referred to our genetic laboratory by neurological or neuropsychiatric departments across Japan. And we summarized the clinical and genetic features of these patients. **Results:** In seven unrelated families, we identified one previously reported and three novel likely pathogenic *SLC12A6* heterozygous variants, as well as two variants of uncertain significance. The mean age of onset for these patients was 17.5 ± 16.1 years. Regarding electrophysiology, the median motor nerve conduction velocity was 39.6 ± 9.5 m/sec. For the first time, we observed intellectual disability in three patients. One patient developed epilepsy, and her brain MRI revealed frontal and temporal lobe atrophy without changes in white matter and corpus callosum. **Conclusions:** Screening for the *SLC12A6* gene should be considered in patients with CMT, particularly those with central nervous system lesions, such as cognitive impairment and epilepsy, regardless of the CMT subtype.

Introduction

Charcot–Marie–Tooth (CMT) disease is the most common type of inherited peripheral neuropathy, with a common phenotype of progressive sensory-motor or motor neuropathy, foot deformity, and altered tendon reflexes. The prevalence of CMT ranges from 9.7/100,000 to 82.3/100,000.¹ CMT is categorized into the demyelinating type and axonal type in accordance with the motor nerve conduction velocity (MNCV). Generally, CMT with a slow MNCV (median MNCV <38 m/sec) is classified as CMT1 (autosomal dominant inheritance) and CMT4 (autosomal recessive inheritance), while CMT without a slow MNCV (median MNCV >38 m/sec) is classified as CMT2. There is an intermediate type of CMT, with the MNCV value between CMT1 and CMT2 (median MNCV; 25–45 m/sec).² To date, more than 100 genes have been associated with CMT and related disorders (<https://neuromuscular.wustl.edu/>). Despite presenting with varying clinical phenotypes, both dominant and recessive mutations of multiple genes, such as *MFN2*, *GDAP1*, and *MME*, have been specifically linked to peripheral neuropathy.^{3–8}

The *SLC12A* (solute carrier family 12) family encodes K^+ - Cl^- co-transporters (KCCs), and *SLC12A6* encodes KCC3. KCCs play crucial roles in cell volume homeostasis, epithelial transport, and neuronal excitability.⁹ Biallelic *SLC12A6* mutations are known to cause severe peripheral neuropathy with agenesis of the corpus callosum.¹⁰ In 2016, a heterozygous de novo p. Thr991Ala variant in *SLC12A6* was identified in a child with severe and progressive peripheral neuropathy via whole-exome sequencing.¹¹ The mechanism of neuropathy due to *SLC12A6* heterozygous variants was predicted to be gain-of-function changes in KCC3, resulting in abnormal cell volume homeostasis.¹¹ Additional reports of sensorimotor neuropathy caused by *SLC12A6* heterozygous variants have recently been reported from Germany and China.^{12,13}

In this study, we analyze the comprehensive genetic data collection from a large-scale case series of Japanese patients with CMT and identified heterozygous *SLC12A6* mutations in multiple families.

Materials and Methods

Patients

We analyzed DNA samples from 2598 patients with clinically diagnosed CMT across Japan between 2007 and 2021. Before enrollment in this study, all patients with demyelinating CMT were confirmed negative for *PMP22* duplication/deletion using fluorescence in situ hybridization or multiplex ligation probe amplification.

Mutation screening was performed in chronological order using DNA microarray (419 patients), Illumina MiSeq (438 patients), and Ion Proton (1741 patients). *SLC12A6* was included as a target gene in all aforementioned genetic analyses. Figure 1 depicts the flowchart of our study.

Genomic DNA extraction

We extracted genomic DNA from peripheral blood or saliva using a Gentra Puregene Blood Kit (QIAGEN, Valencia, CA) or Oragene DNA self-collection kit (DNA Genotek, Ottawa, Ontario, Canada) according to the manufacturer's instructions.

Microarray chip sequencing

For the initial 419 patients enrolled between 2007 and 2012, we performed mutation screening of 30 genes using a customized MyGeneChip[®] CustomSeq[®] Resequencing Array (Affymetrix, Inc., Santa Clara, CA). The detailed procedure has previously been described.¹⁴

Targeted resequencing

Since 2012, mutation screening has been conducted to target 60 and 72 known/candidate CMT-related genes using Illumina MiSeq (Illumina Inc., San Diego, CA) and Ion Proton (ThermoFisher Scientific, Inc., Waltham, MA), respectively. The detailed sequencing and analysis methods have previously been described.¹⁵

Data analysis and variant interpretation

We extracted all *SLC12A6* (NM_133647) variants from all aforementioned studies and compared them to a global control database (gnomAD; <https://gnomad.broadinstitute.org/>), a Japanese control database (jMorp; <https://jmorp.megabank.tohoku.ac.jp/202109/>), and our in-house control database. Furthermore, we performed six lines of computational analysis, namely, SIFT/PROVEAN (<http://provean.jcvi.org/index.php>), PolyPhen-2 (<http://genetics.bwh.harvard.edu/pph2/>), Mutation Assessor (<http://mutationassessor.org/r3/>), FATHMM (<http://fathmm.biocompute.org.uk>), and Condel (<https://bbglab.irbbarcelona.org/fannsd/>), to predict the pathogenicity of these variants. Protein stability analysis was also performed using DynaMut (<http://biosig.unimelb.edu.au/dynamut/>) and iMutant (<https://folding.biofold.org/i-mutant/i-mutant2.0.html>). All variants were validated using Sanger sequencing and interpreted according to ACMG-AMP (American College of Medical Genetics and Genomics and the Association for Molecular Pathology) standards and guidelines.¹⁶

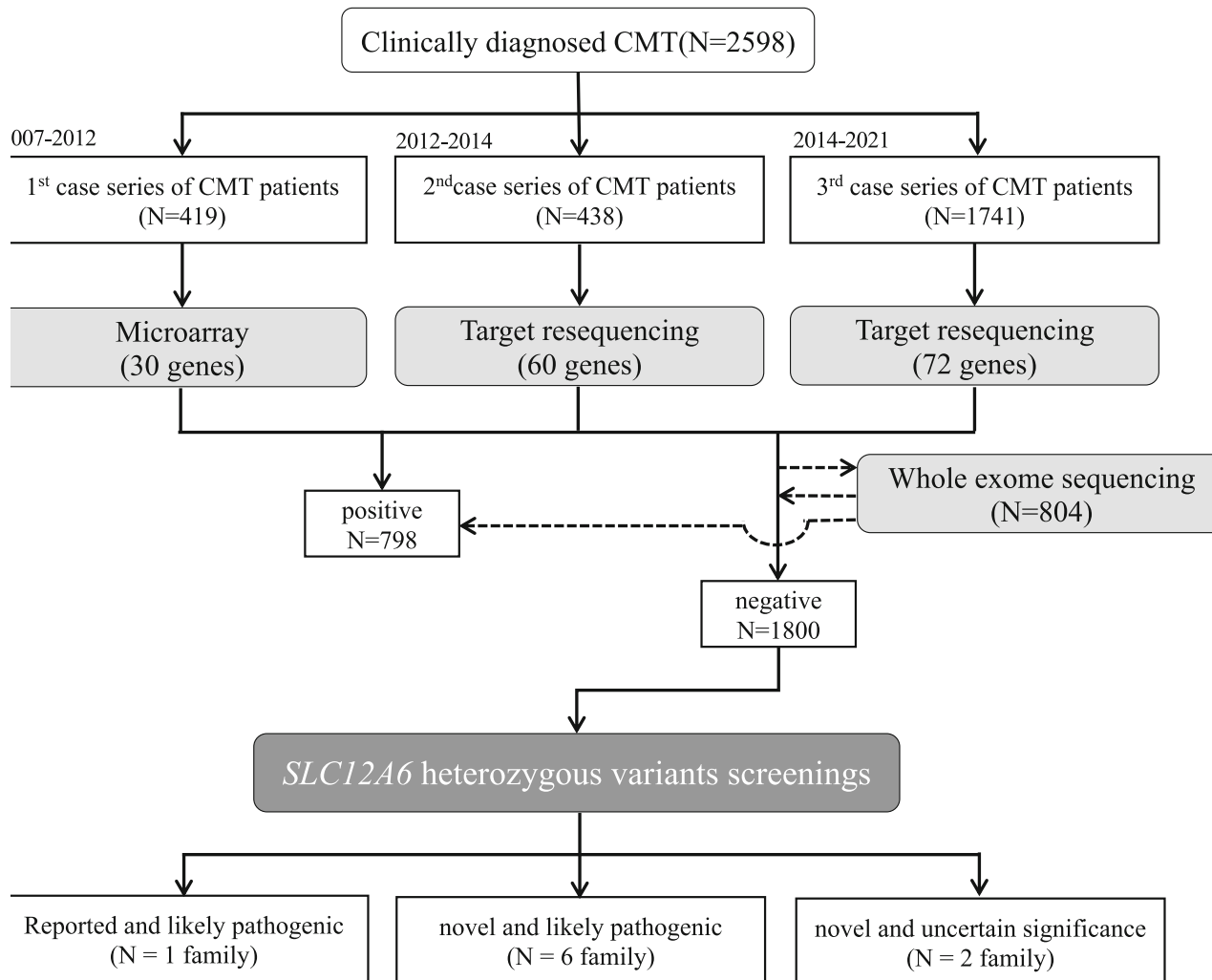


Figure 1. Flow chart of our study. Using DNA microarray and target resequencing, we analyzed 2598 patients with clinically diagnosed CMT, and extracted all *SLC12A6* (NM_133647) variants from the 1800 test-negative patients. CMT, Charcot–Marie–Tooth.

Ethics statement

This study was approved by the Institutional Review Board of Kagoshima University. All patients and family members provided informed consent for participation in the study and genetic analysis.

Results

Clinical findings

Table 1 summarizes the clinical and electrophysiological findings of seven cases with likely pathogenic *SLC12A6* heterozygous variants. The families are depicted in Figure 2A. Their CMT neuropathy scores (CMTNS) are shown in Table S1, and the clinical and

electrophysiological features of two cases with a variant of uncertain significance are shown in Data S1 and Figure 1.

Family 1 (p.Arg207His)

The proband was an eight-years-old girl with no family history of neuromuscular disease. Frequent falling was noted since she was a year old. Her first hospital visit was at 8 years old due to a foot deformity. She was diagnosed with CMT, which caused distal muscle weakness, muscle atrophy, decreased vibration sensation, and loss of tendon reflexes. She also had progressive vision loss. Based on her nerve conduction studies (NCS), she was classified as CMT-intermediate type (right median MNCV 30.9 m/sec and left median MNCV 41.9 m/sec).

Table 1. Clinical and electrophysiological features of current and reported CMT patient with SLC12A6 heterozygous variants.

	Kahle et al. (2016)		Park et al. (2019)		Shi et al. (2021) This report							
	Patient 1	Patient 2	Patient 1	Patient 2	Patient 3	Patient 1	Patient 2	Patient 3	Patient 4	Patient 5	Patient 6	Patient 7
Mutation	c.2971A>G	c.620G>A	c.620G>A	c.620G>A	c.2036A>G	c.620G>A	c.865G>A	c.865G>A	c.1731_1733del	c.1731_1733del	c.1731_1733del	c.2036A>C
Ethnicity	p. T991A American	p. R207H German	p. R207H German	p. R207H German	p. Y679C German	p. R207H Chinese	p. E289L Japanese	p. E289L Japanese	p. F578del Japanese	p. F578del Japanese	p. F578del Japanese	p. Y679S Japanese
Onset age	9 month	1–2 y.o	1–2 y.o	1–2 y.o	1–2 y.o	27 y.o	11 y.o	10 y.o	19 y.o	40 y.o	39 y.o	3 y.o
Exam age	10 y.o	11 y.o	11 y.o	11 y.o	15 y.o	31 y.o	13 y.o	40 y.o	19 y.o	52 y.o	47 y.o	26 y.o
Genotype	Sporadic	Sporadic	Sporadic	Sporadic	Sporadic	Sporadic	AD	AD	AD	AD	AD	Sporadic
Gender	Male	Male	Male	Male	Female	Male	Male	Female	Female	Female	Female	Female
Distal weakness	+	+	–	+	–	+	+	+	+	+	+	+
Distal atrophy	+	+	+	+	+	+	–	–	+	+	+	+
Distal leg MMT	1–2	4–	NA	4+	NA	0	4	NA	2	NA	3	1
Sensory disturbance	–	–	+	–	+	+	+	NA	+	+	–	+
DTR	Absent	Decrease	Absent	Absent	Brisk	Absent	Decrease	Absent	Absent	n.a	Absent	Absent
Cognitive impairment	–	–	–	–	NA	–	Poor school record	–	IQ71	–	–	IQ46
Other symptom	–	Hemolytic anemia	No seizure EEG; burst of generalised spike and polyspike and wave	No seizure EEG; burst of generalised spike and polyspike and wave	Spasticity celiac disease short stature migraine bladder and bowel incontinence	CK427	CK533	–	CK1162	–	–	Epilepsy hemolytic anemia
Median CMAP (mV)	0.2	1.2	3.7–7.3	3.7–7.3	Normal	1.6/5.4	6.2	2.5	5.65	5.5	5.4	0.6/0.2
Median MNCV (m/sec)	31	33	32–35	32–35	Normal	41/41.8	40.3	38	39.3	53	54.5	33.6/25.1
Median SNAP (µV)	9	3.5	NE	NE	Normal	1.0/1.37	NE	NE	1.3	4	NE	2.0/1.0
Median SCV (m/sec)	44	21	NE	NE	Normal	32.4/30.7	NE	NE	38.6	39	NE	40.9/40.0

(Continued)

Table 1 Continued.

	Kahle et al. (2016)			Park et al. (2019)			Shi et al. (2021)							This report								
	Patient 1	Patient 1	Patient 2	Patient 3	Patient 1	Patient 2	Patient 3	Patient 1	Patient 2	Patient 3	Patient 4	Patient 5	Patient 6	Patient 7	Patient 1	Patient 2	Patient 3	Patient 4	Patient 5	Patient 6	Patient 7	
Tibial CMAP (mV)	NA	3.5	NE	33–40	0.07/0.31	n.a	2.3	0.3	0.13	2.1	0.13	0.13	0.14/0.05									
Tibial MNCV (m/sec)	NA	23	NE	1–1.9	NA	21/24	39.8	29	41.6	46	69.2	69.2	13.8/21.1									
Sural SNAP (μ V)	8	NE	NE	NE	NE	n.a	NE	NE	0.3	NE	NE	NE	1.0/2.0									
Sural SCV (m/sec)	27	NE	NE	NE	NE	n.a	NE	NE	25.2	NE	NE	NE	34.1/32.3									
Brain MRI	Normal	Normal	Normal	Normal	Normal	NA	NA	NA	NA	NA	NA	NA	brain atrophy									

MMT, manual muscle test; DTR, deep tendon reflex; NA, not available; AD, autosomal dominant; CK, Creatine kinase (U/L); IQ, intelligence quotient; MNCV, Motor nerve conduction velocity; CMAP, Compound motor action potential; SCV, sensory nerve conduction velocity; SNAP, sensory nerve action potential; NE, not evoked; Normal range, median CMAP >3.1 mV; median MNCV >49.6 m/sec; median SNAP >7.0 μ V; median SCV >47.2 m/sec; tibial CMAP >4.4 mV; tibial MNCV >41.7 m/sec; sural SNAP >5.0 μ V; sural SCV >40.8 m/sec.

Family 2 (p.Glu289Lys)

The proband was a 13-year-old boy with a positive family history of autosomal dominant inheritance. He developed a steppage gait at the age of 11 and experienced abnormal sensations a year later. At 13 years of age, his physical examination revealed weakness and wasting of distal muscles, decreased vibration sensation, and loss of tendon reflexes. He was not mentally retarded but had a poor academic record. His creatine kinase (CK) level was high (533 IU/mL [male >59, <248 IU/mL]), and his NCS revealed sensory dominant axonal neuropathy (median MNCV 40.3 m/sec, CMAP (compound motor action potential) 6.2 mV, SNAP (sensory nerve action potential) not evoked).

Family 3 (p.Glu289Lys)

The proband was a 40-year-old woman, and similar symptoms were observed in her mother, younger sister, and son, indicating autosomal dominant inheritance. Starting at 10 years of age, she had been falling frequently and had difficulty in running. At the age of 40 years, she developed severe muscle atrophy and weakness in her extremities and became wheelchair-bound. Her NCS results indicated CMT-intermediate type (median MNCV 38.0 m/sec, CMAP 2.5 mV, SNAP not evoked).

Family 4 (p.Phe583del)

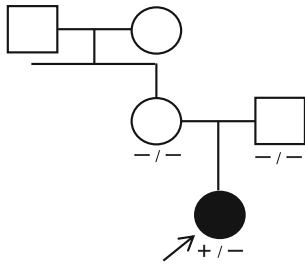
The proband was a 19-year-old girl with an autosomal dominant family history. She was referred to the hospital for hand atrophy, and physical examination revealed weakness and wasting of distal muscles, distal dominant sensory disturbance, and loss of tendon reflexes. Her intelligence quotient (IQ) was 71, which was at the borderline of mental function. High CK levels (1191 IU/mL) were observed, and her NCS indicated an axonal type (median MNCV 39.3 m/sec, CMAP 5.65 mV, SNAP 1.3 μ V).

Family 5 (p.Phe583del)

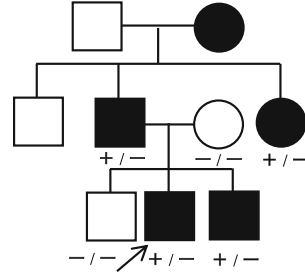
The proband was a 52-year-old woman with an autosomal dominant family history. She developed claudication after the age of 40, and her lower limb muscle weakness and gait disturbance worsened when she was 49. At 52 years of age, physical examination revealed distal dominant weakness and atrophy, as well as decreased vibration sensation. Her NCS indicated sensory dominant axonal neuropathy (median MNCV 53 m/sec, CMAP 5.5 mV, SNAP 4 μ V).

(A)

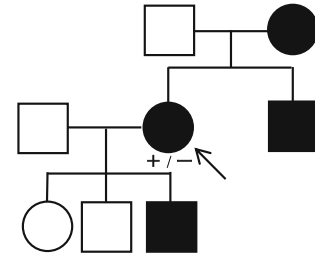
Family 1
c.620G>A, p.Arg207His



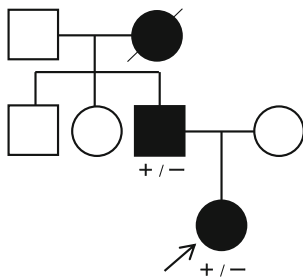
Family 2
c.865G>A, p.Glu289Lys



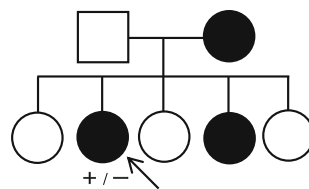
Family 3
c.865G>A, p.Glu289Lys



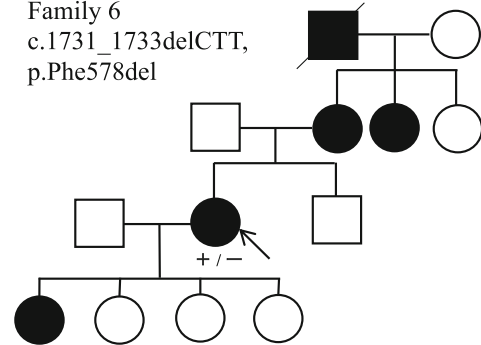
Family 4 c.1731_1733delCTT,
p.Phe578del



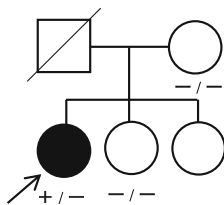
Family 5
c.1731_1733delCTT,
p.Phe578del



Family 6
c.1731_1733delCTT,
p.Phe578del



Family 7
c.2036A>C, p.Tyr679Ser



(B)

	207	289	578	679
KCC3-SLC12A6	L R L T W	G A I E I	S F F S T	F R Y Y H
KCC1-SLC12A4	L R L T W	G A I E I	S F F S T	F K Y Y H
KCC2-SLC12A5	L R L T W	G T I E I	S F F S T	F R Y Y H
KCC4-SLC12A7	L R L T W	G T I E I	S F F S T	F K F Y H
SLC12A6_Human	L R L T W	G A I E I	S F F S T	F R Y Y H
SLC12A6_Mouse	L R L T W	G A I E I	S F F S T	F R Y Y H
SLC12A6_Cat	L R L T W	G A I E I	S F F S T	F R Y Y H
SLC12A6_Dog	L R L T W	G A I E I	S F F S T	F R Y Y H
SLC12A6_Cow	L R L T W	G A I E I	S F F S T	F R Y Y H
SLC12A6_Frog	L R L P W	G A I E I	S F F S T	F H Y Y H

(C)

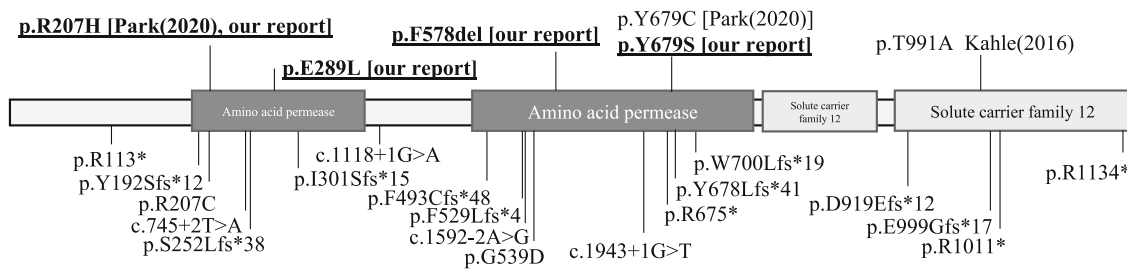


Figure 2. Genetic findings of seven families and variants review from literatures. (A) Seven families with *SLC12A6* heterozygous variants in our study. Arrows indicate proband. -: wild type, +: variant positive (B) The variant residues detected in our study are highly conserved in human KCC family members and across species. (C) Location of *SLC12A6* heterozygous and homozygous variants. Heterozygous variants are labeled above the protein, and variants detected in our study are underlined. Reported homozygous variants are labeled below the protein diagram.

Family 6 (p.Phe583del)

This family also has autosomal dominant history, and the proband was a 47-year-old woman. She has experienced lower limb muscle weakness since the age of 39. Physical examination revealed distal muscle weakness, muscle atrophy, and loss of tendon reflexes, but no sensory disturbance. Her NCS was an axonal type (median MNCV 54.5 m/sec, CMAP 5.4 mV), and no response was recorded on SNAP (SNAP).

Family 7 (p.Tyr679Ser)

The proband was a 26-year-old woman with no family history of neuromuscular disease. She was diagnosed with clubfoot at the age of three. Her motor function was low, and her academic record was poor. She developed epilepsy at the age of 12. Physical examination revealed weakness and wasting of distal muscles, decreased pinprick and vibration sensation, and loss of tendon reflexes. Her IQ was 46, indicating mild mental retardation. Based on her NCS, she was classified as a CMT-demyelinating type (right median MNCV 33.6 m/sec, CMAP 0.6 mV, SNAP 2.0 μ V and left median MNCV 25.1 m/sec, CMAP 0.2 mV, SNAP 1.0 μ V). Her brain MRI revealed frontal and temporal lobe atrophy, but no white matter or corpus callosum abnormalities were observed (Fig. 3). Sural nerve biopsy showed marked loss of myelinated nerve density and thinning myelin sheath, suggesting mixed axonal and demyelinating changes (Fig. S2).

Genetic findings

From seven unrelated families with CMT, we identified heterozygous variants in *SLC12A6*, including a previously reported variant (p.Arg207His) and three likely pathogenic variants (p.Glu289Lys, p.Phe578del, and p.Thr679Ser). Additionally, two other novel variants, p.Thr580Lys and p.Ser647Pro, were detected and classified as having uncertain significance due to a lack of agreement of their family members in segregation analysis. All these novel variants were absent in the public control databases and our in-house control database. We further evaluated the novel variants using six computational analyses (SIFT, POLYPHEN2, PROVEAN, Mutation Assessor, FATHMM, and Condel) and protein stability analyses (Dynamut and i-Mutant). All five novel missense variants were predicted to have a damaging effect in multiple analyses. However, the p.Phe578del variant could only be evaluated using PROVEAN, indicating a deleterious effect. All variants were also highly conserved across species and in other KCC family members, such as *SLC12A4*, *SLC12A5*, and *SLC12A7* (Fig. 2B). We reviewed and summarized the described *SLC12A6* heterozygous and homozygous variants in Figure 2C. Table 2 shows all the genetic findings and ACMG criteria.

Discussion

Using a series of high-throughput sequencing systems, we identified one previously reported (p.Arg207His) and three novel *SLC12A6* heterozygous variants (p.Glu289Lys,

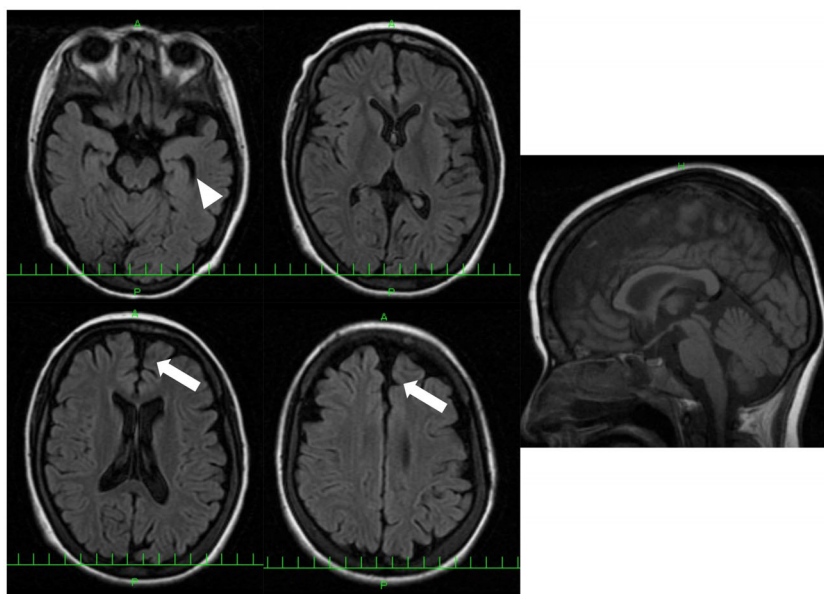


Figure 3. Brain MRI of patient 7 with p.Tyr679Ser variant. FLAIR images show frontal (arrow) and temporal lobe atrophy (arrow head). White matter change and corpus callosum change are not observed.

Table 2. Genetic findings and interpretation of *SLC12A6* heterozygous variants.

Nucleotide change	c.620G>A	c.865G>A	c.1731_1733del	c.2036A>C
Amino acid change	p.Arg207His	p.Glu289Lys	p.Phe578del	p.Tyr679Ser
Zygosity	Heterozygous	Heterozygous	Heterozygous	Heterozygous
Allele frequency-gnomAD	0	0	0	0
Allele frequency-jMorp	0	0	0	0
Our control	–	–	–	–
SIFT/prediction	0	Damaging	0	Damaging
PROVEAN/prediction	–4.57	Deleterious	–3.9	Deleterious
Polyphen2/prediction	0.998	Damaging	1	Damaging
MutationAssesor/prediction	4.025	Damaging	4.27	Damaging
FATHMM/prediction	–5.25	Damaging	–5.12	Damaging
Condel/prediction	0.73	Damaging	0.746	Damaging
Dynamut				
ΔΔG/prediction	–1.285 kcal/mol	Destabilizing	0.841 kcal/mol	Stabilizing
ΔΔG (ENCOM)/prediction	–0.127 kcal/mol	Destabilizing	–0.108 kcal/mol	Destabilizing
iMutant				
RI/stability	8	Decrease	0	Decrease
ACMG				
Population data	PS4_Supporting PM2	PS4_Supporting PM2	PS4_Moderate PM2	PS4_Supporting PM2
In sillico data	PP3	PP3		PP3
De novo/segregation data	PM6	PP1_Moderate	PP1	
Other data	PS3		PM4	PM5
Criteria	Pathogenic	Likely pathogenic	Likely pathogenic	Likely pathogenic

In silico analysis cut off: SIFT <0.05; PP2 >0.9; PROVEAN < –2.5; MA >1.9; FATHMM < –1.5; Condel >0.47.

p.Phe578del, and p.Thr679Ser) in seven patients from our large case series of Japanese patients with CMT. Their CMT phenotypes were diverse, including demyelinated, axonal, and intermediate types. Furthermore, various central nervous system (CNS) involvements were observed.

KCC3, which is encoded by *SLC12A6*, is expressed in both the CNS and peripheral nervous system.¹⁷ Loss of KCC3 function affects both the CNS and peripheral nervous system, with serious consequences manifesting as corpus callosum agenesis and severe sensorimotor neuropathy.¹⁰ In a previous report, patients with the de novo *SLC12A6* p.Thr991Ala heterozygous variant had early-onset and progressive motor-predominant axonal neuropathy without sensory neuropathic symptoms.¹¹ Since then, CMT patients with other mutations in *SLC12A6* (p.Arg207His heterozygous or p.Tyr679Cys heterozygous) have been reported.^{12,13} We summarized the clinical and electrophysiological findings from previous reports and our report (Table 1). In our report, the mean age of onset was 17.5 ± 16.1 years (range; 1–40), and the inheritance pattern was sporadic for two patients and autosomal dominant for the others. Patients with the p.Phe578del variant in *SLC12A6* developed CMT symptoms at an age later than that of other patients, indicating a less damaging effect.

Regarding electrophysiology, the median MNCV was 39.6 ± 9.5 m/sec (range 25.0–54.5) in our cases, not much different than previous reports of 34.7 ± 4.6 m/sec (range 31.0–41.8).^{11–13} CMT caused by *SLC12A6* heterozygous variants may be classified as demyelinating, axonal, or intermediate type. This is consistent with the mixed axonal and demyelinating changes in sural nerve pathology of patient 7 in this study. Therefore, genetic analysis of the *SLC12A6* gene should be considered in all types of CMT. Interestingly, we observed intellectual disability in three patients (42.9%). Patients 4 (IQ 71) and 6 (IQ 46) had their IQs confirmed. Patient 2 was also suspected of having mental retardation due to poor academic performance, but IQ was not confirmed. Additionally, the proband of family 7 was diagnosed with epilepsy (generalized tonic seizure). Park et al. reported a case with EEG abnormality but no convulsions.¹² More importantly, to the best of our knowledge, this is the first report of a CMT patient with a heterozygous *SLC12A6* variant developing brain atrophy. Actually, various CNS involvements have been described only in patients with biallelic *SLC12A6* variants until now. Our findings indicate that CMT with *SLC12A6* heterozygous variants may also affect the CNS, broadening the current phenotypic spectrum. Additionally, hyperCKemia has been observed

in multiple patients in our study and previous reports,¹³ which might also be a feature of *SLC12A6*-related CMT.

Standardized and accurate variant evaluation is essential for an effective genetic diagnosis. Therefore, disease-specific ACMG-AMP guidelines for consistent and accurate variant classification have been developed for several diseases. However, there are no specific ones for CMT. Therefore, we used the expert panel of RASopathy, another clinically and genetically heterogeneous disease, which is comparable to CMT, as a reference for the classification.¹⁸ The classification method is summarized in Table S2. All previously reported (p.Arg207His) and novel variants (p.Glu289Lys, p.Phe578del, and p.Thr679Ser) detected in our study were absent in the global, Japanese, and in-house databases (PM2; ACMG criteria). The p.Arg207His variant of family 1 was not found in her unaffected parents and thus was considered as *de novo* (PM6). Additionally, a functional study (PS3) revealed that this variant has a complete loss of function.¹² We classified this variant as pathogenic. Among the novel variants, the p.Glu289Lys variant was identified from two families (PS4-supporting) and was found co-segregated from multiple affected/unaffected family members of family 2 (PP1-moderate), and a deleterious effect was indicated by several *in silico* analyses (PP3). Whereas, p.Phe578del, detected in three probands (PS4-moderate), would produce a shorter protein (PM4). Otherwise, p.Tyr679Ser locates at the residue where another pathogenic variant (p.Tyr679Cys) has been reported (PM5).¹² Taken together, we interpreted these three novel variants as likely pathogenic.

Meanwhile, p.Thr580Lys and p.Ser647Pro were discovered in two families. Computational analysis revealed that they had deleterious effects and were highly conserved across species and in other KCC family members, such as *SLC12A4*, *SLC12A5*, and *SLC12A7* (Fig. S1). However, the segregation study was insufficient, and we were unable to perform functional studies due to technical and material limitations. As a result, we classified these two variants as having uncertain significance, and further studies are required to clarify their pathogenicity.

Conclusively, we described one previously reported and three novel *SLC12A6* heterozygous variants in Japanese CMT patients with/without CNS involvement. Mutation screening of *SLC12A6* should be considered in all patients with CMT, regardless of the clinical subtype. Our findings broaden the clinical spectrum of *SLC12A6* heterozygous variants, manifesting with motor and sensory polyneuropathies and CNS dysfunctions. In the clinic, it is recommended to pay more attention to CNS lesions, particularly in patients showing cognitive impairment and epilepsy.

Acknowledgments

The authors appreciate Tomoko Ohnishi at Kagoshima University, for her great technical assistance. The authors are supported by Enago (www.enago.jp) for reviewing the English in this report. We appreciate the Division of Gene Research, Research Support Centre, Kagoshima University, for the use of their facilities. This work was supported by Grants-in-Aid from the Research Committee of Ataxia, Health Labour Sciences Research Grant, the Ministry of Health, Labour and Welfare, Japan (201610002B). This research is also supported by the Research program for conquering intractable disease from Japan agency for Medical Research and development (AMED) (201442014A, 201442071A, 17929553) and JSPS KAKENHI Grant Numbers JP18H02742, JP20K16604, JP21K15702, JP21H02842.

Author Contributions

MA, YH, JY, and HT contributed to the concept and design of the study. MA, YH, JY, and AY contributed to the analysis and interpretation of data. MA and HT produced the first draft of the manuscript. All authors provided input into subsequent drafts and reviewed and approved the final version for submission.

Conflict of Interest

All authors declare that there is no conflict of interest.

References

1. Braathen GJ, Sand JC, Lobato A, Høyer H, Russell MB. Genetic epidemiology of Charcot-Marie-Tooth in the general population. *Eur J Neurol*. 2011;18:39-48.
2. Stojkovic T. Hereditary neuropathies: an update. *Rev Neurol (Paris)*. 2016;172(12):775-778.
3. Zuchner S, Mersiyanova IV, Muglia M, et al. Mutations in the mitochondrial GTPase mitofusin 2 cause Charcot-Marie-Tooth neuropathy type 2A. *Nat Genet*. 2004;36:449-451.
4. Polke JM, Laura M, Pareyson D, et al. Recessive axonal Charcot-Marie-Tooth disease due to compound heterozygous mitofusin 2 mutations. *Neurology*. 2011;77:168-173.
5. Baxter RV, Ben Othmane K, Rochelle JM, et al. Ganglioside-induced differentiation-associated protein-1 is mutant in Charcot-Marie-Tooth disease type 4A/8q21. *Nat Genet*. 2002;30:21-22.
6. Auranen M, Ylikallio E, Toppila J, Somer M, Kiuru-Enari S, Tyynismaa H. Dominant GDAP1 founder mutation is a common cause of axonal Charcot-Marie-Tooth disease in Finland. *Neurogenetics*. 2013;14:123-132.

7. Higuchi Y, Hashiguchi A, Yuan J, et al. Mutations in MME cause an autosomal-recessive Charcot-Marie-Tooth disease type 2. *Ann Neurol*. 2016;79:659-672.
8. Auer-Grumbach M, Toegel S, Schabhuettl M, et al. Rare variants in MME, encoding metalloprotease neprilysin, are linked to late-onset autosomal-dominant axonal polyneuropathies. *Am J Hum Genet*. 2016;99:607-623.
9. Gagnon KB, Delpire E. Molecular physiology of SPAK and OSR1: two Ste20-related protein kinases regulating ion transport. *Physiol Rev*. 2012;92:1577-1617.
10. Howard HC, Mount DB, Rochefort D, et al. The K-Cl cotransporter KCC3 is mutant in a severe peripheral neuropathy associated with agenesis of the corpus callosum. *Nat Genet*. 2002;32:384-392.
11. Kahle KT, Flores B, Bharucha-Goebel D, et al. Peripheral motor neuropathy is associated with defective kinase regulation of the KCC3 cotransporter. *Sci Signal*. 2016;9:ra77.
12. Park J, Flores BR, Scherer K, et al. *De novo* variants in *SLC12A6* cause sporadic early-onset progressive sensorimotor neuropathy. *J Med Genet*. 2020;57(4):283-288.
13. Shi J, Zhao F, Pang X, et al. Whole-exome sequencing identifies a heterozygous mutation in *SLC12A6* associated with hereditary sensory and motor neuropathy. *Neuromuscul Disord*. 2021;31(2):149-157.
14. Hashiguchi A, Higuchi Y, Nomura M, et al. Neurofilament light mutation causes hereditary motor and sensory neuropathy with pyramidal signs. *J Peripher Nerv Syst*. 2014;19:311-316.
15. Yoshimura A, Yuan JH, Hashiguchi A, et al. Genetic profile and onset features of 1005 patients with Charcot-Marie-Tooth disease in Japan. *J Neurol Neurosurg Psychiatry*. 2019;90:195-202.
16. Richards S, Aziz N, Bale S, et al. Standards and guidelines for the interpretation of sequence variants: a joint consensus recommendation of the American College of Medical Genetics and Genomics and the Association for Molecular Pathology. *Genet Med*. 2015;17:405-424.
17. Pearson MM, Lu J, Mount DB, Delpire E. Localization of the K(+)-Cl(-) cotransporter, KCC3, in the central and peripheral nervous systems: expression in the choroid plexus, large neurons and white matter tracts. *Neuroscience*. 2001;103:481-491.
18. Gelb BD, Cavé H, Dillon MW, et al. ClinGen's RASopathy Expert Panel consensus methods for variant interpretation. *Genet Med*. 2018;20:1334-1345.

Supporting Information

Additional supporting information may be found online in the Supporting Information section at the end of the article.

Figure S1. Clinical and genetic findings of variants of uncertain significance.

Figure S2. Sural nerve pathology from patient 7 (*SLC12A6* p.Tyr679Ser).

Table S1. CMT neuropathy score (CMTNS) of seven CMT probands with *SLC12A6* heterozygous variants.

Table S2. ACMG criterion of our report.

Data S1. Clinical summary of probands with variants of uncertain significance in *SLC12A6*.