



Esthesioneuroblastoma (Olfactory Neuroblastoma): Overview and Extent of Surgical Approach and Skull Base Resection

Emily E. Karp¹ Jamie J. Van Gompel^{1,2} Garret Choby^{1,2}

¹Department of Otolaryngology – Head & Neck Surgery, Mayo Clinic, Rochester, Minnesota, United States

²Department of Neurologic Surgery, Mayo Clinic, Rochester, Minnesota, United States

Address for correspondence Garret Choby, MD, Department of Otolaryngology – Head & Neck Surgery, Mayo Clinic, 200 First St SW, Rochester, MN 55905, United States (e-mail: Choby.Garret@mayo.edu).

J Neurol Surg Rep 2022;83:e80–e82.

Abstract

Esthesioneuroblastoma is a rare malignancy originating from the olfactory epithelium. Treatment consists of surgical resection with strong consideration for adjuvant treatment in advanced Kadish stage and high Hyams grade. In the modern era, overall outcomes for esthesioneuroblastoma are favorable compared with many other sinonasal malignancies with 5-year overall survival estimated to be 80%. When selecting the optimal surgical approach, the surgeon must consider the approach that will allow for a negative margin resection and adequate reconstruction. In appropriately selected patients, endoscopic outcomes appear at least equivalent to open approaches and unilateral endoscopic approach may be used in select olfactory preservation cases.

Keywords

- ▶ esthesioneuroblastoma
- ▶ endoscopic
- ▶ craniofacial resection
- ▶ olfactory
- ▶ neuroblastoma

Introduction

Esthesioneuroblastoma is a rare malignancy originating from the olfactory epithelium. Treatment consists of surgical resection with strong consideration for adjuvant treatment in advanced Kadish stage and high Hyams grade.^{1,2} In the modern era, overall outcomes for esthesioneuroblastoma are favorable compared with many other sinonasal malignancies with 5-year overall survival estimated to be 80%.^{2,3}

Case Presentation

A 48-year-old male presented with left-sided nasal obstruction. Magnetic resonance imaging demonstrated invasion of the anterior left cribriform plate into the inferior aspect of the anterior cranial vault, invasion of bilateral olfactory

bulbs, and slight extension laterally over the left orbit (▶ **Fig. 1A** and **B**). Workup demonstrated no regional or distant metastatic disease. This esthesioneuroblastoma was a modified Kadish stage C and Hyams grade 3. The patient underwent surgical resection with endoscopic bilateral craniofacial resection (CFR) (▶ **Fig. 2**), and margin negative resection was achieved. Reconstruction with pericranium, fascia lata, and extended nasoseptal flap was performed. He completed adjuvant radiation to the anterior skull base and disease free 3 years posttreatment.

Overview

Treatment of esthesioneuroblastoma is dependent on the extent of the tumor at presentation. Surgical resection is the mainstay of treatment with consideration for adjuvant radiation with or without chemotherapy.¹ In rare cases,

received
May 19, 2022
accepted
May 29, 2022

DOI <https://doi.org/10.1055/s-0042-1753519>.
ISSN 2193-6358.

© 2022. The Author(s).

This is an open access article published by Thieme under the terms of the Creative Commons Attribution-NonDerivative-NonCommercial-License, permitting copying and reproduction so long as the original work is given appropriate credit. Contents may not be used for commercial purposes, or adapted, remixed, transformed or built upon. (<https://creativecommons.org/licenses/by-nc-nd/4.0/>)

Georg Thieme Verlag KG, Rüdigerstraße 14, 70469 Stuttgart, Germany

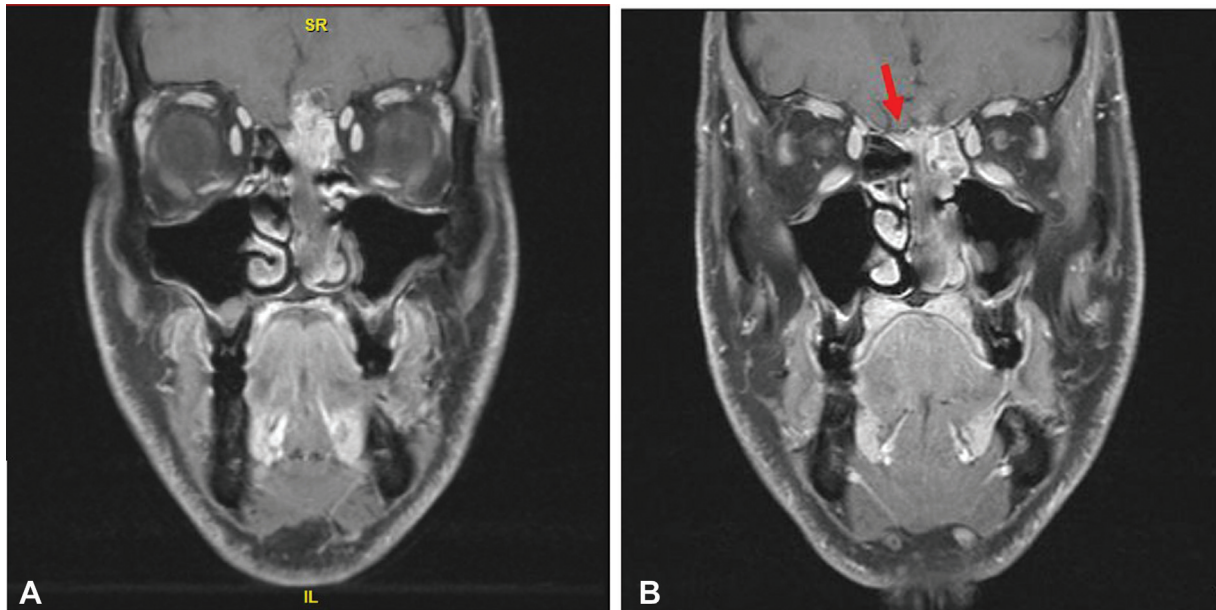


Fig. 1 (A) Case presentation of coronal magnetic resonance imaging, T1 postgadolinium. (B) Arrow indicates contralateral olfactory tract involvement.

induction chemotherapy may be indicated prior to definitive treatment for locally unresectable tumors.⁴

In the modern era, open CFR refers to bifrontal craniotomy combined with assistance from an endoscopic endonasal approach for intranasal tumor resection, margin sampling, and assistance with reconstruction. An open approach is often selected where negative margins are not achievable with endoscopic approaches such as extensive intracranial involvement, orbital invasion, lateral ex-

tent of tumor past mid-plane of the orbit, extension to the optic canal and cavernous sinus, or when there is tumor high in the frontal sinus.^{1,5} An open approach may also be selected when tumor involvement precludes intranasal reconstructive as it allows for direct dural repair with fascia lata and placement of pericranial flap for cranial base reconstruction.¹

In high-volume skull base centers, many tumors can be addressed with a completely transnasal endoscopic CFR with

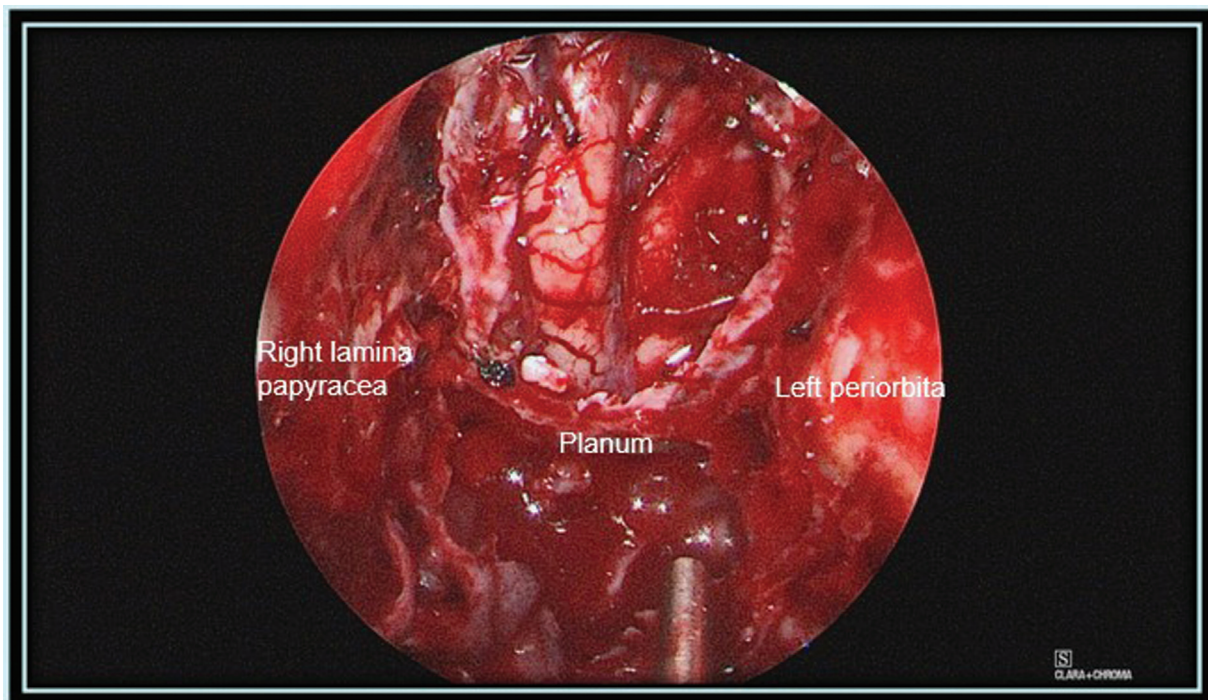


Fig. 2 Endoscopic bilateral craniofacial resection.

comparable outcomes to open approaches.^{1,5,6} Kadish stage A and B tumors can typically be managed completely endoscopically. Increasingly larger Kadish stage C tumors may be resected solely with an endoscopic approach with clear surgical margins and endoscopic reconstruction. Historical teaching includes resection of bilateral olfactory bulbs and tracts. However, modification of the traditional surgical extent for preserved olfaction may be considered using a unilateral endoscopic skull base resection.^{1,7–10} Unilateral endoscopic resection may be considered when high-quality preoperative imaging suggests no involvement of contralateral olfactory bulb or tract along with the assistance of intraoperative frozen section margin analysis to ensure complete resection.^{7,8}

Conclusion

Overall, esthesioneuroblastoma has favorable survival outcomes when compared with other sinonasal malignancies.^{2,3} When selecting the optimal surgical approach, the surgeon must consider the approach that will allow for a negative margin resection and adequate reconstruction. In appropriately selected patients, endoscopic outcomes appear at least equivalent to open approaches and unilateral endoscopic approach may be used in select olfactory preservation cases.

Conflict of Interest

None declared.

References

- 1 Wang EW, Zanation AM, Gardner PA, et al. ICAR: endoscopic skull-base surgery. *Int Forum Allergy Rhinol* 2019;9(S3):S145–S365
- 2 Lechner M, Takahashi Y, Turri-Zanoni M, et al. Clinical outcomes, Kadish-INSICA staging and therapeutic targeting of somatostatin receptor 2 in olfactory neuroblastoma. *Eur J Cancer* 2022;162:221–236
- 3 McMillian RA, Van Gompel JJ, Link MJ, et al. Long-term oncologic outcomes in esthesioneuroblastoma: an institutional experience of 143 patients. *Int Forum Allergy Rhinol* Published online April 6, 2022. Doi: 10.1002/ALR.23007
- 4 Miller KC, Marinelli JP, Janus JR, et al. Induction therapy prior to surgical resection for patients presenting with locally advanced esthesioneuroblastoma. *J Neurol Surg B Skull Base* 2021;82 (Suppl 3):e131–e137
- 5 Harvey RJ, Nalavenkata S, Sacks R, et al. Survival outcomes for stage-matched endoscopic and open resection of olfactory neuroblastoma. *Head Neck* 2017;39(12):2425–2432
- 6 Fu TS, Monteiro E, Muhanna N, Goldstein DP, de Almeida JR. Comparison of outcomes for open versus endoscopic approaches for olfactory neuroblastoma: a systematic review and individual participant data meta-analysis. *Head Neck* 2016;38(Suppl 1):E2306–E2316
- 7 Gompel JJV, Janus JR, Hughes JD, et al. Esthesioneuroblastoma and olfactory preservation: is it reasonable to attempt smell preservation? *J Neurol Surg B Skull Base* 2018;79(02):184–188
- 8 Tajudeen BA, Adappa ND, Kuan EC, et al. Smell preservation following endoscopic unilateral resection of esthesioneuroblastoma: a multi-institutional experience. *Int Forum Allergy Rhinol* 2016;6(10):1047–1050
- 9 Wessell A, Singh A, Litvack Z. Preservation of olfaction after unilateral endoscopic approach for resection of esthesioneuroblastoma. *J Neurol Surg Rep* 2014;75(01):e149–e153
- 10 Abiri A, et al. Postoperative protocols following endoscopic skull base surgery: An evidence based review with recommendation. *Int Forum Allergy Rhinol* 2022 PMID 35678720