

Hepatic Function Predictive Value of Hepatic Venous Waveform versus Portal Vein Velocity in Liver Cirrhosis

Chidiogo Chukwunweike Onwuka^{1*}, Olusola Comfort Famurewa², Olusegun Adekanle³, Oluwagbemiga Oluwole Ayoola², Olugbenga Olumide Adegbehingbe¹

¹Department of Radiology, ABUAD Multi System Hospital, Ado-Ekiti, Nigeria, ²Department of Radiology, Faculty of Clinical Sciences, Obafemi Awolowo University, Ile-Ife, Osun State, Nigeria, ³Department of Medicine, Obafemi Awolowo University Teaching Hospitals, Obafemi Awolowo University, Ile-Ife, Osun State, Nigeria

Abstract

Background: This study assessed the hepatic vein waveform (HVW) and mean maximum portal vein velocity (MM-PVV) on Doppler ultrasound in patients with liver cirrhosis (LC) and compared it with that of age and sex-matched controls. It correlated the degree of HVW abnormality and MM-PVV changes with liver function based on Child-Turcotte-Pugh (CTP) to determine which was more predictive of CTP. **Methods:** Sixty patients with LC and 60 healthy controls were consecutively recruited into this study. Each patient was classed based on the CTP system after relevant tests. Doppler evaluation of the hepatic vein (HV) and MM-PVV were performed. HVW obtained was classified either into triphasic, biphasic, or monophasic. **Results:** Sixty cirrhotic and 60 age-matched control subjects aged 19–69 and 18–69 years, respectively, completed this study. All control subjects had a normal HVW pattern while 46 (76.7%) cirrhotic subjects had abnormal HVW ($P < 0.001$). The MM-PVV was significantly lower in cirrhotic subjects than in controls; 22.8 cm/s versus 33.6 cm/s ($P < 0.001$). The degree of HVW abnormality among cirrhotics showed a significant positive correlation with CTP ($r = 0.283$, $P = 0.029$). MM-PVV on the other hand showed no correlation with CTP class ($r = -0.124$; $P = 0.346$). Linear regression showed that HVW was a significant predictor of hepatic dysfunction based on CTP. **Conclusion:** Changes in the waveform pattern of the HVs are a good predictor of the derangement of hepatic function in patients with LC than changes in PVV. HVW pattern could therefore serve as an adjunct to CTP class in hepatic function assessment.

Keywords: Hepatic vein waveform, liver cirrhosis, portal vein velocity, ultrasound

INTRODUCTION

There are several ways of assessing liver function in patients with liver cirrhosis (LC). Liver biopsy and histology though the gold standard are invasive, associated with risk of patient morbidity and mortality, and samples a small portion of the liver which may not represent an ongoing pathological process.^[1,2] In our environment, noninvasive clinical and biochemical methods are mainly used. These are computed into a scoring system known as Child-Turcotte-Pugh (CTP) score.^[3,4]

B-mode ultrasound is also used to follow-up patients with LC and to screen for malignant transformation. It, however, provides little information on hepatic function. Conversely, Doppler ultrasound demonstrates the hemodynamics of the portal venous system, hepatic artery, and veins, which reflect

hepatic functional status.^[2] Doppler indices commonly used for the evaluation of cirrhosis and portal hypertension include measurement of portal and splenic venous blood flow velocity and resistivity indices of splenic, hepatic, and superior mesenteric arteries. However, these indices are plagued by poor reproducibility and accuracy.^[5]

Doppler ultrasound of the hepatic vein (HV) has been suggested as an additional tool that will help to increase the diagnostic accuracy of these parameters.^[6,7] In healthy subjects, the hepatic vein waveform (HVW) is normally described as triphasic, although it has four components: a retrograde A-wave, an antegrade S-wave, a transitional

Address for correspondence: Dr. Chidiogo Chukwunweike Onwuka, Department of Radiology, ABUAD Multi System Hospital, Ado-Ekiti, Nigeria. E-mail: dronwuka@abuad.edu.ng

Received: 16-04-2021 Revised: 13-06-2021 Accepted: 22-07-2021 Available Online: 03-05-2022

Access this article online

Quick Response Code:



Website:
www.jmuonline.org

DOI:
10.4103/JMU.JMU_91_21

This is an open access journal, and articles are distributed under the terms of the Creative Commons Attribution-NonCommercial-ShareAlike 4.0 License, which allows others to remix, tweak, and build upon the work non-commercially, as long as appropriate credit is given and the new creations are licensed under the identical terms.

For reprints contact: WKHLRPMedknow_reprints@wolterskluwer.com

How to cite this article: Onwuka CC, Famurewa OC, Adekanle O, Ayoola OO, Adegbehingbe OO. Hepatic function predictive value of hepatic venous waveform versus portal vein velocity in liver cirrhosis. J Med Ultrasound 2022;30:109-15.

V wave (could be antegrade, retrograde, or neutral), and an antegrade D-wave corresponding to atrial contraction, ventricular systole, atrial overfilling, and opening of the tricuspid valve, respectively.^[8,9] Changes in the liver parenchyma impair the compliance of the wall of the HV resulting in the alteration of the normal phasic waveform. Initially, there is loss of the retrograde A-wave resulting in a biphasic waveform. With worsening fibrosis, complete loss of phasicity occurs with flattening of the waveform pattern.^[10]

This study aimed to evaluate the HVW of patients with LC using ultrasound in comparison with control subjects. The mean maximum portal vein velocity (MM-PVV) was also measured. Both parameters were compared independently with the severity of liver disease based on the CTP class, and then, an attempt was made to determine which of them was more predictive of liver disease.

SUBJECTS AND METHODS

This is a case-controlled, comparative nonrandomized study in which 60 study subjects, above the age of 18 years, with LC along with 60 healthy age and sex-matched control subjects were consecutively recruited over 12 months – from July 2017 to June 2018. This study was approved by our Institutional Review Board of Obafemi Awolowo University Teaching Hospitals Complex, Ile-Ife. (approval number: ERC/2017/01/02) Informed consent was obtained from all study subjects.

Diagnosis of LC was made based on a combination of typical clinical features and biochemical findings as well as typical B-mode ultrasound features such as shrunken liver size with irregular outline, ascites, and portal hypertension. The control group was comprised of apparently healthy adult volunteers or subjects who had no clinical signs and symptoms of liver or renal disease. Subjects with heart failure, HV or inferior vena cava (IVC) obstruction, hepatocellular carcinoma, or other liver masses were excluded.

Relevant biodata, history, and physical examination findings were obtained. The subjects' weight (kg) and height (M) were measured and were body mass index calculated. Hepatic encephalopathy was graded based on the West Haven Grading System from Grade 0 to Grade 4.^[11]

Venous blood was obtained from cirrhotic subjects following an overnight fast. Laboratory parameters that were done include liver function test, serum electrolytes, urea and creatinine, prothrombin time/international normalized ratio (INR), and serum albumin.

Sonographic assessment/technique

Patients and controls were scanned following an overnight fast of at least 6–8 h to reduce excess bowel gas that may obscure the vascular structures. Real-time US examinations were performed with a 3.5-MHz transducer (Toshiba Real-time Ultrasound scanner Model TUS-F30 with Doppler facilities) by the lead researcher.

With the patient in the supine position, B-mode ultrasound of the hepatic parenchyma was done first to assess the liver span, echogenicity, echotexture, and surface nodularity. Pulsed Doppler evaluation of HV was then performed in the transverse plane and the probe manipulated (either through an intercostal approach or a subcostal approach over the right hypochondrium), until the star-like confluence of the HVs to the IVC was visualized. The HV evaluation was done after nonforced (quiet) expiration.^[10,12] Doppler signals were, in general, obtained from the right^[5,13] or middle^[6,10] HVs at a distance of 3–6 cm from the junction of the HV and the IVC to increase the impact of hepatic parenchyma changes on the HVWs instead of the IVC flow.^[7] The left HV was not evaluated because the pulsatility within it is greater than that in the middle and right HVs,^[13,14] which can lead to flow artifacts of the Doppler sonographic signal.^[15] The HVW assessments were made on the lowest frequency range possible without aliasing. In addition, the lowest possible wall filter was utilized, the sample volume set at 2–5 mm, and angles of insonation <60°.

The HVW was classified into three groups according to the Doppler signal characteristics:

1. Type 0, triphasic waveform; the presence of a short phase of reversed flow
2. Type I, biphasic waveform; decreased amplitude of the phasic oscillations without the short phase of reversed flow
3. Type II, monophasic waveform; complete flat waveform [Figure 1].

The transverse diameter of the main PV was measured at its midpoint. The direction of flow was noted. The maximum velocity was measured using the same Doppler settings as described above. Three values of the maximum PVV were obtained and the average was taken to get the MM-PVV. To decrease the effect of respiration on the portal blood flow, measurements were obtained during a short time of breath-holding.^[16]

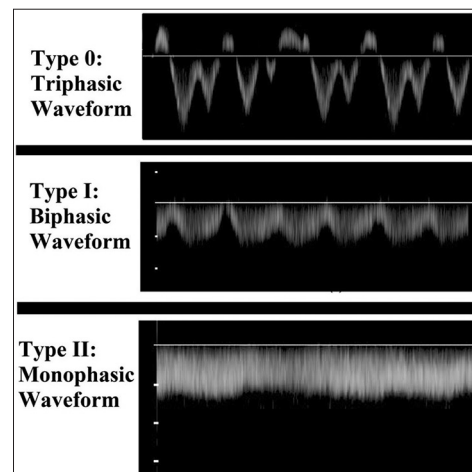


Figure 1: Spectral waveform of 3 cirrhotic study subjects showing the classification of hepatic vein waveform patterns

Other parameters taken were spleen span and the presence of ascites. Splenomegaly was defined as spleen span >12 cm.^[8] Ascites were graded according to Haktanir *et al.*^[17] criteria into 3 categories: Absent, mild, and moderate-to-severe.

For cirrhotic patients, disease severity was assessed using the CTP score, which took into account five conventional clinical (hepatic encephalopathy and ascites) and laboratory (albumin, prothrombin time, and bilirubin values) parameters.

Data and statistical analysis

The data obtained were analyzed using IBM Statistical Package for the Social Sciences (IBM SPSS Statistics for Windows, Version 21.0. Armonk, NY, USA). Differences in the distribution of various HVWs between control subjects and cirrhotic patients and among the various groups of cirrhotic patients were analyzed with the Chi-square (χ^2) or Fisher’s exact test as appropriate. Differences in the CTP ordinal score were analyzed with the χ^2 or Fisher’s exact test as appropriate for trend. To compare means, student’s *t*-test was performed. For multiple values, ANOVA was used. The Spearman correlation was used to analyze the relationship of CTP class with the changes in the HVW and MM-PVV. Linear regression was used to evaluate the degree of relationship between CTP class and the Doppler parameters, HVW and MM-PVV. The level of statistical significance was set at *P* < 0.05.

RESULTS

A total of 120 study subjects comprising 60 cirrhotic and 60 age- and-sex-matched healthy controls subjects completed this study. The distribution of cirrhotic subjects showed two age peaks; 40–49 and ≥60 years. The cirrhotic patients comprised 44 (73.3%) males and 16 (26.7%) females with a male-female ratio of 2.8:1.

Table 1 shows the Doppler characteristics of subjects and controls. There was a statistically significant difference between the HVW of cirrhotic subjects and controls. Abnormal HVW was present in 76.6% (46) of cirrhotic subjects [Figure 2]. All control subjects had triphasic HVW pattern.

The control subjects had a significantly higher MM-PVV than cirrhotic subjects [Table 1]. All control subjects had MM-PVV ≥15 cm/s while 23.3% of cirrhotic subjects had significantly reduced MM-PVV <15 cm/s. The cirrhotic patients had hepatopetal portal blood flow except for 2 subjects who demonstrated no flow in the PVs.

No significant relationship was noted between HVW and other ultrasound parameters MM-PVV, PV diameter, liver span, splenic span, and presence of ascites [Table 2]. MM-PVV showed a significant negative correlation with PV diameter [Table 3] with *r* = -0.272 and *P* = 0.035. It showed no correlation with liver span or splenic span. No relationship was also noted between MM-PVV and the presence or absence of ascites.

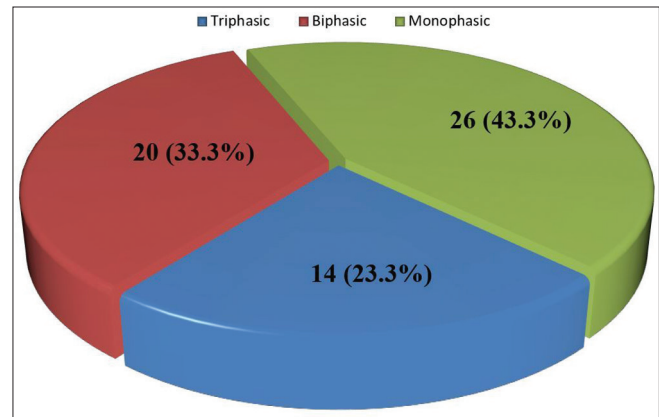


Figure 2: Pie chart showing the distribution of hepatic vein waveform in cirrhotic subjects

Variables	Cirrhotics (n=60)	Controls (n=60)	Statistics	df	P
HVW, n (%)					
Triphasic	14 (23.3)	60 (100)	86.931	2	<0.001*
Biphasic	20 (33.3)	0			
Monophasic	26 (43.4)	0			
PVD (cm)					
Mean±SD	1.30±0.25	0.94±0.18	9.319	118	<0.001#
Range	0.79-1.79	0.57-1.36			
n (%)					
Diameter <1.30	27 (45.0)	58 (96.7)	38.763	1	<0.001*
Diameter ≥1.30	33 (55.0)	2 (3.3)			
Portal vein velocity (cm/s)					
Mean±SD	22.8±10.4	33.6±11.1	-5.530	118	<0.001#
Range	0.0-44.0	15.3-70.2			
n (%)					
Velocity ≥15	46 (76.7)	60 (100)	15.894	1	<0.001*
Velocity <15	14 (23.3)	0 (0.0)			

*Chi-square/Fisher’s exact test statistic was used to compare proportions, #Independent samples *t*-test was used to compare means. PVD: Portal vein diameter, SD: Standard deviation, HVW: Hepatic vein waveform

Table 2: Association between hepatic vein waveform, other ultrasound, and biochemical parameters in cirrhotic subjects

Variables	Triphasic (n=14)	Biphasic (n=20)	Monophasic (n=26)	P
MM-PVV (cm/s) mean±SD	25.4±8.3	23.9±11.6	20.5±10.3	0.319 [#]
Velocity ≥15	13 (92.9)	16 (80.0)	17 (65.4)	0.134*
Velocity <15	1 (7.1)	4 (20.0)	9 (34.6)	
PVD (cm), mean±SD	1.3±0.2	1.2±0.3	1.4±0.3	0.211 [#]
Diameter <1.30	5 (35.7)	12 (60.0)	10 (38.5)	0.252*
Diameter ≥1.30	9 (64.3)	8 (40.0)	16 (61.5)	
Ascites, n (%)				
Absent	6 (42.9)	4 (20.0)	3 (11.5)	0.221*
Mild	1 (7.1)	4 (20.0)	5 (19.2)	
Moderate to severe	7 (14.3)	12 (30.0)	18 (19.2)	
Liver span (cm), mean±SD	11.6±1.6	13.0±2.7	11.9±2.4	0.185 [#]
Splenic span (cm), mean±SD	15.2±3.6	14.9±3.4	15.2±3.6	0.827 [#]
Span <12.0	3 (21.4)	4 (20.0)	4 (15.4)	0.836*
Span >12.5	11 (78.6)	16 (80.0)	22 (84.6)	
Bilirubin (µmol/l), mean±SD	42.5±26.9	36.5±22.2	54.5±33.0	0.101 [#]
Albumin (g/l), mean±SD	27.9±9.1	27.1±6.8	30.1±5.8	0.319 [#]
PT (s), mean±SD	17.5±3.2	17.4±3.4	18.9±3.6	0.266 [#]
INR, mean±SD	1.5±0.3	1.4±0.3	1.6±0.4	0.265 [#]
Na (mmol/l), mean±SD	129.9±6.1	125.0±22.8	130.9±5.4	0.346 [#]
K (mmol/l), mean±SD	3.6±0.5	3.8±0.5	3.9±0.6	0.405 [#]
Creatinine (µmol/l), mean±SD	84.6±15.3	86.2±20.0	82.6±19.6	0.814 [#]
Urea (mmol/l), mean±SD	5.5±2.3	6.1±2.5	7.3±4.0	0.212 [#]

*Chi-square/Fisher's exact test statistic was used to compare proportions, [#]One-way ANOVA was used to compare means. PVD: Portal vein diameter, PT: Prothrombin time, INR: International normalized ratio, SD: Standard deviation, MM-PVV: Mean maximum portal vein velocity

Table 3: Association between mean maximum portal vein velocity other ultrasound parameters and biochemical parameters

Variables	Statistics	P
PVD	-0.272*	0.035
Liver span	0.077*	0.559
Spleen span	-0.190*	0.147
Ascites, n (%)	0.962 [#]	0.388
Bilirubin (µmol/l)	0.116*	0.376
Albumin (g/l)	-0.092*	0.486
PT (s)	-0.176*	0.178
INR	-0.175*	0.182
Na (mmol/l)	0.157*	0.231
K (mmol/l)	-0.280*	0.030
Creatinine (µmol/l)	-0.087*	0.511
Urea (mmol/l)	-0.096*	0.468

*Pearson correlation coefficient, [#]One-way ANOVA. PVD: Portal vein diameter, PT: Prothrombin time, INR: International normalized ratio

HVW pattern did not show any significant correlation with serum bilirubin, albumin, creatinine, urea, sodium, and potassium levels [Table 2]. It was also unrelated to prothrombin time and INR.

Similarly, (MM-PVV) showed no correlation with serum bilirubin, albumin, creatinine, urea, and sodium levels [Table 3]. It, however, showed a significant negative correlation with serum potassium levels; $r = -0.280$ and $P = 0.030$.

Table 4 shows the distribution of CTP classes based on HVW. The proportion of subjects with triphasic waveform pattern in Class A was more than those in Classes B and C. Similarly, Class C had significantly more subjects with monophasic waveform than Classes A and B. HVW also showed a significant positive correlation with CTP class with $r = 0.283$ and $P = 0.029$. In contrast, no significant relationship or correlation is noted between MM-PVV and CTP class [Table 5].

On linear regression, HVW was a significant predictor of hepatic dysfunction based on CTP class. The regression equation was as follows: CTP class = $2.014 + 0.266 \times HVW$, $R^2 = 0.097$, $F = 6.252$, $P = 0.015$. PVV on the other hand was not a significant predictor of CTP class with $P = 0.496$ [Table 6].

DISCUSSION

This study showed normal triphasic hepatic venous waveform in all the control subjects. This was similar to the results from other studies.^[5,6,10,12,13,18,19] On the other hand, Shapiro *et al.*^[20] observed triphasic waveform in 90.7% of healthy subjects, while 9.3% had abnormal tracing. This may be attributable to technique since theirs was done under breath-hold which could lead to inadvertent Valsalva maneuver with consequent increased intraabdominal pressure and dampening of the tracing.^[8,9] Coulden *et al.*^[14] corroborated this in their study in which normal subjects with triphasic waveform had an absent reverse component of the waveform and subsequent progressive loss of pulsatility following increased intra-abdominal pressure.

Table 4: Relationship between hepatic vein waveform and Child-Pugh classes/scores

Variables	Triphasic (n=14)	Biphasic (n=20)	Monophasic (n=26)	Statistics	df	P
Child-Pugh class						
A	5 (35.7)	1 (5.0)	1 (3.8)	12.836*	4	0.012
B	4 (28.6)	12 (60.0)	10 (38.5)			
C	5 (35.7)	7 (35.0)	15 (57.7)			
-				r= 0.283**		0.029
Bilirubin score (µmol/l), n (%)						
<34	7 (50.0)	11 (55.0)	8 (30.8)	9.610*	4	0.048
34-50	3 (21.4)	6 (30.0)	3 (11.5)			
>50	4 (28.6)	3 (15.0)	15 (57.7)			
-				r=269**		0.037
Albumin score (g/l), n (%)						
>35	4 (28.6)	2 (10.0)	3 (11.5)	8.839*	4	0.065
30-35	4 (28.6)	5 (25.0)	15 (57.7)			
<30	6 (42.9)	13 (65.0)	8 (30.8)			
INR score, n (%)						
<1.7	11 (78.6)	16 (80.0)	16 (61.5)	3.060*	4	0.548
1.7-2.3	3 (21.4)	4 (20.0)	4 (34.6)			
>2.3	0	0	1 (3.8)			
Ascites score, n (%)						
None	6 (42.9)	4 (20.0)	3 (11.5)	5.715*	4	0.221
Mild	1 (7.1)	4 (20.0)	5 (19.2)			
Moderate-to-severe	7 (50.0)	12 (60.0)	18 (69.2)			
HE score, n (%)						
None	14 (100.0)	20 (100.0)	23 (88.5)	4.130*	2	0.127
Grade I - II	0	0	3 (11.5)			
Grade III - IV	0	0	0			

*Chi-square test statistic was used to compare proportions, #One-way ANOVA was used to compare means, **Spearman's rho correlation coefficient. HE: Hepatic encephalopathy, INR: International normalized ratio

Table 5: Relationship between mean maximum portal vein velocity and Child-Pugh classes/scores

Variables	Statistics	df	P
Child-Pugh class			
Class A versus B versus C	0.494#	2	0.613
Class A versus B	1.020*	31	0.315
Class A versus C	0.920*	32	0.364
Class B versus C	-0.043*	51	0.966
Total Child-Pugh score	-0.124**		0.346
Bilirubin score	0.198#	2	0.821
Albumin score	0.202	2	0.817
INR score	1.298#	2	0.281
Ascites score	0.962#	2	0.388
HE score	1.323#	1	0.255

*t-test was used to compare means, **Spearman rho correlation coefficient, #One-way ANOVA was used to compare means. HE: Hepatic encephalopathy, INR: International normalized ratio

In this study, 76.7% of cirrhotic subjects had abnormal HVW (33.3% biphasic and 43.3% monophasic), while 23.3% had normal (triphasic) waveform. This is comparable to that obtained in other studies.^[10,12,13,21] Sudhamshu *et al.*^[22] and Bolondi *et al.*,^[6] however, had lower values of 60%, 50%, and 50%, respectively, while Bhutto *et al.*^[23] and Baik *et al.*^[5] had higher values of 92.3% and 92.0%, respectively. The

reason for these differences is unclear although the breath-hold method employed by Bhutto *et al.* and Baik *et al.* might explain their higher values. Furthermore, Baik *et al.* recruited patients with both cirrhosis and a history of variceal bleeding; those with advanced disease. The etiology of cirrhosis might also account for these differences. For example, in the study by von Herbay *et al.*^[13] and Sudhamshu *et al.*,^[22] the major etiologic agent for cirrhosis was alcohol while hepatitis C virus infection was the main agent in the study by Bhutto *et al.*^[23] In contrast, hepatitis B virus infection is the main causative agent of cirrhosis in this environment.^[24,25]

Similar to results obtained in previous studies,^[10,12,21,23,26] this study revealed a significant difference in the HVW pattern between cirrhotic subjects and controls with a $P < 0.05$. The degree of HVW abnormality among cirrhotic subjects also showed a significant relationship with hepatic dysfunction based on CTP class as noted in other studies.^[6,23,27,28] In the study by Bhutto *et al.*, the proportion of monophasic waveform by class was 90%, 73.91%, and 50% for Classes C, B, and A, respectively, which differed from that in this study which was 57.7%, 38.5%, and 3.8%, respectively. On the other hand, in the study by Antil *et al.*, no patient in Class A had monophasic HVW while in Classes B and C, 33.3% and 87.0%, respectively, had monophasic HVW. The reason for these variations is unclear although the inhomogeneous

Table 6: Linear regression analysis of hepatic vein waveform and portal vein velocity versus Child–Pugh class

Dependent variable: Child-Pugh class						
	R^2	F	df	P	Constant	b1
Independent variable						
HVW	0.097	6.252	1	0.015	2.014	0.266
PVV	0.008	0.469	1	0.496	2.467	-0.006

PVV: Portal vein velocity, HVW: Hepatic vein waveform

affection of the hepatic parenchyma by the cirrhotic process may account for it.^[4] Comparable to findings by von Herbay *et al.*,^[13] this study showed a decreasing incidence of triphasic waveform pattern with increasing CTP class. Ohta *et al.*^[29] likewise observed that monophasic waveform correlated with high CTP score and poor survival rate. In contrast, Sudhamshu *et al.* in two separate studies^[22,30] and Joseph *et al.*^[26] did not demonstrate any relationship between CTP class and HVW. Monophasic waveform was rare in both studies by Sudhamshu *et al.* with only approximately 3% of subjects having monophasic HVW. His second study excluded subjects with hepatofugal portal blood flow secondary to large portosystemic shunts. This might likely have contributed to the rarity of monophasic waveform pattern in his studies since other studies have shown that loss of the normal triphasic pattern has high sensitivity in detecting large esophageal varices,^[26,27] which is a major portosystemic shunt. Although Joseph *et al.*^[26] did not make similar exclusion as Sudhamshu *et al.*, they excluded patients with acute variceal hemorrhage and patients who had undergone endoscopic variceal ligation or sclerotherapy. Second, HVW assessment in their study was done under breath-hold.

In the index study as in other studies, PVV was significantly lower in cirrhotic subjects than in controls.^[20,31-33] O'Donohue *et al.*^[21] on the other hand observed no significant difference in the PVV of cirrhotic subjects and controls. This difference might be accounted for by his smaller sample. Furthermore, the evaluation of the PVV in their study was done during normal respiration in contrast to this study in which it was obtained during a short time of breath-holding. Contrary to the findings in this study, Iwao *et al.*^[31] and Zironi *et al.*^[33] noted a significant difference in the mean PVV between each CTP class. Annet *et al.*^[32] and Kutlu *et al.*^[34] on the other hand did not observe any correlation between mean PVV and CTP score. The reason for this wide variability in results from studies on PV is not clearly understood. It has been attributed to various factors such as equipment and observer variability, postural changes, exercise, cardiac output, postprandial effects, and the presence of collateral pathways.^[8,21,35]

CONCLUSION

Changes in the waveform pattern of the HVs are a significant predictor of the presence of cirrhotic changes in the liver parenchyma. It also has significant relationship with the degree

of derangements in hepatic function based on CTP score. Although reduction of PVV is significantly more in cirrhotic patients than in controls, it correlates less with the degree of changes in hepatic function than changes in HVW.

Financial support and sponsorship

Nil.

Conflicts of interest

There are no conflicts of interest.

REFERENCES

- Macarini L, Stoppino LP. Radiologic assessment of liver fibrosis – Present and future. In: Practical Management of Chronic Viral Hepatitis. In Tech; 2013. p. 115-6. <https://www.intechopen.com/books/3312>.
- Goyal N, Jain N, Rachapalli V, Cochlin DL, Robinson M. Non-invasive evaluation of liver cirrhosis using ultrasound. *Clin Radiol* 2009;64:1056-66.
- Tsochatzis EA, Bosch J, Burroughs AK. Liver cirrhosis. *Lancet* 2014;383:1749-61.
- Schuppan D, Afdhal NH. Liver cirrhosis. *Lancet* 2008;371:838-51.
- Baik SK, Kim JW, Kim HS, Kwon SO, Kim YJ, Park JW, *et al.* Recent variceal bleeding: Doppler US hepatic vein waveform in assessment of severity of portal hypertension and vasoactive drug response. *Radiology* 2006;240:574-80.
- Bolondi L, Li Bassi S, Gaiani S, Zironi G, Benzi G, Santi V, *et al.* Liver cirrhosis: Changes of Doppler waveform of hepatic veins. *Radiology* 1991;178:513-6.
- Aubé C, Winkfield B, Oberti F, Vuillemin E, Rousselet MC, Caron C, *et al.* New Doppler ultrasound signs improve the non-invasive diagnosis of cirrhosis or severe liver fibrosis. *Eur J Gastroenterol Hepatol* 2004;16:743-51.
- Davis M, Chong WK. Doppler ultrasound of the liver, portal hypertension, and transjugular intrahepatic portosystemic shunts. *Ultrasound Clin* 2014;9:587-604.
- Scheinfeld MH, Bilali A, Koenigsberg M. Understanding the spectral Doppler waveform of the hepatic veins in health and disease. *Radiographics* 2009;29:2081-98.
- Colli A, Coccio M, Riva C, Martinez E, Prisco A, Pirola M, *et al.* Abnormalities of Doppler waveform of the hepatic veins in patients with chronic liver disease: Correlation with histologic findings. *AJR Am J Roentgenol* 1994;162:833-7.
- Ferenci P, Lockwood A, Mullen K, Tarter R, Weissenborn K, Blei AT. Hepatic encephalopathy – Definition, nomenclature, diagnosis, and quantification: Final report of the working party at the 11th World Congresses of Gastroenterology, Vienna, 1998. *Hepatology* 2002;35:716-21.
- Arda K, Ofelli M, Çalikoglu U, Olçer T, Cumhuri T. Hepatic vein Doppler waveform changes in early stage (Child-Pugh A) chronic parenchymal liver disease. *J Clin Ultrasound* 1997;25:15-9.
- von Herbay A, Frieling T, Häussinger D. Association between duplex Doppler sonographic flow pattern in right hepatic vein and various liver diseases. *J Clin Ultrasound* 2001;29:25-30.
- Coulden RA, Lomas DJ, Farman P, Britton PD. Doppler ultrasound of the hepatic veins: Normal appearances. *Clin Radiol* 1992;45:223-7.
- Dietrich CF, Lee JH, Gottschalk R, Herrmann G, Sarrazin C, Caspary WF, *et al.* Hepatic and portal vein flow pattern in correlation with intrahepatic fat deposition and liver histology in patients with chronic hepatitis C. *Am J Roentgenol* 1998;171:437-43.
- Iliopoulos P, Vlychou M, Karatza C, Yarmenitis SD, Repanti M, Tsamis I, *et al.* Ultrasonography in differentiation between chronic viral hepatitis and compensated early stage cirrhosis. *World J Gastroenterol* 2008;14:2072-9.
- Haktanir A, Cihan BS, Celenk C, Cihan S. Value of Doppler sonography in assessing the progression of chronic viral hepatitis and in the diagnosis and grading of cirrhosis. *J Ultrasound Med* 2005;24:311-21.
- Lo RH, Afif AM, Wang Y, Lau D, Ooi CC. A sonographic Doppler

- study of hepatic vein, portal vein and hepatic artery in liver cirrhosis: Correlation of hepatic haemodynamics and liver dysfunction. *Clin Radiol* 2012;67:S10.
19. Gorka W, Kagalwalla A, McParland BJ, Kagalwalla Y, al Zaben A. Diagnostic value of Doppler ultrasound in the assessment of liver cirrhosis in children: Histopathological correlation. *J Clin Ultrasound* 1996;24:287-95.
 20. Shapiro RS, Winsberg F, Maldjian C, Stancato-Pasik A. Variability of hepatic vein Doppler tracings in normal subjects. *J Ultrasound Med* 1993;12:701-3.
 21. O'Donohue J, Ng C, Catnach S, Farrant P, Williams R. Diagnostic value of Doppler assessment of the hepatic and portal vessels and ultrasound of the spleen in liver disease. *Eur J Gastroenterol Hepatol* 2004;16:147-55.
 22. Sudhamshu KC, Sharma D, Chataut SP. Hepatic vein waveforms in liver cirrhosis re-evaluated. *Hepatol Int* 2010;5:581-5.
 23. Bhutto AR, Abbasi A, Butt N, Khan A, Munir SM. Hepatic vein waveform in liver cirrhosis: Correlation with child's class and size of varices. *J Pak Med Assoc* 2012;62:794-7.
 24. Omuemu CE, Ndububa DA, Nnabuchi CV. Prevalence of hepatitis B surface antigen and anti-hepatitis C antibodies in chronic liver disease patients in a Nigerian Teaching Hospital. *J Med Res Pract* 2012;1:58-60.
 25. Musa BM, Bussell S, Borodo MM, Samaila AA, Femi OL. Prevalence of hepatitis B virus infection in Nigeria, 2000-2013: A systematic review and meta-analysis. *Niger J Clin Pract* 2015;18:163-72.
 26. Joseph T, Madhavan M, Devadas K, Ramakrishnannair VK. Doppler assessment of hepatic venous waves for predicting large varices in cirrhotic patients. *Saudi J Gastroenterol* 2011;17:36-9.
 27. Antil N, Sureka B, Mittal MK, Malik A, Gupta B, Thukral BB. Hepatic venous waveform, splenoportal and damping index in liver cirrhosis: Correlation with child pugh's score and oesophageal varices. *J Clin Diagn Res* 2016;10:C01-5.
 28. Abdallah TM, El Shelfa W, El-Sayed SB, Dawoud H. Hemodynamic changes of hepatic veins as predictors of large oesophageal varices in liver cirrhotic patients. *Afro Egypt J Infect Endem Dis* 2014;4:32-40.
 29. Ohta M, Hashizume M, Kawanaka H, Akazawa K, Tomikawa M, Higashi H, *et al.* Prognostic significance of hepatic vein waveform by Doppler ultrasonography in cirrhotic patients with portal hypertension. *Am J Gastroenterol* 1995;90:1853-7.
 30. Sudhamshu KC, Matsutani S, Maruyama H, Akiike T, Saisho H. Doppler study of hepatic vein in cirrhotic patients: Correlation with liver dysfunction and hepatic hemodynamics. *World J Gastroenterol* 2006;12:5853-8.
 31. Iwao T, Toyonaga A, Oho K, Tayama C, Masumoto H, Sakai T, *et al.* Value of Doppler ultrasound parameters of portal vein and hepatic artery in the diagnosis of cirrhosis and portal hypertension. *Am J Gastroenterol* 1997;92:1012-7.
 32. Annet L, Materne R, Danse E, Jamart J, Horsmans Y, Van Beers BE. Hepatic flow parameters measured with MR imaging and Doppler US: Correlations with degree of cirrhosis and portal hypertension. *Radiology* 2003;229:409-14.
 33. Zironi G, Gaiani S, Fenyves D, Rigamonti A, Bolondi L, Barbara L. Value of measurement of mean portal flow velocity by Doppler flowmetry in the diagnosis of portal hypertension. *J Hepatol* 1992;16:298-303.
 34. Kutlu R, Karaman I, Akbulut A, Baysal T, Sigirci A, Alkan A, *et al.* Quantitative Doppler evaluation of the splenoportal venous system in various stages of cirrhosis: Differences between right and left portal veins. *J Clin Ultrasound* 2002;30:537-43.
 35. Kok T, van der Jagt EJ, Haagsma EB, Bijleveld CM, Jansen PL, Boeve WJ. The value of Doppler ultrasound in cirrhosis and portal hypertension. *Scand J Gastroenterol Suppl* 1999;230:82-8.