



Since January 2020 Elsevier has created a COVID-19 resource centre with free information in English and Mandarin on the novel coronavirus COVID-19. The COVID-19 resource centre is hosted on Elsevier Connect, the company's public news and information website.

Elsevier hereby grants permission to make all its COVID-19-related research that is available on the COVID-19 resource centre - including this research content - immediately available in PubMed Central and other publicly funded repositories, such as the WHO COVID database with rights for unrestricted research re-use and analyses in any form or by any means with acknowledgement of the original source. These permissions are granted for free by Elsevier for as long as the COVID-19 resource centre remains active.

Case Report

# Severe encephalopathy associated with SARS-CoV-2 Omicron BA.1 variant infection in a neonate

Kenichi Tetsuhara<sup>a,\*</sup>, Satoshi Akamine<sup>b</sup>, Yoshie Matsubara<sup>b</sup>, Shunsuke Fujii<sup>a</sup>,  
Wataru Kashimada<sup>c</sup>, Kentaro Marutani<sup>a</sup>, Michiko Torio<sup>b,d</sup>, Yuya Morooka<sup>d</sup>,  
Nozomu Hanaoka<sup>e</sup>, Tsuguto Fujimoto<sup>e</sup>, Haruna Nakamura-Miwa<sup>f</sup>, Satoru Arai<sup>f</sup>,  
Keiko Tanaka-Taya<sup>f</sup>, Kenji Furuno<sup>d</sup>, Yumi Mizuno<sup>g</sup>, Ryutaro Kira<sup>b</sup>

<sup>a</sup> Department of Critical Care Medicine, Fukuoka Children's Hospital, Fukuoka, Japan

<sup>b</sup> Department of Pediatric Neurology, Fukuoka Children's Hospital, Fukuoka, Japan

<sup>c</sup> Department of Cardiology, Fukuoka Children's Hospital, Fukuoka, Japan

<sup>d</sup> Department of General Pediatrics and Interdisciplinary Medicine, Fukuoka Children's Hospital, Fukuoka, Japan

<sup>e</sup> Center for Emergency Preparedness and Response, National Institute of Infectious Diseases, Tokyo, Japan

<sup>f</sup> Center for Surveillance, Immunization, and Epidemiologic Research, National Institute of Infectious Diseases, Tokyo, Japan

<sup>g</sup> Department of Pediatric Infectious Disease and Immunology, Fukuoka Children's Hospital, Fukuoka, Japan

Received 18 April 2022; received in revised form 12 June 2022; accepted 27 June 2022

## Abstract

**Introduction:** The coronavirus disease 2019 (COVID-19), including the Omicron variant, is less severe in children than in adults. To date, there has been no detailed description of COVID-19-associated severe encephalopathy due to the Omicron variant during the neonatal and early infantile periods.

**Case presentation:** During the outbreak of the Omicron variant, a 29-day-old male presented with a pale and ill appearance. The patient was intubated for mechanical ventilation owing to recurrent apnea, which subsequently turned out to be a breath-holding that may have been caused by seizure. In addition, nonconvulsive status epilepticus was observed. Total duration of repetitive seizure activities was approximately 30 min per hour when seizures were most severe. Brain magnetic resonance imaging (MRI) on day 14 revealed extensive hyperintensity in the T2 sequence, hypointensity in the fluid-attenuated inversion recovery (FLAIR) sequence in the deep and subcortical white matter, and diffusion restriction in the corpus callosum. The Omicron BA.1 variant of the severe acute respiratory syndrome coronavirus 2 was detected in his respiratory sample. Follow-up MRI on day 45 revealed multiple cystic cavitations.

**Conclusion:** Although COVID-19 is not severe in most children, life-threatening conditions such as COVID-19-associated severe encephalopathy can occur during the neonatal and early infantile periods.

© 2022 The Japanese Society of Child Neurology Published by Elsevier B.V. All rights reserved.

**Keywords:** Coronavirus disease 2019 (COVID-19); Encephalomalacia; Neonate; Omicron variant; Severe encephalopathy

## 1. Introduction

The coronavirus disease 2019 (COVID-19) is less severe in children than in adults [1], although it is slightly

\* Corresponding author at: Fukuoka Children's Hospital, 5-1-1, Kashii-Teraha, Higashi-ku, Fukuoka City, Fukuoka 813-0017, Japan.  
E-mail address: ken-tetsuhara@mti.biglobe.ne.jp (K. Tetsuhara).

more severe in children under 1 year of age [2]. Neurological involvement occurs in 22–40% of children who require admission [3,4]. It is occasionally associated with life-threatening conditions, such as severe encephalopathy [3,5]. Little is known about COVID-19-associated encephalopathy during the neonatal and early infantile periods [6]. Herein, we report a case of a 28-day-old baby with COVID-19-associated severe encephalopathy caused by the Omicron variant of the severe acute respiratory syndrome coronavirus 2 (SARS-CoV-2).

## 2. Case presentation

A 28-day-old male experienced sneezing in January 2022 during the outbreak of the Omicron variant (day 1). The following day, he presented to the emergency department looking pale and ill. He was born at a gestational age of 37 weeks, with a birth weight of 3013 g and had an uneventful perinatal course. His newborn screening test, including lysosomal storage diseases, was negative. His mother's older brother who had epilepsy died at the age of 30 years due to unknown causes. The patient's parents were unvaccinated against SARS-CoV-2. His father had developed COVID-19 one day before admission.

On day 2, the patient appeared pale and ill. He developed apnea with bradycardia during ambulance transport. On arrival, his body weight was 3.7 kg, and his vital signs were as follows: respiratory rate of 58 bpm with oxygen saturation (SpO<sub>2</sub>) of 100% on room air, heart rate of 188 bpm, blood pressure of 98/72 mmHg, Glasgow Coma Scale score of E2V3M5, and axillary temperature of 36.3 °C. Physical examination revealed normal lung and heart sounds without increased respiratory effort and normal peripheral circulation. He developed apnea, and his SpO<sub>2</sub> dropped below 50%, which improved with skin stimulation. Point-of-care ultrasonography did not reveal congenital heart disease. Chest radiography did not reveal any lung consolidation or cardiac enlargement. Venous blood gas analysis revealed the following: pH, 7.30; carbon dioxide, 60.2 mmHg; bicarbonate, 29.9 mmol/L; and lactate, 1.4 mmol/L. Head computed tomography did not reveal any abnormalities, such as ischemic changes, brain edema, or hemorrhage. The laboratory findings were as follows: white blood cell count, 7790/mm<sup>3</sup>; neutrophil count, 69.2%; lymphocyte count, 17.8%; hemoglobin, 10.4 g/dL; platelet count, 474,000/mm<sup>3</sup>; lactate dehydrogenase, 231 U/L; C-reactive protein, <0.03 mg/dL; ferritin, 226 ng/mL; D-dimer, <0.5 µg/mL; and fibrinogen, 191 mg/dL (Table 1). SARS-CoV-2 was detected using a multiplex polymerase chain reaction (PCR) system (FilmArray™ Respiratory Panel 2.1 [BioFire Diagnostics, Utah, USA]). No other pathogens, including pertussis and respiratory syncytial virus, were detected. He was intubated due to recurrent apnea and

Table 1  
Laboratory findings.

	Day 2	Day 5	Day 11	Day 29
White blood cell, /mm <sup>3</sup>	7,790	2,530	4,700	12,380
Lactate dehydrogenase, U/L	231	178	653	196
C-reactive protein, mg/dL	<0.03	0.07	0.41	<0.03
Ferritin, ng/mL	226.8	276.8	1481.0	220.4
Procalcitonin, ng/mL	0.07			
D-dimer, µg/mL	<0.5	1.6	3.3	
Fibrinogen, mg/dL	191	150	163	
Serum IL-6, pg/mL		46.7		<1.5
CSF IL-6, pg/mL			11.8	

IL-6; interleukin 6, CSF; cerebrospinal fluid.

was admitted to the intensive care unit. We administered continuous midazolam for sedation. Cefotaxime and vancomycin were administered until the blood and urine cultures came out negative.

On day 3, the SpO<sub>2</sub> recurrently dropped down to 30% without bradycardia under mechanical ventilation. During hypoxemia, although the airway resistance did not increase, the static compliance decreased based on the ventilator measurements. Therefore, the apnea was considered to be caused by breath-holding and not by the absence of respiratory effort.

On day 4, continuous electroencephalography (cEEG) was started to differentiate seizure as the cause of breath holding. When breath-holding occurred, we immediately confirmed several times that no ictal pattern was observed on cEEG, and discontinued cEEG following a procedure on day 5. We administered a continuous neuromuscular blocking agent to suppress breath-holding, which was discontinued on day 5. Since we had to minimize the time spent in the patient's room where the cEEG was kept, we could not assess the EEG findings sufficiently. In the retrospective analysis, rhythmic spike or spike and wave complex of 1.5–2 Hz occurred mostly in the left hemisphere for several minutes at frequent intervals from day 4 (Fig. 1A–C). Total duration of repetitive seizure activities is approximately 30 min per hour when seizures were most severe (Fig. 1D). We could not confirm ictal pattern during breath-holding because the video did not show the SpO<sub>2</sub> monitor. From day 6, myoclonic movements occurred in the lower extremities several times per day. On day 7, after an episode of myoclonic movements in both lower limbs for a few seconds with conjugate eye deviation to the left, his SpO<sub>2</sub> transiently decreased to 50%. We resumed cEEG after suspecting seizure. We confirmed the ictal pattern on cEEG when myoclonic movements occurred (Fig. 1E), and subsequently increased the dosage of midazolam and administered phenobarbital. Consequently, breath-holding, hypoxemia, myoclonic movements, and seizures on EEG disappeared. We discontinued cEEG on day 9.

Cerebrospinal fluid examination on day 11 revealed a white blood cell count of 2 /µL, protein of 57 mg/dL,

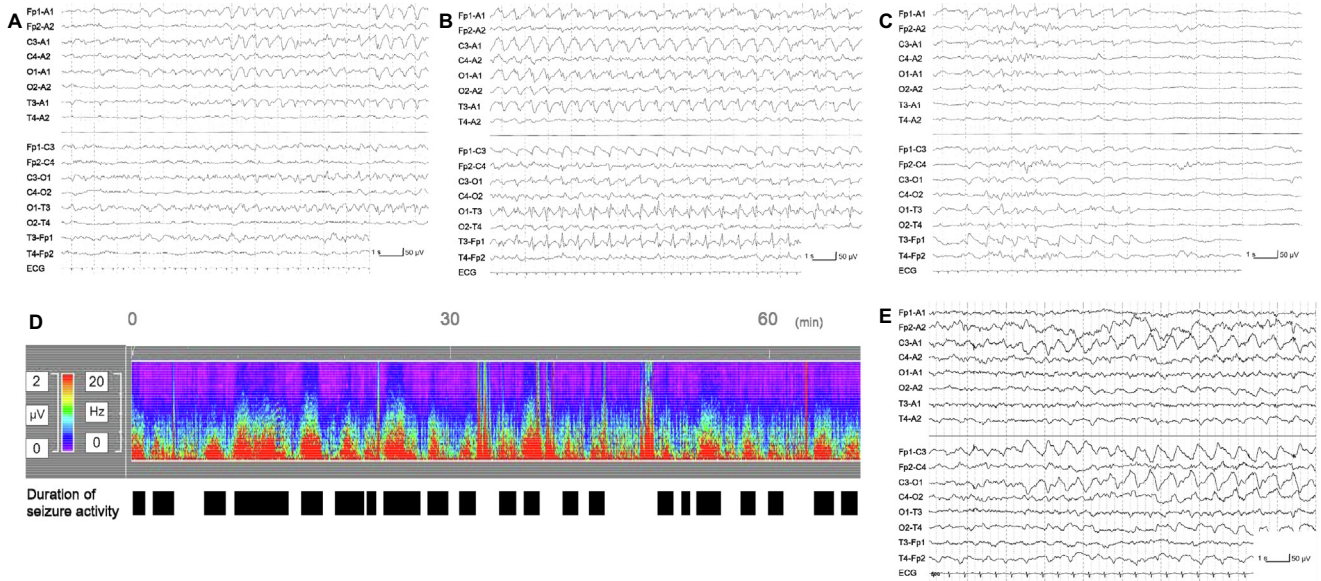


Fig. 1. Electroencephalogram during nonconvulsive status epilepticus (NCSE) on day 4 revealing ictal onset (A), rhythmic spike or spike and wave complex of 1.5–2 Hz occurring in the left hemisphere (B), and ictal termination (C). Density spectral array during NCSE on day 4 (D). Ictal pattern during myoclonic movement on day 7 (E).

and glucose of 72 mg/dL. The cultures were negative. Brain magnetic resonance imaging (MRI) on day 14 revealed hyperintensity on T2 and hypointensity on fluid-attenuated inversion recovery (FLAIR) sequence in the deep and subcortical white matter of the left frontal, bilateral temporal, and parietal lobes (Fig. 2A–C). In addition, it showed hyperintensity on the diffusion-weighted sequence and a decreased apparent diffusion coefficient value in the corpus callosum (Fig. 2D–E).

Finally, the patient was diagnosed with probable encephalitis due to the SARS-CoV-2 Omicron variant, following the diagnostic criteria for encephalitis by the International Encephalitis Consortium [7]. The metabolomic analysis using urine sample on day 8 (Japan Clinical Metabolomics Institute, Ishikawa, Japan) and the primary immunodeficiency panel (Kazusa DNA Research Institute, Chiba, Japan) were negative. We used comprehensive PCR methods (Fasttrack

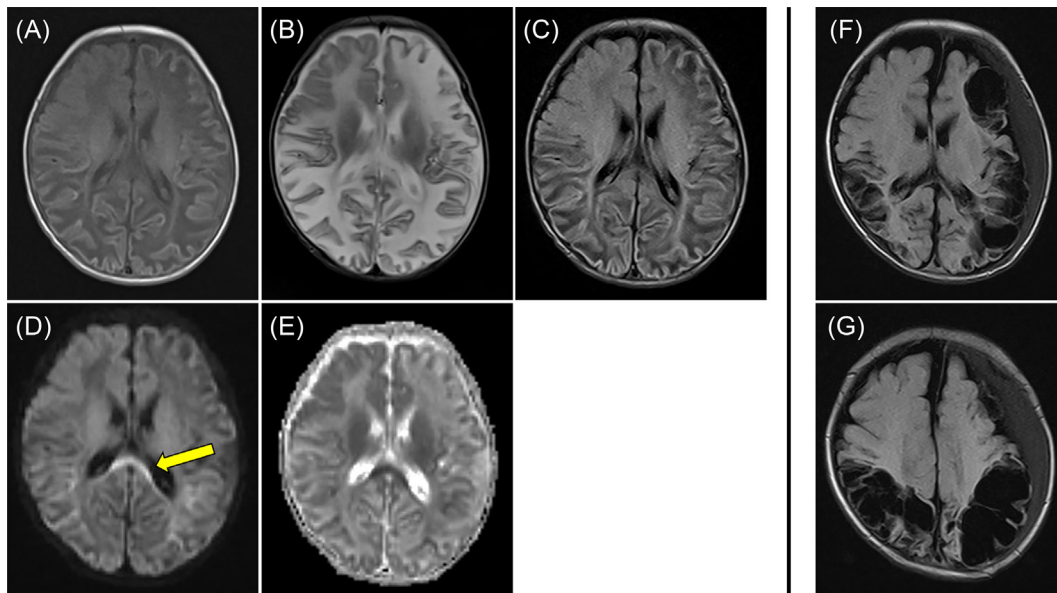


Fig. 2. Brain MRI on day 14 revealing hypo-intensity on T1 (A) and fluid-attenuated inversion recovery (C) sequence and hyper-intensity on T2 (B) in the deep and subcortical white matter of the left frontal, bilateral temporal to parietal lobes, and hyper-intensity on diffusion-weighted sequence (D) and decreased apparent diffusion coefficient value (E) in the corpus callosum (arrow). Fluid-attenuated inversion recovery sequence on day 45 revealing cystic cavitations in left cerebral hemisphere and right temporal, occipital, and parietal lobes and left epidural fluid accumulation (E, F).

DIAGNOSTICS [Riken genesis, Tokyo, Japan]; FTD respiratory pathogens 21, FTD fever and rash, FTD viral meningitis, and FTD viral gastroenteritis) that are highly sensitive for detecting 32 different viruses associated with acute encephalitis and encephalopathy, testing spinal fluid, whole blood, serum, plasma, pharyngeal swab, fecal, and urine samples. These clinical specimens were properly stored. Only the SARS-CoV-2 gene was detected in the nasopharyngeal and stool specimens, but not in the other specimens. The whole-genome sequence of SARS-CoV-2 revealed the Omicron BA.1 variant (Fukuoka City Institute of Health and Environment, Fukuoka, Japan). He was extubated on day 9, discharged from the intensive care unit on day 13, and discharged home on day 30 without special health care needs. Brain MRI on day 45 revealed multiple cystic cavitations in the left cerebral hemisphere, right temporal, occipital, and parietal lobes, as well as left epidural fluid accumulation (Fig. 2F-G). The basal ganglia and thalamus were intact.

### 3. Discussion

We describe a male with COVID-19-associated severe encephalopathy during neonatal and early infantile periods, who subsequently developed multiple cystic cavitations due to the Omicron BA.1 variant. Although there are case reports of COVID-19 encephalopathy with neuroimaging abnormalities in neonates [8], there have been no reports of COVID-19-associated encephalopathy during the neonatal and early infantile periods as severe as in this case. COVID-19 is less severe in children, especially within the Omicron predominance [1,9,10]. However, this could induce severe conditions.

Neurological involvement associated with COVID-19 varies, and abnormal findings on brain imaging include severe encephalitis with or without cytotoxic lesions of the callosal splenium, acute necrotizing encephalopathy, acute disseminated encephalomyelitis, posterior reversible encephalopathy syndrome, vasculitis, and infarction [3,11]. In the first MRI of this case, the hypointensity in the FLAIR sequence implies the encephalopathy in subacute phase. The corpus callosum can show residual cytotoxic edema due to infection [12]. Therefore, we consider that cytotoxic edema of the extensive white matter develops in the acute phase. This may represent the most severe form of COVID-19-associated encephalopathy.

The suggested pathophysiology of COVID-19-induced central nervous system (CNS) dysfunction is as follows: (1) invasion of SARS-CoV-2 from the olfactory tract or angiotensin-converting enzyme 2 receptor to the CNS induces the release of pro-inflammatory cytokines from microglia and astrocytes; (2) COVID-19 breaks the blood–brain barrier, causing the entry of peripheral cytokines into the CNS; and (3) COVID-19 induces oxidative stress and mitochondrial

dysfunction [13]. Corpus callosum lesions tend to develop in cytokinopathy because of the higher density of cytokines and glutamate receptors [12]. There are reports of corpus callosum lesions associated with SARS-CoV-2 infection in children, including multi-system inflammatory syndrome [14]. In this case, systemic inflammation, indicated by elevated ferritin or serum IL-6 level, was not severe and cerebrospinal fluid IL-6 in subacute phase was not high. Therefore, the encephalopathy may be due to the direct invasion of SARS-CoV-2, and vascular endothelial damage and/or localized cytokinopathy caused by COVID-19. Furthermore, we also noted cystic cavitations, which are caused by hypoxic-ischemic insults, toxic insults, infections, or metabolic disorders [15]. Encephalopathy with corpus callosum lesions associated with COVID-19, subsequently developing cystic cavitations, has also been reported [8]. In this case, ischemia could be caused by vascular endothelial damage. Hypoxia was unlikely because the findings did not reveal hypoxemia or shock sufficient to cause tissue hypoxia, the basal ganglia were intact, and cerebral abnormalities were asymmetrical on brain MRI. So far, we considered that encephalopathy was caused by COVID-19 in this case. However, congenital factors were not completely ruled out. Therefore, the possibility remains that COVID-19 could be a trigger for aggravating any underlying disease that was not known at that time.

Due to severe encephalopathy, the present patient developed nonconvulsive status epilepticus (NCSE) [16]. Although there are reports of adults with COVID-19-associated NCSE with a prevalence of approximately 5% [17], it remains unclear in children. However, there are reports of NCSE in children due to non-COVID-19 causes [18]. In critically ill children with encephalopathy, nonconvulsive seizures has a frequency of 7 to 47% [19], with neonates tending to develop NCSE. Because NCSE is associated with unfavorable outcomes and can only be detected by EEG, we should use EEG in children with COVID-19 at risk of NCSE, such as those with altered mental status and young age [19].

We considered that the patient had developed central apnea on admission, subsequently turned out to be a breath-holding by ventilator measurements. Infections can cause apnea in neonates. For example, respiratory syncytial virus infection has been proposed to cause apnea by disrupting the neural control pathway [20]. Apnea in children with COVID-19 has also been reported [6]. However, when the thorax stops moving, it may not be central apnea but breath-holding due to seizure. In this case, we could not indicate ictal pattern by EEG during breath holding, however, it was improved by phenobarbital, suggesting the possibility of breath-holding due to seizure.

In conclusion, although COVID-19 is not severe in most children, life-threatening conditions such as

COVID-19-associated severe encephalopathy can occur during the neonatal and early infantile periods.

### Declaration of Competing Interest

The authors declare that they have no known competing financial interests or personal relationships that could have appeared to influence the work reported in this paper.

### Acknowledgement

We thank the Fukuoka City Institute of Health and Environment (Fukuoka, Japan) for genetic analysis of SARS-CoV-2.

### Funding

This study was supported in part by a research grant from the Ministry of Health, Labour, and Welfare of Japan (19HA1002 to RK, TF and KT-T).

### Ethics statement

Written informed consent for the study and publication was obtained from the parents.

The research protocol was reviewed and approved by the medical research ethics committee of the National Institute of Infectious Diseases (NIID) for the use of human subjects (No. 965).

### Author contributions

K.T. and S.A. contributed to design the study, collect the data, draft the initial manuscript, and revise the manuscript; Y.M., S.F., W.K., K.M., M.T., Y.M., K. F., and Y.M. treated the patients and reviewed the manuscript; N.H., T.F., H.N-M., S.A., and K.T-T. collected data and reviewed the manuscript; R.K. contributed to design the work and critically review the manuscript and supervise the whole process; All authors approved the final manuscript as submitted and agree to be accountable for all aspects of the work.

### References

- [1] World Health Organization. COVID-19 disease in children and adolescents. published September 29, 2021. Published online 2021. <https://apps.who.int/iris/rest/bitstreams/1375120/retrieve>.
- [2] Swann OV, Holden KA, Turtle L, Pollock L, Fairfield CJ, Drake TM, et al. Clinical characteristics of children and young people admitted to hospital with covid-19 in United Kingdom: prospective multicentre observational cohort study. *BMJ*. 2020;370:m3249.
- [3] LaRovere KL, Riggs BJ, Poussaint TY, Young CC, Newhams MM, Maamari M, et al. Neurologic involvement in children and adolescents hospitalized in the United States for COVID-19 or multisystem inflammatory syndrome. *JAMA Neurol* 2021;78:536.
- [4] Fink EL, Robertson CL, Wainwright MS, Roa JD, Lovett ME, Stulce C, et al. Prevalence and risk factors of neurologic manifestations in hospitalized children diagnosed with acute SARS-CoV-2 or MIS-C. *Pediatr Neurol* 2022;128:33–44.
- [5] Ray STJ, Abdel-Mannan O, Sa M, Fuller C, Wood GK, Pysden K, et al. Neurological manifestations of SARS-CoV-2 infection in hospitalised children and adolescents in the UK: a prospective national cohort study. *Lancet Child Adolesc Health* 2021;5:631–41.
- [6] Mark EG, Golden WC, Gilmore MM, Sick-Samuels A, Curless MS, Nogee LM, et al. Community-onset severe acute respiratory syndrome coronavirus 2 infection in young infants: A systematic review. *J Pediatr* 2021;228:94–100.e3.
- [7] Venkatesan A, Tunkel AR, Bloch KC, Luring AS, Sejvar J, Bitnun A, et al. Case definitions, diagnostic algorithms, and priorities in encephalitis: consensus statement of the international encephalitis consortium. *Clin Infect Dis* 2013;57:1114–28.
- [8] Fragoso DC, Marx C, Dutra BG, da Silva CJ, da Silva PM, Martins Maia Junior AC, et al. COVID-19 as a Cause of Acute Neonatal Encephalitis and Cerebral Cytotoxic Edema. *Pediatr Infect Dis J* 2021;40:e270–1.
- [9] Iuliano AD, Brunkard JM, Boehmer TK, Peterson E, Adjei S, Binder AM, et al. Trends in disease severity and health care utilization during the early omicron variant period compared with previous SARS-CoV-2 high transmission periods - United States, December 2020–January 2022. *MMWR Morb Mortal Wkly Rep* 2022;71:146–52.
- [10] Wang L, Berger NA, Kaelber DC, Davis PB, Volkow ND, Xu R. COVID infection rates, clinical outcomes, and racial/ethnic and gender disparities before and after Omicron emerged in the US. medRxiv [Preprint]. [Posted 2022 February 22] Available from: <https://doi.org/10.1101/2022.02.21.22271300>.
- [11] Wong AM, Toh CH. Spectrum of neuroimaging mimics in children with COVID-19 infection. *Biomed J* 2021;S2319–4170:00151–7.
- [12] Aksu Uzunhan T, Maraş Genç H, Kutlubay B, Kalın S, Bektaş G, Yapıcı Ö, et al. Cytotoxic lesions of the corpus callosum in children: etiology, clinical and radiological features, and prognosis. *Brain Dev* 2021;43:919–30.
- [13] Nikbakht F, Mohammadkhanizadeh A, Mohammadi E. How does the COVID-19 cause seizure and epilepsy in patients? The potential mechanisms. *Mult Scler Relat Disord* 2020;46:102535.
- [14] Lindan CE, Mankad K, Ram D, Kociolek LK, Silvera VM, Boddaert N, et al. Neuroimaging manifestations in children with SARS-CoV-2 infection: a multinational, multicentre collaborative study. *Lancet Child Adolesc Health* 2021;5:167–77.
- [15] Armstrong DL, Halliday W, Hawkings C, Takashima S, editors. *Pediatric neuropathology: A text-atlas*. New York: Springer; 2007.
- [16] Hirsch LJ, Fong MWK, Leitinger M, LaRoche SM, Beniczky S, Abend NS, et al. American Clinical Neurophysiology Society's Standardized Critical Care EEG Terminology: 2021 Version. *J Clin Neurophysiol* 2021;38:1–29.
- [17] Lin L, Al-Faraj A, Ayub N, Bravo P, Das S, Ferlini L, et al. Electroencephalographic abnormalities are common in COVID-19 and are associated with outcomes. *Ann Neurol* 2021;89:872–83.
- [18] Greiner HM, Holland K, Leach JL, Horn PS, Hershey AD, Rose DF. Nonconvulsive status epilepticus: the encephalopathic pediatric patient. *Pediatrics* 2012;129:e748–55.
- [19] Wilson CA. Continuous electroencephalogram detection of non-convulsive seizures in the pediatric intensive care unit: review of the utility and impact on management and outcomes. *Transl Pediatr* 2015;4:283–9.
- [20] Bohmwald K, Espinoza JA, González PA, Bueno SM, Riedel CA, Kalergis AM. Central nervous system alterations caused by infection with the human respiratory syncytial virus. *Rev Med Virol* 2014;24:407–19.