




Since January 2020 Elsevier has created a COVID-19 resource centre with free information in English and Mandarin on the novel coronavirus COVID-19. The COVID-19 resource centre is hosted on Elsevier Connect, the company's public news and information website.

Elsevier hereby grants permission to make all its COVID-19-related research that is available on the COVID-19 resource centre - including this research content - immediately available in PubMed Central and other publicly funded repositories, such as the WHO COVID database with rights for unrestricted research re-use and analyses in any form or by any means with acknowledgement of the original source. These permissions are granted for free by Elsevier for as long as the COVID-19 resource centre remains active.



Short Communication

Myelin oligodendrocyte glycoprotein-IgG associated disorders (MOGAD) following SARS-CoV-2 infection: A case series

Jeffrey Lambe^a, Marisa P. McGinley^a, Brandon P. Moss^a, Yang Mao-Draayer^b, Roman Kassa^c, John R. Ciotti^d, Sara Mariotto^e, Amy Kunchok^{a,*}

^a Neurological Institute, Cleveland Clinic, Cleveland, OH, USA

^b Department of Neurology, Autoimmunity Center of Excellence, University of Michigan Medical Center, MI, USA

^c Department of Neurology and Rehabilitation Medicine, University of Cincinnati, Cincinnati, OH, USA

^d Department of Neurology, University of South Florida, Tampa, FL, USA

^e Neurology Unit, Department of Neurosciences, Biomedicine, and Movement Sciences, University of Verona, Verona, Italy



ARTICLE INFO

Keywords:

MOGAD
SARS-CoV-2
COVID-19
Transverse myelitis
Optic neuritis

ABSTRACT

This case series describes 9 patients diagnosed with myelin oligodendrocyte glycoprotein (MOG)-IgG associated disorder (MOGAD) following severe acute respiratory syndrome coronavirus 2 (SARS-CoV-2) infection. Patients developed neurological symptoms between 4 days and 5 weeks following SARS-CoV-2 infection. Myelitis was observed in 4 patients; 4 presented with optic neuritis; and encephalopathy was observed in 3. Serum MOG-IgG cell-based assay was medium or high positive in each case. The majority of patients had near-complete recovery following acute immunosuppression. This series adds to the growing number of cases of central nervous system demyelination following SARS-CoV-2 infection and highlights a potential role of infection in the immunopathogenesis of MOGAD.

1. Introduction

Neurological complications of severe acute respiratory syndrome coronavirus 2 (SARS-CoV-2) are increasingly recognized. Myelin oligodendrocyte glycoprotein (MOG)-IgG associated disorder (MOGAD) is a neuroinflammatory disorder predominantly affecting the optic nerves, brain, and spinal cord, a subset of which have a post-infectious history. (Marignier et al., 2021) Here we present 9 de novo cases of MOGAD post-SARS-CoV-2 infection.

2. Methods

Patients were individually identified from our respective neuroimmunology centers with a clinical phenotype of MOGAD and positive MOG-IgG within 6 weeks of SARS-CoV-2 infection. MOG-IgG antibodies were measured by fluorescence-activated cell sorting assay (FACS) for 6 patients, and MOG-IgG antibodies were measured by live cell-based

immunofluorescence assay (CBA) for 3 patients, as described elsewhere. (Mariotto et al., 2017; Waters et al., 2019) All patients provided informed consent.

3. Results

Clinical characteristics of patients are outlined in Table 1. Nine patients were identified (7 females, 2 males), with a median age of 44 (range 20–85) years.

3.1. SARS-CoV-2 infection

The median latency from SARS-CoV-2 infection to neurological symptom onset was 2 weeks (range 4 days–5 weeks). SARS-CoV-2 infection was non-severe in 8/9 patients; one had severe SARS-CoV-2-related pneumonia.

Abbreviations: CBA, cell-based assay; FLAIR, fluid attenuated inversion recovery; FACS, fluorescence-activated cell sorting; IVIg, intravenous immunoglobulin; IVMP, intravenous methylprednisolone; MOG, myelin oligodendrocyte glycoprotein; MOGAD, myelin oligodendrocyte glycoprotein-IgG associated disorder; MRI, magnetic resonance imaging; N/A, not available; OCBs, oligoclonal bands; ON, optic neuritis; PLEX, plasma exchange; SARS-CoV-2, severe acute respiratory syndrome coronavirus 2; VA, visual acuity; WBC, white blood cells.

* Corresponding author at: Mellen Center for Multiple Sclerosis Treatment and Research, Cleveland Clinic, 9500 Euclid Avenue, U-10, Cleveland, OH, USA.

E-mail address: kunchoa@ccf.org (A. Kunchok).

<https://doi.org/10.1016/j.jneuroim.2022.577933>

Received 2 May 2022; Received in revised form 3 July 2022; Accepted 12 July 2022

Available online 14 July 2022

0165-5728/© 2022 Elsevier B.V. All rights reserved.

Table 1
Characteristics of patients diagnosed with MOGAD following SARS-CoV-2 infection.

Case	Age (years)/ Gender	Comorbidities	SARS-CoV-2 Severity*	Latency**	Neurological presentation	MRI findings	CSF findings	MOG-IgG	Treatment	Outcome	Relapsing course	Follow-up time
1	21/ Female	None	Non-severe	11 days	Acute myelitis; Brainstem syndrome	T2 hyperintensity throughout cervical and thoracic spine, periaqueductal gray matter, pons, posterior corpus callosum (Fig. 1A-C)	WBC 108 cells/mm ³ , protein 38 mg/dL, glucose 77 mg/dL, OCBs absent	1:1000 †	IVMP for 5 days, PLEX for 5 sessions	Complete recovery	No	3 months
2	20/ Female	None	Non-severe	2 weeks	Acute myelitis; Encephalopathy	T2 hyperintensity throughout cervical spinal cord and conus; Diffuse, poorly demarcated cortical, periventricular and juxtacortical T2 hyperintensities also involving thalamus and brainstem (Fig. 1D-F)	WBC 144 cells/mm ³ , protein 45 mg/dL, glucose 45 mg/dL, no unique OCBs	1:2560 ‡	IVMP for 5 days, oral prednisone taper	Near-complete recovery (mild residual paraparesis)	No	1 month
3	30/ Female	Major depressive disorder	Non-severe	2 weeks	Acute myelitis	T2 hyperintensity throughout cervical spine (C2-C7), with heterogenous signal throughout the thoracic spine	WBC 68 cells/mm ³ , protein 46 mg/dL, glucose 55 mg/dL, OCBs absent	1:1000 †	IVMP for 5 days	Near-complete recovery (mild ataxia, mild sensory deficit)	No	18 months
4	36/ Female	Hypertension	Non-severe	3 weeks	Acute myelitis	No abnormalities	WBC 139 cells/mm ³ , protein 37 mg/dL, glucose 55 mg/dL, OCBs absent	1:1000 †	IVMP for 3 days, IVIg 2 g over 5 days, maintenance IVIg	Near-complete recovery (residual bladder dysfunction)	No	3 months
5	57/ Male	Parkinson's Disease	Non-severe	2 weeks	Left ON	Left optic nerve enhancement (anterior, with perineural sheath enhancement; Fig. 1H)	WBC 1 cells/mm ³ , protein 30 mg/dL, glucose 58 mg/dL, OCBs absent	1:320 †	Oral prednisone taper, maintenance IVIg	Complete recovery	No	5 months
6	73/ Female	Hypertension; type 2 diabetes mellitus; thyroiditis	Non-severe	5 weeks	Right ON	Right optic nerve T2 hyperintensity without contrast enhancement	N/A	1:5120 ‡	IVMP for 3 days, oral prednisone taper	Partial recovery (20/25 VA)	No	5 months
7	74/ Male	Type 2 diabetes mellitus; hypertension	Non-severe	4 days	Bilateral ON	Bilateral (left > right) optic nerve enhancement (anterior; Fig. 1I)	WBC 2 cells/mm ³ , protein 53 mg/dL, glucose 105 mg/dL, OCBs absent	1:100 †	IVMP for 3 days	Complete recovery	No	12 months
8	44/ Female	None	Non-severe	3 weeks	Encephalopathy; Bilateral ON	Diffuse, poorly demarcated cortical/subcortical T2 hyperintensities in the bilateral parietal lobes	WBC 63 cells/mm ³ , protein 61 mg/dL, glucose 66 mg/dL	1:100 †	IVMP for 5 days, PLEX for 5 sessions	Complete recovery	No	8 months
9	85/ Female	Hypertension	Severe	2 weeks	Encephalopathy; Seizures	Diffuse, poorly demarcated bilateral cortical/subcortical hyperintensities (Fig. 1G)	WBC 2 cells/mm ³ , protein 45 mg/dL, glucose 50 mg/dL, OCBs absent	1:2560 ‡	IVMP, ceftriaxone, acyclovir	Death (severe SARS-CoV-2)	No	3 weeks

CSF = cerebrospinal fluid; IVIg = intravenous immunoglobulin; IVMP = intravenous methylprednisolone; MOG = myelin oligodendrocyte glycoprotein; MOGAD = myelin oligodendrocyte glycoprotein-IgG1 associated disorder; MRI = magnetic resonance imaging; N/A = not available; OCBs = oligoclonal bands; ON = optic neuritis; PLEX = plasma exchange; SARS-CoV-2 = severe acute respiratory syndrome coronavirus 2; VA = visual acuity; WBC = white blood cells.

* All patients tested positive by nasopharyngeal polymerase chain reaction.

** Latency = time from SARS-CoV-2 infection to onset of neurological symptoms.

† MOG-IgG1 quantified by fluorescence-activated cell sorting assay.

‡ MOG-IgG quantified by live cell-based immunofluorescence assay.

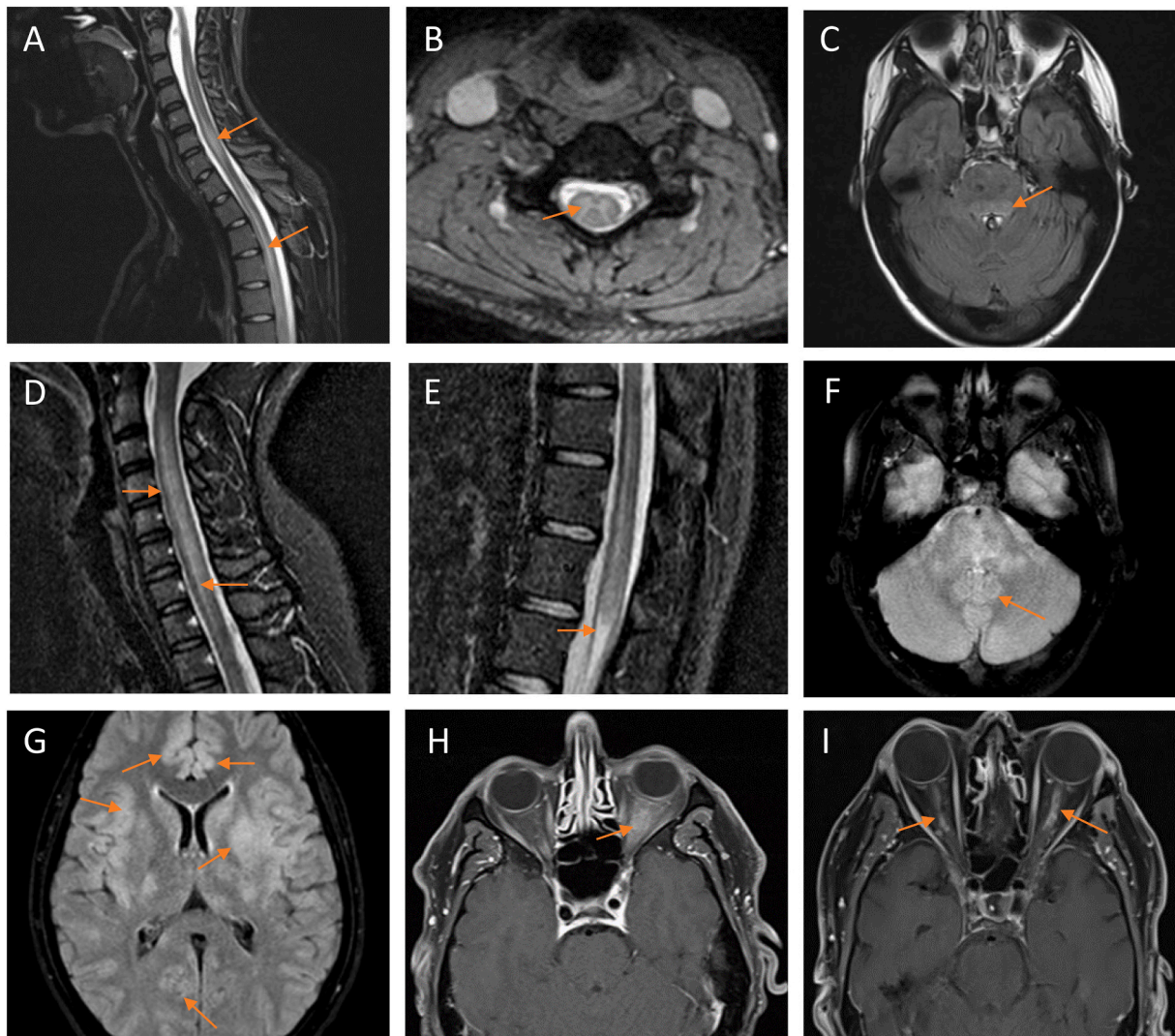


Fig. 1. MRI findings.

Patient #1 (A–C) exhibited longitudinally extensive T2-weighted hyperintensities in the cervical and thoracic spine on sagittal short-tau inversion recovery (STIR; A) and axial (B) sequences, and T2-weighted fluid-attenuated inversion recovery (FLAIR) hyperintensities on axial sequences in the periaqueductal gray matter/pons (C). Patient #2 (D–F) similarly demonstrated longitudinally extensive T2-weighted hyperintensities in the cervical spine (D) and conus medullaris (E) on sagittal STIR sequences, and T2-weighted FLAIR hyperintensities in the brainstem on axial sequences (F). Patient #9 exhibited diffuse, poorly demarcated bilateral cortical and juxtacortical T2-weighted FLAIR hyperintensities (G). Patient #5 demonstrated T1-weighted thickening and contrast-enhancement of the anterior segment of the left optic nerve and nerve sheath on axial sequences (H). Patient #7 exhibited T1-weighted contrast-enhancement of the anterior segment of the optic nerves bilaterally (left greater than right) on axial sequences (I).

3.2. Clinical and MRI features

Optic neuritis (ON) was observed in 4 patients (unilateral [2], bilateral [2]). Myelitis was observed in 4. Encephalopathy/encephalitis was observed in 3, of whom 1 developed status epilepticus. One patient experienced a brainstem attack with nausea, vertigo, and multidirectional nystagmus.

Magnetic resonance imaging (MRI) spine features of myelitis included non-enhancing, longitudinally extensive T2 hyperintensities (Fig. 1A–B and 1D–E). MRI brain lesions were observed in 4 patients, including T2 hyperintensity in the periaqueductal gray matter and brainstem (Fig. 1C and F), cortex and juxtacortical regions (Fig. 1G), and other subcortical regions including the parietal lobes and caudate nucleus. MRI features of ON included anterior-predominant contrast-enhancement with perineural sheath enhancement of >50% of the length of the optic nerves (Fig. 1H–I).

3.3. Cerebrospinal fluid and serology

Cerebrospinal fluid analyses were performed in 8/9 patients. White blood cell count was elevated among 5/8 with a median of 65.5 (elevated range 63–144) cells/mm³. Oligoclonal bands were absent (7/8) or matched (1). Serum MOG-IgG titers ranged from 1:100–1:1000; FACS [6], and 1:2560–1:5120; live CBA [3]. All patients were negative for serum aquaporin-4-IgG.

3.4. Treatment and outcomes

All patients were initially treated with corticosteroids (intravenous methylprednisolone [8], high-dose oral prednisone [1]). Two patients received plasma exchange, and 1 received intravenous immunoglobulin (IVIg) acutely. Two patients received maintenance IVIg. The majority (7/9) of patients exhibited complete or near-complete recovery at a median follow-up of 5 months (range 23 days–18 months). No patients had a relapsing course. One patient with seizures died of severe SARS-

Table 2
Characteristics of previously described adult patients diagnosed with MOGAD following SARS-CoV-2 infection.

Case report	Age (years)/ Gender	Comorbidities	SARS-CoV-2 Severity*	Latency**	Neurological presentation	MRI findings	CSF findings	MOG-IgG	Treatment	Outcome	Relapsing course	Follow-up time
Zhou et al., 2020	26/ Male	None	Non-severe	2 days	Bilateral ON; acute myelitis	Bilateral optic nerve enhancement (globe to pre-chiasm); patchy contrast-enhancing hyperintensities in lower cervical and upper thoracic spinal cord	WBC 55 cells/mm ³ , protein 31 mg/dL, glucose 57 mg/dL, no unique OCBs	1:1000†	IVMP for 5 days, oral prednisone taper	Partial recovery (residual 20/30 VA bilaterally)	No	3 weeks
Sawalha et al., 2020	44/ Male	None	Non-severe	14 days	Bilateral ON	Bilateral optic nerve enhancement (pre-chiasm)	WBC 3 cells/mm ³ , protein 50 mg/dL, glucose 88 mg/dL, OCBs absent	1:160‡	IVMP for 5 days, oral prednisone taper	Near-complete recovery (right eye impaired VA)	No	5 days
Kogure et al., 2021	47/ Male	Right adrenal resection; recurrent sinusitis	Non-severe	2 days	Left ON	Bilateral (left>right) optic nerve contrast enhancement	Reportedly normal WBC, normal protein, SARS-CoV-2 PCR negative	1:128‡	IVMP for 3 days	Partial recovery (left eye residual VA 20/160)	No	2 weeks
Durovic et al., 2021	22/ Male	None	Non-severe	3 days	Meningism	Cortical T2 hyperintensities without contrast enhancement	WBC 31 cells/mm ³ , protein 40 mg/dL, glucose 64 mg/dL, SARS-CoV-2 PCR negative	1:640‡	IVMP for 5 days	Complete recovery	No	2 months
Peters et al., 2021	23/ Male	Childhood non-febrile seizures	Non-severe	0–14 days	Seizures; encephalopathy	Diffuse left-hemispheric cortical FLAIR hyperintensity with left hemispheric leptomeningeal enhancement	WBC 57 cells/mm ³ , protein 40 mg/dL, glucose 60 mg/dL, OCBs absent, SARS-CoV-2 PCR negative	1:100‡	IVMP for 5 days, oral prednisone taper	Near-complete recovery (residual cognitive impairment)	No	8 weeks

CSF = cerebrospinal fluid; FLAIR = fluid attenuated inversion recovery; IVMP = intravenous methylprednisolone; MOG = myelin oligodendrocyte glycoprotein; MOGAD = myelin oligodendrocyte glycoprotein-IgG1 associated disorder; MRI = magnetic resonance imaging; OCBs = oligoclonal bands; ON = optic neuritis; PLEX = plasma exchange; SARS-CoV-2 = severe acute respiratory syndrome coronavirus 2; VA = visual acuity; WBC = white blood cells.

* All patients tested positive by nasopharyngeal polymerase chain reaction.

** Latency = time from SARS-CoV-2 infection to onset of neurological symptoms.

† MOG-IgG1 quantified by fluorescence-activated cell sorting assay.

‡ MOG-IgG quantified by live cell-based immunofluorescence assay.

§ Method of MOG-IgG quantification not stated.

CoV-2 pneumonia.

4. Discussion

Here we describe 9 de novo MOGAD attacks that developed post-SARS-CoV-2 infection with typical clinical and radiological features and good recovery. To date, few cases of MOGAD following SARS-CoV-2 infection have been reported. Similar to the patients in this series, cases described have generally been young or middle-aged, with mild SARS-CoV-2 severity, presenting with features typical of MOGAD (ON, myelitis and brain involvement). Latency period from SARS-CoV-2 infection to development of neurological symptoms ranged from several days to weeks, with generally good recovery and no clinical/radiologic relapses over limited follow-up periods ranging from several days to 2 months (Table 2). (Durovic et al., 2021; Kogure et al., 2021; Peters et al., 2021; Sawalha et al., 2020; Zhou et al., 2020).

Several pathophysiological mechanisms of SARS-CoV-2-related CNS inflammatory disorders have been proposed, including direct viral neuroinvasion, cytokine-induced CNS inflammation, hypercoagulability, and/or hypoxia. (Durovic et al., 2021; Kogure et al., 2021) MOG-IgG antibodies are postulated to cause demyelination through various mechanisms, including antibody-dependent cytotoxicity and encephalitogenic T-cells. (Marignier et al., 2021).

In our cases, SARS-CoV-2 infection was generally non-severe, suggesting that viral-mediated cytokine storming and/or systemic inflammation are unlikely to underpin the development of MOGAD. The temporal relationship observed between SARS-CoV-2 infection and MOGAD may suggest an autoimmune or inflammatory para-infectious or post-infectious phenomenon, with viral triggering of autoantibodies to CNS antigens. While the global incidence of MOGAD since the beginning of the SARS-CoV-2 pandemic remains unknown, there are reports of increased detection of MOGAD by some neuroimmunological laboratories. (Mariotto et al., 2022) However, to date there has been a relative paucity of reported cases of MOGAD following SARS-CoV-2 infection, suggesting that clinicians have not observed a significant rise in the incidence of MOGAD during this time. Differences in the host response to SARS-CoV-2 may explain why only a small subgroup of individuals develop MOGAD following infection. Viral infection and a subsequent immune-mediated phenomenon may trigger an initial clinical event in individuals that have a predilection towards developing MOGAD, potentially due to underlying immune dysregulation or genetic susceptibility. This hypothesis is supported by observations of MOGAD occurring in a subset of patients following viral infections, including herpes simplex virus, Epstein-Barr virus, and Borrelia. (Marignier et al., 2021) The diversity of these potential triggers further supports a host-mediated response, rather than factors specific to a particular inciting pathogen. Potential mechanisms may include molecular mimicry (as outlined by Vojdani and Kharrazian, 2020), bystander activation, epitope spreading, and B-cell receptor-mediated co-capture of antigens,

among others. (Marignier et al., 2021; Vojdani and Kharrazian, 2020).

5. Conclusions

We present a series of 9 patients diagnosed with MOGAD in the period following SARS-CoV-2 infection. These cases highlight a potential role of infection in the immunopathogenesis of MOGAD. Further studies are needed to evaluate whether the incidence of MOGAD has increased during the SARS-CoV-2 pandemic, and to elucidate whether host or disease factors may contribute to this association.

References

- Durovic, E., Bien, C., Bien, C.G., Isenmann, S., 2021. MOG antibody-associated encephalitis secondary to Covid-19: case report. *BMC Neurol.* 21, 414. <https://doi.org/10.1186/s12883-021-02449-5>.
- Kogure, C., Kikushima, W., Fukuda, Y., Hasebe, Y., Takahashi, T., Shibuya, T., Sakurada, Y., Kashiwagi, K., 2021. Myelin oligodendrocyte glycoprotein antibody-associated optic neuritis in a COVID-19 patient: a case report. *Medicine (Baltimore)* 100, e25865. <https://doi.org/10.1097/MD.00000000000025865>.
- Marignier, R., Hachohen, Y., Cobo-Calvo, A., Pröbstel, A.-K., Aktas, O., Alexopoulos, H., Amato, M.-P., Asgari, N., Banwell, B., Bennett, J., Brilot, F., Capobianco, M., Chitnis, T., Ciccarelli, O., Deiva, K., De Sèze, J., Fujihara, K., Jacob, A., Kim, H.J., Kleiter, I., Lassmann, H., Leite, M.-I., Linington, C., Meinl, E., Palace, J., Paul, F., Petzold, A., Pittock, S., Reindl, M., Sato, D.K., Selmaj, K., Siva, A., Stankoff, B., Tintore, M., Traboulsee, A., Waters, P., Waubant, E., Weinschenker, B., Derfuss, T., Vukusic, S., Hemmer, B., 2021. Myelin-oligodendrocyte glycoprotein antibody-associated disease. *Lancet Neurol.* 20, 762–772. [https://doi.org/10.1016/S1474-4422\(21\)00218-0](https://doi.org/10.1016/S1474-4422(21)00218-0).
- Mariotto, S., Ferrari, S., Monaco, S., Benedetti, M.D., Schanda, K., Alberti, D., Farinazzo, A., Capra, R., Mancinelli, C., De Rossi, N., Bombardi, R., Zuliani, L., Zoccarato, M., Tanel, R., Bonora, A., Turatti, M., Calabrese, M., Polo, A., Pavone, A., Grazian, L., Sechi, G., Sechi, E., Urso, D., Delogu, R., Janes, F., Deotto, L., Cadaldini, M., Bianchi, M.R., Cantalupo, G., Reindl, M., Gajofatto, A., 2017. Clinical spectrum and IgG subclass analysis of anti-myelin oligodendrocyte glycoprotein antibody-associated syndromes: a multicenter study. *J. Neurol.* 264, 2420–2430. <https://doi.org/10.1007/s00415-017-8635-4>.
- Mariotto, S., Carta, S., Dinoto, A., Lippi, G., Salvagno, G.L., Masin, L., Alberti, D., Marignier, R., Ferrari, S., 2022. Is there a correlation between MOG-associated disorder and SARS-CoV-2 infection? *Eur. J. Neurol. ene.15304* <https://doi.org/10.1111/ene.15304>.
- Peters, J., Alhasan, S., Vogels, C.B.F., Grubaugh, N.D., Farhadian, S., Longbrake, E.E., 2021. MOG-associated encephalitis following SARS-CoV-2 infection. *Mult. Scler. Relat. Disord.* 50, 102857 <https://doi.org/10.1016/j.msard.2021.102857>.
- Sawalha, K., Adeodokun, S., Kamoga, G.-R., 2020. COVID-19-induced acute bilateral optic neuritis. *J. Investig. Med. High Impact Case Rep.* 8 <https://doi.org/10.1177/2324709620976018>, 2324709620976018.
- Vojdani, A., Kharrazian, D., 2020. Potential antigenic cross-reactivity between SARS-CoV-2 and human tissue with a possible link to an increase in autoimmune diseases. *Clin. Immunol.* 217, 108480 <https://doi.org/10.1016/j.clim.2020.108480>.
- Waters, P.J., Komorowski, L., Woodhall, M., Lederer, S., Majed, M., Fryer, J., Mills, J., Flanagan, E.P., Irani, S.R., Kunchok, A.C., McKeon, A., Pittock, S.J., 2019. A multicenter comparison of MOG-IgG cell-based assays. *Neurology*. <https://doi.org/10.1212/WNL.0000000000007096>.
- Zhou, S., Jones-Lopez, E.C., Soneji, D.J., Azevedo, C.J., Patel, V.R., 2020. Myelin oligodendrocyte glycoprotein antibody-associated optic neuritis and myelitis in COVID-19. *J. Neuroophthalmol.* 40, 398–402. <https://doi.org/10.1097/WNO.0000000000001049>.