

# Tracheal Hamartoma: A Case Report

Carlos A. Ortega<sup>1</sup> , Brandon I. Esianor, MD<sup>2</sup> ,  
 James S. Lewis Jr., MD<sup>2,3</sup>, and Sarah L. Rohde, MD, MMHC<sup>2</sup>

OTO Open  
 2022, Vol. 6(3) 1–5  
 © The Authors 2022  
 Article reuse guidelines:  
[sagepub.com/journals-permissions](http://sagepub.com/journals-permissions)  
 DOI: 10.1177/2473974X221108696  
<http://oto-open.org>  


## Keywords

tracheal hamartoma, benign tracheal mass, tracheal neoplasm

Received March 22, 2022; accepted May 9, 2022.

Hamartomas are benign tumors that contain a mixture of cell types appropriate for the tissue of origin but in abnormal amounts, patterns, and distributions.<sup>1</sup> Pulmonary hamartomas are the most common benign neoplasm of the lungs, with a reported incidence of 0.025% to 0.032% in adults.<sup>2</sup> Among all tracheobronchial hamartomas, only 1.4% are endobronchial, while tracheal hamartomas are much rarer, with fewer than 30 cases documented in the literature.<sup>3</sup> In this report, we review the clinical management of an adult patient with an incidental tracheal hamartoma discovered during routine lung screening.

## Case Report

Approval was obtained from Vanderbilt University Medical Center Institutional Review Board (#212158). This study adheres and incorporates CARE case report guidelines.

A 69-year-old man with a 30-pack-year smoking history underwent routine lung cancer screening with a low-dose computed tomography (CT) chest scan. The patient reported no family history of cancers. Imaging demonstrated a 1.2-cm mass along the left tracheal wall at the level of the thoracic inlet (**Figure 1**). Serial imaging was performed at 3-month and 6-month intervals without appreciable change in the appearance of the mass. An otolaryngology referral was made due to the possibility of malignancy given the patient's smoking history. He presented to our clinic 14 months following the initial diagnosis without complaints of shortness of breath, wheezing, stridor, cough, difficulty swallowing, or hoarseness. We reviewed options of continued imaging surveillance vs endoscopic excision; the patient opted for surgery. Direct laryngoscopy was performed with a Dedo laryngoscope in the setting of intermittent endotracheal intubation. A 0-degree Hopkins rod endoscope was used for visualization. We identified the intraluminal mass projecting from the left lateral posterior aspect of the first tracheal ring (**Figure 1**) and performed near-total resection using a variety of forceps and suction. Specimens were sent for permanent pathology. They demonstrated a polypoid, benign cartilaginous, fibrous tumor

covered by surface epithelium with squamous metaplasia consistent with a tracheal (chondroid) hamartoma (**Figure 1**). A repeat CT scan performed at 1-year follow-up did not reveal evidence of recurrence. The interval was selected due to the slow growth of tracheal hamartomas.

## Discussion

Primary tracheal tumors are rare, with a reported incidence of 2.6 per 1,000,000 people. In adults, only 10% are benign, while 70% to 90% are benign in children.<sup>4</sup> The differential for benign neoplasms of the trachea includes squamous papilloma, salivary pleomorphic adenoma, mucous gland adenoma, oncocytoma, hamartoma, and leiomyoma.<sup>4</sup> Tracheal hamartomas are composed of a mixture of cells in an abnormal distribution and have not been shown to exhibit malignant transformation potential. There have been fewer than 30 reported cases of tracheal hamartomas (**Table 1**). Compared to pulmonary hamartomas, tracheal hamartomas are usually symptomatic secondary to intraluminal obstruction in the proximal airway. Shortness of breath and dyspnea are the most common presenting symptoms. Less common symptoms include stridor, cough, and chest pain. The overlap in symptoms with obstructive airway diseases may delay diagnosis, as demonstrated by 10 of 27 (37%) previous cases of tracheal hamartomas diagnosed initially as asthma.

Tracheal hamartomas may first be identified on CT scans of the neck or chest. Direct visualization requires endoscopic evaluation, at which time a biopsy can be performed to obtain a tissue diagnosis. In the literature, the average reported pathological or radiographical size of tracheal hamartomas is approximately 2 cm, ranging from 0.5 to 3.0 cm (**Table 1**). Routine surveillance is acceptable for patients with a confirmed diagnosis and lack of symptoms. Surgery is the

<sup>1</sup>Vanderbilt University School of Medicine, Nashville, Tennessee, USA

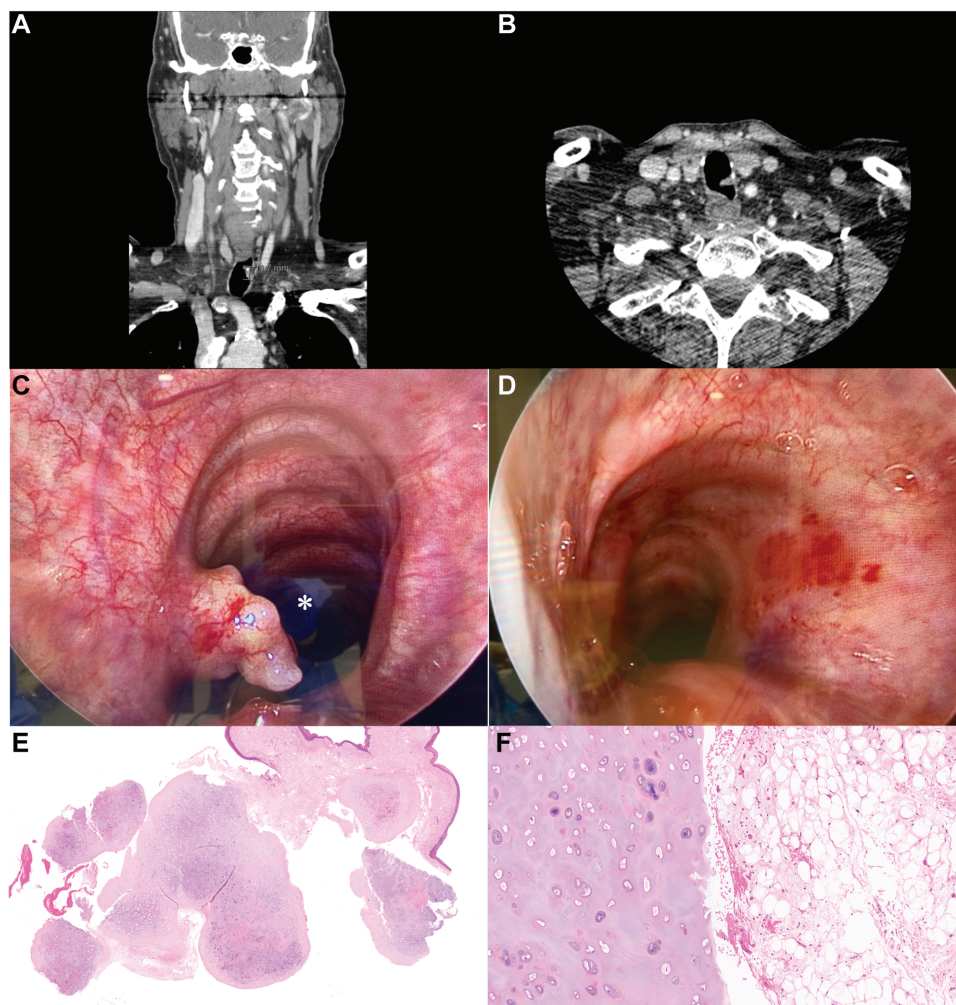
<sup>2</sup>Department of Otolaryngology–Head and Neck Surgery, Vanderbilt University Medical Center, Nashville, Tennessee, USA

<sup>3</sup>Department of Pathology, Microbiology, and Immunology, Vanderbilt University Medical Center, Nashville, Tennessee, USA

## Corresponding Author:

Brandon I. Esianor, MD, Department of Otolaryngology–Head and Neck Surgery, Vanderbilt University Medical Center, 1215 21st Avenue South, 7209 Medical Center East South Tower, Nashville, TN 37232-8605, USA.  
 Email: [brandon.esianor@vumc.org](mailto:brandon.esianor@vumc.org)





**Figure I.** (A) Coronal and (B) axial computed tomography images showing a 1.2-cm endotracheal tumor. (C) Mass visualized on direct tracheoscopy.\* (D) Post-resection. (E) Specimen on medium power (4 $\times$ ) and (F) higher power (10 $\times$ ). \*Reflection artifact present.

**Table I.** Case Reports of Tracheal Hamartomas.

Article (author, year published)	Age (y), sex	Symptoms or diagnosis	Surgery/procedure	Size, cm
Hamartoma of the trachea. Report of a case, with a review of the literature of benign trachea neoplasms (Engelking, 1959) <sup>5</sup>	51, M	Asthma	Tracheotomy, morcellation	NR
Tracheo-bronchial and pulmonary chondro-adenoma (hamartoma) (Perry, 1959) <sup>6</sup>	50, M	Asthma	Tracheostomy, submucosal resection	NR
Tracheal hamartoma (Hurst, 1977) <sup>7</sup>	75, M	Chronic cough, wheezing	Thoracotomy, segmental tracheal resection	NR
A case of tracheal hamartoma (Kaneko, 1978) <sup>8</sup>	34, M	Dyspnea	Tracheotomy and cauterization	NR
Tracheal hamartoma causing unique stridor and a review of the literature (Kim, 1982) <sup>9</sup>	47, M	Asthma	Bronchoscopy with multiple punch biopsies	NR
Reconstructive surgery for obstructing lesions of the intrathoracic trachea in infants and small children (Nakayma, 1982) <sup>10</sup>	4, F <sup>a</sup>	Asthma	Bronchoscopic excision; thoracotomy and tracheal wedge resection	2x3
	23, M	NR		2

(continued)

Table 1. (continued)

Article (author, year published)	Age (y), sex	Symptoms or diagnosis	Surgery/procedure	Size, cm
Tracheobronchial tumors: an eighteen-year series from Capital Hospital, Peking, China (Xu, 1983) <sup>11</sup>			Submucous excision and cauterization	
Tracheal hamartoma (Carilli, 1986) <sup>12</sup>	66, F	Asthma	Mediastinotomy	3 × 2 × 2
Endotracheal hamartoma (Alexander, 1987) <sup>13</sup>	48, M	SOB	Thoracotomy, sleeve resection	NR
Tracheal hamartoma—report of a case successfully treated with endoscopic surgery (Ogawa, 1991) <sup>14</sup>	88, M	Obstructive pneumonia	Endoscopic resection	1.9 × 1.5 × 1.3
Peripheral intrapulmonary hamartoma accompanied by a similar endotracheal lesion (Suzuki, 1994) <sup>15</sup>	70, M	None	None	NR
Multiple pulmonary chondrohamartomas in trachea, bronchi and lung parenchyma: review of the literature (Dominguez, 1996) <sup>16</sup>	88, F	Chronic bronchitis	None	NR
Tracheal hamartoma: report of a child with a neck mass (Gross, 1996) <sup>17</sup>	1, F	None	Neck exploration through transverse lower neck incision and complete excision	2.5 × 2.3 × 1.7
Surgical treatment of tracheal hamartoma (Tastepe, 1998) <sup>18</sup>	61, F	SOB; cough	Thoracotomy with segmental tracheal wall resection	2
Tracheal hamartoma: CT findings in two patients (Reittner, 1999) <sup>19</sup>	1.15, F 2.42, M	1. Asthma 2. Asthma	1. Bronchoscopy with segmental resection 2. Bronchospasm resection	1. 1.5 × 1 × 1 2. 0.3 × 0.3 × 0.5
Tracheal hamartoma: pericardial flap replacement of membranous tracheal wall (Fica, 2002) <sup>20</sup>	14, M <sup>a</sup>	Asthma	Bronchoscopic resection; tracheal stenting; cervico-external resection	NR
Asthmatic bronchitis for 2 years—a case report (Starakis, 2003) <sup>21</sup>	60, M	SOB, chronic bronchitis	Surgical excision	2.2
Maffucci's syndrome and cartilaginous neoplasms of the trachea (Moore, 2003) <sup>22</sup>	9, F <sup>a</sup>	Intermittent stridor	19 endoscopic ablations with CO <sub>2</sub> laser; median sternotomy with submucosal resection	NR
Rare tracheal chondroid hamartoma masquerading as asthma in a 14-year-old girl (Nadrous, 2004) <sup>23</sup>	14, F	Asthma	Thoracotomy	1
A hamartoma located in the trachea (Cetinkaya, 2011) <sup>24</sup>	52, M	Asthma	Tracheostomy with segmental resection	NR
Tracheal hamartoma (Pinto, 2011) <sup>25</sup>	65, M	None	Bronchoscopy with complete resection	NR
A case of tracheal hamartoma resected with loop electrocautery (Panagiotou, 2013) <sup>26</sup>	67, M	COPD	Bronchoscopy with loop electrocautery	1.8 × 1.1 × 1.7
Tracheal resection with patient under local anesthesia and conscious sedation (Loizzi, 2013) <sup>27</sup>	39, F	Dyspnea, stridor	Cervical collar incision and segmental resection	NR
Chronic obstructive pulmonary disease mismatch: a case of tracheal hamartoma (Ivanovic, 2017) <sup>28</sup>	65, M	COPD	Bronchoscopy with segmental resection	2
Endotracheal hamartoma case report: two contrasting clinical presentations of a rare entity (Hon, 2017) <sup>29</sup>	1.67, M 2.46, M	1. None 2. Chest pain, SOB	1. Bronchoscopy 2. Bronchoscopy	1. NR 2. 1.8 × 1.8 × 2

Abbreviations: COPD, chronic obstructive pulmonary disease; NR, not reported; SOB, shortness of breath.

<sup>a</sup>Indicates recurrence of tracheal hamartoma.

definitive management option for symptomatic patients and those with a clinical history concerning for underlying malignancy. The most common surgical intervention for excision is direct endoscopy with excision. Other surgical techniques include thoracotomy, mediastinotomy, transcervical approach with segmental resection, and CO<sub>2</sub> laser ablation. Concurrent tracheostomy at the time of surgery may be necessary as observed in 4 of 27 (14.8%) reported cases.

Clinicians should consider the presence of tracheal hamartomas in patients with obstructive airway symptoms whose respiratory symptoms do not improve with standard therapies. Unrecognized tracheal hamartomas can lead to critical airway obstruction and early detection can prevent avoidable complications, including death. This article reviews key clinical characteristics and provides an overview of management to aid providers who may encounter this disease process.

### Acknowledgments

The authors thank the patient in this case report.

### Author Contributions

**Carlos A. Ortega**, substantial contributions to the conception or design of the work, drafting the work, final approval of the version to be published, agreement to be accountable for all aspects of the work in ensuring that questions related to the accuracy or integrity of any part of the work are appropriately investigated and resolved; **Brandon I. Esianor**, substantial contributions to the conception or design of the work, drafting the work, final approval of the version to be published, agreement to be accountable for all aspects of the work in ensuring that questions related to the accuracy or integrity of any part of the work are appropriately investigated and resolved; **James S. Lewis Jr.**, substantial contributions to the conception or design of the work, revising it critically for important intellectual content, final approval of the version to be published, agreement to be accountable for all aspects of the work in ensuring that questions related to the accuracy or integrity of any part of the work are appropriately investigated and resolved; **Sarah L. Rohde**, substantial contributions to the conception or design of the work, revising it critically for important intellectual content, final approval of the version to be published, agreement to be accountable for all aspects of the work in ensuring that questions related to the accuracy or integrity of any part of the work are appropriately investigated and resolved.


### Disclosures


**Competing interests:** None.

**Sponsorships:** None.

**Funding source:** None.

### ORCID iDs

Carlos A. Ortega  <https://orcid.org/0000-0002-2394-8975>

Brandon I. Esianor  <https://orcid.org/0000-0002-9893-5466>

### References

- Albrecht E. Über Hamartome. *Verh Deutsch Path Ges.* 1904;7:153-157.
- Murray J, Kielkowski D, Leiman G. The prevalence and age distribution of peripheral pulmonary hamartomas in adult males: an autopsy-based study. *S Afr Med J.* 1991;79(5):247-249.
- Gjevre JA, Myers JL, Prakash UB. Pulmonary hamartomas. *Mayo Clin Proc.* 1996;71(1):14-20.
- Macchiarini P. Primary tracheal tumours. *Lancet Oncol.* 2006;7(1):83-91.
- Engelking CF. Hamartoma of the trachea. Report of a case, with a review of the literature of benign trachea neoplasms. *Laryngoscope.* 1959;69:1278-1286.
- Perry DC. Tracheo-bronchial and pulmonary chondro-adenoma (hamartoma). *Br Med J.* 1959;1(5137):1572-1574.
- Hurst IJ, Jr., Nelson KG. Tracheal hamartoma. *Chest.* 1977;72(5):661-662.
- Kaneko H, Uemura, T., Kobayashi, K., Fujita, H., Hiramatsu, Y. A case of tracheal hamartoma. *Jibi to Rinsho.* 1978;24:723-727.
- Kim SK, Cho BK, Park CI, Lee WY, Kim K. Tracheal hamartoma causing unique stridor and a review of the literature. *Yonsei Med J.* 1982;23(2):153-158.
- Nakayama DK, Harrison MR, de Lorimier AA, Brasch RC, Fishman NH. Reconstructive surgery for obstructing lesions of the intrathoracic trachea in infants and small children. *J Pediatr Surg.* 1982;17(6):854-868.
- Xu LT, Sun ZF, Li ZJ, Wu LH, Wang ZZ. Tracheobronchial tumors: an eighteen-year series from Capital Hospital, Peking, China. *Ann Thorac Surg.* 1983;35(6):590-596.
- Carilli AD, Locurto J, Conoscenti C, Bitsack J, Neville R, Wahba M. Tracheal hamartoma. *Am J Med.* 1986;81(6):1113-1114.
- Alexander JE, Brodman R. Endotracheal hamartoma. *NY State J Med.* 1987;87(7):408-409.
- Ogawa J, Inoue H, Shohtsu A, Makuuchi H. Tracheal hamartoma—report of a case successfully treated with endoscopic surgery. *Jpn J Surg.* 1991;21(4):458-461.
- Suzuki N, Ohno S, Ishii Y, Kitamura S. Peripheral intrapulmonary hamartoma accompanied by a similar endotracheal lesion. *Chest.* 1994;106(4):1291-1293.
- Dominguez H, Hariri J, Pless S. Multiple pulmonary chondrohamartomas in trachea, bronchi and lung parenchyma. Review of the literature. *Respir Med.* 1996;90(2):111-114.
- Gross E, Chen MK, Hollabaugh RS, Joyner RE. Tracheal hamartoma: report of a child with a neck mass. *J Pediatr Surg.* 1996;31(11):1584-1585.
- Tastepe AI, Kuzucu A, Demircan S, Liman ST, Demirag F. Surgical treatment of tracheal hamartoma. *Scand Cardiovasc J.* 1998;32(4):239-241.
- Reittner P, Muller NL. Tracheal hamartoma: CT findings in two patients. *J Comput Assist Tomogr.* 1999;23(6):957-958.
- Fica M, Rodriguez P, Prats R, Manana M. Tracheal hamartoma: pericardial flap replacement of membranous tracheal wall. *Eur J Cardiothorac Surg.* 2002;21(2):355-357.
- Starakis I, Mylona M, Spyropoulos K, Dimopoulos PA. Asthmatic bronchitis for 2 years. A case report. *Acta Radiol.* 2003;44(4):392-394.

22. Moore BA, Rutter MJ, Cotton R, Werkhaven J. Maffucci's syndrome and cartilaginous neoplasms of the trachea. *Otolaryngol Head Neck Surg.* 2003;128(4):583-586.
23. Nadrous HF, Allen MS, Wylam ME. Rare tracheal chondroid hamartoma masquerading as asthma in a 14-year-old girl. *Ann Allergy Asthma Immunol.* 2004;92(5):576-579.
24. Cetinkaya E, Gunluoglu G, Eyhan S, Gunluoglu MZ, Dincer SI. A hamartoma located in the trachea. *Ann Thorac Cardiovasc Surg.* 2011;17(5):504-506.
25. Pinto S, Cirino-Marciano, M, Dobkin, J, Zhu, C. Tracheal hamartoma. *Chest.* 2011;140.
26. Panagiotou M, Kalkanis A, Karagiannidis N, Polychronopoulos V. A case of tracheal hamartoma resected with loop electrocautery. *Case Rep Pulmonol.* 2013;2013:568590.
27. Loizzi D, Sollitto F, De Palma A, Pagliarulo V, Di Giglio I, Loizzi M. Tracheal resection with patient under local anesthesia and conscious sedation. *Ann Thorac Surg.* 2013;95(3):e63-65.
28. Ivanovic AM, Stevic R, Popovic M, Stojsic J, Masulovic D, Jakovic R. Chronic Obstructive Pulmonary Disease Mismatch: A Case of Tracheal Hamartoma. *Med Princ Pract.* 2017;26(2):176-178.
29. Hon C, O'Hara CJ, Little VR. Endotracheal hamartoma case report: Two contrasting clinical presentations of a rare entity. *Int J Surg Case Rep.* 2017;38:98-101.