







## ORIGINAL ARTICLE

# Expanding the phenotype of *HNRNPU*-related neurodevelopmental disorder with emphasis on seizure phenotype and review of literature

James Taylor<sup>1</sup>  | Michael Spiller<sup>2</sup> | Kara Ranguin<sup>3</sup> | Antonio Vitobello<sup>4</sup> |  
Christophe Philippe<sup>4,5</sup> | Ange-Line Bruel<sup>4,5</sup>  | Gerarda Cappuccio<sup>6</sup>  |  
Nicola Brunetti-Pierri<sup>6,7</sup>  | Marjolaine Willems<sup>8</sup>  | Bertrand Isidor<sup>9</sup> |  
Kristen Park<sup>10</sup> | Meena Balasubramanian<sup>11,12</sup> 

<sup>1</sup>Medical School, University of Sheffield, Sheffield, UK

<sup>2</sup>Sheffield Diagnostic Genetics Service, Sheffield Children's NHS Foundation Trust, Sheffield, UK

<sup>3</sup>Department of Genetics, Reference Centre for Rare Diseases and Developmental Anomalies, Caen, France

<sup>4</sup>Inserm, UMR1231, Equipe GAD, Bâtiment B3, Université de Bourgogne Franche Comté, Dijon Cedex, France

<sup>5</sup>Unité Fonctionnelle Innovation en Diagnostic Génomique des Maladies Rares, Dijon, France

<sup>6</sup>Department of Translational Medicine, University of Naples Federico II, Naples, Italy

<sup>7</sup>Telethon Institute of Genetics and Medicine, Pozzuoli, Italy

<sup>8</sup>Medical Genetic Department for Rare Diseases and Personalized Medicine, Reference Center AD SOOR, AnDDI-RARE, Groupe DI, Inserm U1298, INM, Montpellier University, Centre Hospitalier Universitaire de Montpellier, Montpellier, France

<sup>9</sup>CHU de Nantes, Service de Génétique Médicale, Nantes, France

<sup>10</sup>Department of Paediatrics and Neurology, University of Colorado School of Medicine, Aurora, Colorado, USA

<sup>11</sup>Department of Oncology & Metabolism, University of Sheffield, Sheffield, UK

<sup>12</sup>Sheffield Clinical Genetics Service, Sheffield Children's NHS Foundation Trust, Sheffield, UK

## Correspondence

Meena Balasubramanian, Department of Oncology & Metabolism, University of Sheffield, Sheffield, UK.

Email: meena.balasubramanian@nhs.net or m.balasubramanian@sheffield.ac.uk

## Funding information

Telethon Foundation, Grant/Award Number: GSP15001

## Abstract

Pathogenic variants in heterogeneous nuclear ribonucleoprotein U (*HNRNPU*) results in a novel neurodevelopmental disorder recently delineated. Here, we report on 17 previously unpublished patients carrying *HNRNPU* pathogenic variants. All patients were found to harbor *de novo* loss-of-function variants except for one individual where the inheritance could not be determined, as a parent was unavailable for testing. All patients had seizures which started in early childhood, global developmental delay, intellectual disability, and dysmorphic features. In addition, hypotonia, behavioral abnormalities (such as autistic features, aggression, anxiety, and obsessive-compulsive behaviors), and cardiac (septal defects) and/or brain abnormalities (ventriculomegaly and corpus callosum thinning/agenesis) were frequently observed. We have noted four recurrent variants in the literature (c.1089G>A p.(Trp363\*), c.706\_707del p.(Glu236Thrfs\*6), c.847\_857del p.(Phe283Serfs\*5), and c.1681dels p.(Gln561Serfs\*45)).

This is an open access article under the terms of the Creative Commons Attribution-NonCommercial-NoDerivs License, which permits use and distribution in any medium, provided the original work is properly cited, the use is non-commercial and no modifications or adaptations are made.

© 2022 The Authors. *American Journal of Medical Genetics Part A* published by Wiley Periodicals LLC.

## KEYWORDS

global developmental delay, *HNRNPU*, intellectual disability, seizures

## 1 | INTRODUCTION

Heterogeneous nuclear ribonucleoproteins (*HNRNPs*) are a large family of RNA-binding proteins that play a role in controlling the maturation of newly formed heterogeneous nuclear RNAs into messenger RNAs, and have roles in RNA splicing, polyadenylation, capping, modification, export, localization, translation, and turnover (Glisovic et al., 2008; Keene, 2007; Wu et al., 2018). Through interacting with ribonucleoproteins (RNPs), *HNRNPs* are directly involved in every stage of mRNA formation and processing as well as overseeing its entire development (Chen et al., 2013; Lim et al., 2016). The ability to do this shows that the *HNRNP* family comprises a number of incredibly complex and versatile proteins. In fact, it is thought that the functional flexibility the *HNRNP* family possesses can be explained by their ability to produce multiple alternatively spliced isoforms and their ability to form complexes with other *HNRNP* members (Geuens et al., 2016).

*HNRNPs* have also been linked to various diseases, including cancer, neurodevelopmental disorders, spinal muscular atrophy, amyotrophic lateral sclerosis, congenital myasthenic syndrome, multiple sclerosis, Alzheimer's disease, and fronto-temporal lobe dementia (Low et al., 2021). Their key roles in regulating transcriptional and post-transcriptional gene expression and their links to numerous diseases mean that unsurprisingly they have attracted much attention by researchers.

Most *HNRNP* proteins are predominantly present in the nucleus during steady state and translocate into the cytoplasm upon post-translational stimulation or when recruited by other *HNRNPs* (Han et al., 2010). This too is true of *HNRNPU*—the largest of the *HNRNP* proteins, its role largely involves transcription and alternative splicing (among other functions) (Geuens et al., 2016).

Patients with variants in *HNRNPU* have been known to present with seizures, global developmental delay, and intellectual disability (ID). To date, several studies have reported probands of patients with deletions encompassing or pathogenic variants of *HNRNPU* (Bramswig et al., 2017; Caliebe et al., 2010; Depienne et al., 2017; Durkin et al., 2020; Leduc et al., 2017; Song et al., 2021; Thierry et al., 2012; Yates et al., 2017). In this study, we expand on previously unpublished data from our group and further describe unreported  $n = 17$  probands who have *de novo* loss-of-function variants in *HNRNPU*. We provide a comprehensive overview of published literature with specific emphasis on the seizure phenotype which has not been expanded previously and examine the genotype data available from both this study and previous studies.

## 2 | MATERIALS AND METHODS

### 2.1 | Editorial policies and ethical considerations

Informed consent for inclusion and publication was obtained from all participants involved in this study.

The DDD study has UK Research Ethics Committee approval (10/H0305/83, granted by the Cambridge South REC, and GEN/284/12 granted by the Republic of Ireland REC).

### 2.2 | Method

In this study, we describe 17 probands with previously unreported likely pathogenic variants. We used the American College Medical Genetics (ACMG) guidelines for variant classification (Richards et al., 2015). Proband 6 was identified through identifying previously unpublished patients on DECIPHER (<http://decipher.sanger.ac.uk/>) (Firth et al., 2009). Proband 5, 7 and 8 were identified by contacting clinicians who have uploaded *HNRNPU* submissions onto GeneMatcher (<https://genematcher.org/statistics/>). The rest of the probands (1–4 and 9–17) were identified through contacting individuals who are part of an online support group for families supporting individuals with *HNRNPU* variants. This meant that for these patients (patients 1–4 and 9–17) anonymized data on a standardized clinical proforma was collected from the affected individual's carer/parent and where possible, additional data was collated by contacting the clinician responsible for these patients.

For the literature review, a systematic method was used to perform an initial search of the relevant literature. The databases used include Web of Science, MEDLINE via Ovid, PubMed, and The Cochrane Library. Searches were undertaken using the keyword “*HNRNPU*.” Publications were used based on their title, then the abstract and further publications were identified through the references of included papers.

## 3 | RESULTS

### 3.1 | Proband 1

Patient 1 was a 4-year-old male born to nonconsanguineous white European parents with no family history of intellectual disability or epilepsy. The pregnancy was complicated by pre-eclampsia and abnormalities detected on foetal scans. Borderline ventriculomegaly, mild bilateral hydronephrosis, and a short femur length were detected antenatally. At 36 weeks, intra-uterine growth restriction (IUGR) and abnormal umbilical artery dopplers were detected, so the decision was made to induce labor, and baby was delivered at 36 + 6 weeks gestation by emergency caesarean section. He required phototherapy for mild jaundice. There was no history of maternal illnesses and no significant exposures during the pregnancy.

His birth weight was on the 3rd centile. He was born with feeding difficulties and had mild bilateral hydronephrosis which resolved spontaneously at birth. He was found to have ostium secundum atrial

septal defect (ASD) of moderate size and mild branch pulmonary stenosis at birth, both of which resolved spontaneously. He also developed neonatal jaundice which resolved with phototherapy.

He developed a seizure phenotype at 6 months. His seizures characteristically started as absence seizures and then moved on to become focal, and if they continued for a significant amount of time became tonic-clonic. He had five admissions to the intensive care unit (ICU)—four of which were for status epilepticus and one from respiratory arrest due to a benzodiazepine overdose. He has been seizure free for over a year. He remained on topiramate and sodium valproate for epilepsy and clobazam was added in when he was unwell. Before the age of 3 years, he suffered from breakthrough seizures despite medications, these occurred every few weeks to every few months and were triggered by high fevers.

He has moderate intellectual disability and global developmental delay. He spoke his first word at 2 years, and this remained the only word he could speak. He was able to sit unsupported at 10 months and took his first steps at 30 months.

Dysmorphic features included a bilateral and a long columella. He was also born with four limb post-axial polydactyly and a convergent strabismus. He had a left sided inguinal hernia at 2 months. Polydactyly was removed, and the hernia was repaired at 2 months.

### 3.2 | Proband 2

Patient 2 was a 34-year-old female, third child born to non-consanguineous parents. The family history was unremarkable other than one paternal first cousin with a history of epilepsy. There was no history of maternal illnesses or significant exposures during pregnancy. There were no abnormalities noted on scans during pregnancy.

She was born at 39 weeks gestation with a birth weight on the 56th centile. There was hypotonia noted during the neonatal period and she remained hypotonic. She developed a seizure phenotype at 12 months and was diagnosed with epilepsy with tonic-clonic seizures. She had several breakthrough seizures in early childhood and during adolescence despite being on medication—but since starting lacosamide she has remained seizure free.

She has global developmental delay. She was able to sit unsupported at 12 months, spoke her first word at 24 months and took her first steps at 3.5 years. She has moderate intellectual disability. Dysmorphic features included a thin upper vermillion, slight frontal bossing and prominent eyebrows. She also had strabismus.

She was also diagnosed with autism, obsessive compulsive disorder (OCD), and anxiety.

### 3.3 | Proband 3

Patient 3 was an 11-year-old female. Her maternal grandparents are cousins. There was a family history of maternal multiple sclerosis. The mother took interferon beta-1a (Rebif) injections for her MS for the first 5 weeks of pregnancy but stopped this as soon as she found out

she was pregnant. There was no family history of intellectual disability or epilepsy. There were no abnormalities detected antenatally, however the child's mother noted that there were reduced foetal movements compared to her first pregnancy.

She was born by elective caesarean at 37 + 6 weeks gestation, birth weight on the 6th centile, head circumference on the 31st centile and height on the 5th centile. She was born hypotonic and had feeding difficulties during the neonatal period and remained hypotonic.

She was diagnosed with epilepsy at 2 years of age and had therapy-refractory focal and secondary generalized seizures, tonic seizures, as well as absence seizures with eyelid myoclonus. She was on clobazam, lamotrigine, perampanel, and brivaracetam for her epilepsy, yet still had between 5 and 12 breakthrough seizures a month.

She had severe intellectual disability and global developmental delay. Developmental abnormalities were first noticed at 3 months of age when it was noted that she rarely smiled, had poor eye contact and poor drinking. She was able to sit unsupported at 12 months and took her first steps at 3 years. She is aphasic. She was also diagnosed with autism spectrum disorder and has secondary microcephaly.

### 3.4 | Proband 4

Patient 4 was a 7-year-old female born to nonconsanguineous, white European parents. She was the oldest of four children, all her siblings were fit and well with no medical conditions. There was a family history of childhood and adult epilepsy affecting family members on her paternal side. There were no maternal illnesses or significant exposures during the pregnancy. The pregnancy was normal apart from vanishing twin syndrome at 7 weeks gestation.

She was born at 42 weeks with a birth weight on the 2nd centile and head circumference on the 23rd centile. She was hypotonic and had feeding difficulties at birth; the hypotonia has remained.

She experienced her first tonic-clonic seizure at 14 months, although it was suspected she was having absence seizures prior to this. She suffered from tonic-clonic and focal seizures which were controlled with medication, however, she experienced breakthrough seizures when her medication dose was not closely monitored.

She has global developmental delay and severe intellectual disability. She could sit unsupported at 12 months and took her first steps at 22 months.

Dysmorphic features included a small nose, a narrow mouth and frontal bossing. She also has a diagnosis of autism spectrum disorder and strabismus.

A brain MRI noted mesial sclerosis of the hippocampus and enlarged temporal lobe, there were no other abnormalities noted on MRI.

### 3.5 | Proband 5

Patient 5 was a 26-year-old female born at 39 weeks gestation on the 19th centile for weight. She did not experience hypotonia or feeding difficulties during the neonatal period.

She has epilepsy and took lamotrigine. She had previously taken sodium valproate and vigabatrin which was unable to control the seizures completely.

She has severe intellectual disability and global developmental delay. She was aphasic, was unable to sit unsupported and took her first steps at 30 months. She also displayed auto-aggressive behavior, depression, and anxieties related to hyperventilation. There was no hypotonia.

Dysmorphic features included a prominent nose, low set ears, a prominent epicanthus, a low set hairline, hallux valgus, and alopecia. She also had scoliosis.

### 3.6 | Proband 6

Patient 6 was a 9-year-old female. She was born by caesarean section at term of gestation complicated by IUGR with a birth weight of 2330 gr (10th centile), length of 46 cm (10th-25th centile), and occipitofrontal circumference of 31.5 cm (5th centile). Her perinatal history was unremarkable, and she was neither hypotonic nor had feeding problems in the neonatal period. At 15 months of age, she had her first tonic-clonic generalized seizure with abnormal EEG and she was started on valproate. She had several other seizures always during fever episodes.

She walked independently at 18 months and said her first words at 10 months, but her language development was delayed and by the age of 6 years she could say about 100 words and she spoke in short sentences of 1–2 words. By the age of 9 years, her language further improved, and she was able to speak by simple sentences and to make simple calculations. She had good social skills. She developed hyperphagia and gained weight by the age of about 9 years. On physical examination at the age of 9 years, her weight was 26.5 kg (25th centile), her height was 116.5 cm (SDS –2.9), her BMI was 19.5 (89th centile) and her occipitofrontal circumference was 49.6 cm (SDS –3.1).

She was noted to have dysmorphic features including a thin upper vermillion and bilateral II-III toe syndactyly. She was also found to have cyclical neutropenia with an otherwise normal hematological work-up. An MRI of her brain showed ventriculomegaly and a cyst on the pineal gland.

### 3.7 | Proband 7

Patient 7 was a 5-year-old male. He was born at 40 + 1 weeks and weighed on 27th centile. He suffered from hypotonia in the neonatal period as well as feeding problems and reflux. He does not have epilepsy, however, has had seven febrile seizures – the first of which was at 12 months of age.

He has moderate intellectual disability and global developmental delay. He first sat unsupported at 12 months and said his first word and took his first steps both at 24 months.

Dysmorphic features included hypermetropia, and a thin upper vermillion. He had a large atrial septal defect which required surgery. He also had autism, strabismus and hyperlaxity.

A brain MRI showed medio-posterior atrophy of the corpus callosum, occipital atrophy, and global cerebral atrophy.

### 3.8 | Proband 8

Patient 8 was a 23-year-old female, born at 40 weeks on the 49th centile for weight. She had hypotonia and feeding difficulties in the neonatal period. She remained hypotonic.

She suffered from epilepsy for which she took levetiracetam and lamotrigine. She had moderate intellectual disability and global developmental delay. She took her first steps at 2 years and spoke her first word at 3 years.

Dysmorphic features included a long columella, a high-arched palate, synophrys, and hallux valgus.

### 3.9 | Proband 9

Patient 9 was a 3-year-old male, born to nonconsanguineous parents with no significant family history. There was no history of maternal illnesses nor significant exposures during the pregnancy. He was born at 40 weeks and weighed on the 62nd centile. He did not suffer feeding difficulties or hypotonia during the neonatal period.

Since birth, he developed hypotonia and epilepsy with EEG abnormalities, he took levetiracetam for epilepsy which remains well controlled. He experienced his first febrile seizure at 11 months and his first afebrile seizure at 18 months. His seizures were originally focal seizures but have since progressed to generalized tonic-clonic seizures.

He has global developmental delay. He was able to first sit unsupported at 14 months, spoke his first word at 23 months and took his first steps at 3 years.

He had a ventricular septal defect (VSD) repair at 4 months and a bilateral orchidopexies at 3 years 4 months for cryptorchidism. Dysmorphic features included a sacral dimple and single palmar crease.

### 3.10 | Proband 10

Patient 10 was a 3-year-old male born to white European, non-consanguineous parents. There was no history of maternal illnesses, significant exposures, or abnormal scans during the pregnancy. The family history was unremarkable.

He was born at 39 weeks and weighed on the 44th centile. He was born with hypotonia (which remained) and feeding difficulties.

At 10 months, he experienced his first possible febrile seizure. At 12 months, he had his first absence seizure. He was on medication for his epilepsy, but still experienced breakthrough seizures when his levetiracetam dose was adjusted.

He has intellectual disability and global developmental delay. He was able to sit unsupported at 11 months, said his first word at 12 months and took his first steps at 19 months. He has autism spectrum disorder.

### 3.11 | Proband 11

Patient 11 was a 14-year-old female born to nonconsanguineous, white European parents. She was born at 39 weeks gestation with a head circumference on the 32nd centile. She experienced hypotonia during the neonatal period (which has remained) and her feeding difficulties led to her being gastrostomy fed as a neonate.

She had her first seizure at 11 months. Her epilepsy consisted of tonic-clonic, absence and atonic seizures. Her absence seizures are refractory to treatment with sodium valproate and lamotrigine.

She has severe intellectual disability and global developmental delay. She was able to sit unsupported at 18 months, took her first steps at 6 years and said her first word at 12 years.

Dysmorphic features included a small nose. She also had scoliosis, joint hypermobility, a hirsute back, clinodactyly of the Vth finger bilaterally and has grommet insertion in both ears.

She was diagnosed with autism spectrum disorder and displayed aggressive behavior.

### 3.12 | Proband 12

Patient 12 was an 8-year-old male. Like his brother, he was born at 36 weeks by caesarean section because of pre-eclampsia and IUGR. He was born with a weight on the 14th centile, height on the 8th centile and head circumference on the 10th centile. He had hypotonia, jaundice and hypoglycaemia soon after birth and needed total parenteral nutrition. He had haematemesis during the neonatal period.

He has intellectual disability and epilepsy for which he took sodium valproate. He has global developmental delay; he said his first word at 18 months and gained sphincteric control at 5 years old.

Dysmorphic features included a depressed nasal bridge, a high forehead, synophrys, diastasis of the upper incisors, bilateral single palmer crease, clinodactyly of the Vth finger bilaterally, preaxial polydactyly of right foot, syndactyly II-III toe of left foot and proportionate short stature.

### 3.13 | Proband 13

Patient 13 was an 18-year-old male born to nonconsanguineous parents with an unremarkable family history. There were no abnormalities on antenatal scans, or significant illnesses or exposures during pregnancy. He was born at 40 weeks and his birthweight was on the 54th centile. He did not experience hypotonia during the neonatal period, but he did have feeding difficulties.

He has epilepsy and experienced his first seizure at 12 months of age. He had tonic-clonic seizures for which he took sodium valproate, but these remained refractory to treatment. An EEG showed diffuse slowing, L epileptiform discharges.

He was diagnosed with severe intellectual disability and global developmental delay; he was aphasic. He first sat unsupported at 11 months and took his first steps at 24 months.

Dysmorphic features included hypertelorism, bilateral epicanthic folds, a broad nasal root, a high and narrow palate, dysplastic pinnae, posteriorly rotated and slightly low set ears, bitemporal narrowing, a prominent forehead, II-III toe syndactyly with prominent and large central incisors.

He displays autistic features but is not formally diagnosed with autism spectrum disorder. He also has behavioral issues. He displays hypertonia in the extremities but axial hypotonia and has been diagnosed with spastic diplegic cerebral palsy. Brain MRIs at 6 months and at 6 years were both normal.

### 3.14 | Proband 14

Patient 14 was a 3-year-old male born to nonconsanguineous parents. There were no significant maternal exposures or illnesses during pregnancy and no abnormalities were detected on antenatal scans. There was no significant family history. He was born at 40 + 2 weeks and weighed on the 62nd centile. There was no hypotonia or feeding difficulties during the neonatal period.

He experienced his first febrile seizure at 11 months. His first tonic-clonic seizure occurred at 18 months. His epilepsy is well controlled on levetiracetam. He has moderate-severe intellectual disability and global developmental delay. He first sat upright at 14 months, spoke his first word at 23 months and took his first steps at 3 years.

Dysmorphic features included a thin upper vermillion, a single palmar crease, and a sacral dimple. He had a ventricular septal defect repair at 4 months and a bilateral orchidopexies at 3 years 4 months for cryptorchidism.

### 3.15 | Proband 15

Patient 15 was a 2-year-old female born to nonconsanguineous parents with no significant family history. There were no significant maternal exposures or illnesses during pregnancy. IUGR was noted on antenatal the scans, and her mother reported that this baby had reduced foetal movements compared to her previous pregnancy.

She was born at 37 weeks and weighed on the 0.4th centile. She was hypotonic during the neonatal period but did not have feeding difficulties. She has epilepsy with EEG abnormalities and experienced her first seizure at 18 months. She had focal seizures and occasionally had refractory seizures despite treatment with levetiracetam.

She has moderate intellectual disability and global developmental delay. She has not taken her first steps nor spoken her first word yet at 2 years of age but sat unsupported at 12 months.

### 3.16 | Proband 16

Patient 16 was a 36-year-old male born to nonconsanguineous parents. The pregnancy was normal apart from hospitalisation at 7 weeks due to hyperemesis. There were no abnormalities observed on antenatal scans. He was born at 40 weeks on the 63rd centile.

He was hypotonic and had feeding difficulties during the neonatal period. He did not have epilepsy but at 18 months had the first of many febrile seizures. He has mild intellectual disability and global developmental delay yet. He first sat upright at 6.5 months, spoke his first word at 9.5 months and took his first steps at 10.5 months.

He displayed autistic features and anxiety as well as aggressive behavior and has been diagnosed with OCD. He had swallowing problems, constipation, and an incisor with two roots and has suffered from chronic ear infections. He had ear surgery on a perforated ear drum and used a hearing aid.

He is not diabetic but has low insulin levels and experienced low blood sugars. He also struggled to gain weight despite eating a high calorific diet.

### 3.17 | Proband 17

Patient 17 was a 3-year-old female born to nonconsanguineous parents with no significant family history. There were no abnormalities observed on antenatal scans and there were no significant maternal illnesses/ exposures. She was born at 39 + 4 weeks and weighed on the 53rd centile.

She was hypotonic in the neonatal period (which remains) but experienced no feeding difficulties. She has epilepsy with no EEG abnormalities and experienced her first seizure at 10 months. She had both tonic-clonic and absence seizures which remained well controlled with sodium valproate.

She has mild intellectual disability and global developmental delay. She first sat unsupported at 9 months, spoke her first word at 12 months, and took her first steps at 2 years and 3 months.

Brain imaging showed asymmetry of lateral ventricles (left bigger than right) and she was born with an atrial septal defect. She also takes levothyroxine for hypothyroidism.

## 4 | LITERATURE REVIEW AND DISCUSSION

### 4.1 | *HNRNPU*-related neurodevelopmental disorder

The *HNRNPU* gene, located on 1q44, is a DNA and RNA-binding protein (Durkin et al., 2020). It is involved in nuclear chromatin organization, telomere-length regulation, mRNA alternative splicing and stability, Xist-mediated transcriptional silencing, mitotic cell cycle regulation, negatively regulates glucocorticoid-mediated transcriptional activation and participates in circadian regulation

(<https://www.genecards.org/cgi-bin/carddisp.pl?gene=HNRNPU>).

Thierry et al. (2012) showed that *HNRNPU* is expressed in at least six different tissues: adult brain, heart, kidney, liver, cerebellum tissues, and foetal brain tissue, with the strongest expression in the cerebellum.

Previous research has found that deletions encompassing or *de novo* loss-of-function variants of *HNRNPU* can lead to a neurodevelopmental disorder characterised by variable degree but usually moderate to severe intellectual disability, seizures, behavioral abnormalities, and characteristic craniofacial dysmorphism and agenesis of the corpus callosum (Ballif et al., 2012; Bramswig et al., 2017; Durkin et al., 2020; Leduc et al., 2017; Yates et al., 2017). The phenotypic variability is possibly attributable to the variable size and gene content between patients (Caliebe et al., 2010). Additionally, a study by Caliebe et al. (2010) in which whole exome sequencing was used suggested that haploinsufficiency was the main mechanism of pathogenicity in *HNRNPU* variants.

A comprehensive review of the literature published so far on *HNRNPU* found eight papers which described clinical features of affected individuals. The detailed findings of our 17 probands can be found in Table 1, and the collated findings of this literature review are reported in Table 2. Table 3 depicts the association between gene variant, type of variant and phenotype. Variant nomenclature in Tables 1 and 3 is according to gene transcript NM\_031844.2.

In the following discussion, the numbers quoted for individual phenotypes includes both data collected from this study and the data collated from the literature.

Our research has further delineated common phenotypes of individuals with *HNRNPU* variants. Our data shows 11/17 individuals had neonatal hypotonia and 10/17 had neonatal feeding difficulties. Previous research by our group found that 11/21 individuals had feeding difficulties during the neonatal period and 2/7 had neonatal hypotonia (Durkin et al., 2020; Yates et al., 2017). The literature review found that 46% of individuals with *HNRNPU* variants experienced neonatal hypotonia and 57% neonatal feeding difficulties. 80% of individuals had hypotonia after the neonatal period.

Fourteen of seventeen patients had moderate or severe intellectual disability, two had mild ID. ID was suspected but not confirmed in the other case. Every individual (17/17) had global developmental delay. This is in keeping with published literature, which shows 100% of patients with *HNRNPU* had global developmental delay, and 87% have intellectual disability. Evidently, both phenotypes—particularly global developmental delay are common phenotypes associated with variants in this gene.

Seizures are another very widely reported feature of *HNRNPU* variants, and it is no surprise that our study further describes this. In the literature, 95% of patients had seizure phenotype—very few of these were febrile seizures and not epileptic. Interestingly, 91% of patients with epilepsy had their first epileptic seizure before their second birthday—and one patient had it days after their second birthday. The most common seizure type in our study was tonic-clonic seizures, with 8/11 individuals who reported seizure type describing this. Six of eleven described absence seizures and 6/11 described seizures which

**TABLE 1** Phenotypic data patients 1–17

Patient number	Patient 1	Patient 2	Patient 3	Patient 4	Patient 5	Patient 6	Patient 7	Patient 8	Patient 9
Sex	Male	Female	Female	Female	Female	Female	Male	Female	Male
Age (in years)	3.9	34.83	7.4	7.9	26.5	9.83	5.5	23	3.83
Consanguinity in the family	No	No	Grandparents are cousins	No	-	No	-	-	No
Family history of intellectual disability or epilepsy	No	First cousin has epilepsy	No	Several have epilepsy	-	First cousin of the father and paternal grandmother who has meningioma	-	-	No
Heterozygous cDNA change	c.878-9T>G	c.508C>T	c.2270_2271delCT	c.893 A>G	c.1617dup	c.2304_2305del	c.2425-2A>G	c.730_731delAG	-
Amino acid change	-	p.Gln170	p.Pro757Argfs*7	p.(H298R)	p.(Ala540Serfs*10)	p.(Gly769Glu fs*83)	-	p.(Arg244Gly fs*3)	-
Inheritance	De novo	De novo	De novo	De novo	De novo	De novo	De novo	De novo	De novo
Additional genetic defect	-	No	No	m.15266A>G	No	No	No	No	No
Gestational age at birth (weeks)	36+6	39	35	42	39	38	40+1	40	40
Birth weight (kg)	2.3	3.20	2.77	2.78	2.86	2.33	3.28	3.4	3.7
Maternal illnesses or significant exposures	Pre-eclampsia	No	Rebif for first 5 weeks	No	-	No	-	-	No
Abnormalities/ abnormal scans	Ventriculomegaly, bilateral hydronephrosis, short femurs, IUGR	No	No	Vanishing twin syndrome at 7 weeks	-	IUGR	-	-	-
Neonatal hypotonia	No	Yes	Yes	Yes	No	No	Yes	Yes	No
Neonatal feeding difficulties	Yes	Yes	Yes	Yes	No	No	Yes	Yes	No
Other neonatal problems	Jaundice	No	No	No	No	No	Reflux	No	No
Intellectual disability	Yes	Yes	Yes	Yes	Yes	Yes	Yes	Yes	-
Severity of intellectual disability	Moderate	Moderate	Moderate to severe	Severe	Severe	Moderate	Moderate	Moderate	-
Global developmental delay	Yes	Yes	Yes	Yes	Yes	Yes	Yes	Yes	Yes

(Continues)

TABLE 1 (Continued)

Patient number	Patient 1	Patient 2	Patient 3	Patient 4	Patient 5	Patient 6	Patient 7	Patient 8	Patient 9
Language delay	Yes	Yes	Yes	Yes	Yes	Yes	Yes	Yes	Yes
Age of first words	2 - only has one word	24 months	Aphasic	Aphasic	Aphasic	10 months	2 years	3 years	23 months
Motor delay	Yes	Yes	Yes	Yes	Yes	Yes	Yes	Yes	Yes
Age first sat unsupported	10 months	12 months	12 months	12 months	-	-	12 months	-	14 months
Age of first steps	30 months	3.5 years	36 months	22 months	30 months	18 months	24 months	2 years	3 years
Any psychiatric diagnosis?	No	Autism, OCD, Anxiety	Autism	Autism	No	No	Autism	No	No
Other psychopathology	No	No	No	No	Aggressive behavior, depression, anxiety	Hyperphagia	No	No	No
Hypotonia	Yes	Yes	Yes	Yes	No	No	Yes	Yes	Yes
Epilepsy	Yes	Yes	Yes	Yes	Yes	Yes	No but had seven febrile seizures	Yes	Yes
EEG abnormality	No	No	-	Yes	No	Yes	-	-	Yes
Delayed myelination	No	-	No	No	No	No	No	-	No
Corpus callosum abnormalities	No	-	No	-	No	No	Medio-posterior atrophy	-	No
Colpocephaly	No	-	No	No	No	No	No	-	No
Ventriculomegaly	Borderline ventriculomegaly	-	No	No	No	Yes	No	-	No
Other	No	-	No	Mesial sclerosis of hippocampus, enlarged temporal lobes	No	Cyst on pineal gland	Occipital atrophy, global cerebral atrophy	-	No
Age of first seizure	6 months	12 months	<24 months	14 months	-	15 months	12 months febrile	-	11 months febrile, 18 months epileptic
Seizure types	Absence, focal, tonic-clonic	Tonic-clonic	Focal, tonicclonic, tonic, absences, myoclonus	Absence, focal, tonic-clonic	-	Tonic-clonic	-	-	Focal, tonic-clonic
Refractory seizures	No longer	No	Yes	Yes	-	No	-	-	No
Dysomorphic features: eyes	Bilateral convergent squint	Strabismus	-	Strabismus	Prominent epicanthus	Normal	Strabismus, hypermetropia	Synophris	-



TABLE 1 (Continued)

Patient number	Patient 1	Patient 2	Patient 3	Patient 4	Patient 5	Patient 6	Patient 7	Patient 8	Patient 9
Nose	Long columella	-	-	Small	Prominent nose	Normal	Normal	Long columella	-
Mouth	-	Thin upper vermillion	-	Narrow	Cleft palate	Thin upper vermillion	Thin upper vermillion	No	-
Ear	-	-	-	-	Low set	Normal	Normal	No	-
Face	-	Oblong, prominent eyebrows	Aspecific dysmorphism	Round, small	-	Normal	-	No	-
Forehead	-	Slight frontal bossing	-	Frontal bossing	Low-set hairline	Normal	-	No	-
Other	-	-	Tapering fingers, cutis marmorata	-	Scoliosis, hallux valgus, short hand, big phalanx	Short stature, II-III toe syndactyly	-	No	-
Other clinical features	Four limb post-axial polydactyly, inguinal hernia, moderate ASD secundum, mild pulm. stenosis	-	-	-	Alopecia, eczema	Cyclic neutropenia	Large ASD, hyperlaxity	Arched palate, hallux valgus	Sacral dimple, single palmar crease, VSD, Bilateral undescended testes
Past tests:	46XY	-	-	-	Yes	-	No	No	No
Karyotyping	-	-	-	-	Yes	Yes	Normal	Normal	Yes
CGH-array	-	-	Normal	Yes	Yes	Yes	Normal	Normal	Yes
Single gene tests	-	-	No	No	Yes	Yes	Yes	No	No
Metabolic testing	-	-	Normal	Yes	Yes	No	Normal	No	Yes
Current medical treatment	Topiramate, sodium valproate, clobazam	Lacosamide	Clobazam, lamotrigine, perampanel and brivaracetam	-	Lamotrigine, omeprazole, trimebutine, hydroxyzine, betamethasone	Sodium valproate	No	Keppra, lamotrigine	Keppra
Medical treatment used in the past	-	-	-	-	Sodium valproate, vigabatrin, forlax	-	-	-	-
<b>Patient 10</b>	<b>Patient 11</b>	<b>Patient 12</b>	<b>Patient 13</b>	<b>Patient 14</b>	<b>Patient 15</b>	<b>Patient 16</b>	<b>Patient 17</b>	<b>Patient 18</b>	<b>Patient 19</b>
Male	Female	Male	Male	Male	Female	Male	Female	Female	Female
3.3	14	8.75	18.08	3.75	2.1	36.7	3.16	3.16	3.16
No	No	-	No	No	No	No	No	No	No
No	-	-	No	No	No	-	No	No	No
-	-	c.1665_1666delGT	c.1834G>A	Del exons 1-11	c.742dup	c.804-9_804-6del	c.1243del	c.1243del	c.1243del
-	-	-	p.Asp612Asn	-	pARG248Lysfs*12	-	-	p. (Asp415metfsr3)	-
De novo	De novo	De novo	-	De novo	De novo	De novo	De novo	De novo	De novo

(Continues)

TABLE 1 (Continued)

Patient 10	Patient 11	Patient 12	Patient 13	Patient 14	Patient 15	Patient 16	Patient 17
-	-	-	Loss of clone RP11-38O23 at Xp11.23	No	No	No	Duplication (16p13.11p12.3)
39	39	36	40	40+2	37	40	39+4
3.49	-	2.26	3.6	3.7	2	3.71	3.44
No	-	Pre-eclampsia	No	No	No	Hyperemesis at 7 weeks	No
No	-	IUGR	No	No	IUGR, few foetal movements	No	No
Yes	Yes	Yes	No	No	Yes	Yes	Yes
Yes	Yes	Yes	Yes	No	No	Yes	No
No	No	Haemateme sis, jaundice	No	No	No	-	No
Yes	Yes	Yes	Yes	Yes	Yes	Yes	Yes
-	Severe	-	Severe	Moderate	Moderate	Mild	Mild
Yes	Yes	Yes	Yes	Yes	Yes	Yes	Yes
Yes	Yes	Yes	Yes	Yes	Yes	Yes	Yes
12 months	12 years	18 months	Aphasic	23 months	Aphasic	5.5 months	12 months
-	Yes	Yes	Yes	Yes	Yes	Yes	Yes
11 months	18 months	-	11 months	14 months	12 months	6 months	9 months
19 months	6 years	-	24 months	3 years	Not achieved	10.5 months	2 years 3 months
Autism	Autism	-	Likely autism	-	-	Autistic features, OCD	No
No	Aggressive behavior	-	Behavioral issues	No	No	Aggressive behaviors, anxiety	No
Yes	Yes	Yes	Hypertonic in extremities, axial hypotonia	Yes	Yes	Yes	Yes
Yes	Yes	Yes	Yes	Yes	Yes	No (but febrile seizures)	Yes
-	Yes	-	Diffuse slowing, 1 epileptiform discharges	Yes	Yes	As a child	No
-	-	-	-	-	-	No	No
-	-	-	No	No	-	No	No
-	-	-	Normal	No	-	No	No
-	-	-	No	No	-	No	Asymmetry (left>right)
-	-	-	No	No	-	No	No
10 months febrile, 12 months absence	11 months	-	12 months	11 months febrile, 18 months epileptic	18 months	18 months febrile	10 months

TABLE 1 (Continued)

Patient 10	Patient 11	Patient 12	Patient 13	Patient 14	Patient 15	Patient 16	Patient 17
Absence	Tonic-clonic, absence, atonic	-	Tonic-clonic	Tonic-clonic	Focal seizures	-	Tonic-clonic, absence
Yes	Yes	-	Yes	Yes	Yes	-	No
Strabismus	-	Synophris	Hypertelorism, bilateral epicanthal folds	No	No	Thinning outer eyebrows	No
-	Small	Depressed nasal bridge	Broad nasal root	No	No	Depressed nasal bridge	No
-	-	Diastasis of upper incisors	High and narrow palate	Thin upper vermillion	Thin upper vermillion	Slightly high palate	No
-	-	-	Dysplastic pinnae, posteriorly rotated, low set	No	No	-	No
-	-	-	Bitemporal narrowing	No	No	-	No
-	-	High forehead	Prominent	No	No	-	No
-	Clinodactyly of Vth finger bilaterally, preaxial polydactyly of right foot, syndactyly II-III toe of left foot	Clinodactyly of Vth finger bilaterally, preaxial polydactyly of right foot, syndactyly II-III toe of left foot	II-III toe syndactyly	Single palmar crease, sacral dimple	No	Swallowing problems, constipation, chronic ear infections.	No
-	Hypermobile, hairy back, grommet's stature	Single palmar crease bilaterally, short stature	Prominent and large central incisors, Spastic diplegia	Hypermetropia, VSD, bilateral undescended testes	-	An incisor is a double tooth with two roots	ASD
-	-	Yes	46XY	No	-	Yes	-
-	Yes	-	Yes	No	Yes	No	Inherited duplicati
-	-	-	No	No	Yes	No	Nono
-	-	-	Yes	No	No	Yes	Yes
Levetiracetam	Sodium valproate, lamotrigine	Sodium valproate	Sodium valproate	Keppra	Levetiracetam	CBD with low THC, manganese Linacotide, Melatonin, B12	Sodium valproate, levothyroxine
-	-	-	Carbamazepine, Levetiracetam	-	Grommets, Toe alignment splint	Phenobarbital, phenytoin. Bilateral hearing aids. Ear surgery. Citalopram, risperidone	No

Note: Variant nomenclature is according to gene transcript NM\_031844.2. "-" indicates no data was available.

TABLE 2 Phenotype data from literature review

	Our study	Durkin et al. (2020)	Thierry et al. (2012)	Yates et al. (2017)	Bramswig et al. (2017)	Leduc et al. (2017)	Deplenne et al. (2017)	Caliebe et al. (2010)	Song et al. (2021)	Overall
Neonatal hypotonia	11/17	n/r	n/r	2/7	2/7	1/4	n/r	n/r	n/r	16/35 (45.7%)
Neonatal feeding difficulties	10/17	10/15	n/r	1/6	3/7	n/r	n/r	n/r	n/r	21/37 (56.8%)
Intellectual disability	16/17	11/21	11/11	7/7	6/6	4/4	7/7	4/4	1/2	69/79 (87.3%)
Global developmental delay	17/17	20/20	11/11	7/7	5/5	4/4	7/7	4/4	2/2	75/75 (100%)
Autistic features	8/16	3/21	4/9	1/5	4/6	1/4	1/7	n/r	1/2	23/70 (32.9%)
Hypotonia	15/17	n/r	4/9	2/7	6/7	2/4	4/5	3/4	n/r	36/45 (80.0%)
Seizures	17/17	20/21	11/11	5/7	6/6	4/4	6/7	4/4	2/2	75/79 (94.9%)
Seizures before 24 months	12/12	9/10	10/11	5/6	5/6	3/4	6/6	n/r	2/2	52/57 (91.2%)
Seizure type										
Tonic-clonic	8/11	7/16	n/r	1/6	4/6	3/4	5/5	n/r	2/2	30/50 (60.0%)
Absence	6/11	5/16	n/r	2/6	3/6	2/4	4/5	n/r	0/2	22/50 (44.0%)
Refractory	6/11	n/r	1/11	1/6	2/5	n/r	6/6	1/4	1/2	19/42 (45.2%)
Dysmorphism	16/17	21/21	10/11	6/7	7/7	4/4	n/r	3/3	2/2	69/72 (95.8%)
Thin upper vermillion	7/15	3/20	n/r	6/7	3/6	0/4	n/r	2/3	1/2	22/58 (37.9%)
Strabismus	5/15	3/20	4/8	1/7	2/6	2/4	n/r	2/3	1/2	20/57 (35.1%)
Abnormality on brain MRI	6/12	5/15	8/11	3/6	5/6	3/4	4/6	4/4	0/2	37/64 (57.8%)
Cardiac abnormality	7/16	3/14	1/10	1/6	4/6	0/4	n/r	1/4	2/2	19/62 (30.6%)

**TABLE 3** Genotype–phenotype data from the literature

Variants	Neonatal feeding difficulties	Intellectual disability	Autistic features	Hypotonia	Tonic-clonic seizures	Absence seizures	Refractory seizures	Brain abnormalities	Cardiac abnormalities	Variant identified by
Splice site variants										
c.692-1G>A p.?	-	+	-	-	-	-	-	-	-	Depienne et al. (2017)
c.2425-3C>A p.?	-	+	+	-	+	+	-	+	-	Depienne et al. (2017)
c.1117+1G>A p.?	-	+	-	+	-	-	-	-	-	Yates et al. (2017)
c.1743+1G>C p.?	+	+	-	-	+	+	-	-	-	Durkin et al. (2020)
c.692-1G>A p.?	-	-	-	-	-	-	-	-	+	Durkin et al. (2020)
c.2425-2A>G p.?	+	+	-	+	-	-	-	+	+	This study
c.143-149del7 p.?	-	-	-	-	+	-	-	-	+	Song et al. (2021)
c.878-9T>G p.?	+	+	+	-	+	+	-	+	+	This study
c.804-9_804-6del p.?	+	+	+	+	-	-	-	-	-	This study
Nonsense variants										
c.508C>T p.(Gln170*)	-	+	+	-	-	-	-	-	-	This study
c.619C>T p.(Gln207*)	+	-	-	-	-	+	-	-	-	Durkin et al. (2020)
c.1450C>T p.(Arg484*)	-	-	-	-	-	-	-	-	-	Durkin et al. (2020)
c.67C>T p.(Arg23*)	+	-	-	-	-	-	-	-	-	Durkin et al. (2020)
c.1088G>A p.(Trp363*)	-	+	-	-	-	-	-	-	+	Durkin et al. (2020)
c.1801C>T p.(Arg601*)	-	+	+	-	-	-	-	-	-	Durkin et al. (2020)
c.1089G>A p.(Trp363*)	-	+	+	+	+	+	+	+	+	Durkin et al. (2020)
c.960G>A p.(Trp320*)	-	+	-	+	+	-	-	-	-	Yates et al. (2017)
c.1714C>T p.(Arg572*)	-	+	-	+	+	-	-	+	-	Leduc et al. (2017)
c.1089G>A p.(Trp363*)	-	+	+	+	+	+	+	+	+	Leduc et al. (2017)
c.817C>T p.(Gln273*)	+	+	-	+	-	-	-	-	+	Bramswig et al. (2017)
c.511C>T p.(Gln171*)	+	+	-	+	+	-	-	+	+	Bramswig et al. (2017)
c.523C>T p.(Gln175*)	-	+	-	-	+	+	-	-	-	Bramswig et al. (2017)
c.1681C>T p.(Gln561*)	-	+	-	+	-	+	-	-	-	Depienne et al. (2017)
Missense variants										
c.893A>G p.(His298Arg)	+	+	+	+	+	+	+	+	-	This study
c.418G>A p.(Glu140Lys)	+	+	+	-	-	-	-	-	+	Yates et al. (2017)
c.970A>G p.(Arg324Gly)	+	+	-	+	-	-	+	+	+	Bramswig et al. (2017)
c.1132T>C p. (Ser378Pro)	-	+	-	+	+	+	+	+	-	Bramswig et al. (2017)
c.1834G>A p. (Asp612Asn)	+	+	+	+	+	-	+	-	-	This study

(Continues)



TABLE 3 (Continued)

Variants	Neonatal feeding difficulties	Intellectual disability	Autistic features	Hypotonia	Tonic-clonic seizures	Absence seizures	Refractory seizures	Brain abnormalities	Cardiac abnormalities	Variant identified by
c.2270_2271delCT p. (Pro757Argfs*7)	+	+	+	+	+	+	+	-	-	Leduc et al. (2017)
c.1925_1926del p. (Leu642Profs*5)	+	+	-	-	-	-	-	-	+	Durkin et al. (2020)
c.395_401del p. (Asn132Thrfs*63)	+	-	-	-	+	-	-	-	-	Durkin et al. (2020)
c.2083_2084del p. (Ser695Trpfs*6)	-	-	-	-	+	-	-	-	-	Durkin et al. (2020)
c.706_707del p. (Glu236Thrfs*6)	+	+	+	+	+	+	+	+	+	Durkin et al. (2020)
c.454_466del p. (Ala152Thrfs*41)	-	+	+	-	-	+	-	-	-	Durkin et al. (2020)
c.706_707del p. (Glu236Thrfs*6)	-	+	+	+	+	+	+	+	+	Durkin et al. (2020)
c.712_715del p. (Lys238Alafs*100)	-	-	+	-	-	-	-	-	-	Durkin et al. (2020)
c.1626_1627insA p. (Lys544Glufs*25)	-	+	-	-	-	+	-	-	-	Yates et al. (2017)
c.1424_1425insTC p. (Ile476Profs*7)	-	+	+	-	-	+	+	-	-	Yates et al. (2017)
c.651_660del p. (Gly218Alafs*118)	-	+	-	+	+	-	-	+	-	Leduc et al. (2017)
c.2270_2271del p. (Pro757Argfs*7)	-	+	-	+	-	+	-	-	-	This study
c.2299_2302del p. (Asn767Glufs*66)	-	+	-	+	-	-	-	+	-	Depienne et al. (2017)
c.847_857del p. (Phe283Serfs*5)	-	+	+	+	+	+	+	+	+	Durkin et al. (2020)
Multi-exon deletion	-	-	-	-	-	-	-	-	-	-
c.2167+35_*4156del p.?	-	+	-	-	-	-	-	-	+	Durkin et al. (2020)

Note: Variant nomenclature in each table is according to gene transcript NM\_031844.2.

were refractory to anti-epileptic treatments. Once again, these findings further emphasize findings from the literature where 60% of patients experienced tonic-clonic seizures and 44% absence seizures. Our review found 45% of individuals reported on experiencing seizures refractory to treatment.

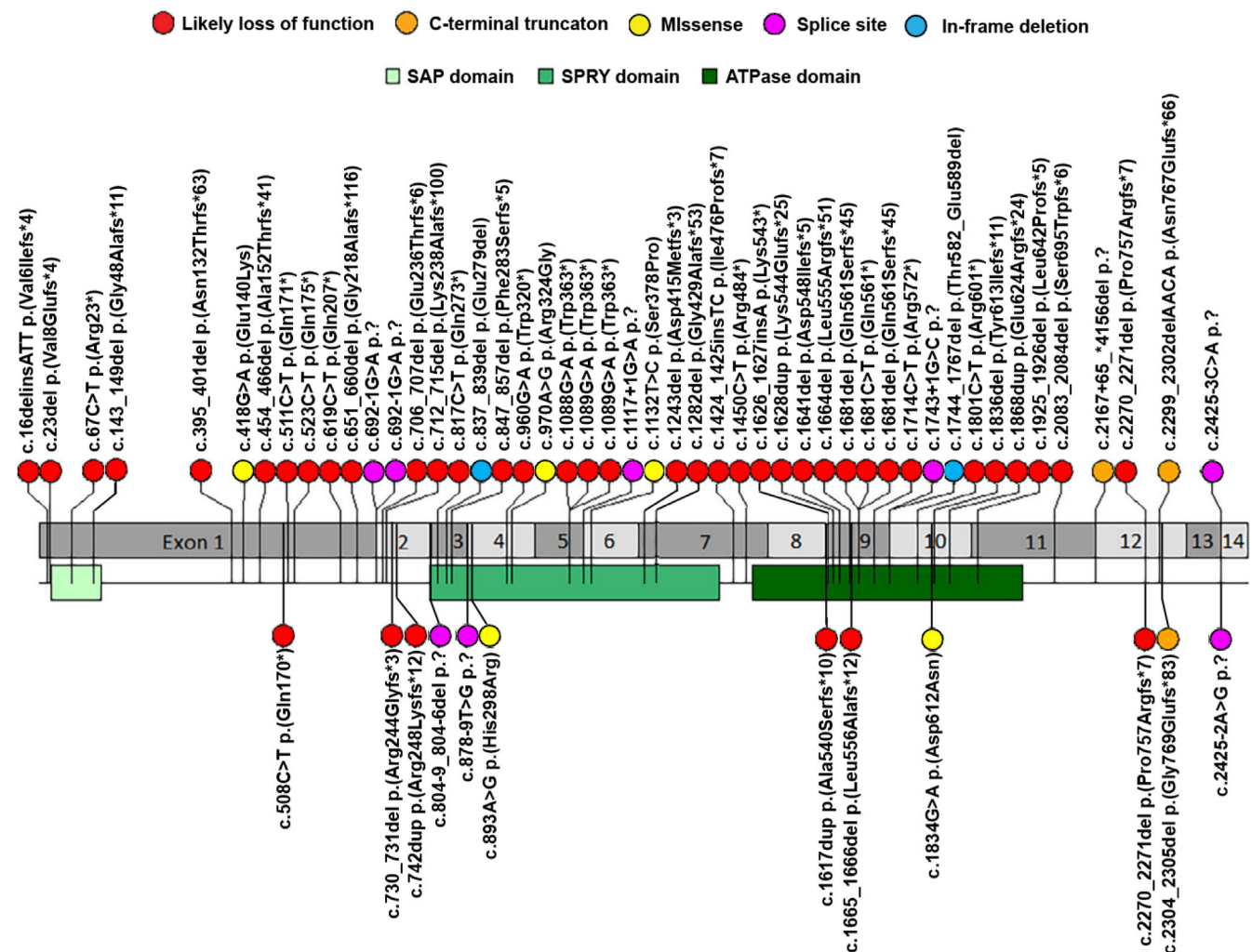
Thirty-three percent of patients from the literature review have either a diagnosis of autism spectrum disorder or autistic features. The incidence of autism/autistic features in our cohort was higher than this with half of our patients (8/16) meeting these criteria.

Our previous research has described the craniofacial dysmorphisms associated with *HNRNPU* variants. In this study, it should be noted that only 6/17 of individuals in our cohort were described by clinicians, the other 9/16 were described by parents of the affected individual so the descriptions for some of these patients are likely to be not all encompassing. Sixteen of seventeen of our cohort were described with a degree of craniofacial dysmorphism. The most frequent features described in our study were 5/15 had strabismus, 7/15 had a thin upper vermillion, 4/15 had frontal bossing, 4/17 had clinodactyly of the V finger, 4/17 had a long columella, 2/17 had

hallux valgus, and 3/17 had syndactyly of the II-III finger. In the literature, we found 96% had a dysmorphism, the most frequent being strabismus 35% and 38% had a thin upper vermillion. Previous work by us suggested that the most common dysmorphic features were palpebral fissure abnormalities, microcephaly, and wide spaced teeth (Durkin et al., 2020). In this cohort, 1 patient was described with palpebral fissure abnormalities and 1 with wide spaced teeth (another of our patient's described a double-rooted incisor), none of the other features were described.

We found 6/12 patients had abnormalities on brain MRI, the most common abnormality being ventriculomegaly (3/11). Fifty-eight percent of individuals in the literature also had nonspecific abnormalities noted on brain MRI.

Seven of sixteen of our patients had a cardiac abnormality—all six were septal defects, four atrial septal defects, and three ventricular septal defect. Once again, this reflects the literature where 31% of individuals had cardiac abnormalities, ASD being the most common followed by VSD, PDA and then jointly tricuspid atresia, tetralogy of Fallot, aortic dilatation, and transposition of the great arteries.



**FIGURE 1** Variant interpretation plot for all probands with pathogenic *HNRNPU* variants in this cohort and published literature. Variant nomenclature is according to gene transcript NM\_031844.2. Refer to Table 3 regarding references for the variants



Yates et al. (2017) described two patients in their study displaying aggressive outbursts and Epi4K-Consortium and Epilepsy Phenome/Genome Project (2013) also described such a patient (who only described one patient with very limited clinical information and therefore, excluded from our literature review). Interestingly, three patients in our cohort were described as displaying aggressive behavior. Also noteworthy is that in our previous research Durkin et al. (2020) described one patient with hyperphagia. Similarly, one patient in this study also displays this phenotype.

Our study found two patients with diagnosed obsessive compulsive disorder. This is not a newly reported finding in *HNRNPU* as Bramswig et al. (2017), Durkin et al. (2020), Depienne et al. (2017), and Leduc et al. (2017) all reported patients who displayed obsessive compulsive behaviors, so there are six cases now reported in the literature.

Other observations from our study include our reporting of three patients with II-III toe syndactyly—previously unreported in the literature. We also reported two cases of polydactyly which adds to the two cases we reported previously. And we report two cases of clinodactyly of the V finger, again furthering on from our previous research (Thierry et al., 2012).

We reported two cases of cryptorchidism, rendering a total of seven cases of this in the literature (Durkin et al., 2020: two patients, Thierry et al., 2012: two patients, and Bramswig et al., 2017: one patient).

Finally, one of our patient's has cyclical neutropenia which was previously unreported in association *HNRNPU*.

## 4.2 | Recurring genotypes

Out of the 57 genetic variants in the literature, we found four recurrent variants. The c.1089G>A p.(Trp363\*), c.706\_707del p.(Glu236Thrfs\*6), c.847\_857del p.(Phe283Serfs\*5), and c.1681dels p.(Gln561Serfs\*45) variants have all been documented on two occasions, and an additional missense variant has been reported occurring at the 1681 nucleotide (c.1681C>T p.(Gln561\*)). Additionally, there have been two reported splice site variants occurring at the 2452 nucleotide (c.2425-2A>G p.? and c.2425-3C>A p.?).

Figure 1 shows that many variants occur in the first half of exon 2 and exons 3, 9, and 10 of *HNRNPU*. Variant nomenclature is according to gene transcript NM\_031844.2. Yet, no variants have occurred in exons 8 or 13. The remaining variants are scattered sparsely through the rest of the gene.

## 5 | CONCLUSION

In this study, we add to our published literature regarding *HNRNPU*-related neurodevelopmental disorder. We have documented phenotypes previously unreported for individuals with *HNRNPU* including II-III toe syndactyly and cyclical neutropenia. And we have identified phenotypes sparsely documented in the literature including hyperphagia,

obsessive compulsive behaviors, polydactyly, clinodactyly of the V finger, and cryptorchidism.

Finally, due to 58% of individuals having abnormalities on brain MRI and 31% of individuals having cardiac abnormalities, we recommend that individuals diagnosed with *HNRNPU* should be evaluated with brain imaging (if refractory to seizure medications) and echocardiogram to screen for anatomical abnormalities (as baseline screening following diagnosis) There is not enough data published to determine on the efficacy of each anti-epileptic medication in controlling seizures. In the literature, the most frequently used medication is sodium valproate which usually works. However, when seizures are refractory to sodium valproate there is no consensus in the literature on the next medication(s) to use.

## ACKNOWLEDGMENTS

This study makes use of data generated by the DECIPHER community. A full list of centers who contributed to the generation of the data is available from <https://deciphergenomics.org/about/stats> and via email from [contact@deciphergenomics.org](mailto:contact@deciphergenomics.org). Funding for the DECIPHER project was provided by Wellcome. This work was supported by Telethon Foundation, Telethon Undiagnosed Diseases Program (TUDP, GSP15001) and was in part generated within the European Reference Network ITHACA. This study also makes use of GeneMatcher. We would also like to thank all the families for consenting to this publication.

## CONFLICT OF INTEREST

The authors declare that there is no conflict of interest that could be perceived as prejudicing the impartiality of the research reported.

## AUTHOR CONTRIBUTIONS

James Taylor wrote the manuscript and collected the data. Meena Balasubramanian supervised the project. Michael Spiller made Figure 1. All other authors contributed to data collection and approved the final manuscript.

## DATA AVAILABILITY STATEMENT

Open access Decipher entries ([www.deciphergenomics.org](http://www.deciphergenomics.org)).

## ORCID

James Taylor  <https://orcid.org/0000-0003-2552-4196>

Ange-Line Bruel  <https://orcid.org/0000-0002-0526-465X>

Gerarda Cappuccio  <https://orcid.org/0000-0003-3934-2342>

Nicola Brunetti-Pierrri  <https://orcid.org/0000-0002-6895-8819>

Marjolaine Willems  <https://orcid.org/0000-0002-2959-0935>

Meena Balasubramanian  <https://orcid.org/0000-0003-1488-3695>

## REFERENCES

- Ballif, B. C., Rosenfeld, J. A., Traylor, R., Theisen, A., Bader, P. I., Ladda, R. L., Sell, S. L., Steinrath, M., Surti, U., McGuire, M., Williams, S., Farrell, S. A., Filiano, J., Schnur, R. E., Coffey, L. B., Tervo, R. C., Stroud, T., Marble, M., Netzloff, M., Hanson, K., ... Shaffer, L. G. (2012).

- High-resolution array CGH defines critical regions and candidate genes for microcephaly, abnormalities of the corpus callosum, and seizure phenotypes in patients with microdeletions of 1q43q44. *Human Genetics*, 131(1), 145–156.
- Bramswig, N. C., Lüdecke, H. J., Hamdan, F. F., Altmüller, J., Beleggia, F., Elcioglu, N. H., Freyer, C., Gerkes, E. H., Demirkol, Y. K., Knupp, K. G., Kuechler, A., Li, Y., Lowenstein, D. H., Michaud, J. L., Park, K., Stegmann, A., Veenstra-Knol, H. E., Wieland, T., Wollnik, B., Engels, H., ... Wieczorek, D. (2017). Heterozygous HNRNPU variants cause early onset epilepsy and severe intellectual disability. *Human Genetics*, 136(7), 821–834.
- Caliebe, A., Kroes, H. Y., van der Smagt, J. J., Martin-Subero, J. I., Tönnies, H., van 't Slot, R., Nievelstein, R. A., Muhle, H., Stephani, U., Alfke, K., Stefanova, I., Hellenbroich, Y., Gillissen-Kaesbach, G., Hochstenbach, R., Siebert, R., & Poot, M. (2010). Four patients with speech delay, seizures and variable corpus callosum thickness sharing a 0.440 Mb deletion in region 1q44 containing the HNRNPU gene. *European Journal of Medical Genetics*, 53(4), 179–185.
- Chen, Q., Jin, M., Zhu, J., Xiao, Q., & Zhang, L. (2013). Functions of heterogeneous nuclear ribonucleoproteins in stem cell potency and differentiation. *BioMed Research International*, 2013, 623978.
- Depienne, C., Nava, C., Keren, B., Heide, S., Rastetter, A., Passemard, S., Chantot-Bastaraud, S., Moutard, M. L., Agrawal, P. B., VanNoy, G., Stoler, J. M., Amor, D. J., Billette de Villemeur, T., Doummar, D., Alby, C., Cormier-Daire, V., Garel, C., Marzin, P., Scheidecker, S., de Saint-Martin, A., ... Mignot, C. (2017). Genetic and phenotypic dissection of 1q43q44 microdeletion syndrome and neurodevelopmental phenotypes associated with mutations in ZBTB18 and HNRNPU. *Human Genetics*, 136, 463–479.
- Durkin, A., Albaba, S., Fry, A. E., Morton, J. E., Douglas, A., Beleza, A., Williams, D., Volker-Touw, C., Lynch, S. A., Canham, N., Clowes, V., Straub, V., Lachlan, K., Gibbon, F., El Gamal, M., Varghese, V., Parker, M. J., Newbury-Ecob, R., Turnpenny, P. D., Gardham, A., ... Balasubramanian, M. (2020). Clinical findings of 21 previously unreported probands with HNRNPU-related syndrome and comprehensive literature review. *American Journal of Medical Genetics Part A*, 182(7), 1637–1654.
- Epi4K-Consortium & Epilepsy Phenome/Genome Project. (2013). De novo mutations in epileptic encephalopathies. *Nature*, 501, 217–221.
- Firth, H. V., Richards, S. M., Bevan, A. P., Clayton, S., Corpas, M., Rajan, D., Van Vooren, S., Moreau, Y., Pettett, R. M., & Carter, N. P. (2009). DECIPHER: Database of chromosomal imbalance and phenotype in humans using ensembl resources. *American Journal of Human Genetics*, 84, 524–533.
- Geuens, T., Bouhy, D., & Timmerman, V. (2016). The hnRNP family: Insights into their role in health and disease. *Human Genetics*, 135, 851–867.
- Glisovic, T., Bachorik, J. L., Yong, J., & Dreyfuss, G. (2008). RNA-binding proteins and post-transcriptional gene regulation. *FEBS Letters*, 582(14), 1977–1986.
- Han, S. P., Tang, Y. H., & Smith, R. (2010). Functional diversity of the hnRNPs: Past, present and perspectives. *Biochemical Journal*, 430, 379–392.
- Keene, J. D. (2007). RNA regulons: Coordination of post-transcriptional events. *Nature Reviews. Genetics*, 8(7), 533–543.
- Leduc, M. S., Chao, H. T., Qu, C., Walkiewicz, M., Xiao, R., Magoulas, P., Pan, S., Beuten, J., He, W., Bernstein, J. A., Schaaf, C. P., Scaglia, F., Eng, C. M., & Yang, Y. (2017). Clinical and molecular characterization of de novo loss of function variants in HNRNPU. *American Journal of Medical Genetics Part A*, 173(10), 2680–2689.
- Lim, I., Jung, Y., Kim, D. Y., & Kim, K. T. (2016). HnRNP Q has a suppressive role in the translation of mouse Cryptochrome1. *PLoS One*, 11(7), e0159018.
- Low, Y. H., Asi, Y., Foti, S. C., & Lashley, T. (2021). Heterogeneous nuclear ribonucleoproteins: Implications in neurological diseases. *Molecular Neurobiology*, 58(2), 631–646.
- Richards, S., Aziz, N., Bale, S., Bick, D., Das, S., Gastier-Foster, J., Grody, W. W., Hegde, M., Lyon, E., Spector, E., Voelkerding, K., Rehm, H. L., & ACMG Laboratory Quality Assurance Committee (2015). Standards and guidelines for the interpretation of sequence variants: A joint consensus recommendation of the American College of Medical Genetics and Genomics and the Association for Molecular Pathology. *Genetics in Medicine*, 17(5), 405–423.
- Song, Z., Zhang, Y., Yang, C., Yi, Z., Li, F., Xue, J., Yang, X., & Li, B. (2021). De novo frameshift variants of HNRNPU in patients with early infantile epileptic encephalopathy: Two case reports and literature review. *International Journal of Developmental Neuroscience*, 81, 663–668.
- Thierry, G., Bénétou, C., Pichon, O., Flori, E., Isidor, B., Popelard, F., Delrue, M. A., Duboscq-Bidot, L., Thuresson, A. C., van Bon, B. W., Cailley, D., Rooryck, C., Paubel, A., Metay, C., Dusser, A., Pasquier, L., Béri, M., Bonnet, C., Jaillard, S., Dubourg, C., ... Le Caignec, C. (2012). Molecular characterization of 1q44 microdeletion in 11 patients reveals three candidate genes for intellectual disability and seizures. *American Journal of Medical Genetics Part A*, 158(7), 1633–1640.
- Wu, B., Su, S., Patil, D. P., Liu, H., Gan, J., Jaffrey, S. R., & Ma, J. (2018). Molecular basis for the specific and multivalent recognitions of RNA substrates by human hnRNP A2/B1. *Nature Communications*, 9(1), 420.
- Yates, T. M., Vasudevan, P. C., Chandler, K. E., Donnelly, D. E., Stark, Z., Sadedin, S., Willoughby, J., Broad Center for Mendelian Genomics, DDD study, & Balasubramanian, M. (2017). De novo mutations in HNRNPU result in a neurodevelopmental syndrome. *American Journal of Medical Genetics Part A*, 173(11), 3003–3012.

**How to cite this article:** Taylor, J., Spiller, M., Ranguin, K., Vitobello, A., Philippe, C., Bruel, A.-L., Cappuccio, G., Brunetti-Pierri, N., Willems, M., Isidor, B., Park, K., & Balasubramanian, M. (2022). Expanding the phenotype of HNRNPU-related neurodevelopmental disorder with emphasis on seizure phenotype and review of literature. *American Journal of Medical Genetics Part A*, 188A:1497–1514. <https://doi.org/10.1002/ajmg.a.62677>