

Radiotherapy With Hydrogen Peroxide-Soaked Gauze for Preauricular Sebaceous Carcinoma

Akiko Adachi ^{1,2}, Takahiro Oike ^{2,1}, Masaaki Tamura ⁵, Norichika Ota ¹, Tatsuya Ohno ^{1,2}

Review began 06/29/2022

Review ended 07/26/2022

Published 07/29/2022

© Copyright 2022

Adachi et al. This is an open access article distributed under the terms of the Creative Commons Attribution License CC-BY 4.0., which permits unrestricted use, distribution, and reproduction in any medium, provided the original author and source are credited.

1. Department of Radiation Oncology, Gunma University Graduate School of Medicine, Maebashi, JPN 2. Heavy Ion Medical Center, Gunma University, Maebashi, JPN 3. Department of Dermatology, Sano Kosei General Hospital, Sano, JPN

Corresponding author: Akiko Adachi, akiadachi@gunma-u.ac.jp

Abstract

Sebaceous carcinoma is a rare and aggressive malignant tumor deriving from the adnexal epithelium of the sebaceous glands. The case of inoperable preauricular sebaceous carcinoma treated with definitive radiotherapy is first reported herein. Radiotherapy of 60 Gy in 30 fractions was combined with a hydrogen peroxide-soaked gauze bolus aiming at potential radiosensitization. Macroscopic complete remission was achieved eight months after radiotherapy with tolerable adverse effects. Although further clinical studies are needed, radiotherapy with a hydrogen peroxide-soaked gauze bolus can be an effective and tolerable treatment for inoperable patients with extraocular sebaceous carcinoma.

Categories: Dermatology, Radiation Oncology

Keywords: radiotherapy, extremely high age, hydrogen peroxide, extraocular, sebaceous carcinoma

Introduction

Sebaceous carcinoma is a rare and aggressive malignant tumor derived from the adnexal epithelium of the sebaceous glands [1]. Sebaceous carcinoma commonly occurs in adults >60 years old, primarily in the eyelids and followed by the head and neck as well as the body trunk [2]. The survival rate for sebaceous carcinoma is 92% and 86% at 5 and 10 years, respectively [3]. Although surgery remains the mainstay of definitive treatment for sebaceous carcinoma, radiotherapy may be an option for those who are considered inoperable or reject surgery [2,3]. However, the optimal radiation dose for controlling sebaceous carcinoma remains unclear because of its rarity. Previous reports indicate that the tumors arising from the eyelid require at least 55 Gy, whereas data are lacking regarding tumors located at the extraocular lesions [3].

In recent years, hydrogen peroxide (H₂O₂) has attracted interest as a radiosensitizer [4-6]. For superficial tumors, H₂O₂-soaked gauze can be used as a bolus for radiotherapy [6-8]. Currently, several case reports have demonstrated that the combination of radiotherapy with an H₂O₂-soaked gauze bolus is effective and tolerable [6-8].

Here, a rare case of inoperable extraocular (i.e., preauricular) sebaceous carcinoma treated with definitive radiotherapy is reported. Since the control probability for this malignancy at the radiation dose conventionally used for common skin cancers (i.e., 60-66 Gy) remained unclear, an H₂O₂-soaked gauze bolus was used aiming at potential radiosensitization [3].

Case Presentation

A 97-year-old woman was referred to the radiation oncology unit from the dermatology unit of the hospital of the current study for the treatment of preauricular sebaceous carcinoma. The patient had been living in a nursing home and experiencing exudation, bleeding, and pain from the tumor for one month before the referral, resulting in impaired quality of life (QOL). The skin tumor was 3.5 cm in diameter and was diagnosed clinically as stage II (T2N0M0) following the eighth edition of the Union for International Cancer Control (Figure 1).

How to cite this article

Adachi A, Oike T, Tamura M, et al. (July 29, 2022) Radiotherapy With Hydrogen Peroxide-Soaked Gauze for Preauricular Sebaceous Carcinoma. Cureus 14(7): e27464. DOI 10.7759/cureus.27464

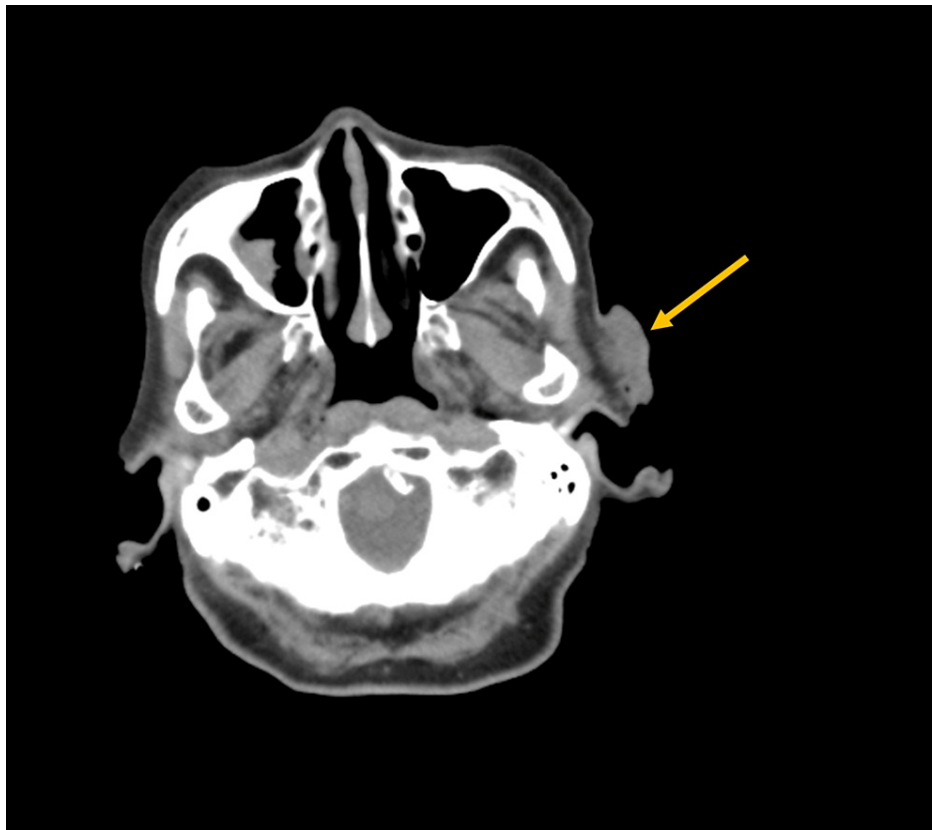


FIGURE 1: Computed tomography image obtained before radiotherapy.

The arrow shows a tumor.

The tumor was diagnosed pathologically as sebaceous carcinoma based on the positivity of the epithelial membrane antigen, androgen receptor, and factor XIIIa [2,3]. Definitive radiotherapy was performed because the patient was considered inoperable due to extremely high age.

Using 6-MeV electrons, 60 Gy was delivered in 30 fractions at five fractions per week (Figure 2). The source-skin distance was 100 cm. The clinical target volume (CTV) was defined as the gross tumor with a margin of at least 1 cm around the tumor. To cover the CTV, a 6-cm-diameter cone was used for the former 50 Gy, followed by a 5-cm-diameter cone for the latter 10 Gy to accommodate tumor shrinkage. An H₂O₂-soaked gauze (5 mm thick) was freshly prepared and placed on the tumor surface at each radiotherapy session.




FIGURE 2: Radiotherapy planning and actual treatment.

(A, B) According to tumor size, a 6- (50 Gy) and 5- (10 Gy) cm-diameter cone (for the former and the latter, respectively) was set to cover the clinical target volume (i.e., the gross tumor plus margin of at least 1 cm). (C) Application of the hydrogen peroxidase-soaked gauze during the radiotherapy session.

Practically, when the patient entered the treatment room, a nurse poured Oxydol (i.e., 2.5-3.5 w/v% H₂O₂; KENEI Pharmaceutical Co. Ltd., Osaka, Japan) into a plastic bag, and gauze was soaked completely in the bag. The tumor showed a fair shrinkage as the treatment progressed.

Pain and exudation and bleeding from the tumor resolved upon treatment completion. The tumor showed

further remission three months after radiotherapy, and macroscopic complete remission was achieved eight months after radiotherapy, which was the last observation date. The patient experienced grade 2 radiation dermatitis based on the Common Terminology Criteria for Adverse Events 5.0, which resolved at two months post-radiotherapy without topical medication and skincare. The patient is currently enjoying life in a nursing home while maintaining QOL (Figure 3).

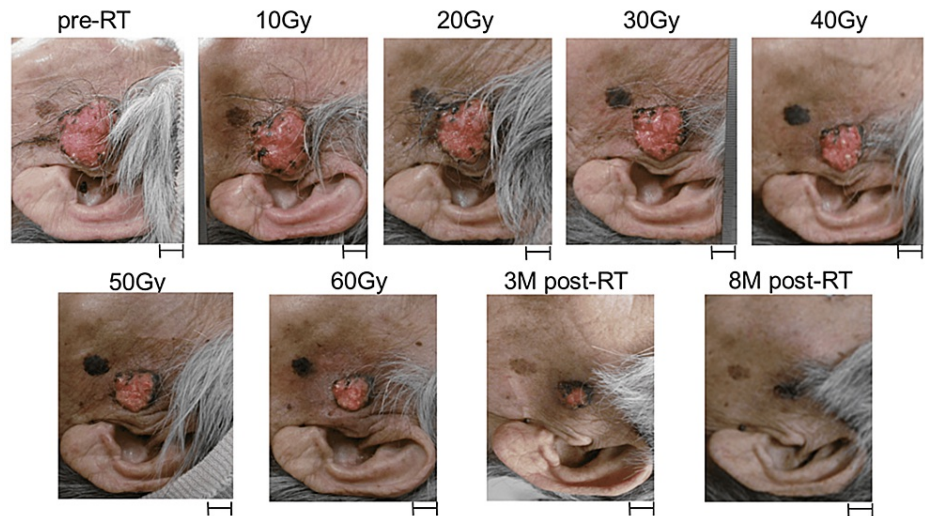


FIGURE 3: Representative pictures showing tumor shrinkage over the course of treatment.

Scales 1 cm, M months, and RT radiotherapy.

Discussion

Sebaceous carcinoma is a rare malignancy, and almost 70% of sebaceous carcinoma arises on the eyelids. Although no currently standardized treatment for sebaceous carcinoma exists, surgical resection has been considered the first choice. Disease-related mortality in surgically treated patients is reported to range from 6% to 30% [9,10]. Radiotherapy can be an alternative option for inoperable cases because of poor general condition, cosmetic concerns, or the patient's refusal, and a few studies have reported the outcome of definitive radiotherapy for sebaceous carcinoma. Hata et al. reported 13 patients with sebaceous carcinoma arising in the eyelid who were treated with radiotherapy [11]. In that study, the radiation dose ranged from 50 to 66.6 Gy and the 5-year local progression-free rate was 100%. Takagawa et al. reported 83 patients with localized sebaceous carcinoma of the eyelid treated with radiotherapy, and the outcome was much worse than that reported by Hata et al.; the radiation dose ranged from 48 Gy to 70.4 Gy, and the 7-year local control rate was 52.3% [11,12]. These studies showed that the dose required for tumor control remains unclear; nevertheless, these data may indicate that 60-66 Gy, which is used to eradicate common skin cancers including basal cell carcinoma and cutaneous squamous cell carcinoma, may be insufficient to control sebaceous carcinoma [13].

Sebaceous carcinoma that arises from the extraocular location is even rarer, and only one report of radiotherapy aside from adjuvant therapy and salvage therapy was known. Oshiro et al. reported a case of sebaceous carcinoma arising from the tongue [14]. Radiotherapy was performed with 63 Gy in 35 fractions in addition to concurrent superselective intra-arterial chemotherapy because the patient refused surgery. Complete response of the primary lesion after radiotherapy was confirmed through multiple biopsies. The patient expired 17 months after completing the initial treatment by distant metastases. In the current case, the patient was at an extremely old age and was thus considered ineligible for surgery and chemotherapy.

Although Oshiro et al. concluded in their report that radiotherapy combined with superselective intra-arterial chemotherapy can be an effective treatment for sebaceous carcinoma of the tongue, the optimal radiation dose for controlling extraocular sebaceous carcinoma remains unclear [14]. At this stage, extraocular sebaceous carcinoma harbors biological characteristics or a radiosensitivity that is different from those of sebaceous carcinoma of the eyelid. Taking all of these factors into consideration, using H₂O₂-soaked gauze in combination with 60-Gy radiotherapy was tried to be used with the aim of potential radiosensitization. As a result, combined radiotherapy plus H₂O₂-soaked gauze resulted in complete tumor remission with tolerable dermatitis, indicating that this treatment can be a viable option for inoperable periauricular sebaceous carcinoma.

The putative mechanisms of the radiosensitizing effect of H₂O₂ are based on reoxygenation of the radioresistant hypoxic tumor microenvironment, the indirect effect of inducing the intracellular production of reactive oxygen species to increase the induction of DNA double-strand breaks, and the influence of several radioresistance-associated signaling pathways [7,15-17]. Ogawa et al. first described the radiosensitization strategy using an H₂O₂-soaked gauze in 2008 [6]. In that study, the authors reported five cases of locally advanced and/or recurrent tumors exposed to the skin surface, which were treated with electrons plus an H₂O₂-soaked gauze. More recently, Oike et al. reported a case of metastatic breast cancer with palliative radiotherapy with 51 Gy in 17 fractions using the H₂O₂-soaked gauze [7]. The tumor showed macroscopic complete remission three months after treatment, with the resolution of the patient's symptoms, including bleeding and exudation. The patient experienced grade one radiation dermatitis, which resolved after radiotherapy without topical medication. Similarly, Shiba et al. reported a case of locally advanced breast cancer involving the skin surface that was treated with radiotherapy with 51 Gy in 17 fractions using the H₂O₂-soaked gauze, with favorable local effects observed [8]. The patient experienced grade three acute radiation dermatitis, which was treated with topical steroids and improved two months after radiation therapy. The tumor showed a complete clinical response to the primary tumor four months after radiotherapy. Together with the present case, these reports suggest the efficacy and tolerability of the treatment with electrons with the H₂O₂-soaked gauze. Nevertheless, solid evidence of the tolerable and optimal dose fractionation for this treatment is lacking, thus warranting further studies in a prospective setting for various cancers.

Conclusions

The current study reported the first case of inoperable periauricular sebaceous carcinoma treated with definitive radiotherapy plus an H₂O₂-soaked gauze. Excellent local control was achieved at least eight months after treatment without severe adverse effects. In addition, the current case indicates that radiotherapy with an H₂O₂-soaked gauze can be an effective and tolerable treatment in inoperable patients with extraocular sebaceous carcinoma.

Additional Information

Disclosures

Human subjects: Consent was obtained or waived by all participants in this study. Ethics Review Committee of Sano Kosei General Hospital issued approval 202202. This study was approved by the Ethics Review Committee of Sano Kosei General Hospital (approval no.: 202202). Written informed consent is declared. This study was conducted following the ethical principles of the Declaration of Helsinki. **Conflicts of interest:** In compliance with the ICMJE uniform disclosure form, all authors declare the following: **Payment/services info:** All authors have declared that no financial support was received from any organization for the submitted work. **Financial relationships:** All authors have declared that they have no financial relationships at present or within the previous three years with any organizations that might have an interest in the submitted work. **Other relationships:** All authors have declared that there are no other relationships or activities that could appear to have influenced the submitted work.

Acknowledgements

Mr. Nobuyuki Sawai, Mr. Michiyuki Wada, Mr. Naonori Haraguchi, Ms. Takami Sugimoto, Ms. Yuki Suzuki, Ms. Erina Ishikawa, and Ms. Mariko Kaneko of Sano Kousei General Hospital are thanked for the clinical assistance.

References

1. Nelson BR, Hamlet KR, Gillard M, Railan D, Johnson TM: Sebaceous carcinoma. *J Am Acad Dermatol.* 1995, 33:1-15. [10.1016/0190-9622\(95\)90001-2](https://doi.org/10.1016/0190-9622(95)90001-2)
2. Owen JL, Kibbi N, Worley B, et al.: Sebaceous carcinoma: evidence-based clinical practice guidelines. *Lancet Oncol.* 2019, 20:E699-714. [10.1016/S1470-2045\(19\)30673-4](https://doi.org/10.1016/S1470-2045(19)30673-4)
3. Knackstedt T, Samie FH: Sebaceous carcinoma: a review of the scientific literature. *Curr Treat Options Oncol.* 2017, 18:47. [10.1007/s11864-017-0490-0](https://doi.org/10.1007/s11864-017-0490-0)
4. Aoyama N, Ogawa Y, Yasuoka M, et al.: Therapeutic response to a novel enzyme-targeting radiosensitization treatment (KORTUC II) for residual lesions in patients with stage IV primary breast cancer, following induction chemotherapy with epirubicin and cyclophosphamide or taxane. *Oncol Lett.* 2017, 13:69-76. [10.3892/ol.2016.5456](https://doi.org/10.3892/ol.2016.5456)
5. Nimalasena S, Gothard L, Anbalagan S, et al.: Intratumoral hydrogen peroxide with radiation therapy in locally advanced breast cancer: results from a phase 1 clinical trial. *Int J Radiat Oncol Biol Phys.* 2020, 108:1019-29. [10.1016/j.ijrobp.2020.06.022](https://doi.org/10.1016/j.ijrobp.2020.06.022)
6. Ogawa Y, Ue H, Tsuzuki K, et al.: New radiosensitization treatment (KORTUC I) using hydrogen peroxide solution-soaked gauze bolus for unresectable and superficially exposed neoplasms. *Oncol Rep.* 2008, 19:1389-94. [10.3892/or.19.6.1389](https://doi.org/10.3892/or.19.6.1389)
7. Oike T, Tomizawa K, Adachi A, Wada M, Ohno T: Radiotherapy with hydrogen peroxide-soaked gauze for unresectable breast cancer. *Cureus.* 2021, 13:e19167. [10.7759/cureus.19167](https://doi.org/10.7759/cureus.19167)
8. Shiba S, Watanabe T, Kaminuma T, et al.: Locally advanced breast cancer involving the skin surface treated

- with radiation therapy using a hydrogen peroxide solution-soaked gauze bolus: a case report. *Adv Radiat Oncol*. 2022, 7:100894. [10.1016/j.adro.2022.100894](https://doi.org/10.1016/j.adro.2022.100894)
9. Song A, Carter KD, Syed NA, Song J, Nerad JA: Sebaceous cell carcinoma of the ocular adnexa: clinical presentations, histopathology, and outcomes. *Ophthalmic Plast Reconstr Surg*. 2008, 24:194-200. [10.1097/IOP.0b013e31816d925f](https://doi.org/10.1097/IOP.0b013e31816d925f)
 10. Shields JA, Demirci H, Marr BP, Eagle RC Jr, Shields CL: Sebaceous carcinoma of the ocular region: a review. *Surv Ophthalmol*. 2005, 50:103-22. [10.1016/j.survophthal.2004.12.008](https://doi.org/10.1016/j.survophthal.2004.12.008)
 11. Hata M, Koike I, Omura M, Maegawa J, Ogino I, Inoue T: Noninvasive and curative radiation therapy for sebaceous carcinoma of the eyelid. *Int J Radiat Oncol Biol Phys*. 2012, 82:605-11. [10.1016/j.ijrobp.2010.12.006](https://doi.org/10.1016/j.ijrobp.2010.12.006)
 12. Takagawa Y, Tamaki W, Suzuki S, et al.: Radiotherapy for localized sebaceous carcinoma of the eyelid: a retrospective analysis of 83 patients. *J Radiat Res*. 2019, 60:622-9. [10.1093/jrr/rrz046](https://doi.org/10.1093/jrr/rrz046)
 13. Likhacheva A, Awan M, Barker CA, et al.: Definitive and postoperative radiation therapy for basal and squamous cell cancers of the skin: executive summary of an American Society for Radiation Oncology Clinical Practice Guideline. *Pract Radiat Oncol*. 2020, 10:8-20. [10.1016/j.prr.2019.10.014](https://doi.org/10.1016/j.prr.2019.10.014)
 14. Oshiro H, Iwai T, Hirota M, et al.: Primary sebaceous carcinoma of the tongue. *Med Mol Morphol*. 2010, 43:246-52. [10.1007/s00795-010-0521-4](https://doi.org/10.1007/s00795-010-0521-4)
 15. Gough DR, Cotter TG: Hydrogen peroxide: a Jekyll and Hyde signalling molecule. *Cell Death Dis*. 2011, 2:e213. [10.1038/cddis.2011.96](https://doi.org/10.1038/cddis.2011.96)
 16. Veal EA, Day AM, Morgan BA: Hydrogen peroxide sensing and signaling. *Mol Cell*. 2007, 26:1-14. [10.1016/j.molcel.2007.05.016](https://doi.org/10.1016/j.molcel.2007.05.016)
 17. Sies H: Hydrogen peroxide as a central redox signaling molecule in physiological oxidative stress: oxidative eustress. *Redox Biol*. 2017, 11:613-9. [10.1016/j.redox.2016.12.035](https://doi.org/10.1016/j.redox.2016.12.035)