



# The gut microbiome contributes to splenomegaly and tissue inflammation in a murine model of primary biliary cholangitis

Cheng-Bo Wang<sup>1</sup>, Yan Wang<sup>2</sup>, Yuan Yao<sup>3</sup>, Jin-Jun Wang<sup>4</sup>, Koichi Tsuneyama<sup>5</sup>, Qiong Yang<sup>1</sup>, Bin Liu<sup>2</sup>, Carlo Selmi<sup>6,7</sup>, M. Eric Gershwin<sup>8</sup>, Shu-Han Yang<sup>1</sup>, Zhe-Xiong Lian<sup>1</sup>

<sup>1</sup>Chronic Disease Laboratory, School of Medicine, South China University of Technology, Guangzhou, China; <sup>2</sup>Department of Rheumatology and Immunology, Affiliated Hospital of Qingdao University, Qingdao, China; <sup>3</sup>Digestive Disease Institute, Guangzhou First People's Hospital and Institutes for Life Sciences, South China University of Technology, Guangzhou, China; <sup>4</sup>College of Environmental Science and Engineering, Yangzhou University, Yangzhou, China; <sup>5</sup>Department of Pathology and Laboratory Medicine, Institute of Biomedical Sciences, Tokushima University Graduate School, Tokushima, Japan; <sup>6</sup>Department of Rheumatology and Clinical Immunology, IRCCS Humanitas Research Hospital, Rozzano, Milan, Italy; <sup>7</sup>Department of Biomedical Sciences, Humanitas University, Milan, Italy; <sup>8</sup>Division of Rheumatology, Allergy, and Clinical Immunology, University of California Davis, Davis, CA, USA

**Contributions:** (I) Conception and design: CB Wang, Y Wang, Y Yao; (II) Administrative support: Q Yang, JJ Wang, SH Yang, B Liu; (III) Provision of study materials or patients: Y Yao, ZX Lian; (IV) Collection and assembly of data: CB Wang, Y Wang; (V) Data analysis and interpretation: CB Wang, Y Wang, K Tsuneyama; (VI) Manuscript writing: All authors; (VII) Final approval of manuscript: All authors.

**Correspondence to:** Bin Liu. Department of Rheumatology and Immunology, Affiliated Hospital of Qingdao University, 16 Jiangsu Road, Qingdao 266003, China. Email: binliu72314@163.com. Shu-Han Yang; Zhe-Xiong Lian. Chronic Disease Laboratory, School of Medicine, South China University of Technology, 382 East Waihuan Road, Guangzhou 510006, China. Email: yangshh@scut.edu.cn; zxlian@scut.edu.cn.

**Background:** Splenomegaly is not just a consequence of numerous chronic and acute conditions but may also contribute to their severity, due to the interaction of the spleen with the gut microbiome. This study aimed to explore the effect of the gut microbiome on splenomegaly.

**Methods:** We used p40<sup>-/-</sup>IL-2R $\alpha$ <sup>-/-</sup> mice as a murine model of primary biliary cholangitis (PBC) as per our previous study. Splenomegaly was evaluated by spleen weight. Severity of liver inflammation was evaluated by hepatic mononuclear cell (MNCs) number and pathological score. Changes of immune cells in the spleen and liver were detected by flow cytometry. The effects of the gut microbiome on splenomegaly and liver inflammation were observed by combined antibiotic treatment in p40<sup>-/-</sup>IL-2R $\alpha$ <sup>-/-</sup> mice.

**Results:** A proportion of p40<sup>-/-</sup>IL-2R $\alpha$ <sup>-/-</sup> mice developed splenomegaly. The results revealed that liver mononuclear cells infiltration, histological scores of hepatic inflammation, and bile duct damage were positively correlated with the degree of splenomegaly. Hepatic CD4<sup>+</sup> and CD8<sup>+</sup> T cells numbers were significantly higher in mice with splenomegaly, and this was particularly observed in activated effector memory CD4<sup>+</sup> T and CD8<sup>+</sup> T cells. A proportion of some other immune cells including granulocytes, B, natural killer (NK), and CD8<sup>+</sup> T effector memory cells were also altered in the enlarged spleen. More importantly, administration of quadruple antibiotics to deplete gut microbiota relieved the splenomegaly of p40<sup>-/-</sup>IL-2R $\alpha$ <sup>-/-</sup> mice, significantly alleviated liver inflammation, and caused a significant reduction of liver and spleen T cell accumulation and activation; however, single antibiotics did not induce these changes.

**Conclusions:** Splenomegaly was associated with more severe liver inflammation in our PBC murine model, and this effect was reversed by quadruple antibiotic treatment.

**Keywords:** Primary biliary cholangitis (PBC); gut microbiome; splenomegaly; immune cells

Submitted Oct 18, 2021. Accepted for publication Feb 08, 2022.

doi: 10.21037/atm-21-5448

View this article at: <https://dx.doi.org/10.21037/atm-21-5448>

## Introduction

Splenomegaly is an abnormal enlargement of the spleen, frequently observed in sepsis, liver cirrhosis, myelofibrosis, and lymphoma (1-5). Splenomegaly is not a mere consequence of several conditions, but may also contribute to the clinical scenario, as represented by the left upper abdominal quadrant derived from the exerted pressure, anemia, and thrombocytopenia related to hypersplenism (6,7), high risk of bleeding from portal hypertension (8), and the possibility of spleen rupture (9). The pathophysiological basis of splenomegaly can be categorized into 3 main groups: increased splenic function, infiltration, and congestion. Immune-mediated disorders, such as rheumatoid arthritis (10) and primary biliary cholangitis (PBC) (11), can lead to hypertrophy of the spleen and then develop to splenomegaly. To date, there is no specific treatment for splenomegaly.

Recently, increasing evidence has suggested that gut microbiota plays a critical role in initiating host inflammatory response, particularly liver inflammation, which is due to the close crosstalk of the gut-liver axis (12). In pathological conditions, the increase of intestinal permeability leads to bacterial translocation and triggers chronic hepatic inflammation and fibrosis. The gut microbiome interacts with the host immune system (13) and also with the spleen, the largest secondary lymphoid organ (14,15), as the microbiome changes following splenectomy (16,17), which in turn ameliorates dysbiosis associated with liver cirrhosis (18). Further, the neonatal gut microbiota is central to spleen development (19), and germ-free mice have defective spleen myeloid cells (20). The gut microbiota also modulates systemic and splenic inflammatory cells induced by sleep deprivation and lipopolysaccharide (LPS) administration (21,22). The spleen-gut axis is further supported by the disappearance of murine intestinal immunoglobulin A (IgA)-secreting plasma cells after splenectomy (23), but additional evidence is needed to better define this interaction.

We have previously reported that  $p40^{-/-}IL-2R\alpha^{-/-}$  mice develop spontaneous autoimmune cholangitis and hepatic fibrosis, which resemble human PBC (24). Furthermore, based on our previous observation that  $p40^{-/-}IL-2R\alpha^{-/-}$  mice develop splenomegaly with enhanced liver T cell-mediated inflammation at 12 weeks of age, we investigated the significant effects of splenomegaly on liver inflammation and gut microbiome that are modulated by antibiotic treatment, ultimately suggesting that the gut

microbiota contributes to splenomegaly. We present the following article in accordance with the ARRIVE reporting checklist (available at <https://atm.amegroups.com/article/view/10.21037/atm-21-5448/rc>).

## Methods

### *Animal models*

We obtained  $IL-2R\alpha^{-/-}$  (B6.129S4-Il2ratm1Dw) and  $p40^{-/-}$  (B6.129S1-Il2btm1Jm) mice from The Jackson Laboratory (Bar Harbor, ME, USA), and  $p40^{-/-}IL-2R\alpha^{-/-}$  mice were subsequently generated using backcrossing. All mice were housed in a specific pathogen-free (SPF) environment. All mice experiments were approved by the Animal Ethics Committee of the South China University of Technology (No. 2017002), in compliance with the South China University of Technology guidelines for the care and use of animals.

### *Administration of antibiotics*

For antibiotics (ABX) mice models, the  $p40^{-/-}IL-2R\alpha^{-/-}$  mice were administered a cocktail of broad-spectrum ABX in their drinking water from 4 weeks until 12 weeks of age. The cocktail consisted of 1 mg/mL ampicillin, 0.35 mg/mL vancomycin, 1 mg/mL metronidazole, and 1 mg/mL neomycin (Sigma, St. Louis, MO, USA) in drinking water, and fresh antibiotics were administered every 3 days.

### *Liver histological grading*

Hematoxylin and eosin (H&E) staining of liver tissue was conducted as reported previously. The dimension of liver inflammation and bile duct damage was assessed by pathologists in a blind manner. The scores of portal inflammation, lobular inflammation, and bile duct injury were generated from the sum of the score of severity and frequency. First, the extent of portal and lobular inflammation was assessed according to the most serious lesions, and the score was as follows: 0, no change; 1, minimal inflammation; 2, mild inflammation; 3, moderate inflammation; and 4, severe inflammation. Similarly, the dimension of bile duct injury was evaluated according to the severity of the most serious lesions, and scored as follows: 0, no change; 1, epithelial damage (only cytoplasmic changes); 2, epithelial damage with cytoplasmic and nuclear changes; 3, nonsuppurative destructive cholangitis (NSDC); and 4,

bile duct loss. Frequency of bile duct injury was determined by the percentage of affected bile duct of each specimen, and scored as follows: 0, none; 1, 1–10%; 2, 11–20%; 3, 21–50%; and 4, over 50%.

### **Liver and spleen cell isolation**

Liver cells were isolated according to a previously reported method (24). In brief, fresh liver tissue was ground with a syringe handle, filtrated through a 200-mesh strainer, and temporarily kept in phosphate-buffered saline (PBS) with 0.2% bovine serum albumin (BSA). Then, the hepatic parenchymal and red blood cells were removed.

Splenomegaly was defined as a spleen weight of over 0.3 g (the mean weight of the spleens of the p40<sup>-/-</sup>IL-2R $\alpha$ <sup>-/-</sup> mice). The spleen was homogenized with 2 glass slides, suspended in PBS with 0.2% BSA, filtrated through a 200-mesh sieve, and erythrocytes were removed. The cell number was counted using a cell counting chamber with a microscope.

### **Flow cytometry**

We incubated 1×10<sup>6</sup> cells with anti-mouse CD16/CD32 antibody [Becton, Dickinson, and Co. (BD) Biosciences, Franklin Lakes, NJ, USA USA] for 15 min at 4 °C to block Fc-receptors and avoid nonspecific binding. Cells were then stained for 20 minutes at 4 °C with a mix of fluorescent antibodies, including PacificBlue-CD3 (17A2, BioLegend, San Diego, CA, USA), PE/Cy7-NK1.1 (PK136, BioLegend), V500-CD8 $\alpha$  (53-6.7, BioLegend), APC/Cy7-CD4 (RM4-5, BD Biosciences), FITC-CD44 (IM7, eBioscience, San Diego, CA, USA), FITC-Gr-1 (RB6-8C5, BD Biosciences), PerCP/Cy5.5-CD11c (N418, BioLegend), APC-CD11b (M1/70, BioLegend), BV510-B220 (RA3-6B2, BioLegend), and PerCP/Cy5.5-CD62L (MEL-14, BioLegend). Stained cells were detected using a FACSVerse Flow Cytometer (BD Biosciences). Flow data were analyzed using FlowJo software (Tree Star, Ashland, OR, USA).

### **Statistical analysis**

All data were presented as the mean  $\pm$  standard error of the mean (SEM), and differences were tested for using a 2-tailed unpaired Student's *t*-test using GraphPad Prism (GraphPad Software Inc., San Diego, CA, USA). We considered P<0.05 to indicate statistical significance.

## **Results**

### **Biliary inflammation following splenomegaly**

When p40<sup>-/-</sup>IL-2R $\alpha$ <sup>-/-</sup> mice were analyzed according to the presence of splenomegaly, liver mononuclear cells (MNCs) were present in significantly higher numbers in the presence of splenomegaly (*Figure 1*). Similarly, histological scores of portal inflammation, lobular inflammation, and bile duct damage were significantly higher in mice with splenomegaly (*Figure 1*), which also manifested as enlarged peripheral lymph nodes (*Figure S1*), indirectly supporting the link between liver inflammation and splenomegaly.

### **Liver and spleen immune cells**

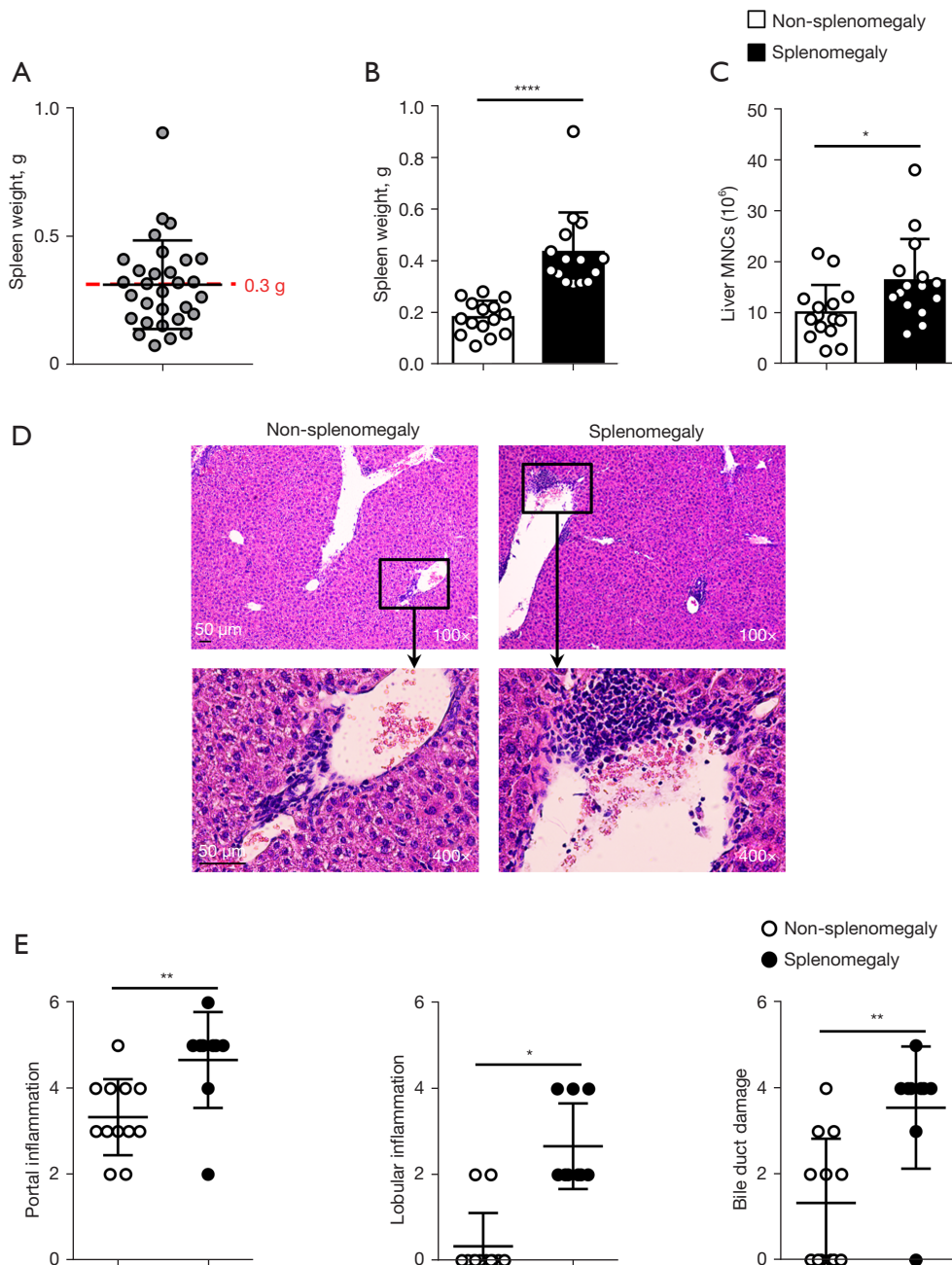
In agreement with our previous data, the absolute number and total proportion of liver CD4<sup>+</sup>, and CD8<sup>+</sup> T cells were significantly higher in the presence of splenomegaly, particularly when activated effector memory CD4<sup>+</sup> T (CD4<sup>+</sup> Tem) and CD8<sup>+</sup> T (CD8<sup>+</sup> Tem) cells (CD44<sup>+</sup>CD62L<sup>-</sup>) were evaluated (*Figure 2*). Conversely, there were no differences with splenomegaly in liver central memory CD8<sup>+</sup> T (CD8<sup>+</sup> Tcm) cells (CD44<sup>+</sup>CD62L<sup>+</sup>) (*Figure 2*).

Spleen MNCs showed no significant associations with splenomegaly (*Figure 3*), while we observed a decrease in granulocytes (Gr-1<sup>hi</sup>CD11b<sup>+</sup>) and B cells (B220<sup>+</sup>CD11c<sup>-</sup>). CD8<sup>+</sup> Tem but not CD4<sup>+</sup> Tem cells were increased in the enlarged spleen (*Figure 3*). The gating strategy image of flow cytometry is shown in *Figure S1B*.

### **Effects of antibiotic treatment on histology and immune cells**

We used combined antibiotics treatment, a standard and accepted method (25), in p40<sup>-/-</sup>IL-2R $\alpha$ <sup>-/-</sup> mice to explore the effect of gut microbiota on splenomegaly. The spleen weight and the number of spleen and liver MNCs were reduced following the antibiotics combination treatment, ultimately preventing splenomegaly, while the spleen weight was similar in p40<sup>-/-</sup>IL-2R $\alpha$ <sup>-/-</sup> mice treated with antibiotics and WT C57BL/6 mice (*Figure 4*). The scores of portal inflammation, lobular inflammation, and bile duct damage in mice treated with antibiotics also decreased (*Figure 4*). These results were not observed when single antibiotics were used (*Figure S2*).

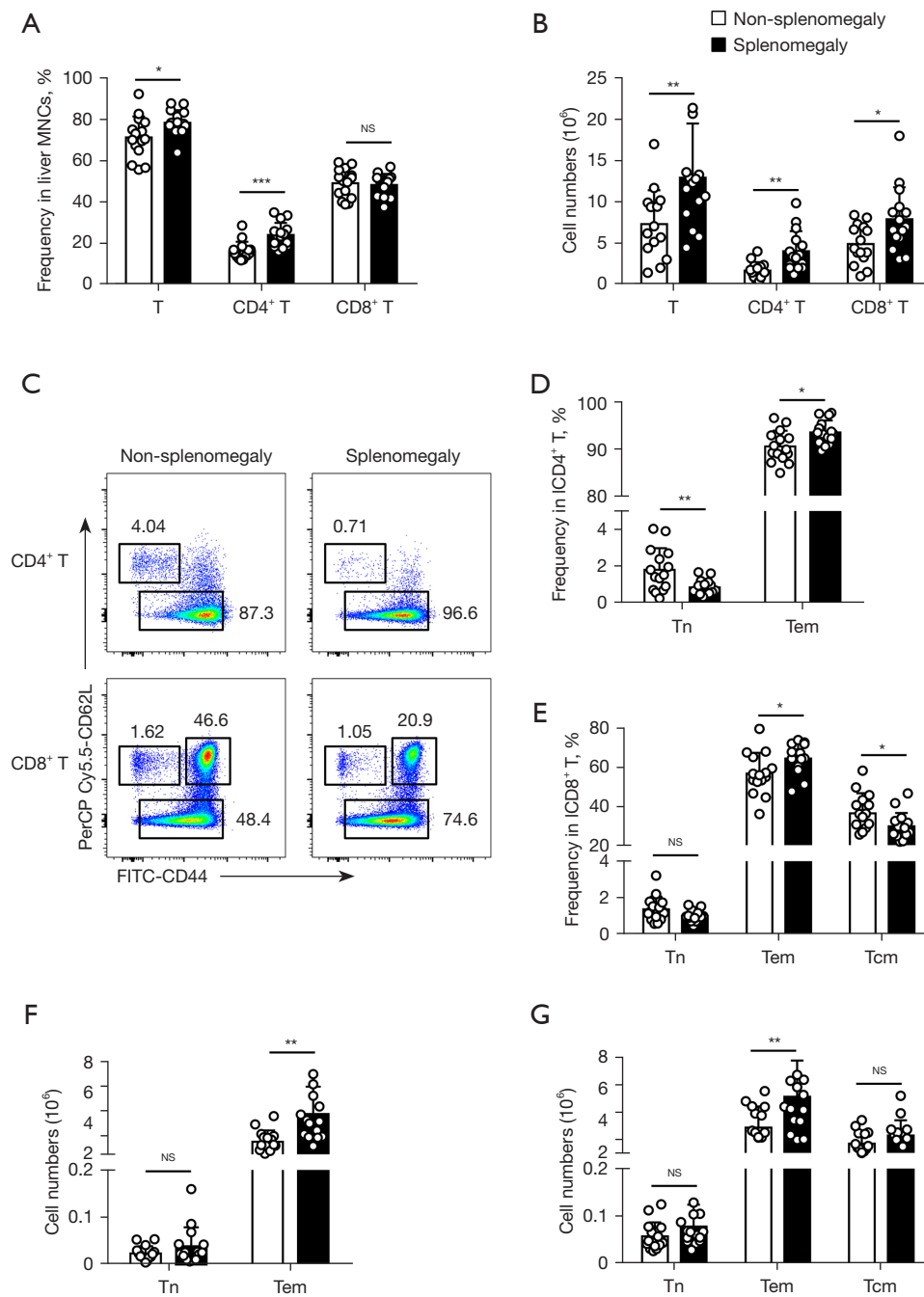
We observed a significant reduction of liver T cells and CD4<sup>+</sup> T and CD8<sup>+</sup> T cell subsets both in terms of frequency and number following treatment with four antibiotics



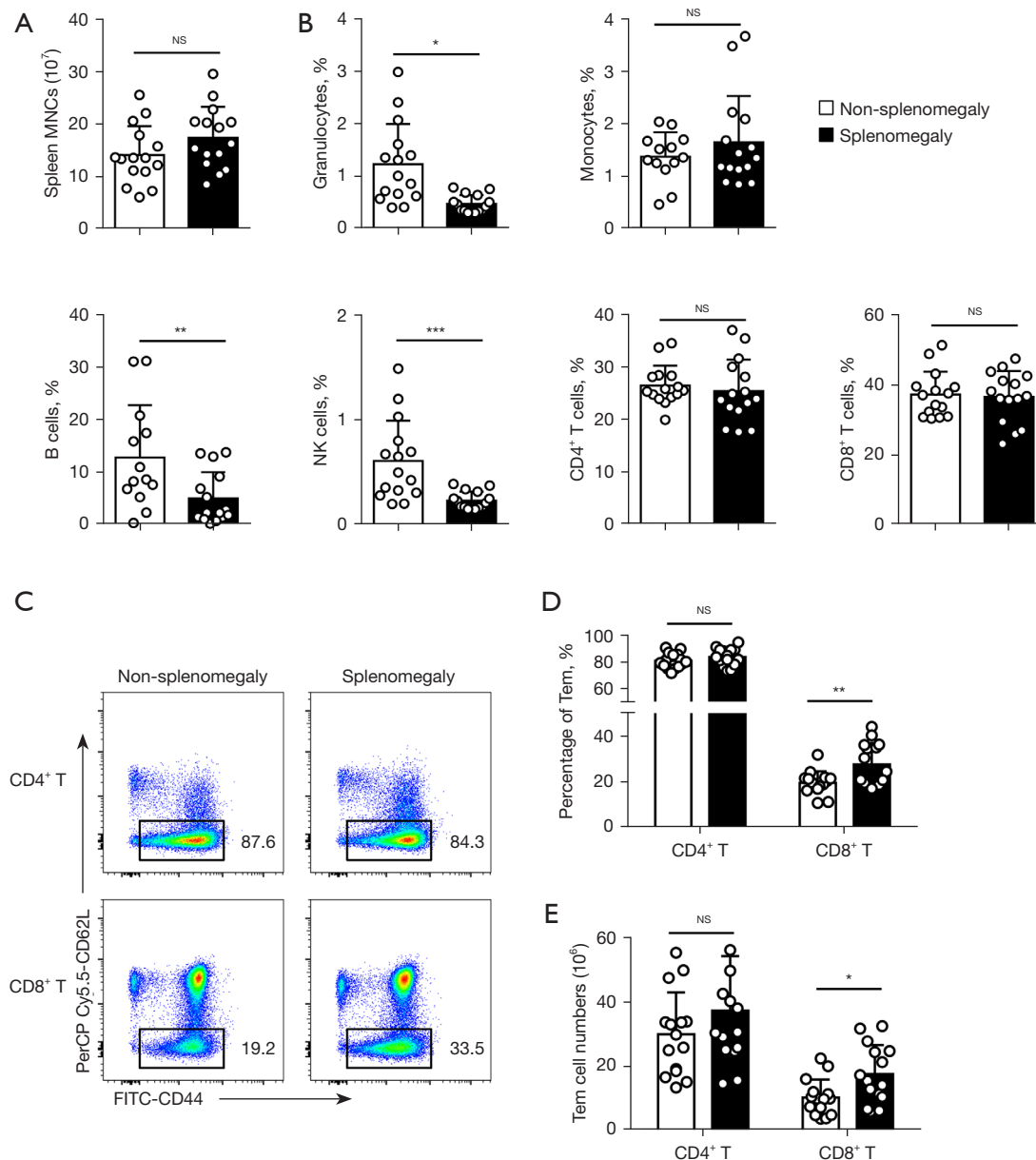
**Figure 1** Effects of splenomegaly in  $p40^{-/-}IL-2R\alpha^{-/-}$  mice. (A) Spleen weight of  $p40^{-/-}IL-2R\alpha^{-/-}$  mice ( $n=30$ ). (B) Spleen weight and (C) absolute number of hepatic mononuclear cells (MNCs) in  $p40^{-/-}IL-2R\alpha^{-/-}$  mice with ( $n=15$ ) or without splenomegaly ( $n=15$ ). (D) Representative H&E staining of liver tissue sections. (E) Grading of portal inflammation, lobular inflammation, and bile duct damage of  $p40^{-/-}IL-2R\alpha^{-/-}$  mice with ( $n=9$ ) or without splenomegaly ( $n=12$ ). \* $P<0.05$ ; \*\* $P<0.01$ ; \*\*\*\* $P<0.0001$ . H&E, hematoxylin and eosin.

(Figure 5). The changes of  $CD4^{+}$  T cell paralleled the decrease of  $CD4^{+}$  Tem subsets and the increase of naïve  $CD4^{+}$  T cell subsets, and similar changes were demonstrated in  $CD8^{+}$  T cells (Figure 5).

The frequency of spleen NK and B cells was increased, while  $CD4^{+}$  T and  $CD8^{+}$  T cells were reduced in  $p40^{-/-}IL-2R\alpha^{-/-}$  mice treated with antibiotics (Figure 6) with the resulting proportions being similar to wild-type mice.



**Figure 2** Liver T cell infiltration in  $p40^{-/-}IL-2R\alpha^{-/-}$  mice according to the development of splenomegaly, illustrated by (A,B) the percentage and absolute number of liver T cells, and CD4<sup>+</sup> T and CD8<sup>+</sup> T cell subsets, (C) the expression of CD44 and CD62L on hepatic CD4<sup>+</sup> T and CD8<sup>+</sup> T cells, (D,E) the frequency and (F,G) number of liver naive CD4<sup>+</sup> T (Tn) and effector memory CD4<sup>+</sup> T (Tem) as well as naive CD8<sup>+</sup> T, effector memory CD8<sup>+</sup> T, and central memory CD8<sup>+</sup> T (Tcm) cell subsets. The data of  $p40^{-/-}IL-2R\alpha^{-/-}$  mice with (n=15) or without splenomegaly (n=15) were combined from 3 independent experiments. \*P<0.05; \*\*P<0.01; \*\*\*P<0.001.

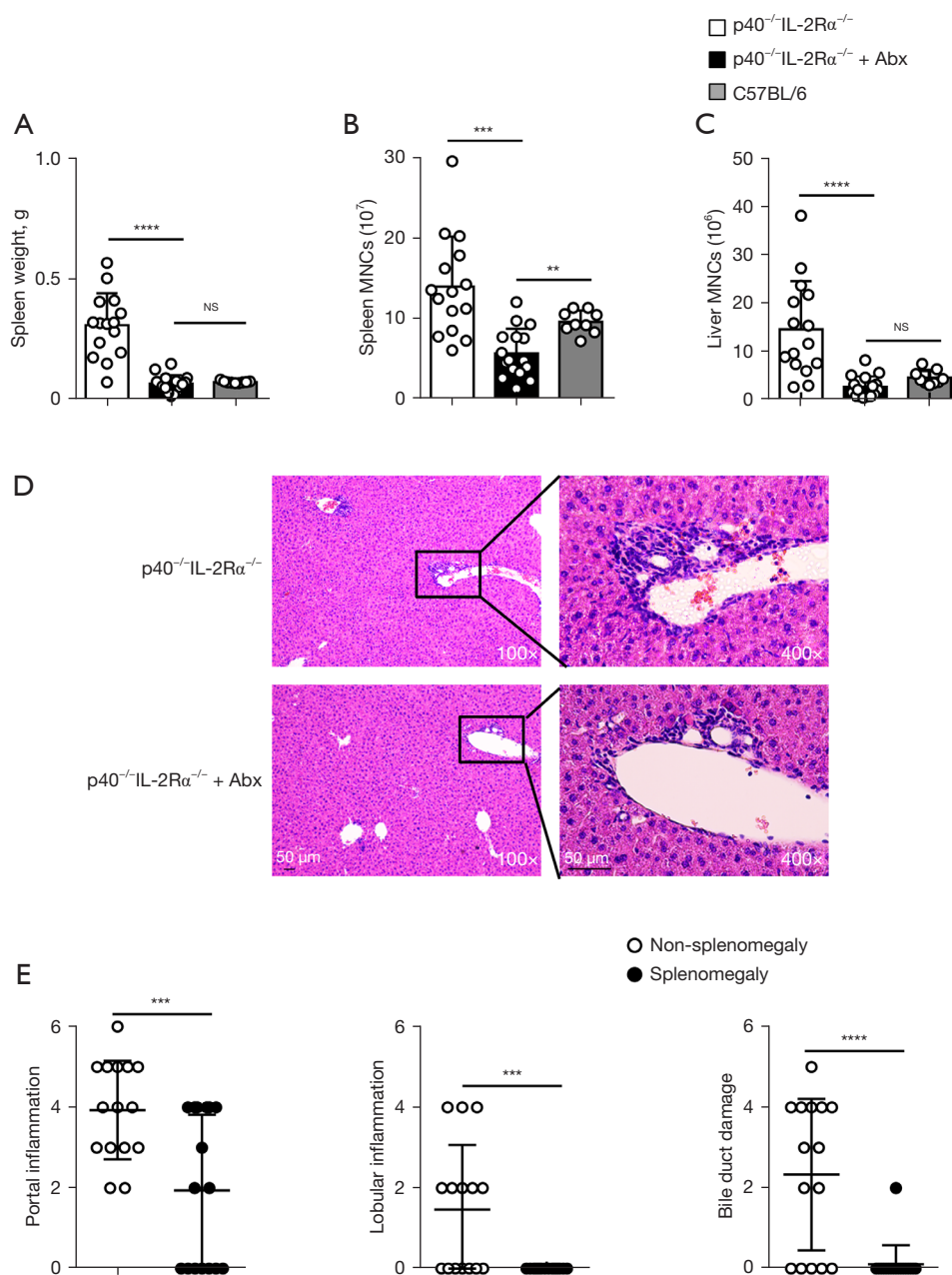


**Figure 3** Spleen and liver immune cell infiltration in  $p40^{-/-}IL-2R\alpha^{-/-}$  mice according to the development of splenomegaly, illustrated by (A) mononuclear cells, (B) frequency of granulocytes ( $Gr-1^{hi}CD11b^{+}$ ), monocytes ( $Gr-1^{int}CD11b^{+}$ ), B cell ( $B220^{+}CD11c^{-}$ ), and CD4<sup>+</sup> T and CD8<sup>+</sup> T cell subsets, (C) expression of CD44 and CD62L on spleen CD4<sup>+</sup> T and CD8<sup>+</sup> T cells, (D, E) frequency and number of liver CD4<sup>+</sup> Tem and CD8<sup>+</sup> Tem cells subsets. The data of  $p40^{-/-}IL-2R\alpha^{-/-}$  mice with ( $n=15$ ) or without splenomegaly ( $n=15$ ) were combined from 3 independent experiments. \* $P<0.05$ ; \*\* $P<0.01$ ; \*\*\* $P<0.001$ .

## Discussion

Our  $p40^{-/-}IL-2R\alpha^{-/-}$  mouse is a PBC model, which spontaneously develops portal lymphocytic infiltrates, liver inflammation, biliary ductular damage, and other autoimmune phenotypes modelling human disease, often

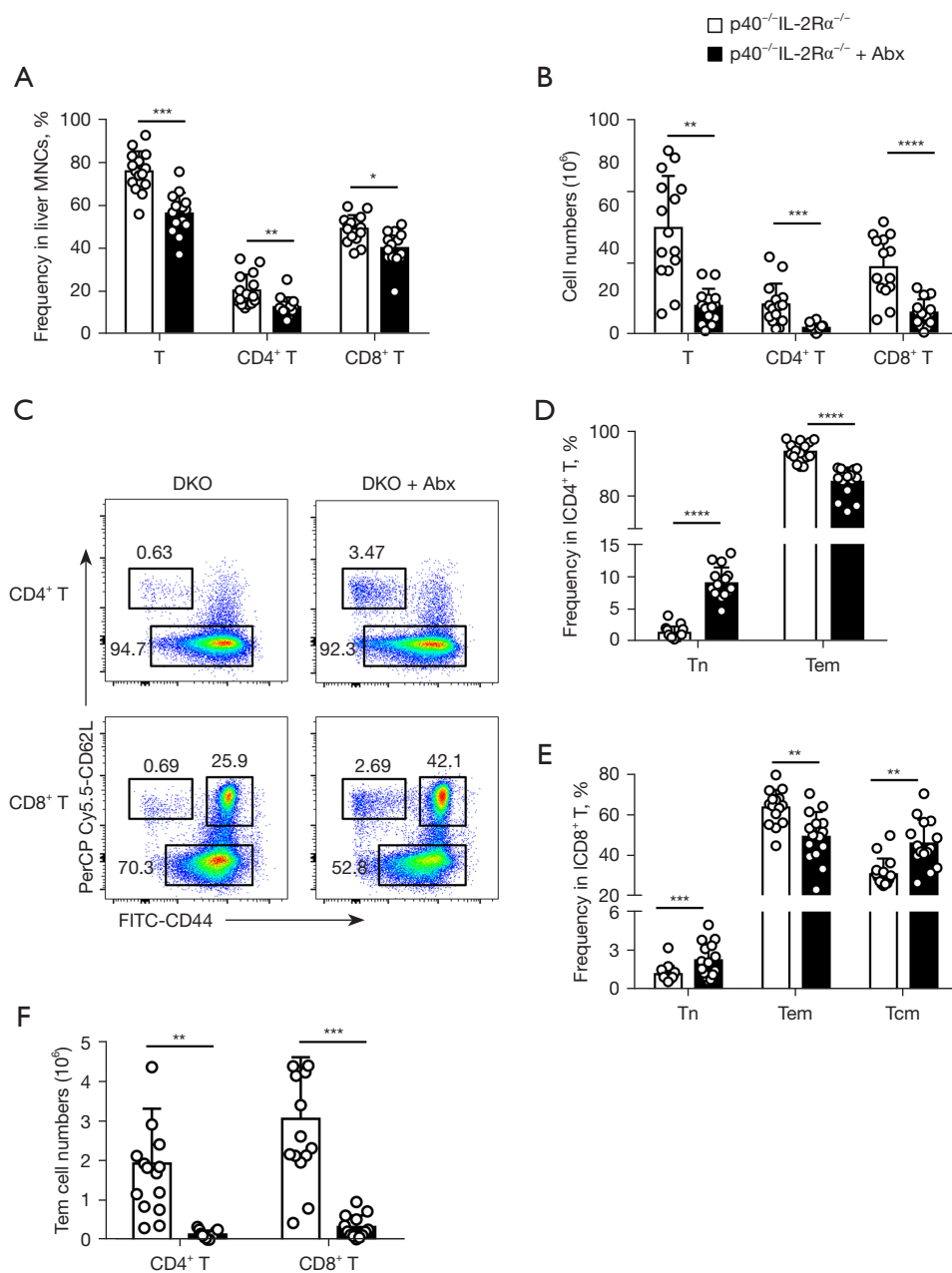
with splenomegaly (26), enhanced liver inflammation, and less severe colitis compared to the  $IL-2R\alpha^{-/-}$  model (24). Here, we reported for the first time that splenomegaly is associated with more severe liver inflammation in our PBC murine model, and that this effect is reversed by a quadruple antibiotic treatment.



**Figure 4** Changes in p40<sup>-/-</sup>IL-2Rα<sup>-/-</sup> mice according to the use of a combination of antibiotics (ABX). Spleen weight (A), number of spleen (B) and liver (C) MNCs of p40<sup>-/-</sup>IL-2Rα<sup>-/-</sup> mice control (n=15), p40<sup>-/-</sup>IL-2Rα<sup>-/-</sup> mice treated with ABX (n=16), and C57BL/6 mice (n=9). (D) Representative H&E staining of liver tissue sections. (E) Liver portal inflammation, lobular inflammation, and bile duct damage of p40<sup>-/-</sup>IL-2Rα<sup>-/-</sup> mice control (n=15) and p40<sup>-/-</sup>IL-2Rα<sup>-/-</sup> mice treated with ABX (n=16). \*\*P<0.01; \*\*\*P<0.001; \*\*\*\*P<0.0001. H&E, hematoxylin and eosin; MNCs; ABX, antibiotics.

The spleen serves as the largest secondary lymphoid organ in the body and plays an important immunological role to modulate inflammation (27). Splenomegaly is associated with multiple conditions (28,29) through

different mechanisms (30), in some cases resulting in spleen hyperactivity (31). Infections such as malaria, measles, typhoid fever, and viral hepatitis, as well as immune-mediated disorders, such as immune thrombocytic purpura,



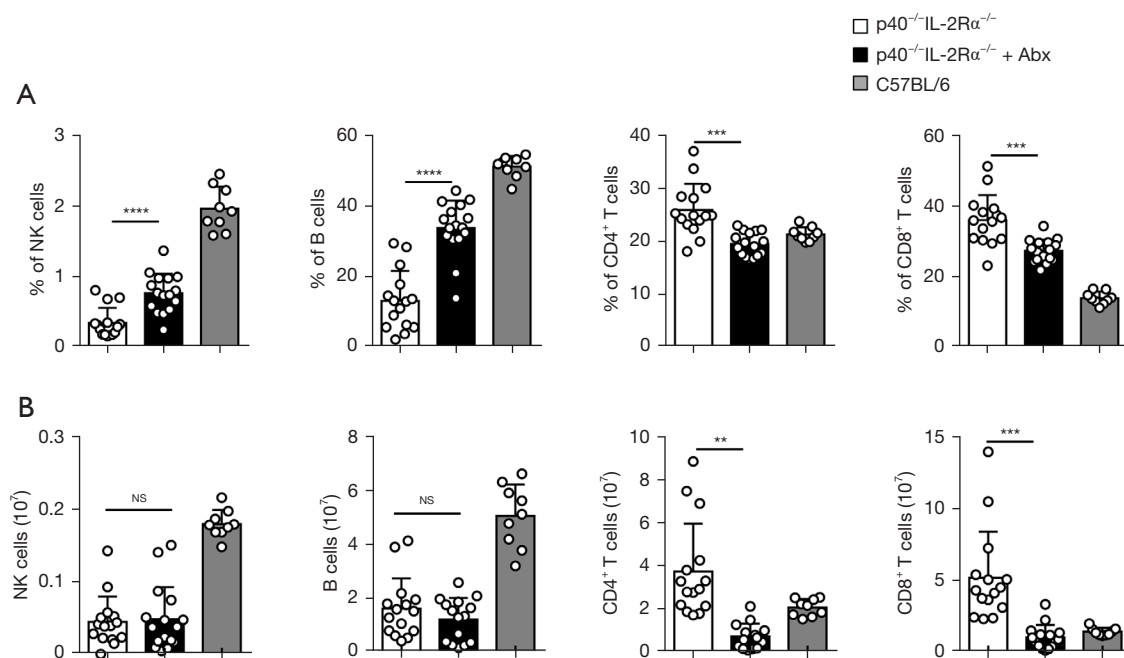
**Figure 5** Changes in  $p40^{-/-}IL-2R\alpha^{-/-}$  mice according to the use of a combination of antibiotics (ABX) in terms of the percentage (A) and absolute number (B) of liver T cells and CD4<sup>+</sup> T and CD8<sup>+</sup> T cell subsets, (C) expression of CD44 and CD62L on liver CD4<sup>+</sup> T and CD8<sup>+</sup> T cells, percentage of (D) naive CD4<sup>+</sup> T (Tn) and CD4<sup>+</sup> Tem, (E) naive CD8<sup>+</sup> T, CD8<sup>+</sup> Tem, and CD8<sup>+</sup> Tcm cell subsets, and (F) number of CD4<sup>+</sup> Tem and CD8<sup>+</sup> Tem cell subsets. Data of  $p40^{-/-}IL-2R\alpha^{-/-}$  mice (n=15) and treatment with ABX (n=16) were combined from three independent experiments. \*P<0.05; \*\*P<0.01; \*\*\*P<0.001; \*\*\*\*P<0.0001. ABX, antibiotics.

rheumatoid arthritis, and PBC (32-36), lead to follicular hyperplasia of the spleen, and it is thus not counterintuitive to hypothesize that splenomegaly may play a role in modulating chronic inflammation. Nonetheless, while the infiltration with inflammatory cells contributes to

splenomegaly, the number of spleen MNCs showed no difference between  $p40^{-/-}IL-2R\alpha^{-/-}$  mice according to spleen weight.

The liver and gut communicate directly through the biliary tract and portal circulation (37), and this provides





**Figure 6** Changes in p40<sup>-/-</sup>IL-2Rα<sup>-/-</sup> mice according to the use of a combination of ABX in terms of percentage (A) and absolute number (B) of spleen NK cells (NK1.1<sup>+</sup>CD3<sup>+</sup>), B cells (B220<sup>+</sup>CD11c<sup>-</sup>), and CD4<sup>+</sup> T and CD8<sup>+</sup> T cell subsets. The data of p40<sup>-/-</sup>IL-2Rα<sup>-/-</sup> mice (n=15), mice treated with ABX (n=16), and C57BL/6 mice (n=9) were combined from three independent experiments. \*\*P<0.01; \*\*\*P<0.001; \*\*\*\*P<0.0001. ABX, antibiotics; NK, natural killer.

an anatomical link to explain how intestinal bacteria may translocate to the liver via increased intestinal permeability (38). Pathogen-associated molecular patterns (PAMPs) are recognized by immune receptors on liver Kupffer cells and stellate cells (39), which activate T cells and initiate inflammatory cascade that ultimately leads to chronic inflammation and liver damage (40). We observed that splenomegaly is associated with more activated T cells infiltrating the liver, and that these effects were reversed by antibiotics, which also ameliorated splenomegaly, thus supporting the hypothesis that gut microbiota changes contribute to splenomegaly and possibly vice versa.

The spleen is a site where innate and adaptive immune responses against pathogens are initiated (41) and this process is disturbed in splenomegaly, particularly affecting T cells (42). Macrophages are the main innate immune cells in the spleen and play a pivotal role in splenomegaly due to their responsibility for the removal of old erythrocytes and apoptotic cells. Increased numbers of macrophages have been detected in the enlarged spleen caused by *Schistosoma* infection (43); however, we did not observe a significant change of monocytes in enlarged spleens of p40<sup>-/-</sup>IL-2Rα<sup>-/-</sup> mice. In our experimental setting, we observed a

change of several immune cells in the enlarged spleen, including granulocytes, B, NK, and CD8<sup>+</sup> Tem cells, while quadruple antibiotics caused a significant reduction of total spleen CD4<sup>+</sup> T and CD8<sup>+</sup> T cells, which may impair the immune response. However, the gut microbiota consisted of probiotic microbiota and pathogenic microbiota. Thus, identifying and specifically eliminating the pathogenic gut microbiota should be investigated in future work.

In conclusion, we demonstrated that the gut microbiota is associated with splenomegaly in a PBC murine model by inducing liver inflammation, and that antibiotics treatment alleviates both splenomegaly and immune cell changes. The gathered evidence suggests that novel approaches to splenomegaly and hypersplenism may result from microbiome modulation in an individualized fashion.

## Acknowledgments

We would like to thank Carlo Selmi and Eric Gershwin for their help in polishing our paper.

**Funding:** This work was supported by the Guangdong Introducing Innovative and Entrepreneurial Teams (2017ZT07S054), the National Natural Science Foundation

of China (82001730, 81873877, and 81671600), the Natural Science Foundation of Shandong Grants (ZR2016HM13), and the Fundamental Research Funds for the Central Universities in the South China University of Technology (2020ZYGXZR045).

## Footnote

**Reporting Checklist:** The authors have completed the ARRIVE reporting checklist. Available at <https://atm.amegroups.com/article/view/10.21037/atm-21-5448/rc>

**Data Sharing Statement:** Available at <https://atm.amegroups.com/article/view/10.21037/atm-21-5448/dss>

**Conflicts of Interest:** All authors have completed the ICMJE uniform disclosure form (available at <https://atm.amegroups.com/article/view/10.21037/atm-21-5448/coif>). The authors have no conflicts of interest to declare.

**Ethical Statement:** The authors are accountable for all aspects of the work in ensuring that questions related to the accuracy or integrity of any part of the work are appropriately investigated and resolved. All mice experiments were approved by the Animal Ethics Committee of the South China University of Technology (No. 2017002), in compliance with the South China University of Technology guidelines for the care and use of animals.

**Open Access Statement:** This is an Open Access article distributed in accordance with the Creative Commons Attribution-NonCommercial-NoDerivs 4.0 International License (CC BY-NC-ND 4.0), which permits the non-commercial replication and distribution of the article with the strict proviso that no changes or edits are made and the original work is properly cited (including links to both the formal publication through the relevant DOI and the license). See: <https://creativecommons.org/licenses/by-nc-nd/4.0/>.

## References

1. Pozo AL, Godfrey EM, Bowles KM. Splenomegaly: investigation, diagnosis and management. *Blood Rev* 2009;23:105-11.
2. Valdés-Ferrer SI, Rosas-Ballina M, Olofsson PS, et al. HMGB1 mediates splenomegaly and expansion of splenic CD11b+ Ly-6C(high) inflammatory monocytes in murine sepsis survivors. *J Intern Med* 2013;274:381-90.
3. Xu R, Zhang Z, Wang FS. Liver fibrosis: mechanisms of immune-mediated liver injury. *Cell Mol Immunol* 2012;9:296-301.
4. Barosi G, Bergamaschi G, Marchetti M, et al. JAK2 V617F mutational status predicts progression to large splenomegaly and leukemic transformation in primary myelofibrosis. *Blood* 2007;110:4030-6.
5. Ingle SB, Ingle CR. Splenic lymphoma with massive splenomegaly: Case report with review of literature. *World J Clin Cases* 2014;2:478-81.
6. Wagner KU, Claudio E, Rucker EB 3rd, et al. Conditional deletion of the Bcl-x gene from erythroid cells results in hemolytic anemia and profound splenomegaly. *Development* 2000;127:4949-58.
7. Motta I, Filocamo M, Poggiali E, et al. A multicentre observational study for early diagnosis of Gaucher disease in patients with Splenomegaly and/or Thrombocytopenia. *Eur J Haematol* 2016;96:352-9.
8. Sharma P, Kirnake V, Tyagi P, et al. Spleen stiffness in patients with cirrhosis in predicting esophageal varices. *Am J Gastroenterol* 2013;108:1101-7.
9. Tremblay D, Schwartz M, Bakst R, et al. Modern management of splenomegaly in patients with myelofibrosis. *Ann Hematol* 2020;99:1441-51.
10. Gorodetskiy V, Probatova N, Sidorova Y, et al. The non-leukemic T cell large granular lymphocytic leukemia variant with marked splenomegaly and neutropenia in the setting of rheumatoid arthritis - Felty syndrome and hepatosplenic T cell lymphoma mask. *Am J Blood Res* 2021;11:227-37.
11. Idilman IS, Venkatesh SH, Eaton JE, et al. Magnetic resonance imaging features in 283 patients with primary biliary cholangitis. *Eur Radiol* 2020;30:5139-48.
12. Ma HD, Zhao ZB, Ma WT, et al. Gut microbiota translocation promotes autoimmune cholangitis. *J Autoimmun* 2018;95:47-57.
13. Rosser EC, Mauri C. A clinical update on the significance of the gut microbiota in systemic autoimmunity. *J Autoimmun* 2016;74:85-93.
14. Yang W, Cong Y. Gut microbiota-derived metabolites in the regulation of host immune responses and immune-related inflammatory diseases. *Cell Mol Immunol* 2021;18:866-77.
15. Barrea L, Di Somma C, Muscogiuri G, et al. Nutrition, inflammation and liver-spleen axis. *Crit Rev Food Sci Nutr* 2018;58:3141-58.
16. Zhu H, Liu Y, Li S, et al. Altered gut microbiota after traumatic splenectomy is associated with endotoxemia. *Emerg Microbes Infect* 2018;7:197.
17. Wei Y, Chang L, Ishima T, et al. Abnormalities of the

- composition of the gut microbiota and short-chain fatty acids in mice after splenectomy. *Brain Behav Immun Health* 2021;11:100198.
18. Liu Y, Li J, Jin Y, et al. Splenectomy Leads to Amelioration of Altered Gut Microbiota and Metabolome in Liver Cirrhosis Patients. *Front Microbiol* 2018;9:963.
  19. Rosado MM, Aranburu A, Scarsella M, et al. Spleen development is modulated by neonatal gut microbiota. *Immunol Lett* 2018;199:1-15.
  20. Khosravi A, Yáñez A, Price JG, et al. Gut microbiota promote hematopoiesis to control bacterial infection. *Cell Host Microbe* 2014;15:374-81.
  21. Wang G, Wu X, Zhu G, et al. Dexmedetomidine alleviates sleep-restriction-mediated exaggeration of postoperative immunosuppression via splenic TFF2 in aged mice. *Aging (Albany NY)* 2020;12:5318-35.
  22. Zhang Y, Xie B, Chen X, et al. A key role of gut microbiota-vagus nerve/spleen axis in sleep deprivation-mediated aggravation of systemic inflammation after LPS administration. *Life Sci* 2021;265:118736.
  23. Carsetti R, Di Sabatino A, Rosado MM, et al. Lack of Gut Secretory Immunoglobulin A in Memory B-Cell Dysfunction-Associated Disorders: A Possible Gut-Spleen Axis. *Front Immunol* 2019;10:2937.
  24. Yao Y, Yang W, Yang YQ, et al. Distinct from its canonical effects, deletion of IL-12p40 induces cholangitis and fibrosis in interleukin-2R $\alpha$ (-/-) mice. *J Autoimmun* 2014;51:99-108.
  25. Iida N, Dzutsev A, Stewart CA, et al. Commensal bacteria control cancer response to therapy by modulating the tumor microenvironment. *Science* 2013;342:967-70.
  26. Terziroli Beretta-Piccoli B, Mieli-Vergani G, Vergani D, et al. The challenges of primary biliary cholangitis: What is new and what needs to be done. *J Autoimmun* 2019;105:102328.
  27. Mebius RE, Kraal G. Structure and function of the spleen. *Nat Rev Immunol* 2005;5:606-16.
  28. Curovic Rotbain E, Lund Hansen D, Schaffalitzky de Muckadell O, et al. Splenomegaly - Diagnostic validity, work-up, and underlying causes. *PLoS One* 2017;12:e0186674.
  29. Sjoberg BP, Menias CO, Lubner MG, et al. Splenomegaly: A Combined Clinical and Radiologic Approach to the Differential Diagnosis. *Gastroenterol Clin North Am* 2018;47:643-66.
  30. Bedu-Addo G, Bates I. Causes of massive tropical splenomegaly in Ghana. *Lancet* 2002;360:449-54.
  31. McKenzie CV, Colonne CK, Yeo JH, et al. Splenomegaly: Pathophysiological bases and therapeutic options. *Int J Biochem Cell Biol* 2018;94:40-3.
  32. Swaroop J, O'Reilly RA. Splenomegaly at a university hospital compared to a nearby county hospital in 317 patients. *Acta Haematol* 1999;102:83-8.
  33. Leoni S, Buonfrate D, Angheben A, et al. The hyper-reactive malarial splenomegaly: a systematic review of the literature. *Malar J* 2015;14:185.
  34. Haqshenas G, Shivaprasad HL, Woolcock PR, et al. Genetic identification and characterization of a novel virus related to human hepatitis E virus from chickens with hepatitis-splenomegaly syndrome in the United States. *J Gen Virol* 2001;82:2449-62.
  35. Scherer HU, Häupl T, Burmester GR. The etiology of rheumatoid arthritis. *J Autoimmun* 2020;110:102400.
  36. Sun C, Xiao X, Yan L, et al. Histologically proven AMA positive primary biliary cholangitis but normal serum alkaline phosphatase: Is alkaline phosphatase truly a surrogate marker? *J Autoimmun* 2019;99:33-8.
  37. Wang R, Tang R, Li B, et al. Gut microbiome, liver immunology, and liver diseases. *Cell Mol Immunol* 2021;18:4-17.
  38. Ju C, Tacke F. Hepatic macrophages in homeostasis and liver diseases: from pathogenesis to novel therapeutic strategies. *Cell Mol Immunol* 2016;13:316-27.
  39. Acharya C, Sahingur SE, Bajaj JS. Microbiota, cirrhosis, and the emerging oral-gut-liver axis. *JCI Insight* 2017;2:94416.
  40. Tilg H, Cani PD, Mayer EA. Gut microbiome and liver diseases. *Gut* 2016;65:2035-44.
  41. Bronte V, Pittet MJ. The spleen in local and systemic regulation of immunity. *Immunity* 2013;39:806-18.
  42. Li Y, Yue H, Yang S, et al. Splenomegaly induced by anemia impairs T cell movement in the spleen partially via EPO. *Mol Immunol* 2019;112:399-405.
  43. Kong D, Zhou C, Guo H, et al. Praziquantel Targets M1 Macrophages and Ameliorates Splenomegaly in Chronic Schistosomiasis. *Antimicrob Agents Chemother* 2018;62:e00005-17.
- (English Language Editors: B. Meiser and J. Jones)

**Cite this article as:** Wang CB, Wang Y, Yao Y, Wang JJ, Tsuneyama K, Yang Q, Liu B, Selmi C, Gershwin ME, Yang SH, Lian ZX. The gut microbiome contributes to splenomegaly and tissue inflammation in a murine model of primary biliary cholangitis. *Ann Transl Med* 2022;10(9):507. doi: 10.21037/atm-21-5448