

IL-6 inhibitors effectively reverse post-infarction cardiac injury and ischemic myocardial remodeling via the TGF- β 1/Smad3 signaling pathway

JIAHONG WANG^{1*}, MINGHONG WANG^{2*}, XIANCHENG LU³, YI ZHANG⁴, SILIANG ZENG⁵, XIN PAN⁶, YIMENG ZHOU¹, HUI WANG⁷, NANNAN CHEN¹, FENGFENG CAI⁴ and EWELINA BISKUP^{7,8}

¹Department of Cardiology, Yangpu Hospital, School of Medicine, Tongji University, Shanghai 200090; ²Department of Health Management Center, Shanghai Public Health Clinical Center, Shanghai 201508; ³Department of Nutrition, Shanghai Yangpu Hospital of Traditional Chinese Medicine; ⁴Department of Breast Surgery, Yangpu Hospital, School of Medicine, Tongji University, Shanghai 200090; ⁵Department of Rehabilitation Therapy, Shanghai Normal University Tianhua College, Shanghai 201815; ⁶Institute for Regenerative Medicine, Shanghai East Hospital, School of Medicine, Tongji University, Shanghai 200123; ⁷Laboratory of Tumor Molecular Biology, School of Basic Medical Sciences, Shanghai University of Medicine and Health Sciences, Shanghai 201318, P.R. China; ⁸Department of Advanced Biomedical Sciences, Division of Cardiology, Federico II University, I-580131 Naples, Italy

Received March 13, 2022; Accepted June 17, 2022

DOI: 10.3892/etm.2022.11513

Abstract. Approximately one in four myocardial infarctions occur in older patients. The majority of therapeutic advances are either not appropriate or not tested in elderly patients. The main reasons for deviating from the guidelines are justified concerns regarding the effectiveness of the recommended forms of therapy, fear of adverse drug reactions and ethical concerns. Targeting interleukin 6 (IL-6) for ventricular remodeling after cardiovascular damage is a feasible alternative to standard polypharmaceuticals, but the underlying molecular mechanisms are not well understood. Continuous activation of the IL-6-associated cytokine receptor gp130 leads to cardiomyopathic hypertrophy. TGF β 1 is involved in forming fibrosis in various organs, and its overexpression can cause myocardial hypertrophy and fibrosis. IL-6 has been hypothesized to be indirectly involved in cardiac remodeling via the TGF β 1/Smad signaling transduction pathway. In the

present study, a rat model of acute myocardial ischemia, IL-6 and IL-6 receptor blockers were injected directly into the necrotic myocardium. Changes in cardiac function, myocardial infarction area, myocardial collagen, necrotic myocardial fibrosis and levels of TGF β 1, IL-6 and MMP2/9 were quantified in myocardial tissue fibrosis by ELISA. The present study demonstrated that IL-6 stimulated myocardial fibrosis through the TGF β 1-Smad-MM2/9 signaling transduction pathway. Overall, this provided a solid foundation for understanding the relationship between IL-6 and ventricular remodeling.

Introduction

Data increasingly points to the role of interleukin 6 (IL-6) in the etiology and progression of heart failure caused by post-myocardial infarction (1-3). The immediate and long-term consequences of cardiac insufficiency and heart failure are of utmost importance to patients. Cardiac remodeling processes differ significantly in extent between individuals and are often limited (4,5). Even though it remains unclear how the inflammatory response and increased oxidative stress contributes to myocardial necrosis, it is undeniable that both myocardial infarction (MI) and the gold standard treatment, percutaneous coronary intervention, cause IL-6 to increase in cardiac tissue, which increases its vulnerability to permanent damage (6-8).

Current studies on ventricular remodeling indicate that the ventricular remodeling mechanism involves changes in the nervous and endocrine systems, the constellation of cytokines, the transduction pathways of cellular signals and mutation patterns (9,10). The TGF β 1-Smad3-MMP2/9 pathway has been identified as a common pathway responsible for tissue fibrosis (11). As a signal transduction factor of TGF β 1, Smad protein is also involved in cardiac development, cell proliferation, growth and apoptosis. Smad protein can interact with

Correspondence to: Dr Fengfeng Cai, Department of Breast Surgery, Yangpu Hospital, School of Medicine, Tongji University, 450 Tengyue Road, Shanghai 200090, P.R. China
E-mail: caifengfeng@tongji.edu.cn

Dr Xin Pan, Institute for Regenerative Medicine, Shanghai East Hospital, School of Medicine, Tongji University, 1800 Yuntai Road, Shanghai 200123, P.R. China
E-mail: xinpanpx@163.com

*Contributed equally

Key words: interleukin 6, interleukin 6 inhibitor, myocardial infarction, rejuvenation, TGF β 1/Smad3, ventricular remodeling

other transcription factors and regulate its activity through cytokines (12,13).

Myocardial injury severity determines the development of ventricular remodeling, and rational drug treatment is important for improving this pathological process (8,10). For ventricular remodeling, current therapeutic drugs such as β -blockers, inhibitors of the angiotensin-converting enzyme (ACE) or antagonists of angiotensin II receptors, are often used together (14,15). At present, the most commonly used ACEIs are benazepril, captopril and ramipril. In addition, drugs that inhibit ventricular remodeling also have calcium channel blockers, which can selectively block Ca^{2+} . The Ca^{2+} channel on the cell membrane decreases the intracellular Ca^{2+} concentration, which helps reverse myocardial remodeling. Statins, including simvastatin, prevent hypertrophy and fibrosis of cardiomyocytes. Cardiomyocytes are inhibited from synthesizing RhoA and Rho-GTPase by statins, which prevent the formation of fibroblasts, tissue fibrosis and cardiac hypertrophy (8,16).

The majority of cardiology cases are revealed in biologically older individuals, either because of chronology or premature aging, such as autoimmune, chronic inflammatory or musculoskeletal conditions. Almost a quarter of all patients with heart attacks are over the age of 75 years old. In addition to heart disease in elderly patients, a significant increase in younger patients with heart damage due to comorbidities or unhealthy lifestyle habits is expected to be observed. In older patients, myocardial infarction, recurrences and heart failure will be more common, and the prognosis will be worse compared with younger patients, with a mortality rate of 20-25% in hospitals. In addition, patient mortality increases almost exponentially with increasing age (9,17,18). Patients in their eighth decade of life have a mortality rate of 17%, and patients in their ninth decade of life have a mortality rate of 33% (19). Therefore, it is important to preserve the cardiac muscle following an infarction. It is hypothesized that blocking IL-6 can prevent myocyte senescence, thereby allowing repair, regeneration and maintenance of cardiac tissue (20-22).

The majority of patients are multimorbid and elderly, so combination therapy is often complicated and should be avoided. Thus, more potent drugs are needed. Identifying new pathophysiological patterns that could be used as therapeutical targets is a need that has not been met. Consequently, the use of IL-6 receptor inhibitors has been investigated as a possible candidate for restoring cardiac function (23,24). The present study examined myocardial remodeling induced by IL-6 receptor inhibitors, evidenced by reduction in infarction size, collagen content and inflammation of the myocardium.

Materials and methods

Animal model. A total of 80 male Sprague-Dawley (SD) rats aged 5 months (average body weight, 300-330 g) were housed in a certified SPF grade facility (Tongji University Laboratory Animal Center, Shanghai, China) with individually ventilated cages and the following conditions: Temperature, 20-24°C; relative humidity, 30-70%; 12-h light-dark cycle (8:00 a.m. to 8:00 p.m.); and free access to food and water. All experiments were performed in accordance with the protocols approved by the Animal Care and Use Committee at Tongji University.

This research proposal was approved by the Ethics Committee of Yangpu Hospital, School of Medicine, Tongji University (approval no. LL-2021-SCI-006).

The myocardial infarction model was established in rats by ligating the left anterior descending coronary artery (LAD). SD rats were first fixed on the operating table and anesthetized with an intraperitoneal injection of sodium pentobarbital (formulated as a 2% solution at a dose of 35 mg/kg). The skin was cut along the left iliac crest and the sternal xiphoid line, muscles and the pericardium were separated. LAD was ligated to a depth of 0.3-0.5 mm under aseptic conditions, without any other injuries (intentional or unintentional) in LAD. V2 lead electrocardiogram was performed postoperatively to determine whether it demonstrated ST-segment elevation and gradual pathological Q waves. The myocardial infarction model was validated by observing the local myocardial color paleness and echocardiography to demonstrate the local myocardial segmental motility disturbances. The acute myocardial infarction (AMI)-rat standard was successfully established using this model. Only AMI rats that met all standard requirements (permanent LAD ligation and proper LAD ligation confirmed by electrocardiography) were included in the experimental groups.

Animal grouping. The rats were randomly divided into four groups: i) Normal control group without any treatment, the N group (n=20); ii) LAD ligation with an injection of normal saline, the LINS group (n=20); iii) LAD ligation with an injection of IL-6 recombinant protein (cat. no. PHC0066; Thermo Fisher Scientific, Inc.), the LIIL group (n=20); and iv) LAD ligation with injection of IL-6 receptor inhibitor (Tocilizumab; cat. no. A2012; Selleck Chemicals), the LIILR group (n=20). Before the treatments, humane endpoint criteria were established, the parameters including labored breathing, obvious loss of body weight (>25%), prostration, unresponsiveness to external stimuli and a drop in body temperature ($\pm 2^\circ\text{C}$) (24). When rats appeared with one or more of aforementioned reactions, they were promptly euthanized. Animal care staff monitored the rats daily, and no rats reached the humane endpoints before the end of the present study. Overall, 10-50% of the rats died from myocardial infarction during or after surgical operation and were immediately euthanized with overdose of sodium pentobarbital by intraperitoneal injection in conformity to their vital signs (apnea and cessation of heart-beat). The anesthetic dose of sodium pentobarbital in rats was 30 mg/kg, the euthanasia dose was 150 mg/kg (25).

Animal treatment in specific groups. In the LINS group, the LAD was ligated. After the successful preparation of the myocardial infarction model, the AMI area was divided into four points and injected with 20 μl of physiological NaCl each (a total of 80 μl) at a distance of 1-2 cm. In the LIIL group and LIILR group, IL-6 recombinant protein (1.8 mg/kg) (26,27) or IL-6 receptor inhibitor (50 mg/kg) (28), respectively, were accordingly injected into the four points in the myocardial infarction area.

Cardiac function test. The Acuson Sequoia C256 ultrasound systems (Siemens AG) linear array probe was used at a frequency of 8 MHz and detection depth of 2 cm to determine

the heart's function at 1 and 4 weeks after surgery. Rats were anesthetized by intraperitoneal injection of sodium pentobarbital. The rat's chest hair was scraped off, the rat was fixed on its back and connected to the V2 lead electrocardiogram. The probe was placed in the rat's chest, and the two-dimensional ultrasound indicated the level of the short axis of the fundus near the papillary muscle. Subsequently, M-mode ultrasound was used to determine the left ventricular end-diastolic diameter (LVEDD) and left ventricular end-systolic diameter (LVESD) of each group of the left ventricular. The left ventricular fractional shortening (LVFS) was calculated using the Teichholtz formula (29), $[\text{Volume}=7D^3/(2.4 + D)]$, where D represents the ventricular diameter (30), and values of the left ventricular ejection fraction (LVEF) were calculated to assess cardiac function. Each set of data illustrated the average of three consecutive cardiac cycles.

Histopathological studies. After anesthetizing rats with an excess of pentobarbital, their hearts were removed by a thoracotomy and cut along the ligature line to obtain the largest cross-sectional area of the left ventricle. Sections were used for Masson staining, hematoxylin and eosin (HE) staining and immunohistochemistry (IHC) (27), while the remains were used to measure myocardial inflammatory response indicators myeloperoxidase (MPO), reactive oxygen species (ROS), interleukin 6 (IL-6), transforming growth factor β 1 (TGF β 1) and matrix metalloproteinase-2/9 (MMP2/9). The remaining hearts tissues were harvested, homogenized and centrifuged (12,000 \times g) at 4°C for 10 min in 300 μ l CTAB buffer [50 mM CTAB (cat. no. H5882; MilliporeSigma) in 50 mM potassium phosphate buffer, pH 6.0]. The tissue supernatant was harvested and used for protein quantitative analysis with a Bicinchoninic Acid protein assay kit (cat. no. 23227; Thermo Fisher Scientific, Inc.). The tissue supernatant was stored at -80°C until used for ELISA assays. MPO in heart homogenate was determined using rat-specific ELISA kits (cat. no. HK105-01; Hycult Biotech Inc.). ROS was measured by rat ROS ELISA kit (cat. no. LS-F9759-1; Lifespan Biosciences). Interleukin 6 (IL-6) was assayed by rat IL-6 ELISA (for lysates) kit (cat. no. ERA32RB; Thermo Fisher Scientific, Inc.). TGF β 1 was determined by TGF β 1 rat ELISA kit (cat. no. BMS623-3; Thermo Fisher Scientific, Inc.). MMP2 was measured by rat MMP2 ELISA kit (cat. no. LS-F32418-1; Lifespan Biosciences). MMP9 was assayed by rat MMP9 ELISA kit (cat. no. LS-F5605-1; Lifespan Biosciences). ELISA assays were performed according to the manufacturer's instructions.

HE staining. HE staining was performed for pathological evaluation (27). Briefly, the tissue was fixed using a 10% formalin solution for 7 days at room temperature. These samples were then paraffin-embedded, and cut into 5- μ m sections, placed on a slide and dried in a 60°C oven for 30 min. The slide was deparaffinized using xylene, rehydrated using 100, 90, 80 and 70% alcohol, and washed under running tap water. Subsequently, the slides were stained with hematoxylin at room temperature for 10 min, and then washed in running tap water to remove excess solution. Slides were differentiated in 1% concentrated hydrochloric acid diluted in 70% ethanol for 30 sec and washed again under running tap water for 1 min.

The sections were then counterstained with eosin for 2 min at room temperature, and dehydrated very quickly through 95 and 100% alcohol, and cleared by 100% xylene. Coverslips were then mounted on the slides using resinous mounting medium. The images were collected using a light microscope (BX43; Olympus Corporation).

Masson staining. Paraffin sections were prepared from animal myocardial tissue. Masson staining was performed to evaluate the size of the infarct and degree of fibrosis in the marginal zone. The formalin-fixed, paraffin-embedded tissues of hearts were cut into 5- μ m sections and affixed on slides, dried in a 60°C oven for 30 min, defaraffinized with xylene, rehydrated in a graded series of alcohols (100, 90, 80 and 70%), and washed under running tap water. Next, the sections were stained according to the manufacturer's instructions of the Masson's trichrome staining kit (cat. no. G1340; Beijing Solarbio Science & Technology Co., Ltd.). The sections were dehydrated very quickly through 95 and 100% alcohol, cleared by xylene and then coverslips were mounted on glass slides using resinous mounting medium. Under the light microscope (BX43; Olympus Corporation), the cardiomyocytes presented with red cytoplasm, black nucleus and blue-green collagen fibers. A total of three sections were selected from each animal. The left ventricular collagen area ratio to the left ventricular area was determined as myocardial infarct size under a low-power field (magnification, \times 2.5). Local myocardial collagen and inflammatory response were observed under a high power objective lens (20X magnification objective). ImageJ software (National Institutes of Health) was used to measure the infarct size or fibrosis area and total area. Each tissue was measured with 5 different regions. The percentage of infarct size or fibrosis area was calculated as the infarct size or fibrosis-positive area divided by the total area.

IHC. Animal myocardial tissues were collected immediately after the rats were sacrificed and fixed overnight with 4% neutral formalin at room temperature and embedded in paraffin. The sections were subjected to IHC to determine the levels and distributions of IL-6 and TGF β 1. Sections (5- μ m) were deparaffinized and rehydrated, and then rinsed in distilled water for 5 min. Slides were microwaved in 0.01 M citrate antigen retrieval buffer pH 6.0 until boiling for at least 15 min, after which they were left to cool to room temperature. The slides were washed with phosphate-buffered saline (PBS) for 5 min and submerged in 3% hydrogen peroxide for 10 min at room temperature to block endogenous peroxidase. This was followed by submersion in blocking reagent (cat. no. 20773-M; MilliporeSigma) for 1 h at room temperature in a humidified, light-protected chamber and then washing with PBS three times. Next, sections were stained with primary and secondary antibodies. The following primary antibodies were used: Rabbit anti-IL-6 (1:100; cat. no. ab6672; Abcam) and rabbit anti-TGF β 1 (1:100; cat. no. ab92486; Abcam). Tissue sections were incubated with a primary antibody overnight at 4°C. Subsequently, slides were washed with PBS and incubated with goat anti-rabbit IgG horseradish peroxidase-conjugated secondary antibody (1:500; cat. no. sc-2004; Santa Cruz Biotechnology, Inc.) at room temperature for 1 h. Next, the sections were washed in PBS and visualized with a DAB

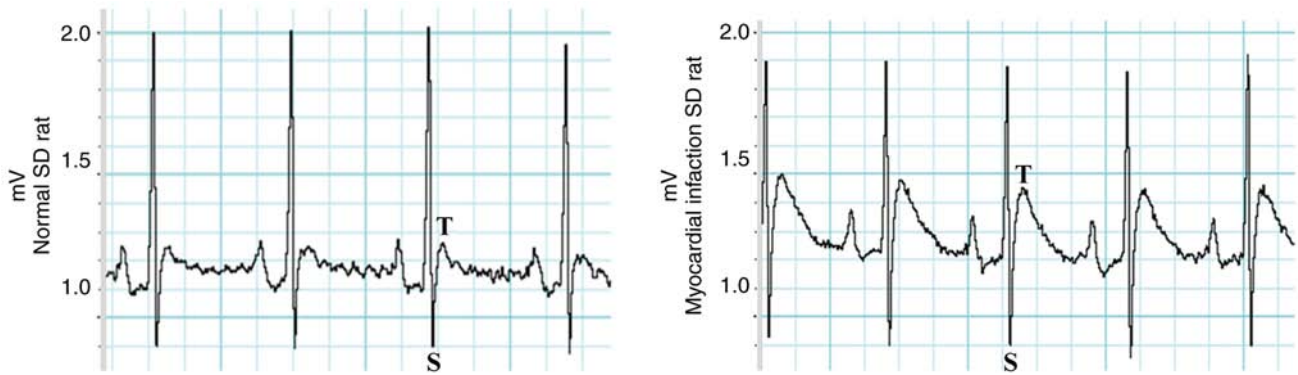


Figure 1. Changes in the record of the bipolar limb lead electrocardiogram of rats after anesthesia. ST segment elevation and the modeling in a standard acute myocardial infarction rat. SD, Sprague-Dawley.

substrate kit (cat. no. ab64238; Abcam) according to the manufacturer's instructions. This was followed by incubation with hematoxylin for 3 min at room temperature and washing with PBS three times. Finally, the sections were dehydrated very quickly using 95 and 100% alcohol and cleared using xylene, and then coverslips were mounted on the slides using resinous mounting medium. Images were observed using an Axio Observer Z1 microscope (Carl Zeiss AG).

Statistical analysis. The SPSS 22.0 software (IBM Corp.) was used for the analyses. All data were expressed as mean \pm standard deviation. Comparisons of multiple groups were analyzed using one-way analysis of variance (ANOVA) with Bonferroni's correction. GraphPad Prism 5.0 (GraphPad Software, Inc.) software was used to present statistical results. Animal survival curves were assessed using the Kaplan-Meier method. $P < 0.05$ was considered to indicate a statistically significant difference.

Results

Standardization of the acute myocardial infarction rat model. The standard AMI rat model and the postoperative validation points were established. Electrocardiograms (ECGs) of all AMI rats exhibited electrocardiographic ST-segment elevation, as presented in Fig. 1.

Survival curve of the animals. The survival of the rats was monitored for 2 weeks after myocardial infarction modeling. Rat mortality was not reported in the N group (survival rate was 100%). Compared with the N group, LAD ligation and normal saline injection (LINS group) resulted in high mortality, with a survival rate of 70%. LAD-ligation and IL-6-injection (LIIL group) had the highest mortality. The LIILR group had a significantly decreased mortality rate (survival rate of 90%) compared with the LIIL group ($P = 0.0068$). The survival curves of each group are depicted in Fig. 2.

Effect of IL-6 and its receptor inhibitor on cardiac function. Changes in cardiac function were measured using an Acuson Sequoia C256 ultrasound systems (Siemens AG) at 1 and 2 weeks after LAD ligation-induced myocardial infarction (Fig. 3). In the LINS group, the LVFS and the LVEF demonstrated a gradual decline, with a progressive LVESD and

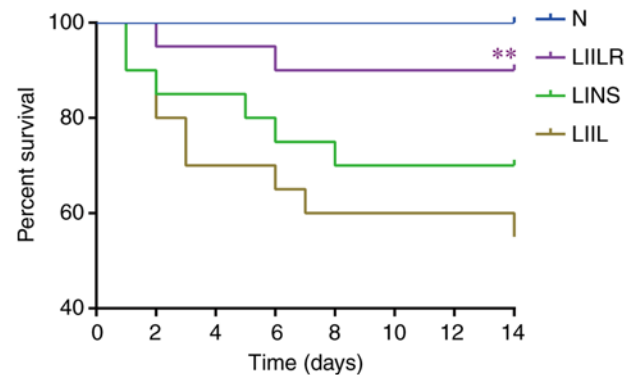


Figure 2. Survival curves of each rat group (N group; LINS group, LIIL group, LIILR group). The LIILR group had a higher survival rate compared with the LIIL group (** $P = 0.0068$). N group, normal control group; LINS group, LAD ligation with an injection of normal saline group; LIIL group, LAD ligation with an injection of IL-6 recombinant protein group; LIILR group, LAD ligation with injection of IL-6 receptor inhibitor group.

LVESD increase compared with the N group. The LIIL group with injection of IL-6 had a significantly decreased LVFS and LVEF at 1 and 2 weeks compared with the N group. In addition, the LIIL group had a significantly increased LVESD and LVESD compared with the N group. In the LIILR group with injection of IL-6 receptor inhibitors, LVFS and LVEF were significantly higher than those in LINS group and LIIL group at 2 weeks. LVESD and LVESD at 1 and 2 weeks in the LIILR group were lower compared with those in the LIIL group (Fig. 3). These results suggest that IL-6 receptor inhibitors can protect cardiac function in myocardial infarction-induced cardiac damage.

Effects of IL-6 and its receptor inhibitors on myocardial infarction size and collagen content. The myocardial infarction size and collagen content were detected by Masson staining. The myocardial structure of the N group was intact at low magnification. The infarct size was the largest in the IL6 injection group (LIIL group), followed by the ligation group (LINS group). The infarct size of the inhibitor group (LIILR group) was significantly smaller compared with that of the previous two groups (Fig. 4).

Under a high-power polarizing microscope, the Masson staining revealed cardiomyocytes in red and the collagen

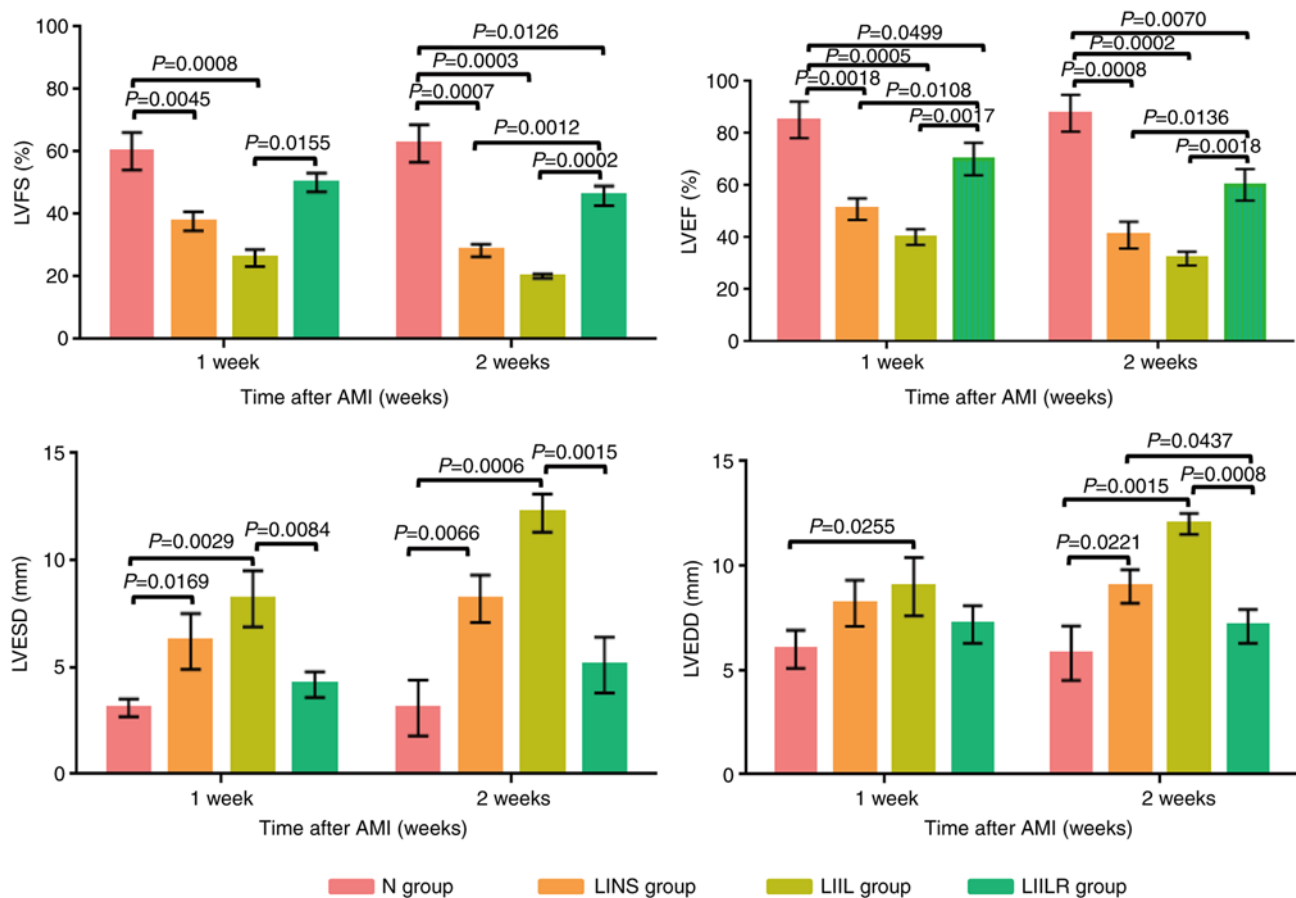


Figure 3. Changes in LVEF, LVFS, LVESD, and LVEDD in groups 1 week and 2 weeks after myocardial infarction. N group, n=20; LINS group, n=13; LIIL group, n=10; LIILR group, n=18. LVEF, left ventricular ejection fraction; LVFS, left ventricular fractional shortening; LVESD, left ventricle end systolic dimension; LVEDD, left ventricle end diastolic dimension; N group, normal control group; LINS group, LAD ligation with an injection of normal saline group; LIIL group, LAD ligation with an injection of IL-6 recombinant protein group; LIILR group, LAD ligation with injection of IL-6 receptor inhibitor group; AMI, acute myocardial infarction.

fibers in blue-green, as presented in Fig. 4. There was no obvious collagen in the N group, and the cardiomyocytes were bright red (Fig. 4B). The myocardial cells in the infarct border area of the rats in the LINS group were disordered, the blue collagen fibers in the interstitium increased, the myocardial bundle was segmented, some collagen fibers were merged and the vacuolar changes were observed locally (Fig. 4D). A significant inflammatory response was observed in the cardiomyocytes of the LIIL group. After treatment with IL-6, there were more blue-green collagen fibers in the myocardial tissue, collagen deposition increased significantly, the inflammatory response was significantly aggravated and the myocardial structure changed accordingly (Fig. 4F). Treatment with IL-6 receptor inhibitors inhibited this phenomenon. An infarcted area showed a weaker inflammatory response, with reduced collagen (Fig. 4H). These results suggest that IL-6 receptor inhibitors could attenuate the myocardial infarction-induced fibrosis.

The quantitative analysis in Fig. 4 demonstrated that the collagen content in the myocardium of each group was significantly higher compared with that in the N group. Compared with the N group, the collagen content of the LIIL group increased significantly after the injection of IL-6. Injection of IL-6 receptor inhibitor significantly reduced collagen content compared with the LIIL group. These results indicated that

IL-6 promoted myocardial collagen deposition and increased fibrosis and inflammatory response.

Effect of IL-6 and its receptor inhibitor on myocardial tissue inflammation. A myocardial tissue inflammation index (MPO) and an oxidative stress index (ROS) were measured to determine the degree of inflammation in the heart. As presented in Fig. 5, ROS and MPO in the LINS group were significantly higher compared with the N group. Injection of IL-6 promoted a further increase in the levels of ROS in the LIIL group compared with the LINS group. In the LIILR group (injection of IL-6 receptor inhibitor), ROS and MPO were significantly lower compared with the LIIL and LINS groups.

HE staining was applied to observe the local inflammatory response of myocardial tissue (Fig. 6) under a high-power microscope. The myocardial tissue of the N group revealed intact and well-defined myocardial cells, while no obvious inflammatory reaction or myocardial necrosis was observed. The LINS group revealed leucocytes in particular infiltrated the infarcted area, accompanied by cardiac myocyte loss. These pathological changes were even more pronounced in the LIIL group, where numerous inflammatory cells infiltrated the infarcted area. Injection of IL-6 receptor inhibitors markedly reduced the local inflammatory response and myocardial hemorrhage. This indicated that IL-6 injection significantly

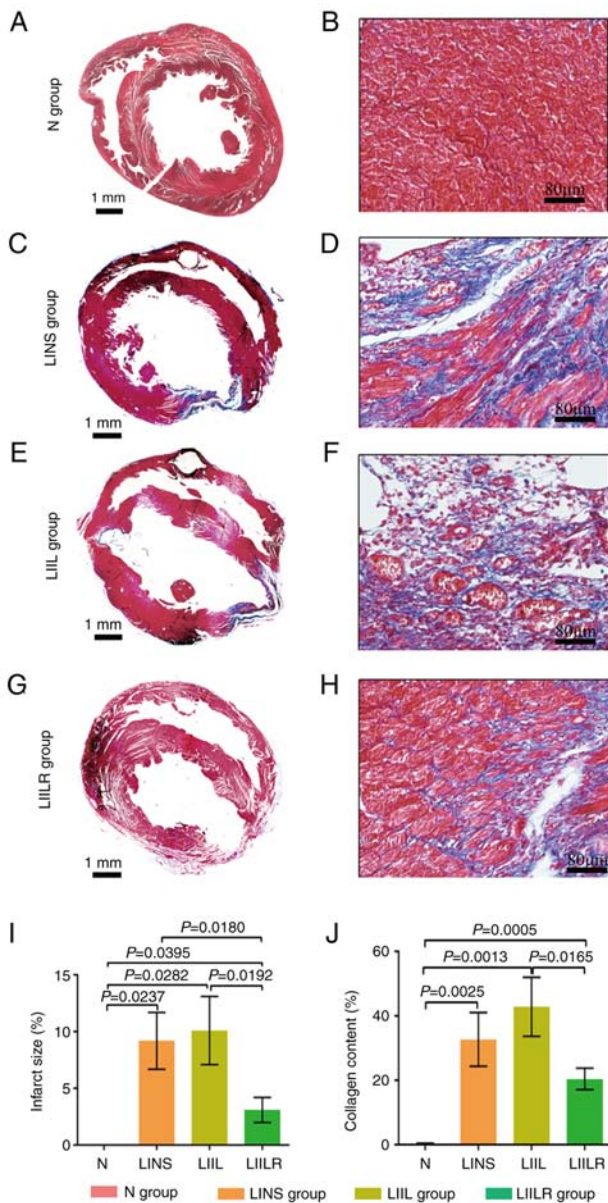


Figure 4. Overall Masson staining and infarct size of the rat heart in the N group, and 2 weeks after myocardial infarction in the LINS group, LIIL group and LIILR group. Masson staining showing myocardial tissue fibrosis in rats. Cardiomyocytes were stained in bright red, collagen in dark blue. (A) Overall Masson staining of the N group. (B) Magnified Masson staining of the N group. (C) Overall Masson staining of the LINS group. (D) Overall Masson staining of the LINS group. (E) Magnified Masson staining of the LIIL group. (F) Magnified Masson staining of the LIIL group. (G) Magnified Masson staining of the LIILR group. (H) Magnified Masson staining of the LIILR group. (I) Quantification of infarct size percentage in each rat group. (J) Quantification of collagen content percentage in each rat group. Left column scale bar, 1 mm; right column scale bar, 80 μ m. N group, n=20; LINS group, n=13; LIIL group, n=10; LIILR group, n=18. N group, normal control group; LINS group, LAD ligation with an injection of normal saline; LIIL group, LAD ligation with an injection of IL-6 recombinant protein; LIILR group, LAD ligation with injection of IL-6 receptor inhibitor group.

increased myocardial inflammation and fibrosis. By contrast, treatment with an IL-6 receptor inhibitor decreased both myocardial fibrosis and the inflammatory response. This suggested that IL-6 promoted fibrosis and inflammation in the infarcted myocardium, which could be partially reversed using IL-6 inhibitors.

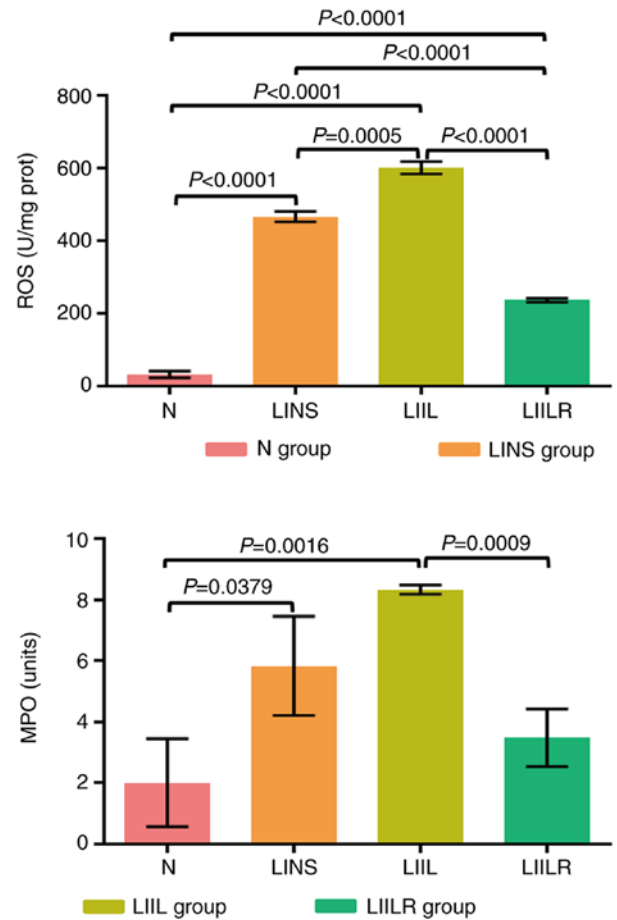


Figure 5. Detection of the myocardial inflammatory response indicators MPO and ROS by enzyme-linked immunosorbent assay (ELISA) and Chemiluminescence. N group, n=20; LINS group, n=13; LIIL group, n=10; LIILR group, n=18. N group, normal control group; LINS group, LAD ligation with an injection of normal saline group; LIIL group, LAD ligation with an injection of IL-6 recombinant protein group; LIILR group, LAD ligation with injection of IL-6 receptor inhibitor group; ROS, reactive oxygen species; MPO, myeloperoxidase.

Effects of IL-6 and its receptor inhibitors on the IL-6/TGF β 1-MMP signaling pathway in myocardial tissue fibrosis. To investigate the local expression of the proteins involved in the IL-6/TGF β 1-MMP signaling pathway analyzed, the present study used immunohistochemical staining and observed the local distribution of IL-6 and TGF β 1 in myocardial tissue. These two factors were mainly expressed in inflammatory regions, vascular endothelium and cardiomyocytes (brown, as presented by the arrows in Fig. 6). Compared with the N group, the number of IL-6 and TGF β 1-positive expression levels of IL-6 and TGF β 1 in the LINS group were markedly higher. These parameters were further increased in the LIIL group (injected with IL-6), while IL-6 receptor inhibitor injection led to a marked reduction of the observed expression of IL-6 and TGF β 1 (LIILR group) (Fig. 6).

Effects of IL-6 and its receptor inhibitors on the IL-6/TGF β 1-MMP signaling pathway in myocardial tissue fibrosis. The effect of the IL-6/TGF β 1-MMP signaling pathway on the fibrosis process was investigated in the infarcted myocardium. First, treatment with IL-6 and its

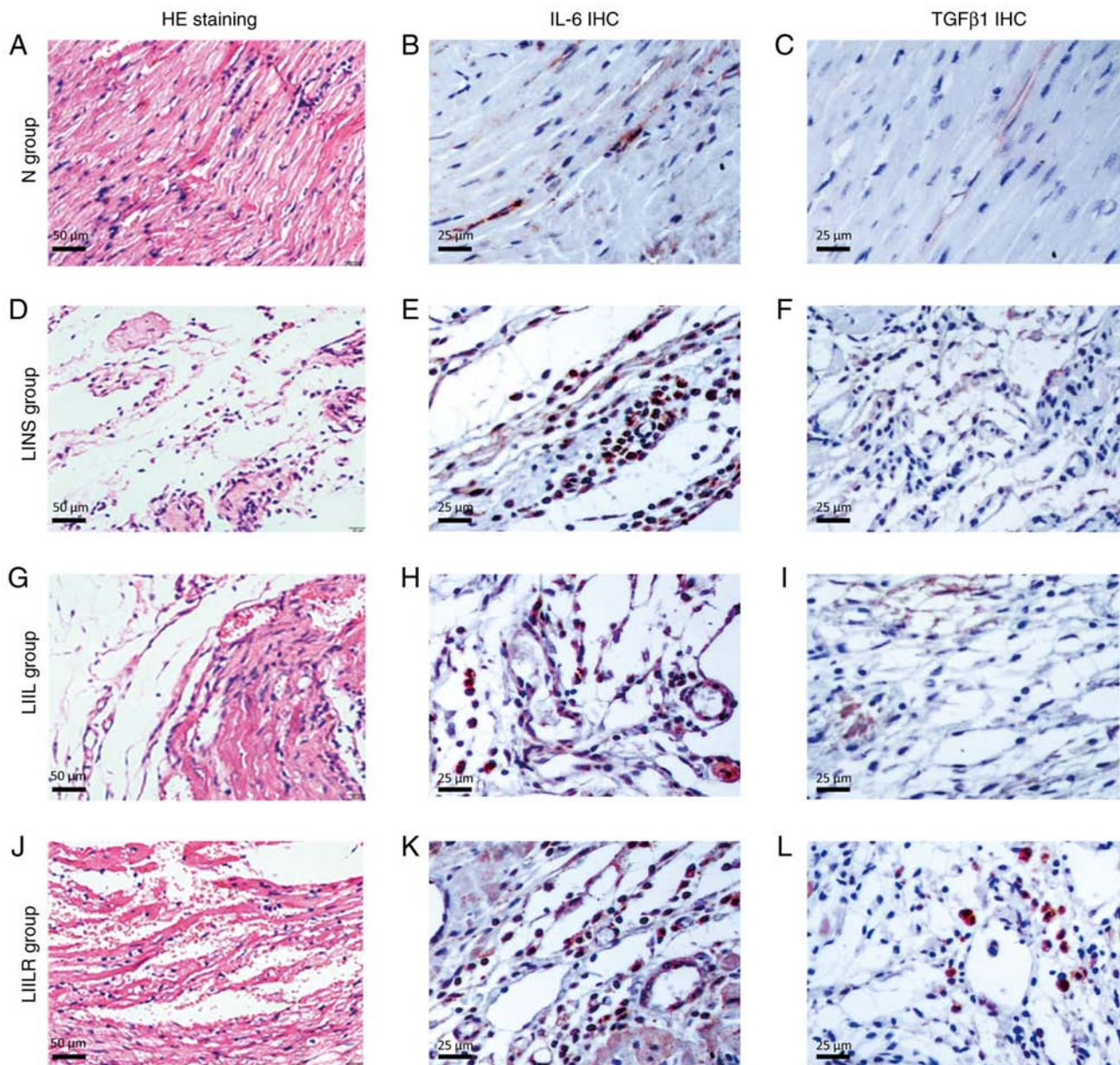


Figure 6. Histological and immunohistological analyses. (A, D, G and J) HE staining shows the inflammatory response of the cardiomyopathy in rats and myocardial necrosis. The myocardial tissue of (A) the N group showed that the morphology of myocardial cells was complete and the boundaries were clear. The (D) LINS groups and (G) LIIL groups saw a large number of inflammatory cells in particular infiltrate the infarcted area, accompanied by removal of disrupted ventricular tissue. These pathological phenomena were significantly reduced in the (J) LIILR group, and local vascular reactivation and residual heart muscle could be observed. Representative images of immunohistochemical staining of IL-6 (brown blots) in heart tissues of rat at 2 weeks are shown as (B), (E), (H) and (K), respectively. The number of positive expression particles in the LIIL group was the largest, followed by the LINS group and the LIILR, where they were significantly reduced, and the N group, where it was rare. TGF β 1 immunized dyeing in myocardial tissue was sepia particles, mainly distributed in the infarction region, the number of positive expression particles was the largest in the (I) LIIL group, followed by the (F) LINS group, (L) LIILR group significantly reduced and the (C) N group was rare. HE, hematoxylin and eosin; IHC, immunohistochemistry; N group, normal control group; LINS group, LAD ligation with an injection of normal saline group; LIIL group, LAD ligation with an injection of IL-6 recombinant protein group; LIILR group, LAD ligation with injection of IL-6 receptor inhibitor group.

receptor inhibitors was induced, followed by an ELISA analysis of IL-6 and TGF β 1 in the infarcted myocardium. Ligation (induction of myocardial infarction) significantly increased the expression levels of IL-6, TGF β 1 and MMP-9 in the hearts of rats in the LINS group compared with the N group. IL-6, TGF β 1, MMP-2 and MMP-9 in the LIIL group were further increased after injection of IL-6. The expression levels of these factors were significantly reduced after using IL-6 receptor inhibitors (Fig. 7).

Discussion

Since the widespread use of cardiac reperfusion therapy, the survival rate of patients with myocardial infarction has significantly increased. Despite this, congestive heart failure caused by remodeling of the is still a significant clinical problem (31-34). The prognosis of these patients is similar to those of numerous patients suffering from end-stage malignancies (35,36). The prognosis of patients with heart

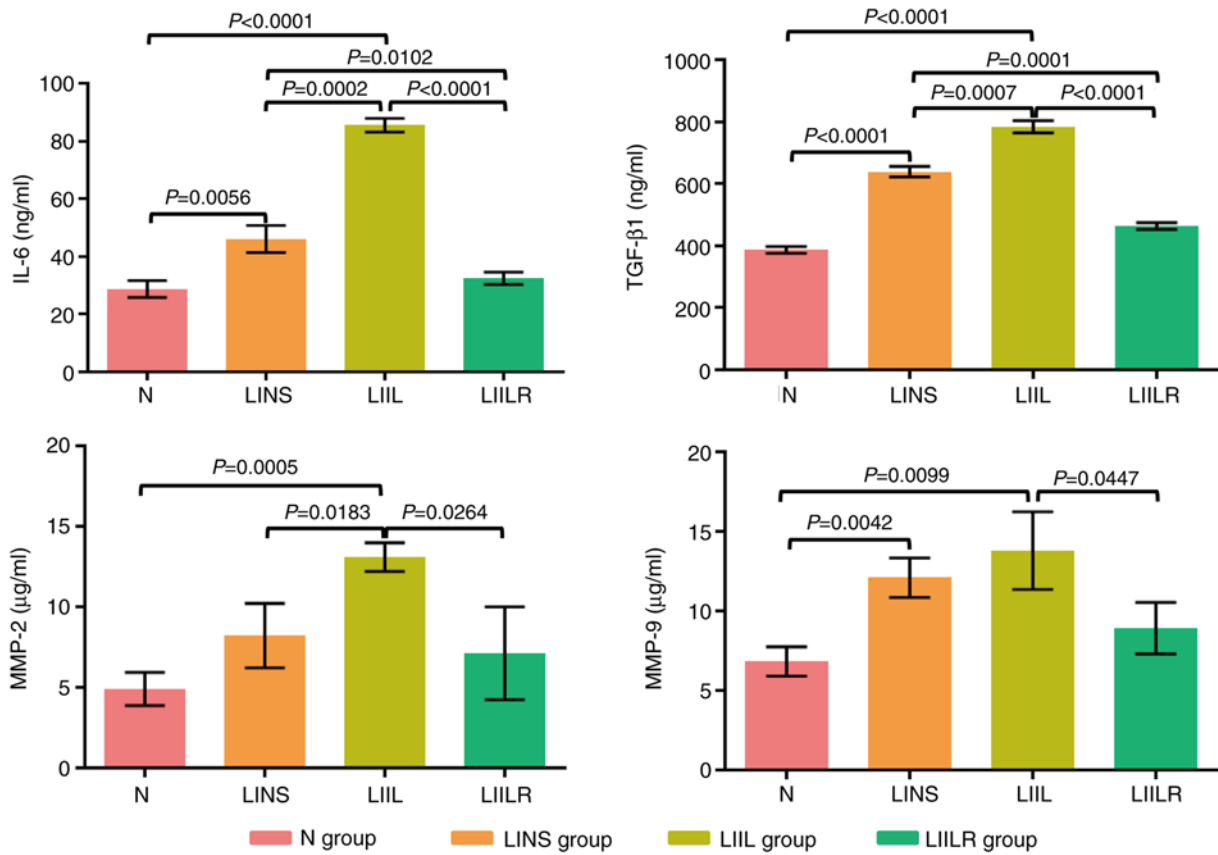


Figure 7. Detection of IL-6, TGFβ1, MMP-2 and MMP-9 by ELISA. N group, n=20; LINS group, n=13; LIIL group, n=10; LIILR group, n=18. N group, normal control group; LINS group, LAD ligation with an injection of normal saline group; LIIL group, LAD ligation with an injection of IL-6 recombinant protein group; LIILR group, LAD ligation with injection of IL-6 receptor inhibitor group.

disease is heavily influenced by left ventricular remodeling. Among its manifestations are myocardial fibrosis, dilation of the ventricles and myocardial dysfunction. An infarct-related remodeling may occur early (within 72 h) or late (after 72 h), which causes further progressive expansion of the early infarct size, left ventricular dilatation, left ventricular wall fibrosis and permanent collagen scarring. Significantly prolonged remodeling causes fibrous tissue necrosis and a large amount of necrotic material to be deposited, further aggravating the process and resulting in a vicious cycle. In clinical terms, this manifests as cardiac insufficiency (37).

The present study demonstrated that, compared with the normal control group (N group), a typical left ventricular remodeling occurred in the LINS group at postoperative week, with a significant expansion of LVEDD. Consequently, left ventricular pump function was also significantly reduced. After 2 weeks, the changes in the LINS group were aggravated, causing the animal survival rate to decrease further. In addition to observing the structural remodeling of the left ventricle, the remodeling of myocardial tissue structures in the left ventricle were observed, indicating that myocardial necrosis, local inflammation and collagen deposition were still occurring. The same left ventricular remodelling processes were observed after IL-6 was injected into the infarct area. The IL-6 inhibitor caused a notable decrease in remodeling. These results indicated that IL-6 was an important cytokine in cells, playing an important role in the occurrence and development of left ventricular remodeling.

The results also confirmed that IL-6 antagonists, such as Tocilizumab, could vastly improve the prognosis of patients with myocardial infarction by inhibiting the overall cardiac infarct remodeling.

The present study observed that the mortality of the infarcted rats in the LIIL group receiving IL-6 injection was higher compared with that in the other groups, while the mortality in the LIILR group injected with the IL-6 receptor inhibitor decreased. Cardiac function (LVEF and LVFS) was progressively decreased in rats after acute myocardial infarction. Infusion of IL-6 further impaired cardiac function (LIIL group), while injection of IL-6 receptor antagonist prevented heart function decline of the infarcted rats (LIIL group), which suggested that such an antagonistic mechanism was a potentially therapeutic preventive target. This would be suitable for post-infarction patients with high IL-6 levels.

In the present study, cardiovascular function was similar between the LINS and LIIL groups, and left ventricular remodeling developed similarly. LVEDD and LVESD increased in both post-induced infarction (LAD ligation, LINS group) and the IL-6-added group (LIIL group). As a result of the injection of IL-6 inhibitor (LIILR group), both LVEDD and LVESD demonstrated measurable improvements in overall cardiac function after myocardial infarction. Furthermore, was demonstrated that IL-6 played an important role in post-infarction patients, since injection of IL-6 also led to typical post-infarction changes in clinical outcomes that are associated with loss of cardiac function.

Moreover, induced infarction through LAD ligation increased the inflammation index (MPO) and oxidative stress index (ROS). These changes were confirmed by pathological analysis, which demonstrated a local inflammatory reaction and collagen formation in the infarcted myocardium. Injection of IL-6 aggravated these pathological changes and expanded the infarction area. Injection of IL-6 receptor inhibitors significantly reduced local myocardial inflammation and the collagen content. Therefore, the physiological changes described as aforementioned are based on local histological improvement due to IL-6 inhibition, suggesting that IL-6 inhibitors could be of importance to post-MI patients. The treatment prevented a rapid expansion of the potentially permanently destroyed infarction area (thus losing cardiac function) and significantly reversed the infarction-caused dilapidation of the cardiac tissue. Several post-infarction syndromes result from this, such as arrhythmia, Dressler's syndrome and cardiac insufficiency. The severity of these conditions significantly impacts patient quality of life (38,39).

The LAD ligation that caused the myocardial infarction also caused an increase in the expression of local myocardial inflammatory factors TGF β 1, MMP2 and MMP9. TGF β 1 is a leading player in the apoptotic cascade (40,41). Previous studies have indicated a close relationship between IL-6 and TGF β 1, where the latter induces phosphorylation of SMAD-2, phosphorylated SMAD-2, and SMAD-4 formation in intestinal epithelial cells (41,42). The complex downregulates IL-6 signaling (43). In the present study, IL-6 significantly upregulated the expression of TGF β 1 in infarcted hearts, while the injection of IL-6 receptor inhibitor significantly reduced its expression, suggesting that TGF β 1 may be involved as a notable gene downstream of IL-6.

Notably, IL-6 injections increased their levels further, while adding IL-6 receptor inhibitors also decreased them. In acute ischemia, these inflammatory factors activate fibroblasts, enhancing their ability to synthesize and secrete collagen. Furthermore, some fibroblasts undergo degeneration and necrosis, releasing cellular debris, further inducing the formation of collagen fibers and their deposition. Myocardial tissue remodeling ends once the tissue environment balances inflammatory factors with fibroblasts. Inhibition of this dynamic process and acceleration of the time-to-balance result in less myocardium losing its original state and thus less functional loss (42-45).

The present study revealed that injection of IL-6 receptor inhibitor led to a significant reduction in the observed expression of IL-6 and TGF β 1 (LIILR group). Thus, the detrimental effect of TGF β 1 was reduced by a reduction in the collagen content in the damaged infarction area, avoiding further sequelae. In another study, strictly linked to myocardial infarction, non-alcoholic fatty liver disease (NAFLD), the fibrotic effect of TGF β 1 is more pronounced, as evident from previous studies (46-49). Furthermore, in NAFLD, the pro-inflammatory cytokine IL-6 plays an important role in increasing its serum concentration, likely inducing the production of a large amount of collagen fiber and their deposition via TGF β 1 (50-52). It is TGF β 1 that subverts Th1 and Th2 differentiation in response to IL-6, resulting in T cells. TGF β 1 in the context of an inflammatory cytokine milieu supports *de novo* differentiation of IL-17-producing T cells (53). IL-17

is also central to the atherosclerosis process and is a potential driver of myocardial infarction (54).

MMP belongs to the Zn-dependent protease family and can degrade extracellular matrix (ECM) components. The tissue inhibitor of metalloproteinase (TIMP) acts oppositely to MMP, inhibiting the degradation and thus regulating the content of ECM. The factors that influence the dynamic balance of MMP and TIMP are generally considered to be mainly TNF- α , EGF and TGF- α . Upregulation of the expression levels of these factors leads to an increase in the ratio of MMP/TIMP. The degradation rate is greater compared with the synthesis rate, resulting in a decrease in ECM, which leads to interstitial filling of the fibers, interstitial fibrosis and ultimately ventricular remodeling (11,31). After treatment with IL-6, the level of MMP2/9 in the homogenate of myocardial tissue also increased, and the IL-6 receptor inhibitor treatment significantly reduced both indices and local tissue fiber content. Similar changes were also observed. The present study indicated that, unlike common tissue necrosis factors such as TNF- α , EGF and TGF- α , the inflammatory mediator IL-6 was also a principal factor affecting ECM in infarcted hearts. Degradation of the ECM imbalance and the synthesis of ECM are key factors that lead to organ fibrosis. Additionally, IL-6 may also affect infarct remodeling by regulating MMP2/9.

In conclusion, the results of the present study provided a novel therapeutic target for left ventricular remodeling after clinical myocardial infarction.

Acknowledgements

Not applicable.

Funding

The present study was supported by the Shanghai Health and Family Planning Commission Project (grant no. 201940057), the Shanghai Yangpu District Health and Family Planning Commission Fund for Hao Yi Shi Training Project (grant nos. 202056 and 2020-2023), the Natural Science Foundation of Shanghai (grant no. 18ZR1436000) and Major Program of National Key Research and Development Project (grant no. 2020YFA0112604-02).

Availability of data and materials

The datasets used and/or analyzed during the current study are available from the corresponding author on reasonable request.

Authors' contributions

XP and JW made substantial contributions to the conception and design of the study, and the acquisition of the experimental data. MW, HW and FC analyzed and interpreted the data. SZ and XP performed the statistical analysis. XP, JW and EB performed the M-mode ultrasound analysis. YZho and NC performed the electrocardiogram analysis. XL and FC assisted with the IHC staining. YZha and EB assisted with the ELISA analysis. XL, YZha and HW drafted the manuscript. FC, XP and EB revised the manuscript for important intellectual

content. FC and XP confirm the authenticity of all the raw data. All authors contributed to the writing of the article and have read and approved the final manuscript.

Ethics approval and consent to participate

This research proposal was approved by the Ethics Committee of Yangpu Hospital, School of Medicine, Tongji University (approval no. LL-2021-SCI-006).

Patient consent for publication

Not applicable.

Competing interests

The authors declare that they have no competing interests.

References

- Iuchi A, Harada H and Tanaka T: IL-6 blockade for myocardial infarction. *Int J Cardiol* 271: 19-20, 2018.
- Ritschel VN, Seljeflot I, Arnesen H, Halvorsen S, Weiss T, Eritsland J and Andersen GØ: IL-6 signalling in patients with acute ST-elevation myocardial infarction. *Results Immunol* 4: 8-13, 2014.
- Gabriel AS, Martinsson A, Wretling B and Ahnve S: IL-6 levels in acute and post myocardial infarction: Their relation to CRP levels, infarction size, left ventricular systolic function, and heart failure. *Eur J Intern Med* 15: 523-528, 2004.
- Azevedo PS, Polegato BF, Minicucci MF, Paiva SA and Zornoff LA: Cardiac Remodeling: Concepts, clinical impact, pathophysiological mechanisms and pharmacologic treatment. *Arq Bras Cardiol* 106: 62-69, 2016.
- Möttönen MJ, Ukkola O, Lumme J, Kesäniemi YA, Huikuri HV and Perkiömäki JS: Cardiac remodeling from middle age to senescence. *Front Physiol* 8: 341, 2017.
- Ellis SG, Tendera M, de Belder MA, van Boven AJ, Widimsky P, Janssens L, Andersen HR, Betriu A, Savonitto S, Adamus J, *et al*: Facilitated PCI in patients with ST-Elevation myocardial infarction. *N Engl J Med* 358: 2205-2217, 2008.
- Ohtsuka T, Hamada M, Inoue K, Ohshima K, Suzuki J, Matsunaka T, Ogimoto A, Hara Y, Shigematsu Y and Higaki J: Relation of circulating interleukin-6 to left ventricular remodeling in patients with reperfusion anterior myocardial infarction: Relation of circulating interleukin-6 to left ventricular remodeling in patients with reperfusion anterior myocardial infarction. *Clin Cardiol* 27: 417-420, 2004.
- González A, Ravassa S, López B, Moreno MU, Beaumont J, San José G, Querejeta R, Bayés-Genís A and Díez J: Myocardial remodeling in hypertension. *Hypertension* 72: 549-558, 2018.
- Williams A, Kamper SJ, Wiggers JH, O'Brien KM, Lee H, Wolfenden L, Yoong SL, Robson E, McAuley JH, Hartvigsen J and Williams CM: Musculoskeletal conditions may increase the risk of chronic disease: A systematic review and meta-analysis of cohort studies. *BMC Med* 16: 167, 2018.
- French BA and Kramer CM: Mechanisms of postinfarct left ventricular remodeling. *Drug Discov Today Dis Mech* 4: 185-196, 2007.
- Segura AM, Frazier OH and Buja LM: Fibrosis and heart failure. *Heart Fail Rev* 19: 173-185, 2014.
- Lan HY: Diverse roles of TGF- β /Smads in renal fibrosis and inflammation. *Int J Biol Sci* 7: 1056-1067, 2011.
- Nakao A, Imamura T, Souchelnytskyi S, Kawabata M, Ishisaki A, Oeda E, Tamaki K, Hanai J, Heldin CH, Miyazono K and ten Dijke P: TGF-beta receptor-mediated signalling through Smad2, Smad3 and Smad4. *EMBO J* 16: 5353-5362, 1997.
- Arrigo M, Jessup M, Mullens W, Reza N, Shah AM, Sliwa K and Mebazaa A: Acute heart failure. *Nat Rev Dis Primers* 6: 16, 2020.
- Mebazaa A, Pitsis AA, Rudiger A, Toller W, Longrois D, Ricksten SE, Bobek I, De Hert S, Wieselthaler G, Schirmer U, *et al*: Clinical review: Practical recommendations on the management of perioperative heart failure in cardiac surgery. *Crit Care* 14: 201, 2010.
- Hanif K, Bid HK and Konwar R: Reinventing the ACE inhibitors: Some old and new implications of ACE inhibition. *Hypertens Res* 33: 11-21, 2010.
- Rich MW, Chyun DA, Skolnick AH, Alexander KP, Forman DE, Kitzman DW, Maurer MS, McClurken JB, Resnick BM, Shen WK, *et al*: Knowledge Gaps in cardiovascular care of the older adult population: A Scientific Statement From the American Heart Association, American College of Cardiology, and American Geriatrics Society. *J Am Coll Cardiol* 67: 2419-2440, 2016.
- Moffat K and Mercer SW: Challenges of managing people with multimorbidity in today's healthcare systems. *BMC Fam Pract* 16: 129, 2015.
- Granger CB, Goldberg RJ, Dabbous O, Pieper KS, Eagle KA, Cannon CP, Van De Werf F, Avezum A, Goodman SG, Flather MD, *et al*: Predictors of hospital mortality in the global registry of acute coronary events. *Arch Intern Med* 163: 2345-2353, 2003.
- Siddiqi S and Sussman MA: Cardiac hegemony of senescence. *Curr Transl Geriatr Exp Gerontol Rep* 2: 10.1007/s13670-013-0064-3, 2013.
- Sussman MA and Anversa P: Myocardial aging and senescence: Where have the stem cells gone? *Annu Rev Physiol* 66: 29-48, 2004.
- Torella D, Rota M, Nurzynska D, Musso E, Monsen A, Shiraishi I, Zias E, Walsh K, Rosenzweig A, Sussman MA, *et al*: Cardiac stem cell and myocyte aging, heart failure, and insulin-like growth factor-1 overexpression. *Circ Res* 94: 514-524, 2004.
- van Merode T, van de Ven K and van den Akker M: Patients with multimorbidity and their treatment burden in different daily life domains: A qualitative study in primary care in the Netherlands and Belgium. *J Comorb* 8: 9-15, 2018.
- Faustino-Rocha AI, Ginja M, Ferreira R and Oliveira PA: Studying humane endpoints in a rat model of mammary carcinogenesis. *Iran J Basic Med Sci* 22: 643-649, 2019.
- Mohamed AS, Hosney M, Bassiony H, Hassanein SS, Soliman AM, Fahmy SR and Gaafar K: Sodium pentobarbital dosages for exsanguination affect biochemical, molecular and histological measurements in rats. *Sci Rep* 10: 378, 2020.
- Wu Y, Wan Q, Shi L, Ou J, Li Y, He F, Wang H and Gao J: Siwu granules and erythropoietin synergistically ameliorated anemia in adenine-induced chronic renal failure rats. *Evid Based Complement Alternat Med* 2019: 5832105, 2019.
- Kobara M, Noda K, Kitamura M, Okamoto A, Shiraishi T, Toba H, Matsubara H and Nakata T: Antibody against interleukin-6 receptor attenuates left ventricular remodeling after myocardial infarction in mice. *Cardiovasc Res* 87: 424-430, 2010.
- Mochizuki D, Adams A, Warner KA, Zhang Z, Pearson AT, Misawa K, McLean SA, Wolf GT and Nör JE: Anti-tumor effect of inhibition of IL-6 signaling in mucoepidermoid carcinoma. *Oncotarget* 6: 22822-22835, 2015.
- Arora G, Morss AM, Piazza G, Ryan JW, Dinwoodey DL, Rofsky NM, Manning WJ and Chuang ML: Differences in left ventricular ejection fraction using teichholz formula and volumetric methods by cmr: Implications for patient stratification and selection of therapy. *J Cardiovasc Magn Reson* 12: P202, 2010.
- Wandt B, Bojő L, Tolagen K and Wranne B: Echocardiographic assessment of ejection fraction in left ventricular hypertrophy. *Heart* 82: 192-198, 1999.
- Konstam MA, Kramer DG, Patel AR, Maron MS and Udelson JE: Left ventricular remodeling in heart failure current concepts in clinical significance and assessment. *JACC Cardiovasc Imaging* 4: 98-108, 2011.
- Eltzschig HK and Collard CD: Vascular ischaemia and reperfusion injury. *Br Med Bull* 70: 71-86, 2004.
- Wu N, Zhang X, Du S, Chen D and Che R: Upregulation of miR-335 ameliorates myocardial ischemia reperfusion injury via targeting hypoxia inducible factor 1-alpha subunit inhibitor. *Am J Transl Res* 10: 4082-4094, 2018.
- Turer AT and Hill JA: Pathogenesis of myocardial ischemia-reperfusion injury and rationale for therapy. *Am J Cardiol* 106: 360-368, 2010.
- Jones NR, Hobbs FR and Taylor CJ: Prognosis following a diagnosis of heart failure and the role of primary care: A review of the literature. *BJGP Open* 1: bjgpopen17X101013, 2017.
- Price JF: Congestive heart failure in children. *Pediatr Rev* 40: 60-70, 2019.

37. Klæboe LG and Edvardsen T: Echocardiographic assessment of left ventricular systolic function. *J Echocardiogr* 17: 10-16, 2019.
38. Malik J, Zaidi SMJ, Rana AS, Haider A and Tahir S: Post-cardiac injury syndrome: An evidence-based approach to diagnosis and treatment. *Am Heart J Plus Cardiol Res Practice* 12: 100068, 2021.
39. Cahill TJ and Kharbanda RK: Heart failure after myocardial infarction in the era of primary percutaneous coronary intervention: Mechanisms, incidence and identification of patients at risk. *World J Cardiol* 9: 407-415, 2017.
40. Cao Y, Chen L, Zhang W, Liu Y, Papaconstantinou HT, Bush CR, Townsend CM Jr, Thompson EA and Ko TC: Identification of apoptotic genes mediating TGF- β /Smad3-induced cell death in intestinal epithelial cells using a genomic approach. *Am J Physiol Gastrointest Liver Physiol* 292: G28-G38, 2007.
41. Walia B, Wang L, Merlin D and Sitaraman SV: TGF- β down-regulates IL-6 signaling in intestinal epithelial cells: Critical role of SMAD-2. *FASEB J* 17: 2130-2132, 2003.
42. Ge Q, Moir LM, Black JL, Oliver BG and Burgess JK: TGF β 1 induces IL-6 and inhibits IL-8 release in human bronchial epithelial cells: The role of Smad2/3. *J Cell Physiol* 225: 846-854, 2010.
43. Ramesh S, Wildey GM and Howe PH: Transforming growth factor beta (TGF β)-induced apoptosis: The rise & fall of Bim. *Cell Cycle* 8: 11-17, 2009.
44. Su JH, Luo MY, Liang N, Gong SX, Chen W, Huang WQ, Tian Y and Wang AP: Interleukin-6: A Novel Target for Cardio-Cerebrovascular Diseases. *Front Pharmacol* 12: 745061, 2021.
45. Shinde AV and Frangogiannis NG: Fibroblasts in myocardial infarction: A role in inflammation and repair. *J Mol Cell Cardiol* 70: 74-82, 2014.
46. Venugopal H, Hanna A, Humeres C and Frangogiannis NG: Properties and functions of fibroblasts and myofibroblasts in myocardial infarction. *Cells* 11: 1386, 2022.
47. Wang JH, Zhao L, Pan X, Chen NN, Chen J, Gong QL, Su F, Yan J, Zhang Y and Zhang SH: Hypoxia-stimulated cardiac fibroblast production of IL-6 promotes myocardial fibrosis via the TGF- β 1 signaling pathway. *Lab Invest* 96: 839-852, 2016.
48. Yang L, Roh YS, Song J, Zhang B, Liu C, Loomba R and Seki E: Transforming growth factor beta signaling in hepatocytes participates in steatohepatitis through regulation of cell death and lipid metabolism in mice. *Hepatology* 59: 483-495, 2014.
49. Okina Y, Sato-Matsubara M, Matsubara T, Daikoku A, Longato L, Rombouts K, Thanh Thuy LT, Ichikawa H, Minamiyama Y, Kadota M, *et al*: TGF- β 1-driven reduction of cytoglobin leads to oxidative DNA damage in stellate cells during non-alcoholic steatohepatitis. *J Hepatol* 73: 882-895, 2020.
50. Xu F, Liu C, Zhou D and Zhang L: TGF- β /SMAD pathway and its regulation in hepatic fibrosis. *J Histochem Cytochem* 64: 157-167, 2016.
51. Tarantino G, Conca P, Riccio A, Tarantino M, Di Minno MN, Chianese D, Pasanisi F, Contaldo F, Scopacasa F and Capone D: Enhanced serum concentrations of transforming growth factor-beta1 in simple fatty liver: Is it really benign? *J Transl Med* 6: 72, 2008.
52. Machado MV and Cortez-Pinto H: Non-invasive diagnosis of non-alcoholic fatty liver disease. A critical appraisal. *J Hepatol* 58: 1007-1019, 2013.
53. Veldhoen M, Hocking RJ, Atkins CJ, Locksley RM and Stockinger B: TGF β in the context of an inflammatory cytokine milieu supports de novo differentiation of IL-17-producing T cells. *Immunity* 24: 179-189, 2006.
54. Brun P, Giron MC, Qesari M, Porzionato A, Caputi V, Zoppellaro C, Banzato S, Grillo AR, Spagnol L, De Caro R, *et al*: Toll-like receptor 2 regulates intestinal inflammation by controlling integrity of the enteric nervous system. *Gastroenterology* 145: 1323-1333, 2013.



This work is licensed under a Creative Commons Attribution-NonCommercial-NoDerivatives 4.0 International (CC BY-NC-ND 4.0) License.