



# Speaking a common language: the international consensus on bicuspid aortic valve nomenclature and classification

Hector I. Michelena

Department of Cardiovascular Medicine, Mayo Clinic, Rochester, MN, USA

Correspondence to: Hector I. Michelena, MD. Department of Cardiovascular Medicine, Mayo Clinic, Rochester, 200 First Street SW, Rochester, MN 55905, USA. Email: michelena.hector@mayo.edu.

The congenital bicuspid aortic valve (BAV) condition is a valvulo-aortopathy with heterogeneous phenotypic expressions and clinical outcomes. A multitude of pre-existing classification systems, some extensive and some succinct, utilize combinations of numbers and/or letters to describe the condition. These diverse nomenclature systems are used according to the random preference of clinicians and researchers, generating confusion in clinical practice and research alike, effectively creating a barrier of communication at multiple levels. Based on imaging, pathology, surgery and clinical history evidence-based principles, and in utilizing the English language, the international nomenclature and classification consensus on the congenital BAV and its aortopathy offers a simple nosologic and phenotypic format that covers all possible phenotypes and clinical presentations of the bicuspid valvulo-aortopathy. From the nosology perspective, the valvulo-aortopathy has three major clinical presentations: (I) typical valvulo-aortopathy; (II) complex valvulo-aortopathy; and (III) undiagnosed or uncomplicated valvulo-aortopathy. From the valvular perspective, the congenital BAV has three major phenotypic expressions: (I) the fused BAV; (II) the 2-sinus BAV; and (III) the partial fusion (forme fruste) BAV. From the aortopathy perspective, the condition has three major phenotypic expressions: (I) ascending phenotype; (II) root phenotype; and (III) extended phenotypes. The international consensus is intended for universal use by Clinicians (pediatric and adult), echocardiography sonographers and physicians, cardiovascular advanced-imaging specialists, interventional cardiologists, cardiovascular surgeons, pathologists, geneticists and researchers encompassing clinical and basic research areas. When new landmark research is available, this international consensus may be subject to change in accordance with evidence-based data.

**Keywords:** Bicuspid aortic valve (BAV); aortopathy; nomenclature; classification



Submitted May 25, 2022. Accepted for publication Jun 28, 2022.

doi: 10.21037/acs-2022-bav-24

View this article at: <https://dx.doi.org/10.21037/acs-2022-bav-24>

## Introduction: why a unified, universal consensus?

Nomenclature refers to the selection of name that is given to a particular structure, abnormality or phenotype, whereas classification refers to the process of arranging or categorizing something according to shared features (1-4). The clinician evaluating the congenital bicuspid aortic valve (BAV) patient must be able to communicate all specific morphological, functional and prognostic aspects of the BAV condition to the patient, other clinicians,

surgeons, interventionalists and researchers, in a common language (5). In addition, there are multiple gaps in the knowledge and understanding of the BAV condition (6). For advancing the clinical, biological and genetic understanding of the BAV condition, a common language that incorporates all possible phenotypic expressions, must be articulated among researchers in all clinical and laboratory research disciplines. Multiple nomenclatures and classifications exist for the BAV condition (1-4), and they are as heterogeneous or more than the BAV condition itself (5). For example,

**Table 1** Critical limitations of the Sievers classification compared to the new international consensus

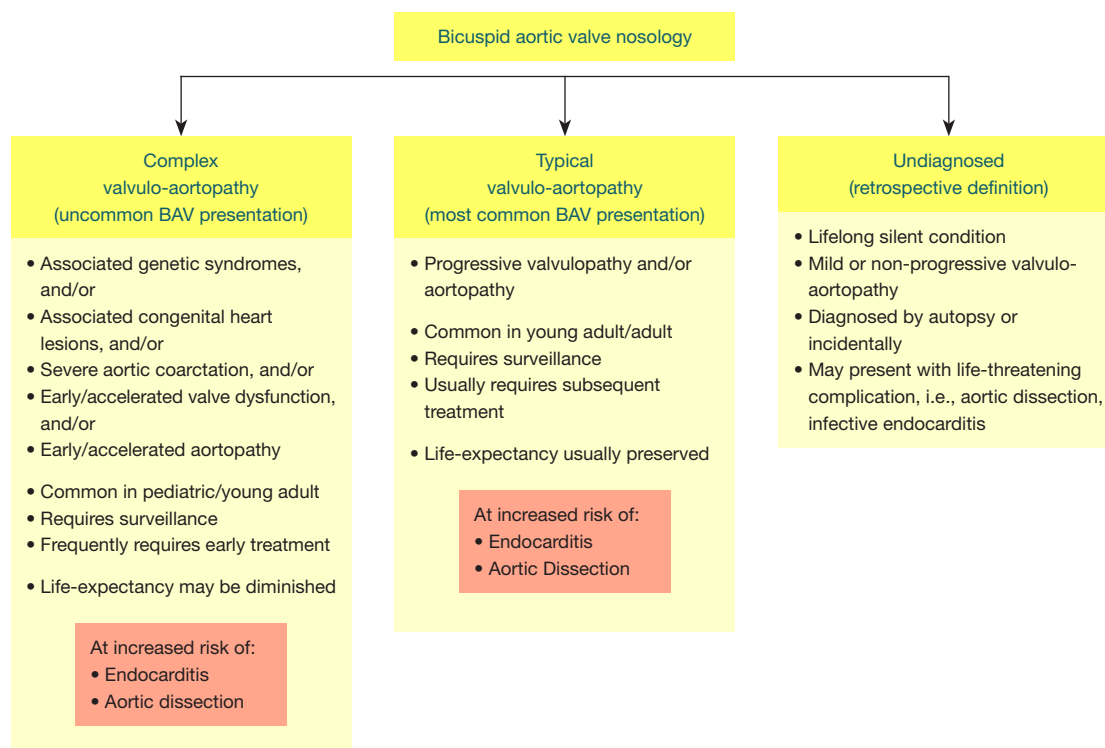
Type of limitation	Specific Sievers limitation	International consensus
Comprehension and retention	Not language-intuitive: types: 0, 1 and 2	Language-intuitive: types: fused, 2-sinus and partial fusion
Unable to define all BAV phenotypes	Type 0 does not differentiate between a fused BAV with no raphe and a 2-sinus BAV	Fused types may have raphe or not; 2-sinus types do not have raphe
Lack of pre repair assessment of symmetry	Nonexistent	Fused types require assessment of symmetry for surgical repair planning
Lack of recognition of BAV phenotypes	Does not recognize the partial-fusion (forme fruste); does not recognize fused BAV with no raphe	Recognizes partial-fusion (forme fruste); recognizes fused BAV with no raphe, which is different from 2-sinus BAV
Lack of recognition of aortopathy phenotypes	Nonexistent	Aorta phenotypes: root, ascending and extended
Includes a non-BAV congenital aortic valve abnormality	Type 2 is not BAV, is unicuspid aortic valve	Does not include unicuspid aortic valves
Evidence-based	Anatomical surgical pathology only	Imaging, anatomical surgical pathology, surgical-functional pathology, clinical associations

From Michelena *et al.* (1-4) with permission. BAV, bicuspid aortic valve.

the Sievers (7), Schaefer (8) and Kang (9) classifications use multiple letters and numbers to describe different aspects of the BAV and its aortopathy that are not intuitive and also are incomplete (1-4). The use of one of the many classifications for research varies randomly according to authors and institutions, and there are specific terminologies that lead to confusion such as the “true” BAV (6); does it mean that the others are false BAV? These heterogeneous classifications cause confusion in clinical practice; failure to identify phenotypes that may predict outcomes; inability to analyze clinical outcome data in registries, systematic reviews and meta-analysis formats; failure to capture anatomical information critical for surgical aortic valve repair; and hamper identification of phenotypic-genetic associations. This international consensus is an imaging-based, descriptive, simple, but comprehensive, nomenclature and classification system that is based on the English language, rather than on numbers or letters (1-4). In addition, it is based on important available anatomical, clinical, surgical and pathological scientific data. This new nomenclature/classification system represents the combined efforts of international BAV experts including Clinicians (both adult and pediatric), surgeons, interventionalists, pathologists, embryologists, geneticists and imagers [echocardiography, computed tomography (CT) and magnetic resonance (MR) experts] (1-4).

### Limitations of the Sievers classification

The Sievers classification (7), based on the presence and number of raphes identified at surgery (i.e., direct surgical visualization), has several shortcomings (Table 1) (1-4): (I) it is not based on imaging, which is the most common method of diagnosing, phenotyping and surveilling the BAV and its aortopathy; (II) it is unable to define all known BAV phenotypes (i.e., does not recognize the partial fusion (forme fruste) BAV and does not recognize fused phenotypes without raphe); (III) it does not recognize the aortopathy phenotypes of a condition (BAV) that is a valvulo-aortopathy; (IV) it lacks assessment of BAV symmetry, which is critical for planning surgical regurgitant-BAV repair (10,11); and (V) it includes as a “BAV”, an incomplete definition of the unicuspid aortic valve morphology (Sievers type 2). Although the morphological spectrum of human congenital aortic valve abnormalities includes unicuspid, bicuspid and quadricuspid aortic valves, their embryologic origins may not necessarily be linked, such that animal models of BAV have displayed all possible BAV phenotypes, quadricuspid valves and pulmonary valve abnormalities, but not unicuspid anatomical forms (12). In addition, the prevalence, age at presentation and prognosis of unicuspid and BAV, are not equivalent (13,14). Furthermore, the anatomic definition of unicuspid aortic valve (one cusp with



**Figure 1** Nosology of the congenital BAV condition. Left: anatomically and prognostically complex presentations of the BAV valvulo-aortopathy are those associated with syndromes, left-sided obstructions, significant aortic coarctation, early/accelerated valve dysfunction (stenosis or regurgitation) and/or early aortopathy. Middle: the anatomically and prognostically typical valvulo-aortopathy is usually diagnosed in young and middle-aged adults although it may be diagnosed in children as well and comprises various degrees of progressive valvular dysfunction (mostly high incidence of aortic stenosis), with a high cumulative incidence of aortopathy over the long-term, manifested as thoracic aortic dilatation, without other major associated conditions. Right: the undiagnosed form is diagnosed retrospectively (without any BAV-related complications, some are diagnosed post-mortem), or may present for the first time with a life-threatening complication such as aortic dissection or infective endocarditis. Modified from Michelena *et al.* (1-4) with permission. BAV, bicuspid aortic valve.

or without a commissure: unicommissural or acommisural) (15,16) is very different from that of BAV (two cusps, two commissures); therefore, the Sievers classification includes only one (unicommissural) of the two types of unicuspid aortic valves as if it were a subtype of BAV, which is not correct.

### Nosology of the congenital BAV condition

The congenital BAV condition is a valvulo-aortopathy, characterized by significant heterogeneity of its valvular and aortic phenotypic expressions, of its associated disorders, of its complications and of its prognosis (5,6,17-19). To reconcile this clinical and prognostic heterogeneity, the BAV condition is broadly categorized into three clinical-prognostic subgroups (*Figure 1*). (I) Complex valvulo-aortopathy (1-5,19) is characterized by

concomitant or associated disorders that may be clinically and prognostically worse than the BAV condition per se (i.e., Turner syndrome, Loeys-Dietz syndrome, Shone complex and severe aortic coarctation) and/or by early/accelerated valve dysfunction and/or aortopathy, more commonly diagnosed earlier in the pediatric, adolescent and young adult population (20,21). This presentation frequently requires early surgical/invasive treatment and close surveillance. (II) Typical valvulo-aortopathy (1-6) is the most common type, with progressive BAV dysfunction and/or aortic dilatation without other major associated disorders, is more commonly diagnosed in the young adult and adult, requires long-term surveillance and commonly requires subsequent surgical/invasive treatment. Patients with complex-presentation and typical-presentation valvulo-aortopathies are at risk of developing infective

endocarditis and aortic dissection (*Figure 1*), although aortic dissection is extremely rare in young children with BAV and rare in adults without aortic dilatation (6,22). (III) The undiagnosed BAV subgroup (1-4,6) exhibits a lifelong silent condition with mild or non-progressing valvulo-aortopathy that does not manifest clinically but may come to light at autopsy or incidentally by imaging (*Figure 1*) but may also present with a life-threatening complication with unknown BAV status. Therefore, it commonly represents a retrospective definition. A critical difference between the typical and complex valvulo-aortopathies is the preserved long-term overall life expectancy that is similar to that of the age- and sex-matched general population in patients with the typical valvulo-aortopathy (23), whereas the life expectancy of patients with complex valvulo-aortopathy may be reduced (1-4).

### Clinical importance and Fundamentals of imaging assessment of the congenital BAV condition

In order of frequency, the most common complications of the congenital BAV condition are (6,23): (I) the need for aortic valve surgery due to aortic stenosis; (II) ascending thoracic aortic dilatation that may require surgical repair; (III) the need for aortic valve surgery due to aortic regurgitation; (IV) mitral valve prolapse including the anterior leaflet that may require surgery (24); (V) infective endocarditis (25); and (VI) aortic dissection (22).

At the center of the BAV condition is echocardiography, which serves as the first-line imaging modality in 6 major capacities (26): (I) BAV diagnosis; (II) valvular phenotyping; (III) assessment of valvular function (26); (IV) measurement of the thoracic aorta (the expression of BAV aortopathy is dilatation of the thoracic aorta); (V) exclusion of aortic coarctation and other associated congenital lesions (6,20); and (VI) assessment of uncommon but serious complications such as infective endocarditis and aortic dissection. Transthoracic echocardiography (TTE) is the best modality for hemodynamic assessment of valvular dysfunction and the initial modality for assessment of thoracic aorta size, presence of aortic coarctation and other congenital lesions. Transesophageal echocardiography (TEE) may aid in the diagnosis and phenotyping of BAV if it is not well visualized by TTE and, has excellent accuracy for the diagnosis of aortic dissection and infective endocarditis (1-4).

Advanced imaging modalities are also critical in assessing the BAV condition: electrocardiographic (ECG)-gated cardiac CT and ECG-gated MR. These imaging techniques

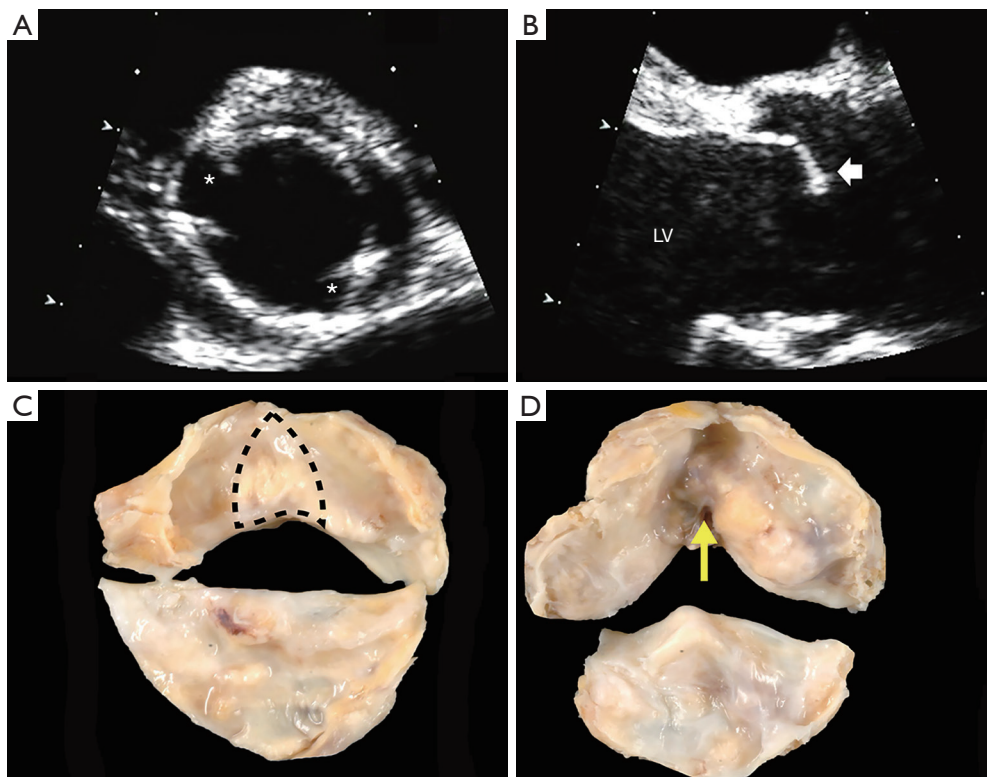
improve diagnostic accuracy and phenotyping of BAV (27,28) and represent the gold standard for measuring the thoracic aorta because they accurately assess aortic diameters that are truly perpendicular to the longitudinal axis of the aorta (1-4). After initial TTE imaging, if any aortic segment cannot be visualized or coarctation cannot be ruled out or any thoracic segment measures  $\geq 45$  mm by TTE, then ECG-gated CT angiography or MR angiography, is recommended (29).

### Definition of the congenital BAV by the international consensus

The congenital BAV is most commonly diagnosed by base-of-the-heart, short-axis aortic valve imaging with TTE or TEE or ECG-gated CT or MR, demonstrating the existence of only two commissures delimiting only two valve cusps (*Figure 2*) (1-4,6,30). On echocardiographic long-axis imaging, systolic doming of the conjoined cusp may be appreciated particularly for right-left coronary cusp fusion (*Figure 2*), but it is less reliable for identifying other BAV phenotypes. The diagnosis can also be made by direct surgical observation (11,31) and by a pathological examination (32). It is important to recognize that a tricuspid aortic valve that is calcified or rheumatic may present a pattern of acquired (non-congenital) fusion of two cusps that may be difficult to differentiate from congenital BAV. In these cases, surgical inspection and/or pathological examination may identify whether the fusion is congenital or not. In the operating room, the surgeon can define the congenital bicuspid condition by comparing the height of the “pseudocommissure” [the attachment of the “raphe” (pseudo-commissure) at the aortic wall], which is lower within the root compared to the height of the true commissures, whose attachment is higher (*Figure 3*). Additional gross features can be used on surgical or pathological inspection, such as the angle formed between the fused cusps (obtuse: congenital fusion; acute: acquired fusion) and the cleavage plane on the ventricular aspect of the fused cusps (absent: congenital; present acquired) (*Figure 2*).

### Definition of the aortic root complex

The term aortic root refers only to the most proximal part of the ascending thoracic aorta, from the distal end of the left ventricular outflow tract to the sinotubular junction (STJ), formed by the sinuses of Valsalva and containing the

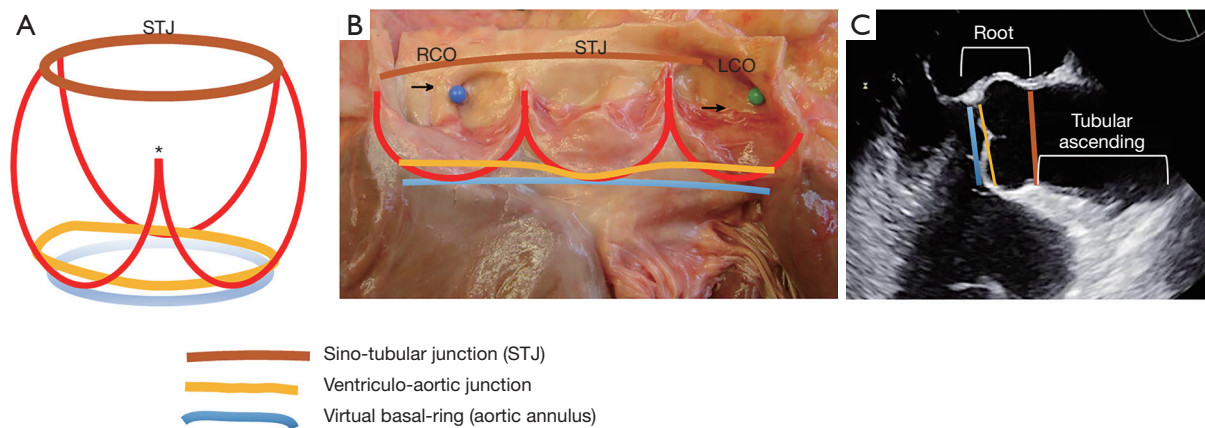


**Figure 2** Diagnosis of congenital BAV by transthoracic echocardiography and pathology. (A) Parasternal short-axis aortic valve systolic still image demonstrating the existence of only 2 commissures (asterisks) delimiting only 2 cusps. (B) Parasternal long-axis still shows systolic doming of the fused (conjoined) cusp (arrow), common for right-left coronary cusp fusion. (C) Pathological congenital BAV specimen shows the area of the raphe (dashed line) from the left ventricular perspective, forming an obtuse angle between the fused cusps. (D) Ventricular side of a tricuspid aortic valve with acquired rheumatic fusion shows the cleavage plane with acute angle (yellow arrow). From Michelena *et al.* (1-4) with permission. LV, left ventricle; BAV, bicuspid aortic valve.

aortic valve (34) (*Figure 3*). The anatomy and physiology of the aortic root complex and its interaction with the valve have been thoroughly investigated as contemporary techniques for aortic valve repair have been introduced and more widely adopted (33,35). Functionally, and particularly, in relation to the competency of the BAV and surgical repair, three elements of the aortic root complex cooperate in determining physiological valve dynamics (36): (I) the STJ; (II) the aortic sinuses with the crown-like attachment line of the aortic valve cusps to the aortic wall at the aortic sinuses (which, as mentioned, assumes a peculiar form in the fused BAV, with 1 of the 3 “crown tips” corresponding to the under-the-raphe pseudocommissure, reaching a lower height than the other 2) (*Figure 3*); and (III) the aortic annulus, which is a virtual circular line inside the left ventricular outflow tract, running through the nadir of the aortic cusps and the bases of the respective inter-cusp

triangles (*Figure 3*). The aortic annulus is a virtual surrogate for the ventriculo-aortic junction, which is the real boundary of the aortic root complex, identified anatomically as the transition from the ventricular muscle to the aortic media and located circumferentially slightly above the nadir of the aortic cusps, crossing the semilunar lines of each cusp’s attachment (*Figure 3*). However, for both surgical and imaging purposes, the virtual aortic annulus is the practical and clinically used anatomical landmark. The aortic root complex, particularly the size of the aortic annulus and the STJ, are indispensable in the maintenance of sufficient diastolic cusp coaptation area to prevent the progression of aortic regurgitation (37) and its recurrence after surgery (38). Therefore, the aortic root complex is the anatomical scaffold that maintains BAV competency, with the BAV cusps acting as a stentless valve and the root complex as its native stent (36).





**Figure 3** The aortic root complex. (A) Schematic drawing of the aortic root: the blue line indicates the virtual basal-ring (aortic annulus); the yellow line depicts the ventriculo-aortic junction (whose non-planar nature is schematically emphasized) (33); the red lines show the crown-shaped attachments of the cusps to the wall of the aortic sinuses [note the different height of the underdeveloped commissure (pseudocommissure, asterisk) compared to that of the other 2 true commissures]; the brown line depicts the STJ. (B) All the above boundaries and structures are reported (same colors as above) in an anatomical specimen of a normal aortic root and tricuspid aortic valve. (C) Echocardiographic view of the aortic root: the levels of the aortic annulus, ventriculo-aortic junction and STJ are shown (same colors as above). It is important to recognize that it is the measurement of the virtual annulus, sinuses and STJ that have clinical and practical implications for the patient with BAV. RCO: blue pin and arrow; LCO: green pin and arrow. From Michelena *et al.* (1-4) with permission. STJ, sinotubular junction; BAV, bicuspid aortic valve; RCO, right coronary orifice; LCO, left coronary orifice.

### BAV types and specific phenotypes by the international consensus

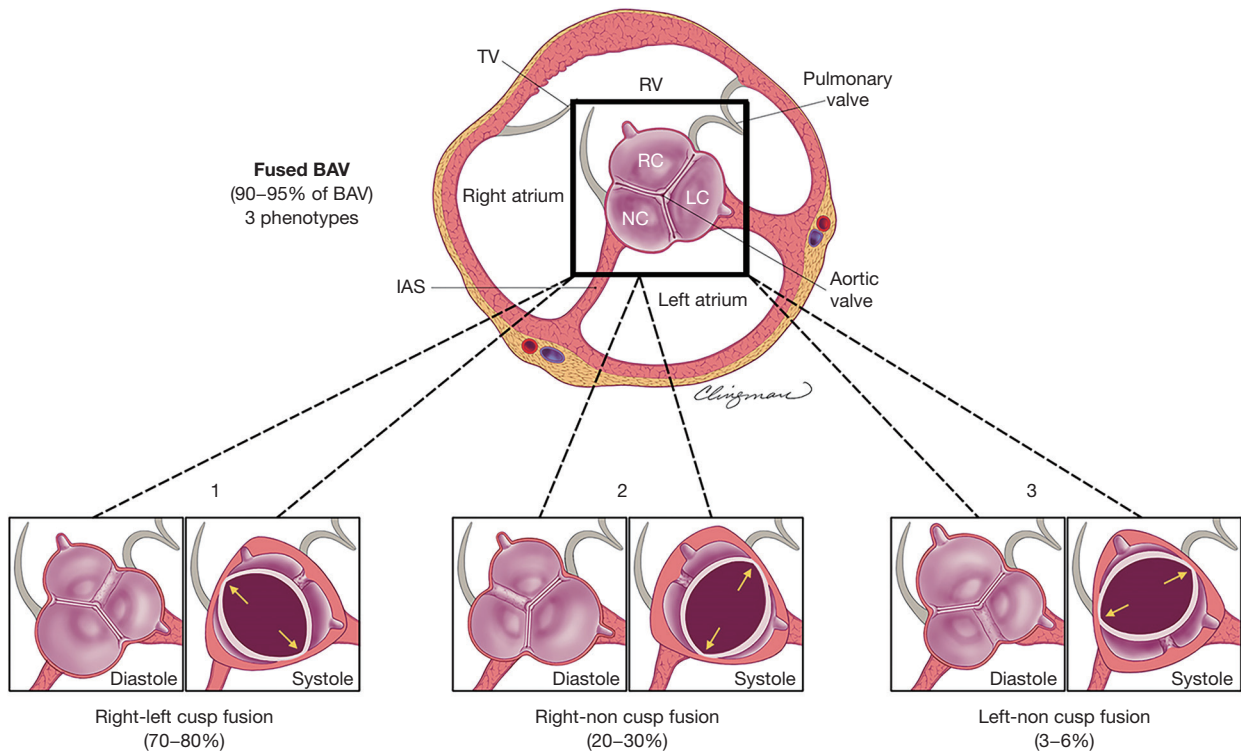
There are three BAV types: the fused BAV, the two-sinus BAV and the partial-fusion BAV, each with specific phenotypes (1-5).

#### The fused BAV type

The fused BAV type is the most common (*Figure 4*), accounting for approximately 90–95% of BAV cases (6,32). The fused BAV is characterized by two of the three cusps anatomically fused or jointed within three distinguishable aortic sinuses, resulting in two functional cusps (one fused or conjoined and the other non-fused) that are usually different in size and shape. Commonly, patients with a fused BAV demonstrate eccentric dominance of the non-fused aortic sinus and its cusp (compared to the other two sinuses and two fused cusps), irrespective of age (39). There are three specific BAV phenotypes within the fused type: right-left cusp fusion, right-non (non-coronary) cusp fusion and left-non cusp fusion (*Figure 4*). The right-left cusp fusion phenotype is the most common (70–80%) (6,32,40). The right-left cusp fusion phenotype is also the most common

across all variations of aortic phenotypes (normal aorta, dilated ascending aorta, dilated root, dilated arch) and across valve dysfunction (regurgitation or stenosis). Although this right-left fusion phenotype statistically develops more AS (6), it has been associated in some patients (41,42) with aortic root dilatation, aortic regurgitation and male preponderance (these associations have been termed the “root phenotype”) (38,39). The right-left cusp fusion is also strongly associated with aortic coarctation in children (43).

The right-non cusp fusion phenotype is the next most common (20–30%). It is associated with a higher prevalence of AS in adults (44) and also, independently predicts aortic regurgitation progression in adults (37). Similarly, the right-non cusp fusion phenotype is associated with a more rapid progression of AS and regurgitation in children and adolescents (43,45). The left-non cusp fusion phenotype is the least common phenotype (3–6%) across studies and needs further study. Referring to the fused phenotypes as BAV with right-left cusp fusion, right-non cusp fusion or left-non cusp fusion, is appropriate. Occasionally, it is possible to recognize a fused BAV but not to be able to discern the fusion phenotype, in which case BAV with indeterminate cusp fusion is appropriate.



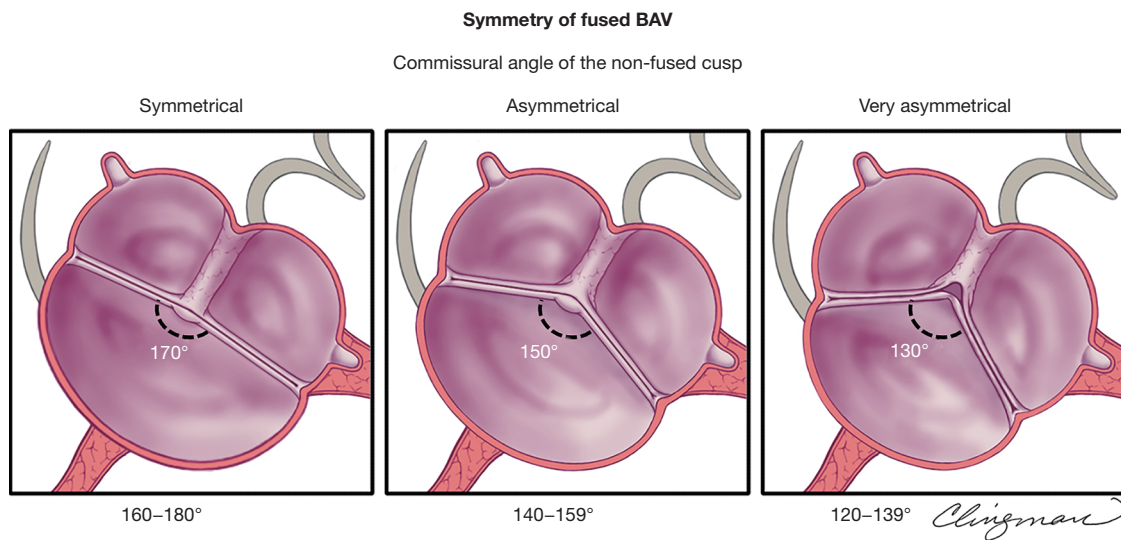
**Figure 4** Schematic of fused BAV phenotypes as seen by parasternal short-axis transthoracic echocardiography. Applicable to similar tomographic views by cardiac computed tomography and cardiovascular magnetic resonance, the figure demonstrates the 3 fused BAV phenotypes as zoomed views of the base of the heart (black square contains a tricuspid aortic valve for reference) for anatomical landmark correlation. Note that all fused BAVs have 3 distinguishable aortic sinuses. Note the oval (American football shape) systolic opening of these 3 valves, as opposed to the triangular opening of a tricuspid aortic valve. 1: Right-left cusp fusion (most common) with visible raphe, different size/shape functional cusps [the non-fused cusp (non-coronary) is commonly a bit larger than the others]. 2: Right-non cusp fusion with visible raphe, different size/shape functional cusps [the non-fused cusp (left) is larger than the others]. 3: Left-non cusp fusion with visible raphe (least common), different size/shape functional cusps [the non-fused cusp (right) is larger than the others]. These 3 fused phenotypes may not have a visible raphe and may also be symmetrical (*Figure 5*). From Michelena *et al.* (1-4) with permission. BAV, bicuspid aortic valve; RC, right cusp; LC, left cusp; NC, noncoronary cusp; RV, right ventricle; TV, tricuspid valve; IAS, interatrial septum.

#### **Importance of raphe and valve symmetry in fused BAV phenotypes**

Frequently (approximately 70%) but not always, a congenital fibrous ridge occurs between the fused cusps, termed “raphe” (32,46). The presence of a raphe has been associated with the progression of valvular dysfunction, particularly AS, and future valvular surgery (30,44,46). A raphe may be present but not initially visible on the echocardiogram and may become visible years later (47). The presence of a significantly calcified raphe may also make the repair of the regurgitant BAV more difficult or not possible. It is important to recognize that some fused BAVs may not have a congenital raphe (32) (this is not recognized by the Sievers’ classification). Therefore, when diagnosing

a fused type, the next descriptor must be: with or without raphe, and further description of the raphe (i.e., calcified versus non-calcified) is warranted.

BAV symmetry for the fused BAV type is defined by the angle between the commissures for the non-fused cusp and, has recently become a critical aspect in the planning and performance of BAV repair for pure aortic regurgitation (5,11,48) (*Figure 5*). From a regurgitation-repair perspective, the BAV “concept” offers a single-line coaptation surface (a tricuspid aortic valve has 3 coaptation lines); if that single coaptation line is straight or almost straight (*Figure 5*, symmetrical), the repair of the regurgitant BAV is simple and reproducible. As the angle between the commissures of the non-fused cusp decreases  $<160^\circ$  (48), the BAV



**Figure 5** Schematic of the transthoracic echocardiographic evaluation of fused BAV symmetry in the parasternal short-axis. Applicable to similar tomographic views by cardiac computed tomography and cardiovascular magnetic resonance, the figure demonstrates different commissural angles of the non-fused cusps (applicable to the 3 fused BAV phenotypes, only right-left cusp fusion is shown), which define symmetry. Left panel: symmetrical (angle 160–180°) right-left cusp fusion BAV with a raphe, where the 2 functional cusps are almost same size/shape (the non-fused cusp is a little larger), and the commissural angle of the non-fused cusp is about 170°. Middle panel: asymmetrical (angle 140–159°) right-left fusion BAV with a raphe, and the commissural angle of the non-fused cusp is about 150°. Right panel: very asymmetrical (angle 120–139°) right-left fusion BAV shows retraction of the conjoined cusp at the raphe level and the commissural angle of the non-fused cusp is about 130°. Note that retraction is more prominent as the angle decreases, which may cause aortic regurgitation. From Michelena *et al.* (1-4) with permission. BAV, bicuspid aortic valve.

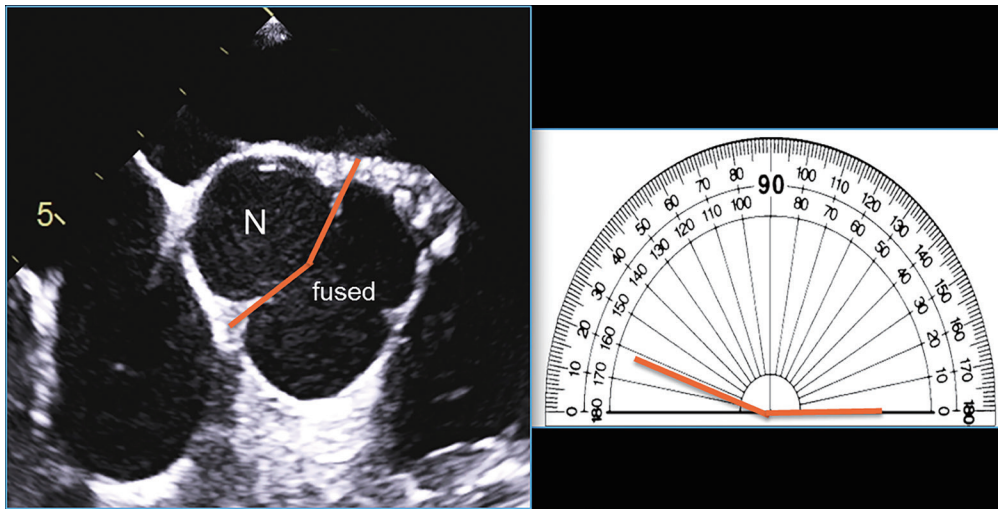
becomes less symmetrical, resembling more a tricuspid (especially <140°) valve (*Figure 5*, very asymmetrical), which becomes technically more challenging for the surgeon to “bicuspidize” during the repair, yet remains repairable in experienced hands. Very asymmetrical valves may exhibit retraction of the free edge of the fused cusp at the raphe level, which is best appreciated by direct surgical visualization (*Figure 5*) or gross pathological inspection and not reliably by imaging. This retraction may contribute to valve regurgitation. Measuring the commissural angle of the non-fused cusp with TEE before cardiopulmonary bypass aids the surgeon in planning the repair (*Figure 6*). Therefore, the symmetry of a fused-type BAV is defined by the angle between the commissures of the non-fused cusp.

### The two-sinus BAV type

The two-sinus BAV type is uncommon, accounting for approximately 5–7% of BAV cases (5,6,32). In contrast to the fused type, the appearance of the two-sinus BAV does not suggest that two of the three cusps have fused; instead,

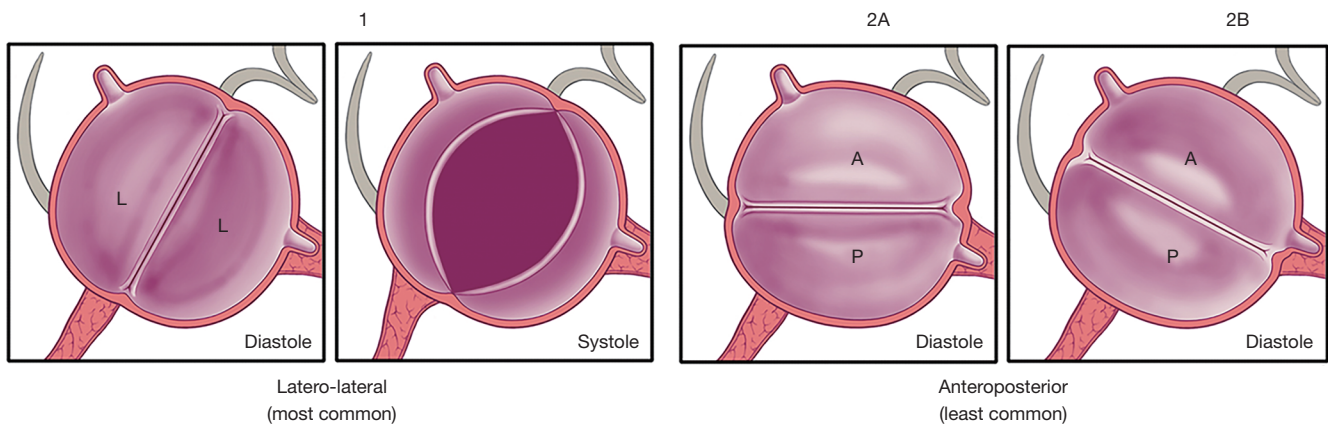
it suggests that two cusps of roughly equal size and shape, each cusp occupying 180° of the annular circumference, were “formed” within only two aortic sinuses, resulting in a two-sinus/two-cusp valve (*Figure 7*) with 180° commissural angles. It is difficult to determine which two cusps could have coalesced to form a two-sinus BAV, but it is usually evident whether the cusps are laterolateral (side-to-side) or anteroposterior (front-to-back) within the short-axis base-of-the-heart plane (*Figure 7*); thus, these are the two specific phenotypes of the two-sinus BAV type. The two-sinus laterolateral BAV has one coronary artery arising from each sinus, whereas the anteroposterior BAV may have one coronary artery arising from each sinus or both coronary arteries arising from the anterior sinus (*Figure 7*). The two-sinus BAV likely represents a more severe expression of the embryologic mechanisms leading to the fused BAV. Referring to these phenotypes as two-sinus laterolateral BAV or two-sinus anteroposterior BAV is appropriate. Occasionally, despite suspicion, it may be difficult to be certain whether there are only two sinuses, in which case, terms such as possible or probable two-



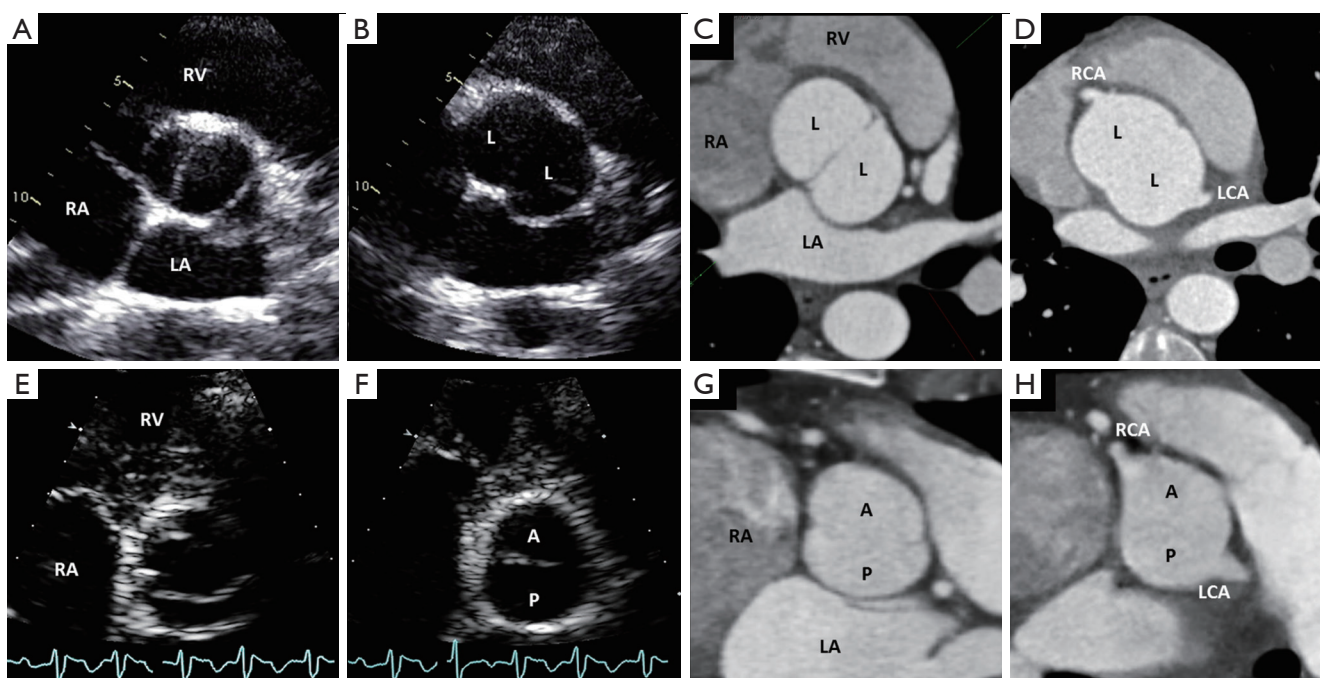


**Figure 6** Transoesophageal echocardiographic measurement of the commissural angle of the non-fused cusp prior to valve repair. Applicable to similar tomographic views by cardiac computed tomography and cardiovascular magnetic resonance, after careful visualization of systolic and diastolic motion of this regurgitant fused-type right-left cusp fusion BAV, the non-fused commissures are identified, and a line is drawn from the position of the commissures to the center of the valve in diastole (left). The angle of the non-fused cusp (N) is then carefully measured at approximately  $162^{\circ}$  on the protractor to the right, suggesting a good repair chance. From Michelena *et al.* (1-4) with permission. BAV, bicuspid aortic valve.

**2-sinus BAV**  
(5–7% of BAV)  
2 phenotypes



**Figure 7** Schematic of the 2-sinus BAV phenotypes as seen by the transthoracic echocardiogram parasternal short-axis. Applicable to similar tomographic views by cardiac computed tomography and cardiovascular magnetic resonance, the figure demonstrates 2-sinus BAV phenotypes as zoomed views of the base of the heart for anatomical landmark correlation. 1: 2-sinus laterolateral BAV with only 2 distinguishable aortic sinuses and 2 roughly equal size/shape cusps each occupying  $180^{\circ}$  of the circumference, with a  $180^{\circ}$  angle of the commissures. The 2-sinus BAV laterolateral phenotype has 1 coronary artery arising from each sinus. 2A: 2-sinus anteroposterior BAV with only 2 distinguishable aortic sinuses and 2 similar size/shape cusps each occupying  $180^{\circ}$  of the circumference, with  $180^{\circ}$  angle of the commissures; 1 coronary arising from each sinus. 2B: 2-sinus anteroposterior BAV, which resembles a fused right-left fusion without a raphe, with only 2 distinguishable aortic sinuses and 2 similar size/shape cusps each occupying  $180^{\circ}$  of the circumference; with coronaries arising from the same sinus. From Michelena *et al.* (1-4) with permission. BAV, bicuspid aortic valve.



**Figure 8** Diastolic and systolic still images of the 2-sinus BAV phenotypes obtained from transthoracic echocardiogram and diastolic still images by ECG-gated cardiac CT. (A) 2-sinus laterolateral BAV in systole, with only 2 distinguishable aortic sinuses in diastole (B) and roughly equal size/shape cusps occupying 180° of the circumference, reproducible on an equivalent tomographic cut as seen with CT (C). Note the coronary arteries arising 1 from each sinus (D). (E) 2-sinus anteroposterior BAV in systole, with only 2 distinguishable aortic sinuses and roughly equal size/shape cusps occupying 180° of the circumference (F, diastolic still frame), reproducible on an equivalent tomographic cut as seen with CT (G). Note coronary arteries arising 1 from each sinus in this particular example (H). From Michelena *et al.* (1-4) with permission. BAV, bicuspid aortic valve; ECG, electrocardiographic; CT, computed tomography; RA, right atrium; RV, right ventricle; LA, left atrium; A, anterior cusp; P, posterior cusp; L, lateral cusp; RCA, right coronary artery; LCA, left coronary artery.

sinus BAV may be used. There is a lack of scientific data on the clinical/prognostic associations of the two-sinus BAV, which represents a “morphologically severe” form of BAV. As with all BAV phenotypes, the short axis tomographic cut is reproducible by MR and CT (*Figure 8*). Therefore, we hope that through this nomenclature/classification system, the research community directs more attention towards this BAV type.

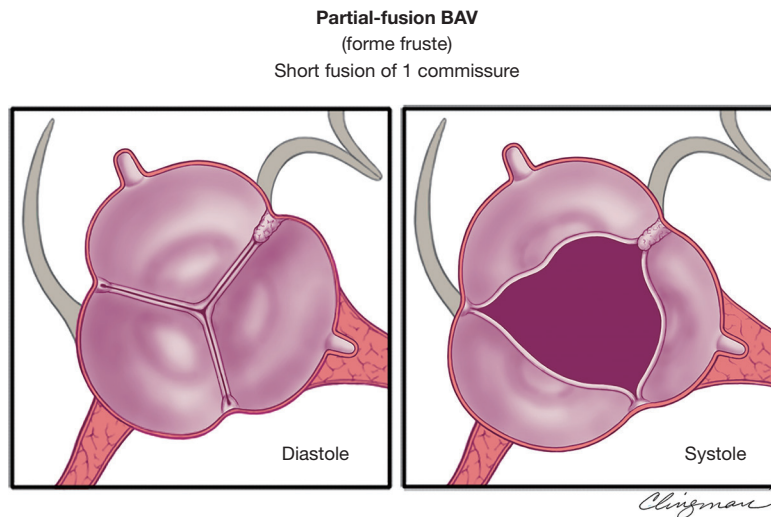
### The partial-fusion (or forme fruste) BAV type

The prevalence of this recently recognized partial-fusion BAV (or forme fruste BAV) is unknown (49) (*Figure 9*). The appearance of the partial-fusion BAV is that of a typical tricuspid aortic valve with three symmetrical cusps with a systolic triangular opening and commissural angles of 120°, yet on surgical inspection or high-resolution imaging, less than 50% cusp fusion is noted at the base of a commissure,

forming a small “mini-raphe” (5,49-51). It is important to recognize and further study the partial-fusion BAV, which has been described most frequently in the operating room in patients undergoing surgery for aortic dilatation (49). This forme fruste BAV results in alteration of aortic flow patterns, consisting of increased flow eccentricity and increased vortices (50), perhaps partially explaining the apparent high prevalence of aortic dilatation in these patients. Referring to this phenotype as partial-fusion BAV or forme fruste BAV is appropriate, as is noting between which cusps the fusion occurs: right-left, right-non and so forth. This phenotype also requires further study.

### Definition of aortic dilatation by the international consensus

The definition of “aortic aneurysm” (52) is rarely applied in clinical practice, and the term aneurysm carries a somber



**Figure 9** Schematic of the partial-fusion BAV phenotype as seen by the transthoracic echocardiographic parasternal short axis. Left panel: The imaging appearance in diastole of the partial-fusion or forme fruste BAV is that of a tricuspid aortic valve. Right panel: The imaging diagnosis is usually made in systole. Although the opening appears triangular, there is a small fusion of the right and left cusps with a “mini-raphe”. These can be suspected by looking at the transoesophageal echocardiogram and sometimes confirmed by a 3D transoesophageal echocardiogram, cardiovascular magnetic resonance or cardiac computed tomography. Definitive confirmation is usually obtained by surgical inspection or pathology. From Michelena *et al.* (1-4) with permission. BAV, bicuspid aortic valve.

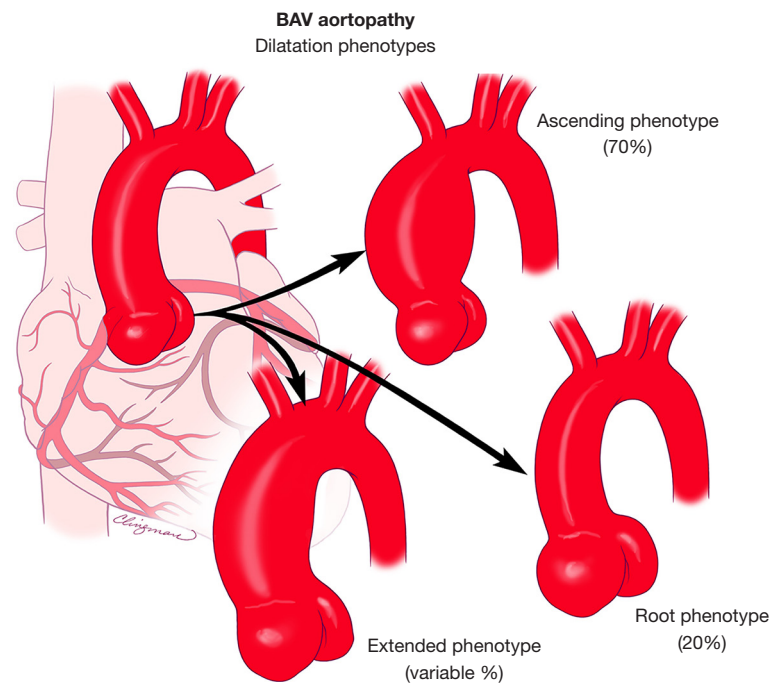
or dismal connotation for patients. Therefore, we propose a simple, universal term: aortic dilatation. Qualitative descriptive terms, such as saccular or fusiform dilatation or STJ effacement, may be important for aorta specialists and surgeons. A full discussion on aortic dilatation in patients with BAV is presented in the full documents (1-4).

### BAV aortopathy phenotypes

The importance of recognizing BAV aortopathic phenotypes is that their presence and association with specific valvular phenotypes and dysfunction patterns may imply different clinical histories for a patient with BAV (53). There are three major forms of aortic dilatation phenotypes: (I) the ascending phenotype (dilatation preferentially located at the tubular ascending tract beyond the STJ (*Figure 10*), accounting for approximately 70% of BAV aortopathy cases; (II) the root phenotype [dilatation preferentially located at the root (sinuses of Valsalva)] accounting for approximately 20% of BAV aortopathy cases (*Figure 10*) (5,41,42,54). Importantly, the root phenotype may have mild ascending dilatation but significantly prevails at the root, and the ascending phenotype may have mild root dilatation but significantly prevails at the ascending portion; (III) the

extended phenotype, where significant dilatation may be present in both the root and tubular ascending aorta without predominance, or significant dilatation of the ascending and arch portions is found (*Figure 10*). The root and ascending phenotypes often correspond to two clearly distinct overall patient phenotypes: roughly, the older patient with BAV, either male or female, presenting more often with aortic valve sclerosis/stenosis and the ascending phenotype and, the younger patient with BAV, usually male, presenting with aortic regurgitation of degrees ranging from mild to severe and the root phenotype (41,55,56). However, those associations are not universal, and the right-left cusp fusion BAV can be associated with either aortic phenotype (56). The root phenotype has been associated with greater rates of acute aortic dissection in the postoperative follow-up of patients with BAV who had undergone simple aortic valve replacement compared to the ascending phenotype (57).

As mentioned, in a proportion of these cases, a localized dilatation at first observation can evolve during follow-up, with possible dilatation of previously normal adjacent segments of the aorta. In this scenario, the ascending phenotype can present, especially if a right-non cusp fusion valve is present, with associated dilatation of the aortic arch; it is appropriate to refer to this condition as ascending



**Figure 10** BAV aortopathy phenotypes. On the left is a normal aorta. Top: the most common phenotype, the ascending phenotype (approximately 70%), is preferential dilatation of the tubular ascending aorta. Middle: the root phenotype involves preferential dilatation of the root, seen in approximately 20% of patients with BAVs with aortopathy. Bottom: the extended phenotype shows dilatation of the root, the ascending aorta and the arch. The most common extended phenotypes are root plus ascending aorta and ascending aorta plus arch. From Michelena *et al.* (1-4) with permission. BAV, bicuspid aortic valve.

phenotype extended. Similarly, the root phenotype has been demonstrated to be independently associated with faster growth of the ascending tubular tract, so that cases of “cross-over” from an initial root phenotype configuration to significant dilatation of both tracts have been observed; root phenotype extended would be the appropriate definition of this form. In the context of a root phenotype, the presence and progression of effacement of the STJ may be an initial sign of this kind of evolution.

### The BAV anatomic spectrum

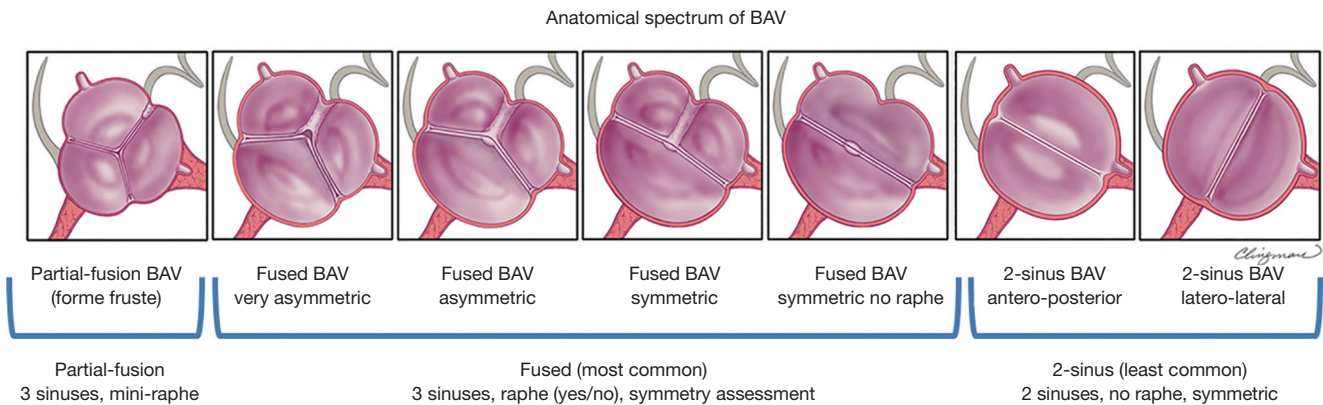
The BAV phenotypic expression represents an anatomical continuum that is likely related to the severity of its embryologic mechanisms. Therefore, we propose a general BAV anatomical spectrum (Figure 11) of BAV phenotypes according to “bicuspidity”, defined as resemblance to a two-sinus BAV. This spectrum represents a continuum that begins with what is closer to a tricuspid aortic valve

(i.e., partial-fusion), continues with the asymmetric fused phenotypes with raphe, and as the symmetry of the valve increases and raphes become absent, it finishes with the two-sinus phenotype.

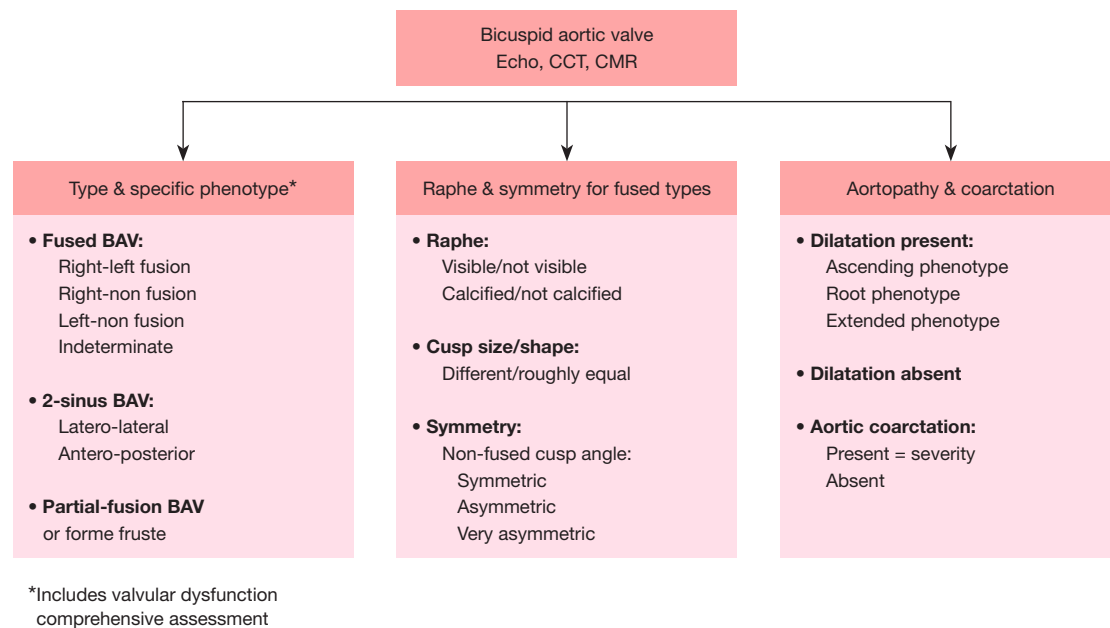
### Conclusions

This international consensus identifies three major types of clinical presentation/outcomes for BAV patients, three major types of valvular phenotypes and three major types of aortopathy phenotypes. Based on the new nomenclature and classification consensus, Figure 12 presents a simple algorithm of the critical imaging evaluation for the BAV valvulo-aortopathy. Three critical anatomic aspects to be described in all patients with BAVs are: (I) the type and specific phenotype of the BAV and valve function; (II) the presence and characteristics of the raphe of the fused BAV, and the symmetry of the fused BAV; and (III) the presence and phenotype of aortopathy and whether coarctation is present.





**Figure 11** Schematic of the BAV anatomical spectrum using the most common right-left cusp fusion as an example. From left to right, note the partial-fusion BAV resembling a tricuspid aortic valve likely associated with a mild embryologic defect, then spanning a continuum of fused BAV with increasing commissural angles and increasing cusp size/shape similarity, ending with the 2-sinus BAV phenotypes that represent almost perfect “bicuspidity” and are likely associated with the most severe embryologic defects. From Michelena *et al.* (1-4) with permission. BAV, bicuspid aortic valve.



**Figure 12** Critical imaging evaluation of the congenital BAV condition. BAV, bicuspid aortic valve; CCT, cardiac computed tomography; CMR, cardiac magnetic resonance.

## Acknowledgments

The author wishes to thank Carl Clingman, MA, Senior Medical Illustrator, Biomedical & Scientific Visualization, Mayo Clinic, for his illustrations.

*Funding:* None.

## Footnote

*Conflicts of Interest:* Artivion (Consulting fees, speaker), and Mayo co-PI of PROACT Xa trial, Biostable Science and Engineering, Inc. (Consulting fees, speaker). The disclosures are unrelated to the keynote lecture.

*Open Access Statement:* This is an Open Access article distributed in accordance with the Creative Commons Attribution-NonCommercial-NoDerivs 4.0 International License (CC BY-NC-ND 4.0), which permits the non-commercial replication and distribution of the article with the strict proviso that no changes or edits are made and the original work is properly cited (including links to both the formal publication through the relevant DOI and the license). See: <https://creativecommons.org/licenses/by-nc-nd/4.0/>.

## References

1. Michelena HI, Corte AD, Evangelista A, et al. International Consensus Statement on Nomenclature and Classification of the Congenital Bicuspid Aortic Valve and Its Aortopathy, for Clinical, Surgical, Interventional and Research Purposes. *Radiol Cardiothorac Imaging* 2021;3:e200496.
2. Michelena HI, Della Corte A, Evangelista A, et al. International consensus statement on nomenclature and classification of the congenital bicuspid aortic valve and its aortopathy, for clinical, surgical, interventional and research purposes. *J Thorac Cardiovasc Surg* 2021;162:e383-414.
3. Michelena HI, Della Corte A, Evangelista A, et al. International Consensus Statement on Nomenclature and Classification of the Congenital Bicuspid Aortic Valve and Its Aortopathy, for Clinical, Surgical, Interventional and Research Purposes. *Ann Thorac Surg* 2021;112:e203-35.
4. Michelena HI, Della Corte A, Evangelista A, et al. International consensus statement on nomenclature and classification of the congenital bicuspid aortic valve and its aortopathy, for clinical, surgical, interventional and research purposes. *Eur J Cardiothorac Surg* 2021;60:448-76.
5. Michelena HI, Della Corte A, Evangelista A, et al. Speaking a common language: Introduction to a standard terminology for the bicuspid aortic valve and its aortopathy. *Prog Cardiovasc Dis* 2020;63:419-24.
6. Michelena HI, Prakash SK, Della Corte A, et al. Bicuspid aortic valve: identifying knowledge gaps and rising to the challenge from the International Bicuspid Aortic Valve Consortium (BAVCon). *Circulation* 2014;129:2691-704.
7. Sievers HH, Schmidtke C. A classification system for the bicuspid aortic valve from 304 surgical specimens. *J Thorac Cardiovasc Surg* 2007;133:1226-33.
8. Schaefer BM, Lewin MB, Stout KK, et al. The bicuspid aortic valve: an integrated phenotypic classification of leaflet morphology and aortic root shape. *Heart* 2008;94:1634-8.
9. Kang JW, Song HG, Yang DH, et al. Association between bicuspid aortic valve phenotype and patterns of valvular dysfunction and bicuspid aortopathy: comprehensive evaluation using MDCT and echocardiography. *JACC Cardiovasc Imaging* 2013;6:150-61.
10. Schneider U, Feldner SK, Hofmann C, et al. Two decades of experience with root remodeling and valve repair for bicuspid aortic valves. *J Thorac Cardiovasc Surg* 2017;153:S65-71.
11. de Kerchove L, Mastrobuoni S, Froede L, et al. Variability of repairable bicuspid aortic valve phenotypes: towards an anatomical and repair-oriented classification. *Eur J Cardiothorac Surg* 2019. [Epub ahead of print].
12. Fernández B, Soto-Navarrete MT, López-García A, et al. Bicuspid Aortic Valve in 2 Model Species and Review of the Literature. *Vet Pathol* 2020;57:321-31.
13. Slostad BD, Witt CM, O'Leary PW, et al. Unicuspid Aortic Valve: Demographics, Comorbidities, Echocardiographic Features, and Long-Term Outcomes. *Circulation* 2019;140:1853-5.
14. Tsang MY, Abudiab MM, Ammash NM, et al. Quadricuspid Aortic Valve: Characteristics, Associated Structural Cardiovascular Abnormalities, and Clinical Outcomes. *Circulation* 2016;133:312-9.
15. Fealey ME, Edwards WD, Miller DV, et al. Unicommisural aortic valves: gross, histological, and immunohistochemical analysis of 52 cases (1978-2008). *Cardiovasc Pathol* 2012;21:324-33.
16. Naito S, Sequeira-Gross T, Petersen J, et al. Focus on a rare clinical entity: unicuspid aortic valve disease. *Expert Rev Cardiovasc Ther* 2020;18:625-33.
17. Michelena HI, Suri RM, Katan O, et al. Sex Differences and Survival in Adults With Bicuspid Aortic Valves: Verification in 3 Contemporary Echocardiographic Cohorts. *J Am Heart Assoc* 2016;5:e004211.
18. Roberts WC. The congenitally bicuspid aortic valve. A study of 85 autopsy cases. *Am J Cardiol* 1970;26:72-83.
19. Michelena HI, Vallabhajosyula S, Prakash SK. Nosology Spectrum of the Bicuspid Aortic Valve Condition: Complex-Presentation Valvulo-Aortopathy. *Circulation* 2020;142:294-9.
20. Niaz T, Poterucha JT, Johnson JN, et al. Incidence, morphology, and progression of bicuspid aortic valve in pediatric and young adult subjects with coexisting congenital heart defects. *Congenit Heart Dis* 2017;12:261-9.

21. Niaz T, Poterucha JT, Olson TM, et al. Characteristic Morphologies of the Bicuspid Aortic Valve in Patients with Genetic Syndromes. *J Am Soc Echocardiogr* 2018;31:194-200.
22. Michelena HI, Khanna AD, Mahoney D, et al. Incidence of aortic complications in patients with bicuspid aortic valves. *JAMA* 2011;306:1104-12.
23. Yang LT, Tribouilloy C, Masri A, et al. Clinical presentation and outcomes of adults with bicuspid aortic valves: 2020 update. *Prog Cardiovasc Dis* 2020;63:434-41.
24. Padang R, Enriquez-Sarano M, Pislaru SV, et al. Coexistent bicuspid aortic valve and mitral valve prolapse: epidemiology, phenotypic spectrum, and clinical implications. *Eur Heart J Cardiovasc Imaging* 2019;20:677-86.
25. Michelena HI, Katan O, Suri RM, et al. Incidence of Infective Endocarditis in Patients With Bicuspid Aortic Valves in the Community. *Mayo Clin Proc* 2016;91:122-3.
26. Michelena HI, Chandrasekaran K, Topilsky Y, et al. The Bicuspid Aortic Valve Condition: The Critical Role of Echocardiography and the Case for a Standard Nomenclature Consensus. *Prog Cardiovasc Dis* 2018;61:404-15.
27. Tanaka R, Yoshioka K, Niinuma H, et al. Diagnostic value of cardiac CT in the evaluation of bicuspid aortic stenosis: comparison with echocardiography and operative findings. *AJR Am J Roentgenol* 2010;195:895-9.
28. Gleeson TG, Mwangi I, Horgan SJ, et al. Steady-state free-precession (SSFP) cine MRI in distinguishing normal and bicuspid aortic valves. *J Magn Reson Imaging* 2008;28:873-8.
29. Borger MA, Fedak PWM, Stephens EH, et al. The American Association for Thoracic Surgery consensus guidelines on bicuspid aortic valve-related aortopathy: Executive summary. *J Thorac Cardiovasc Surg* 2018;156:473-80.
30. Michelena HI, Desjardins VA, Avierinos JF, et al. Natural history of asymptomatic patients with normally functioning or minimally dysfunctional bicuspid aortic valve in the community. *Circulation* 2008;117:2776-84.
31. Angelini A, Ho SY, Anderson RH, et al. The morphology of the normal aortic valve as compared with the aortic valve having two leaflets. *J Thorac Cardiovasc Surg* 1989;98:362-7.
32. Sabet HY, Edwards WD, Tazelaar HD, et al. Congenitally bicuspid aortic valves: a surgical pathology study of 542 cases (1991 through 1996) and a literature review of 2,715 additional cases. *Mayo Clin Proc* 1999;74:14-26.
33. de Kerchove L, Jashari R, Boodhwani M, et al. Surgical anatomy of the aortic root: implication for valve-sparing reimplantation and aortic valve annuloplasty. *J Thorac Cardiovasc Surg* 2015;149:425-33.
34. Sievers HH, Hemmer W, Beyersdorf F, et al. The everyday used nomenclature of the aortic root components: the tower of Babel? *Eur J Cardiothorac Surg* 2012;41:478-82.
35. Khelil N, Sleilaty G, Palladino M, et al. Surgical anatomy of the aortic annulus: landmarks for external annuloplasty in aortic valve repair. *Ann Thorac Surg* 2015;99:1220-6.
36. El Khoury G, Glineur D, Rubay J, et al. Functional classification of aortic root/valve abnormalities and their correlation with etiologies and surgical procedures. *Curr Opin Cardiol* 2005;20:115-21.
37. Yang LT, Pellikka PA, Enriquez-Sarano M, et al. Stage B Aortic Regurgitation in Bicuspid Aortic Valve: New Observations on Progression Rate and Predictors. *JACC Cardiovasc Imaging* 2020;13:1442-5.
38. Schneider U, Hofmann C, Aicher D, et al. Suture Annuloplasty Significantly Improves the Durability of Bicuspid Aortic Valve Repair. *Ann Thorac Surg* 2017;103:504-10.
39. Stefek HA, Lin KH, Rigsby CK, et al. Eccentric Enlargement of the Aortic Sinuses in Pediatric and Adult Patients with Bicuspid Aortic Valves: A Cardiac MRI Study. *Pediatr Cardiol* 2020;41:350-60.
40. Kong WKF, Regeer MV, Poh KK, et al. Inter-ethnic differences in valve morphology, valvular dysfunction, and aortopathy between Asian and European patients with bicuspid aortic valve. *Eur Heart J* 2018;39:1308-13.
41. Della Corte A, Bancone C, Quarto C, et al. Predictors of ascending aortic dilatation with bicuspid aortic valve: a wide spectrum of disease expression. *Eur J Cardiothorac Surg* 2007;31:397-404; discussion 404-5.
42. Detaint D, Michelena HI, Nkomo VT, et al. Aortic dilatation patterns and rates in adults with bicuspid aortic valves: a comparative study with Marfan syndrome and degenerative aortopathy. *Heart* 2014;100:126-34.
43. Fernandes SM, Sanders SP, Khairy P, et al. Morphology of bicuspid aortic valve in children and adolescents. *J Am Coll Cardiol* 2004;44:1648-51.
44. Evangelista A, Gallego P, Calvo-Iglesias F, et al. Anatomical and clinical predictors of valve dysfunction and aortic dilation in bicuspid aortic valve disease. *Heart* 2018;104:566-73.
45. Fernandes SM, Khairy P, Sanders SP, et al. Bicuspid aortic valve morphology and interventions in the young. *J Am Coll Cardiol* 2007;49:2211-4.

46. Kong WK, Delgado V, Poh KK, et al. Prognostic Implications of Raphe in Bicuspid Aortic Valve Anatomy. *JAMA Cardiol* 2017;2:285-92.
47. Yang LT, Enriquez-Sarano M, Michelena HI. The bicuspid aortic valve raphe: an evolving structure. *Eur Heart J Cardiovasc Imaging* 2020;21:590.
48. Aicher D, Kuniyama T, Abou Issa O, et al. Valve configuration determines long-term results after repair of the bicuspid aortic valve. *Circulation* 2011;123:178-85.
49. Sperling JS, Lubat E. 'Forme fruste' or 'Incomplete' bicuspid aortic valves with very small raphes: The prevalence of bicuspid valve and its significance may be underestimated. *Int J Cardiol* 2015;184:1-5.
50. Guala A, Rodriguez-Palomares J, Galian-Gay L, et al. Partial Aortic Valve Leaflet Fusion Is Related to Deleterious Alteration of Proximal Aorta Hemodynamics. *Circulation* 2019;139:2707-9.
51. Michelena HI, Yang LT, Enriquez-Sarano M, et al. The elusive 'forme fruste' bicuspid aortic valve: 3D transoesophageal echocardiography to the rescue. *Eur Heart J Cardiovasc Imaging* 2020;21:1169.
52. Hiratzka LF, Bakris GL, Beckman JA, et al. 2010 ACCF/AHA/AATS/ACR/ASA/SCA/SCAI/SIR/STS/SVM guidelines for the diagnosis and management of patients with Thoracic Aortic Disease: a report of the American College of Cardiology Foundation/American Heart Association Task Force on Practice Guidelines, American Association for Thoracic Surgery, American College of Radiology, American Stroke Association, Society of Cardiovascular Anesthesiologists, Society for Cardiovascular Angiography and Interventions, Society of Interventional Radiology, Society of Thoracic Surgeons, and Society for Vascular Medicine. *Circulation* 2010;121:e266-369.
53. Della Corte A, Michelena HI, Citarella A, et al. Risk Stratification in Bicuspid Aortic Valve Aortopathy: Emerging Evidence and Future Perspectives. *Curr Probl Cardiol* 2021;46:100428.
54. Della Corte A, Bancone C, Buonocore M, et al. Pattern of ascending aortic dimensions predicts the growth rate of the aorta in patients with bicuspid aortic valve. *JACC Cardiovasc Imaging* 2013;6:1301-10.
55. Della Corte A, Bancone C, Dialetto G, et al. The ascending aorta with bicuspid aortic valve: a phenotypic classification with potential prognostic significance. *Eur J Cardiothorac Surg* 2014;46:240-7; discussion 247.
56. Wojnarski CM, Roselli EE, Idrees JJ, et al. Machine-learning phenotypic classification of bicuspid aortopathy. *J Thorac Cardiovasc Surg* 2018;155:461-469.e4.
57. Girdauskas E, Disha K, Rouman M, et al. Aortic events after isolated aortic valve replacement for bicuspid aortic valve root phenotype: echocardiographic follow-up study. *Eur J Cardiothorac Surg* 2015;48:e71-6.

**Cite this article as:** Michelena HI. Speaking a common language: the international consensus on bicuspid aortic valve nomenclature and classification. *Ann Cardiothorac Surg* 2022;11(4):402-417. doi: 10.21037/acs-2022-bav-24