

A concise history of echocardiography: timeline, pioneers, and landmark publications

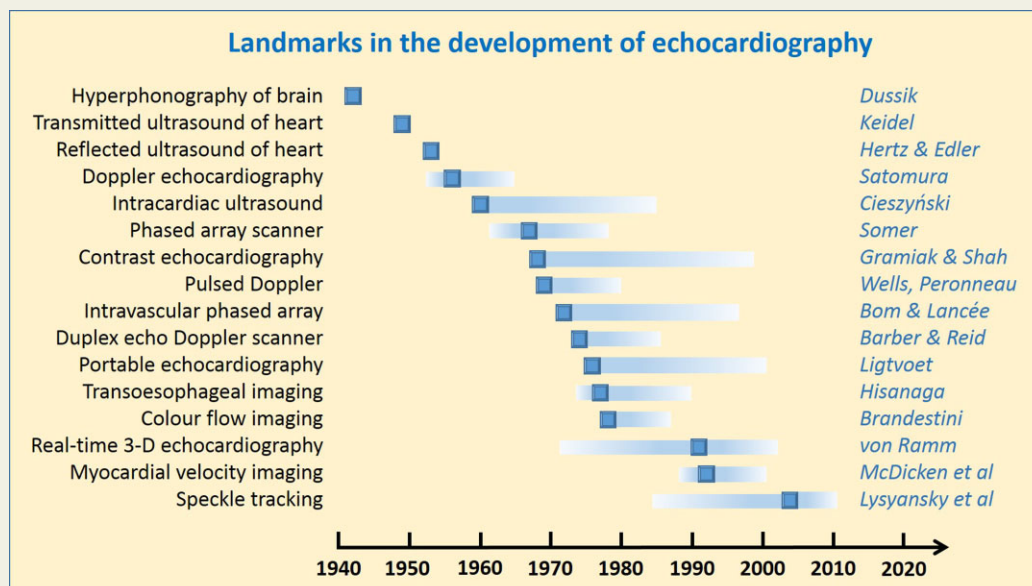
Alan G. Fraser *,¹ **Mark J. Monaghan**², **Antonius F.W. van der Steen**³,
and George R. Sutherland⁴

¹Consultant Cardiologist, University Hospital of Wales, and Emeritus Professor of Cardiology, School of Medicine, Cardiff University, Heath Park, Cardiff CF14 4XW, UK; Visiting Professor, Cardiovascular Imaging and Dynamics, Katholieke Universiteit Leuven, Belgium; ²Immediate Past Director of Non-Invasive Cardiology, King's College Hospital, London, UK; ³Head of Biomedical Engineering, Cardiology Department, Thorax Centre Erasmus University Medical Centre Rotterdam, The Netherlands; and ⁴Retired Professor of Cardiology, St George's Hospital Medical School, London, UK

Received 10 May 2022; revised 24 May 2022; accepted 26 May 2022; online publish-ahead-of-print 28 June 2022

Echocardiography is less than 70 years old, and many major advances have occurred within living memory, but already some pioneering contributions may be overlooked. In order to consider what circumstances have been common to the most successful innovations, we have studied and here provide a timeline and summary of the most important developments in transthoracic and transoesophageal ultrasound imaging and Doppler techniques, as well as in intravascular ultrasound and imaging in paediatric cardiology. The entries are linked to a comprehensive list of first publications and to a collection of first-hand historical accounts published by early investigators. Review of the original manuscripts highlights that it is difficult to establish unequivocal precedence for many new imaging methods, since engineers were often working independently but simultaneously on similar problems. Many individuals who are prominently linked with particular developments were not the first in their field. Developments in echocardiography have been highly dependent on technological advances, and most likely to be successful when engineers and clinicians were able to collaborate with open exchange between centres and disciplines. As with many other new medical technologies, initial responses were sceptical and introduction into clinical practice required persistence and substantial energy from the first adopters. Current developments involve advances in software as much as in equipment, and progress will depend on continuing collaborations between engineers and clinical scientists, for example to identify unmet needs and to investigate the clinical impact of particular imaging approaches.

Graphical Abstract



* Corresponding author. Tel: +44 (0)29 2184 5366, Fax: +44 (0)29 2184 4473, E-mail: fraserag@cf.ac.uk

© The Author(s) 2022. Published by Oxford University Press on behalf of the European Society of Cardiology.

This is an Open Access article distributed under the terms of the Creative Commons Attribution-NonCommercial License (<https://creativecommons.org/licenses/by-nc/4.0/>), which permits non-commercial re-use, distribution, and reproduction in any medium, provided the original work is properly cited. For commercial re-use, please contact journals.permissions@oup.com

Selected principal milestones in the development of echocardiography. Details and references can be found in the text, timeline, and references.

Keywords echocardiography • history • pioneers • key publications

Introduction

Ultrasound imaging is the only major medical imaging modality for which no-one was awarded a Nobel Prize. Although some investigators were nominated, notably Edler and Hertz as pioneers of cardiac imaging, it may have been difficult for the nominating committee to establish precedence since the development of ultrasound for cardiovascular imaging depended on many prior insights from physics (Figure 1), initial technical developments, and preliminary clinical experiments. Nonetheless, certain major milestones can be identified.

Echocardiography is now an ubiquitous and essential diagnostic investigation, yet the first exploratory studies were performed less than 70 years ago, and the technique became established in clinical practice only about 50 years ago. Many key advances are still within living memory. To understand why and how early experiments were performed and prototypes were developed, we identified and have reviewed the original publications, as well as first-hand accounts of their research published or described by pioneering investigators. We provide a timeline of the most important developments, cross-referenced to the first or key publications^{1–94} (Table 1). The objective of this historical perspective is to provide an authoritative summary in a single publication, from which we can identify common circumstances that may contribute to successful innovation and implementation of effective new diagnostic methods

Imaging

The first successful use of *reflected* ultrasound to examine the heart is attributed to Inge Edler, a physician, and Hellmuth Hertz, a physicist, working in Lund in Sweden in 1953. Their initial question came from Edler, who wondered if radar could be used to study the heart. He asked for advice from Hertz,⁹⁵ who was aware of the use of ultrasound for the non-destructive detection of flaws in metals. Hertz arranged to try out a scanner belonging to the Tekniska

Röntgencentralen company and used at the Kockum shipyard in nearby Malmö, on himself, and then he and Edler borrowed it over a weekend. They became convinced that the ‘ultrasonic reflectoscope’ could become a valuable tool for the diagnosis of heart disease,^{96,97} and so they organized the loan of a machine from Siemens. Hertz devised an attachment for recording the output from its cathode ray oscilloscope, whereafter they exposed the first roll of film of an M-mode echocardiographic recording on 29th October 1953 (Figures 2 and 3). They published their initial experience in the proceedings of the Royal Physiographic Society of Lund in 1954.²³ Later both Edler (personal communication) and Hertz⁹⁶ recalled that at that time they had been unaware of earlier experiments with ultrasound for medical imaging.

When his doctoral thesis was published as a supplement to *Acta Medica Scandinavica* in 1961, Edler cited earlier work by Dussik, Keidel, Wild and Reid.²⁸ Dussik had considered using reflected rather than transmitted ultrasound to image the brain but not pursued that option.⁹⁸ Keidel experimented with reflections to image the heart, but without success perhaps because of the low frequency that he was using, and so he reverted to transmitting ultrasound through the thorax.^{16,17,99} Elsewhere during the late 1940s, several groups in the USA were studying the properties of ultrasound in tissue,¹⁰⁰ whereas others were studying its therapeutic potential. Experiments in Boston suggested that the varying intensities of the transmitted signals observed by Dussik and Keidel could be largely explained by absorption and attenuation. Ballantine *et al.*¹⁰¹ in the USA also referred briefly to reflected ultrasound when in 1950 they reported their investigations of the brain with transmitted ultrasound. And not long afterwards, Wild with Neal^{18,19} examined brain tissue *in vitro* and a breast lump *in vivo*, using reflected ultrasound at 15 MHz. He and Reid developed ‘echography’ to scan tissues; by sweeping a single ultrasonic beam mechanically across the surface of a sample, they

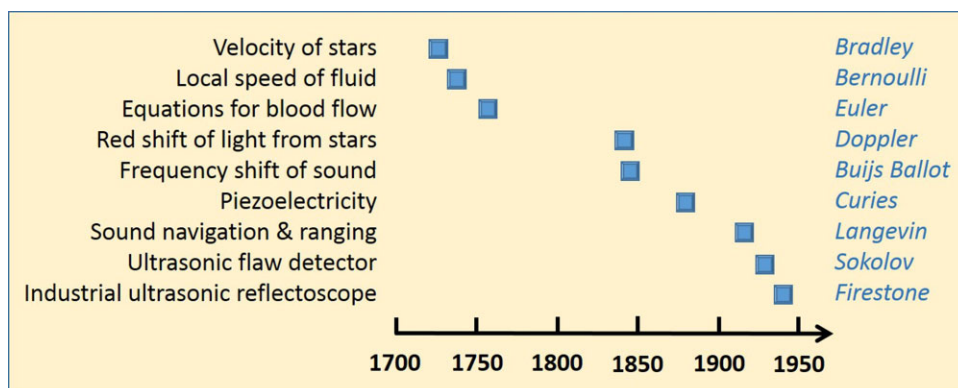


Figure 1 Timeline of key insights from physics that remain important for current echocardiographic practice.

Table 1 Cardiac and cardiovascular ultrasound timeline

| Year | Scientific contribution |
|------|--|
| 1727 | James Bradley reported the aberration of light from stars, and measured its speed. ¹ |
| 1738 | Daniel Bernoulli related the speed of a fluid to a local decrease in pressure or potential energy. ² |
| 1757 | Leonhard Euler (who had studied with Bernoulli's father) published general principles of fluid dynamics, ³ followed in 1775 by his publication on flow in blood that is still applicable to non-invasive haemodynamic assessments. ⁴ |
| 1842 | Christian Doppler gave paper 'On the coloured light of the double stars and certain other heavenly bodies' ⁵ to the Royal Bohemian Society of Sciences, Prague, 25th May (which was a theoretical development of the earlier paper by James Bradley). |
| 1845 | Christophorus Hendrik Diederik Buijs Ballot, observed the frequency shift of sound waves. ⁶ |
| 1880 | Jacques and Pierre Curie discovered the piezoelectric effect. ⁷ |
| 1916 | Paul Langevin (who had been a doctoral student of Pierre Curie) developed SONAR during the First World War; he filed patents with Constantin Chilowsky in 1916 in France ⁸ and 1917 in the USA ⁹ (stating that 'The relative motion of the obstacle and the observation post may be determined by applying Doppler's method..'). |
| 1929 | Sokolov in Russia proposed using ultrasound to test castings. ¹⁰ He filed a US patent application for his ultrasonic flaw detector (as Sergey Sokoloff) in 1937. ¹¹ |
| 1940 | Floyd Firestone constructed an ultrasonic reflectoscope for industrial use. ¹² He applied for a patent during the Second World War, and published his method afterwards in 1946. ¹³ |
| 1942 | Karl Theo Dussik developed what he called 'hyperphonography', using transmitted US to examine the brain, ^{14,15} he considered but did not pursue ultrasound reflection. |
| 1949 | Wolf-Dieter Keidel scanned the heart with transmitted ultrasound, to estimate its volume (after trying but rejecting the pulse-reflection method). ^{16,17} |
| 1952 | John Wild and John Reid applied echo-ranging to determine the structure of biological soft tissues (including breast). ¹⁸⁻²⁰ Figures include 'A-mode' demonstration. (John Wild started his research after locating to the USA in 1946). |
| 1952 | Douglass Howry & Roderic Bliss produced compound scans of human anatomy, equivalent cumulatively to 2D cross-sections ('Somascopie'), ^{21,22} first results obtained in 1950. |
| 1953 | May: first trial by Hellmuth Hertz and Inge Edler on themselves of ultrasound using machine from Kockum shipyard; first A-mode scan (reflected ultrasound) of heart. |
| 1953 | 29th October, first M-mode scan by Edler and Hertz. Published 1954. ²³ |
| 1955 | Ian Donald (who met John Wild in London in the early 1950 s) starts to investigate reflected ultrasound in the abdomen and then in obstetric practice, like Edler and Hertz starting with a borrowed flaw detector; with engineer Tom Brown, develops 'Diasonograph' which produced compound obstetric scans. ²⁴ |
| 1956 | Shigeo Satomura, ultrasonic Doppler method to measure cardiac motion (with continuous wave). Initial report in Japanese, ²⁵ first publication in English in 1957. ²⁶ |
| 1960 | Tomasz Cieszyński, first intravascular scanning and intracardiac echocardiography reported, using a single-element transducer on a catheter (developed from 1956). ²⁷ |
| 1961 | Edler's thesis published as supplement to Acta Medica Scandinavica. ²⁸ |
| 1962 | Ryozo Omoto obtained 2D intravascular images with a slowly rotating, single-element transducer mounted at a catheter tip. ^{29,30} First publication in English in 1967. ^{31,32} |
| 1963 | First dedicated cardiac ultrasound scanner built by John (Jack) Reid, working with cardiologist Claude Joyner. ³³ |
| 1963 | Olofsson develops an optical mirror system for 2D scanning of the heart, ³⁴ working with Hertz. ³⁵ Further development reported by Arne Åsberg (1967). ³⁶ |
| 1964 | 'Ultrasono-cardio-tomography' reported from Sendai, Japan, for 2D imaging using mechanical sector scanning. ³⁷⁻³⁹ |
| 1967 | Francis McLeod, directional Doppler system. ⁴⁰ |
| 1967 | Jan Somer constructed first electronic phased-array scanner ('Electroscan'). ^{41,42} |
| 1968 | Raymond Gramiak and Pravin Shah, first report of (M-mode) contrast echocardiography. ⁴³ |
| 1968 | Daniel Kalmanson, directional flow measurement by continuous wave Doppler. ⁴⁴ |
| 1969 | Range-gated (pulsed) Doppler ultrasound developed by three groups: in 1969 Peter Wells ⁴⁵ (Bristol) and Paul Peronneau ⁴⁶ (Paris); and then Donald Baker ⁴⁷ (1970). |
| 1969 | Transthoracic (continuous wave) recording of aortic flow by Henry Light. ⁴⁸ |
| 1971 | Nicolaas (Klaas) Bom and Charles Lancée, first real-time 2D (linear array) cardiac scans ('Multiscan'). ^{49,50} |
| 1972 | Bom and colleagues, first catheter-based cylindrical phased-array ultrasonic intravascular/intracardiac transducer. ⁵¹ |
| 1972 | First textbook on echocardiography (Harvey Feigenbaum). ⁵² |
| 1973 | First clinical reports on 2D echo (using the Multiscan) by Frank Kloster ⁵³ and Jos Roelandt, ⁵⁴ with Bom and colleagues. |

Continued

Table 1 Continued

| Year | Scientific contribution |
|------|--|
| 1973 | James Griffith and Walter Henry, mechanical sector scanner for 2D imaging. ^{55,56} |
| 1974 | Frederick Thurstone and Olaf von Ramm, phased-array scanner, ^{57,58} clinical studies reported by Joe Kisslo. ⁵⁹ |
| 1974 | Frank Barber with John Reid, ultrasonic duplex echo-Doppler scanner. ⁶⁰ |
| 1974 | Prototype for 3D cardiac imaging by combining 2D images acquired in different planes (Dekker <i>et al.</i>). ⁶¹ |
| 1974 | Louis Teichholz publishes method for calculating ejection fraction from left ventricular echocardiographic dimensions. ⁶² |
| 1974 | Bjørn Angelsen constructed a pulsed Doppler system for recording aortic blood flow. ⁶³ |
| 1976 | Lee Frazin, single-element transoesophageal echocardiography. ⁶⁴ |
| 1976 | Jarle Holen, first publication using Doppler ultrasound to estimate pressure gradients in heart valve disease (using a modified Gorlin formula). ⁶⁵ |
| 1976 | Cees Ligtoet with N Bom and colleagues in Rotterdam, first portable ('hand-held') echocardiography system ('Minivisor'), ⁶⁶ clinical study published in 1978. ⁶⁷ |
| 1977 | Kohzoh Hisanaga, high-speed rotating cross-sectional transoesophageal scanner. ^{68,69} |
| 1977 | Alf Brubakk with Bjørn Angelsen and Liv Hatle proposed a modified Bernoulli equation for Doppler echocardiography to assess the severity of heart valve disease. ⁷⁰ |
| 1978 | Marco Brandestini, multigated Doppler instrument, combining imaging of flow encoded in colour, superimposed initially on M-mode scans and later on 2D images. ^{71–73} |
| 1978 | Griffith and Henry, combined instrument for imaging and Doppler. ⁷⁴ |
| 1978 | Hatle with Angelsen, quantification of mitral stenosis ⁷⁵ (1978) and aortic stenosis ⁷⁶ (1980) by the modified Bernoulli method. |
| 1979 | First report of exercise stress echocardiography using 2-dimensional imaging by Wann <i>et al.</i> , ⁷⁷ further developed by Morganroth, ⁷⁸ and Maurer, ⁷⁹ in 1981. |
| 1981 | Jacques Souquet, Peter Hanrath, transoesophageal phased-array echocardiography. ^{80,81} |
| 1982 | First textbook on Doppler Echocardiography (Bjørn Angelsen and Liv Hatle). ⁸² |
| 1982 | Chihiro Kasai, ⁸³ with Koroku Namekawa <i>et al.</i> : first commercial real-time colour flow imaging system, using autocorrelation, from Aloka; initial clinical publication by Ryozo Omoto. ⁸⁴ |
| 1982 | Pulsed Doppler recording of mitral flow proposed by Akira Kitabatake for the assessment of left ventricular diastolic function. ⁸⁵ |
| 1983 | First commercial system with colour flow mapping (Aloka). |
| 1989 | Karl Isaaz, proof of concept for regional myocardial velocity measurement. ⁸⁶ |
| 1991 | Olaf von Ramm, first real-time 3D imaging system ('Volumetrics'). ⁸⁷ |
| 1992 | Multiplane transoesophageal echocardiography (Hewlett Packard). ⁸⁸ |
| 1992 | Norman McDicken and George Sutherland, development of colour and pulsed tissue Doppler (with Acuson). ⁸⁹ |
| 1998 | Software for imaging of regional myocardial function based on post-processing of colour tissue Doppler, by Lars-Åke Brodin and Bjørn Olstad. ⁹⁰ |
| 1998 | Myocardial strain rate, developed by Andreas Heimdal <i>et al.</i> ⁹¹ |
| 2004 | Peter Lysyansky <i>et al.</i> , first commercial system for speckle tracking of grey-scale images, leading to measurement of global longitudinal strain. ^{92,93} |
| 2008 | Real-time 'live' 3D transoesophageal imaging (Lissa Sugeng <i>et al.</i>). ⁹⁴ |

Note: the entries in italics concern general or non-cardiac imaging applications.

The dates refer either to the first date of use, if available, or to the earliest publication. The entries relate mostly to engineering and technical developments, rather than to the first reports of new clinical applications or insights. This timeline does not list all early investigators.

built up a composite image.²⁰ Similar techniques were developed by Howry & Bliss, and also reported in 1952.^{21,22} In a later historical account, Edler mentioned that Gohr in 1940 also proposed the use of reflected ultrasound.^{102,103}

Edler experimented with imaging hearts obtained from autopsies, in water baths, so that he could correlate the A-mode echoes with anatomical structures. With colleagues in Lund he explored the use of the technique for possible clinical applications beyond his primary interest in assessing rheumatic mitral valve disease.¹⁰⁴ Early visitors to their laboratory included in 1956 Sven Effert from Düsseldorf (and later Aachen), who pioneered echocardiography in Germany in the late 1950s.^{105–107} In general, however, Edler considered that medical colleagues were reluctant to apply their results.

Development accelerated after Edler showed a scientific film of their work at the congress of the European Society of Cardiology in Rome in 1960, and after he and Hertz had attended a symposium organized by the University of Illinois at Urbana in the USA in 1962. The method was taken up and clinical research pursued in the USA by Harvey Feigenbaum (from 1963)¹⁰⁸ and others. The first paper published in the USA concerning cardiac ultrasound imaging had been by Wild and Reid in 1957, when they reported imaging of excised hearts,¹⁰⁹ and Joyner and Reid published an early study on mitral valve disease in 1963.³³ Edler and Hertz had called their technique 'Ultrasound cardiography' (or UCG, to distinguish it from the ECG) but the name 'Echocardiography' was proposed by

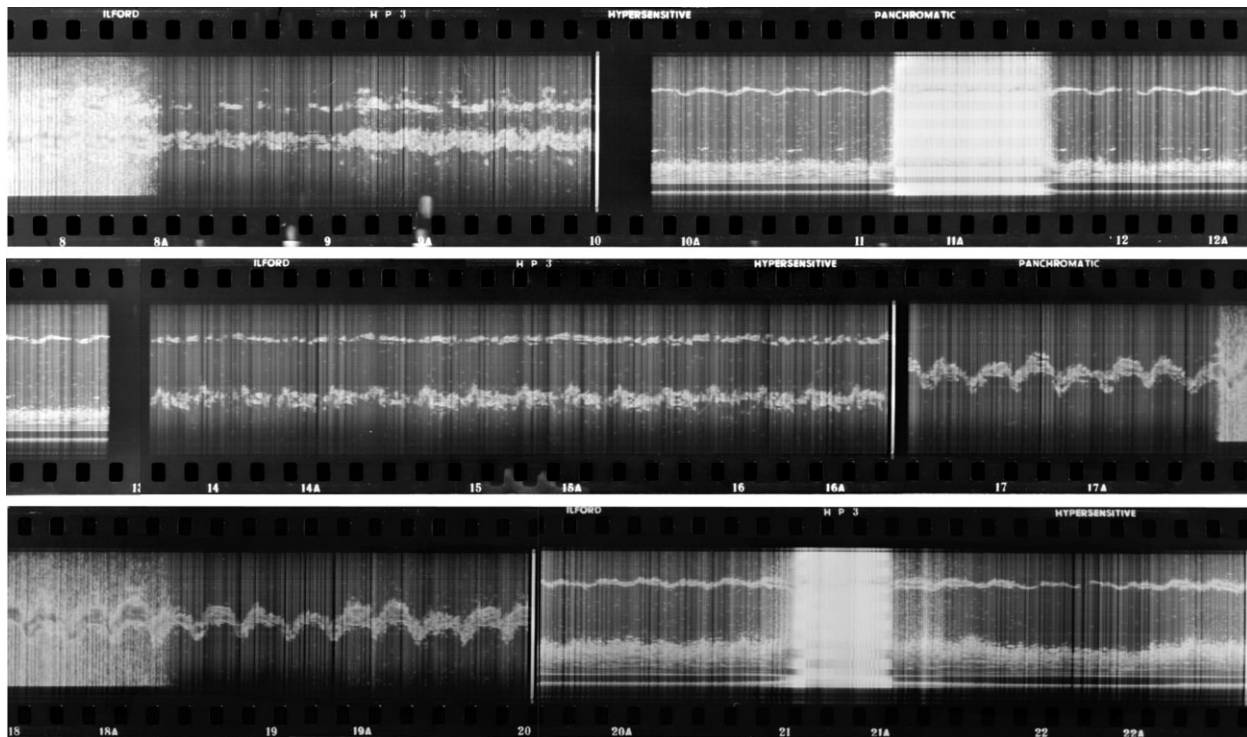


Figure 2 The first photographic film of M-mode echocardiography that was exposed by Edler and Hertz in October 1953, digitally scanned and then displayed as a continuous contact print. (courtesy of Professor Lars Edler)

Segal in 1966 and adopted by the American Institute of Ultrasound in Medicine.^{110,111}

Feigenbaum wrote the first textbook on 'Echocardiography', which was published in 1972.⁵² He and Richard Popp compared echocardiographic measurements with left ventricular volumes estimated by angiography.¹¹² Many other studies were performed in the early 1970s to validate M-mode measurements, including one by Popp that demonstrated the importance of using standard transducer positions.¹¹³

Two-dimensional echocardiography

Hertz had proposed cross-sectional or two-dimensional (2D) echocardiography before suitable technology was available, using a rotating mirror system (Figures 4A and 4B).^{34,114,115} Using this, in 1967 Åsberg reported that it produced sequences of 2D cardiac images which allowed cardiac motion to be followed.³⁶ In addition in the mid-1960s, investigators in Japan developed a prototype mechanical sector scanner that could produce a static 2D silhouette of the heart at any time during the heart cycle.^{37–39,116} That system was used by Teichholz *et al.* in 1974 to compare echocardiographic 2D images with biplane left ventriculography, to estimate volumes and validate their method of estimating ejection fraction from end-diastolic and end-systolic dimensions,⁶² while also recognizing its limitations.¹¹⁷

The first electronic phased-array scanner was constructed by Jan Somer in 1968,^{41,42} and other new transducers were developed in several centres during the early 1970s.¹¹⁸ A linear array was made at the Thoraxcentre in Rotterdam in 1971 by Nicolaas (Klaas) Bom and Charles Lancée^{49,50} and used in initial clinical studies by Jos Roelandt and Frank Kloster^{53,54} (Figure 4C). A mechanical sector

scanner was produced by Jim Griffith and Walter Henry,^{55,56} and a prototype phased-array scanner was built by Thurstone and Von Ramm and evaluated clinically by Joe Kisslo.^{57–59} Another mechanical sector scanner was developed around the same time, initially from a modified electric toothbrush, by Eggleton with Feigenbaum.^{120,108}

These scanners were employed in the early 1970s to identify regional wall motion abnormalities during spontaneous and induced myocardial ischaemia and after myocardial infarction.¹²¹ Inducible ischaemia was diagnosed using M-mode echocardiography by several investigators during the 1970s and then exercise stress echocardiography using cross-sectional imaging was reported first in 1979.⁷⁷ Others developed the technique using wider sector angles, in 1981.^{78,79} Pharmacological stress echocardiography using dipyridamole was proposed by Eugenio Picano and Alessandro Distante in 1985¹²² and stress echocardiography using dobutamine by Luc Piérard and colleagues in 1986.¹²³

Three-dimensional echocardiography

The goal of three-dimensional (3D) imaging of the heart had been considered for a long time before progress in technology and computing could make it a realistic prospect. For example, in 1974 Dekker *et al.* registered the position of a probe attached to a mechanical arm, to reconstruct a 3D image after acquiring multiple 2D cross-sections.⁶¹ Others located the probe position and orientation with spark gap technology, or else they rotated the imaging plane mechanically from a stable probe position. All these original systems required external or internal reference systems to determine where the transducer was positioned in 3D space relative to the heart. Acquisition needed to be gated

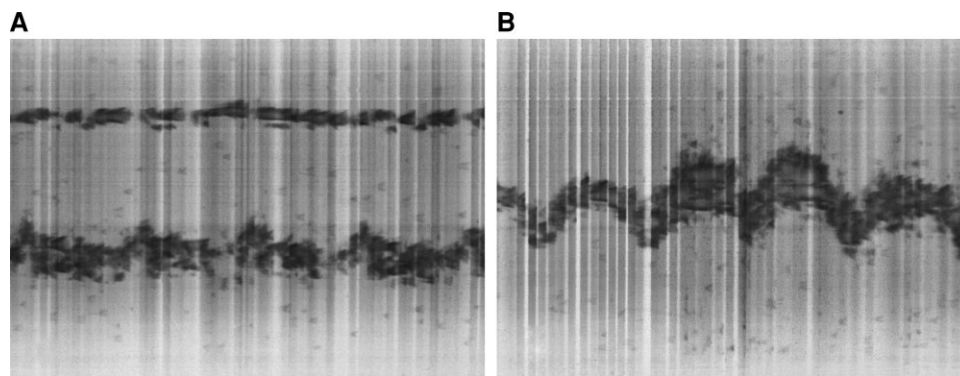


Figure 3 (A) frame 15; and (B) frame 19A; selected from the M-mode echocardiographic film of the heart (shown in Figure 1).

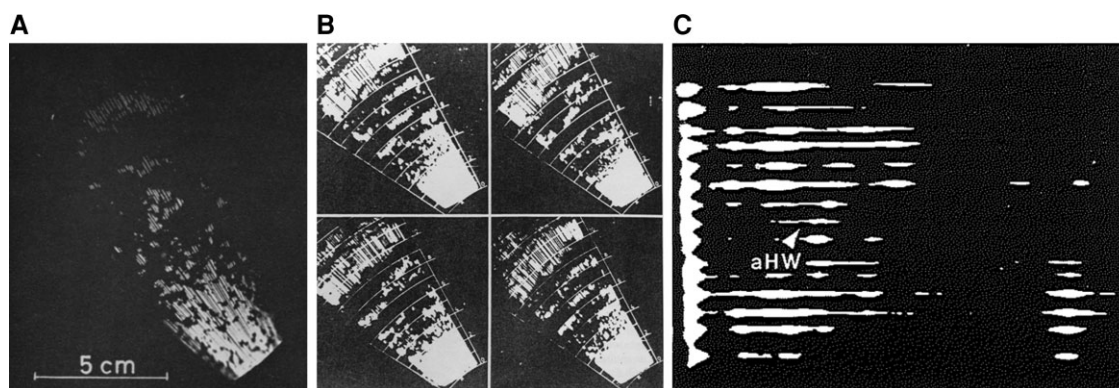


Figure 4 Early 2-dimensional images of the heart and mitral valve, from (A) Hertz 1964¹¹⁴ and (B) Hertz 1967,¹¹⁵ both obtained with a mirror system and recorded on 16 mm film at 7 frames per second; and (C) from Roelandt (1980; page 33)¹¹⁹ recorded about 1971 and described as 'Stop-frame from the first two-dimensional ultrasonic image obtained from a patient with severe pericardial effusion; aHW = anterior heart wall.' In this display, the transducer is along the left side of the image, and the echo-free space to the left of the arrow was interpreted as pericardial fluid in front of the heart.

to the ECG, and it could take several minutes to complete an image data set encompassing the entire heart.¹²⁴

The first system for true 3D echocardiographic imaging was developed by Von Ramm *et al.* from Duke University, North Carolina, in the early 1990s, using a sparse array.⁸⁷ Their machine was very large, and despite parallel processing its frame rate was about 8/s. The first commercially available real-time 3D system using phased-array technology was released by Volumetrics in 1996. Volume rates remained slow and to create an image of the entire heart required stitching together several ECG-synchronized sub-volumes, acquired with the transducer held still while the patient held her or his breath.

Rapid advances in micro-electronics and the development of broadband (1–5 MHz) monocrystal matrix array transducers led to the development of small transducers for 3D imaging with superior sensitivity and good spatial and temporal resolution, reported clinically by Sugeng with Roberto Lang in 2003.¹²⁵ Dynamic real-time transthoracic 3D imaging at high-frame rates became possible from the early 2000s, using a matrix array with 3000 elements. Colour flow images are superimposed onto the 3D tissue display

in real time. More recently, post-processing techniques developed by the cartoon film industry have been applied to produce real-time 'photo-realistic' images. These can be illuminated by a (hypothetical) moveable light source to highlight various anatomical features, and structures can be displayed as semi-transparent.¹²⁶

Transoesophageal echocardiography

In 1972 Olson and Shelton¹²⁷ monitored changes in the diameter of the aortic arch in dogs using an ultrasound crystal attached to an oesophageal probe, and in 1974 Duck *et al.*¹²⁸ reported their initial clinical experience of using a new transoesophageal ultrasonic probe to record aortic blood flow. The possibility of M-mode imaging from the oesophagus was demonstrated by Frazin *et al.* in 1976, using a single crystal that the patient had to swallow.⁶⁴ A few years later, in New York, Masayuki Matsumoto *et al.* monitored left ventricular function during cardiac surgery by transoesophageal M-mode echocardiography, using a home-made system.^{129,130} Matsumoto then received a scholarship to

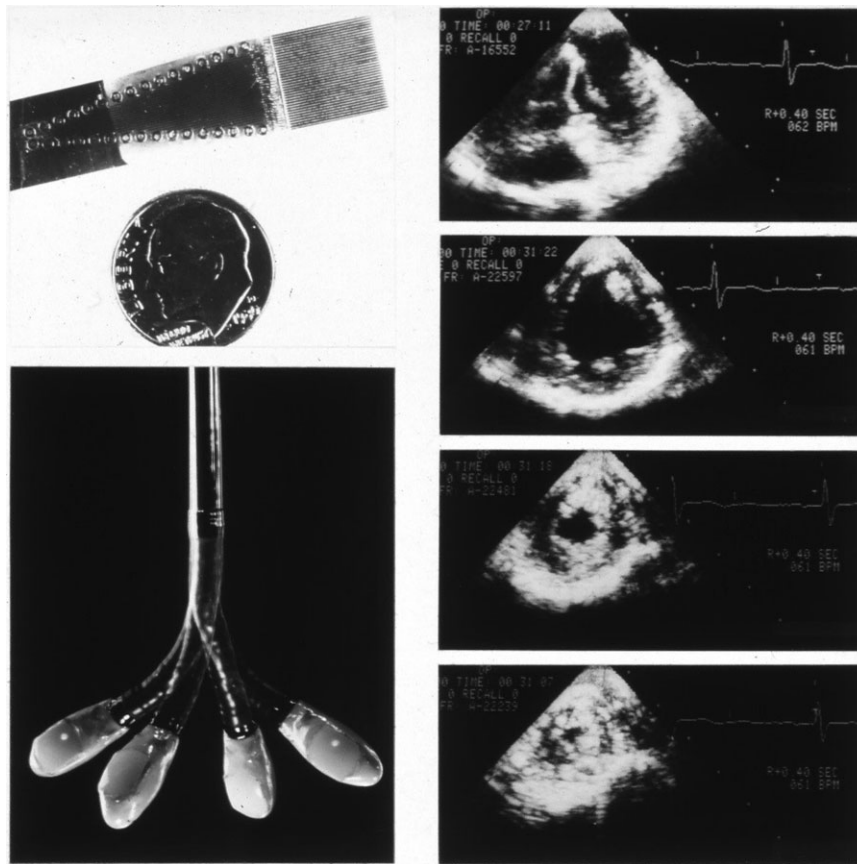


Figure 5 Early monoplane transoesophageal probe and images (courtesy of Professor Peter Hanrath).

spend 1 year at the Cardiology Department of the University Hospital Hamburg Eppendorf, where Peter Hanrath was working.

Although the quality of the images was good, the disadvantage of the M-mode approach was that the transducer position could not be controlled by the physician. To solve this problem, Hanrath contacted Olympus (at that time the world's leading manufacturer of flexible endoscopes) in Hamburg, and they succeeded to install a commercially available single-element transducer into the shaft of a flexible endoscope from which the fibreoptics had been removed. Their results were published in 1981¹³¹ and 1982.¹³²

Working independently in Japan, in 1977 Hisanaga *et al.* had developed a rotating mechanical scanner for cross-sectional imaging of the heart from a transoesophageal approach, and also a transoesophageal-pulsed Doppler probe.^{68,69,133} After the initial M-mode studies in Hamburg, Hanrath searched for an ultrasound company that was able to miniaturize a phased-array transducer to such an extent that it could be built into an endoscope. In 1981, he met the engineer Jacques Souquet at Advanced Technology Laboratories (ATL) in Seattle, and about 6 months later, they delivered such a transducer consisting of 36 crystals, which was then incorporated into an endoscope by Olympus. The resulting first clinical studies of monoplane transoesophageal imaging (Figure 5) were published in 1982.^{80,81} This was followed soon afterwards by their development of a biplane transducer.¹³⁴ Further developments were also taking place in Japan.¹³⁵

Souquet and Hanrath had the idea of a rotatable phased-array transducer in an endoscope, which at that time represented a constructional challenge. They submitted a joint grant application to the German Ministry of Research and Technology in 1982, but it was rejected with the argument that German tax money could not be spent to support American industry. In 1989, Hanrath met engineers from Hewlett Packard in Boston, who felt able and willing to develop a rotatable multiplane probe—but first, legal action was needed to revoke a patent that had in the meantime been claimed by Souquet. Thereafter a prototype multiplanar (or 'Omniplane') probe was delivered to Hanrath (by then in Aachen) from Hewlett Packard in 1991, and their initial clinical experience was published soon afterwards.⁸⁸ In the same year (1992), the Rotterdam group published their first clinical results with another multiplane transoesophageal probe, that they had also developed with Hewlett Packard, called the 'Varioplane'.¹³⁶

A paediatric single-plane 5.0 MHz transoesophageal probe was developed by the Oldelft company in 1989, working with engineers at the Thoraxcentre in Rotterdam.¹³⁷ A series of correlative clinical reports confirmed the additional clinical value of transoesophageal imaging in congenital heart disease.^{138,139} This was followed by the development of biplane and then steered matrix multiplane paediatric transoesophageal probes. In adults, the first clinical report of real-time 3D transoesophageal imaging using a matrix transducer was published in 2008.⁹⁴ Now, high-quality 3D transoesophageal images

can be fused in real-time with fluoroscopic images, to guide cardiac structural interventions by visualising catheters, contrast, tissue structures and blood flow, all spatially synchronized and superimposed.

Doppler ultrasound

There is a long history of the development of ultrasonic methods for recording and displaying blood flow and measuring its velocity in order to derive estimates of intracardiac pressure gradients. Although we apply the name of Christian Doppler, his original presentation in Prague in 1842⁵ was a theoretical development of an earlier study on the motion of distant stars by James Bradley,¹ without any new or original experimental observations.¹⁴⁰ A change in the frequency of sound waves as they are transmitted from a moving target or towards a travelling observer, was first demonstrated a few years later in the Netherlands by Christophorus Buijs Ballot who arranged for a train to travel past stationary musicians playing a constant note on a horn.⁶ He had been sceptical and was trying to disprove Doppler's hypothesis but in fact confirmed it.^{140,141}

Cardiovascular imaging applications now estimate velocities using autocorrelation to assess phase shift,¹⁴² rather than by calculating the Doppler shift in frequency or wavelength, but the eponymous attribution persists. Doppler echocardiography was developed during the 1950s in Japan by Shigeo Satomura, whose first investigations from 1952 were to measure heart motion rather than blood flow.^{25,27,143} In 1956 Yoshida with Satomura reported that Doppler ultrasound signals could be obtained from the human heart due to the motion of heart valves and blood flow.^{144,145} Other Japanese investigators correlated the observed phase shift with the velocity of the target, and related the amplitude of the signal to the number of red cells as reflectors.^{146,147}

In 1966 and independently, both Kato in Japan and Robert Rushmer in the USA reported that they had developed directional blood flow meters.^{148,149} A prototype apparatus for the continuous assessment of flow was also reported by Francis McLeod in 1967,⁴⁰ and another by Daniel Kalmanson in Paris in 1968 with the engineer Gérard Toutain.^{44,150} These machines recorded directional Doppler signals, meaning that it was possible to distinguish blood flow towards or away from the transducer, for example in the jugular vein of patients with right heart disease.¹⁵¹ About the same time, Light was using Doppler from a suprasternal approach to record aortic blood flow.⁴⁸ More significantly, range-gated or pulsed Doppler was being developed independently by three groups—Peter Wells in Bristol⁴⁵ and Paul Peronneau in Paris,⁴⁶ both reported in 1969, and Donald Baker in Seattle, published in 1970.⁴⁷ Thereafter the key advance was the development of a duplex scanner by Frank Barber in 1974, so that images and flow could be recorded using a single ultrasound system.⁶⁰ Griffith and Henry published details of another combined system in 1978.⁷⁴ Thus far, blood flow in the heart and vessels could be assessed only semi-quantitatively.¹⁵²

The first person to demonstrate (in 1976) that Doppler measurements of intracardiac flow velocities could be used to estimate pressure gradients was Jarle Holen, who had worked as an aerodynamics engineer at the Boeing factory in Seattle before studying medicine. He went from Rochester in New York state, where he had worked in the radiology department with Gramiak, to Oslo to undertake his

doctoral research. At first, the university department did not have an echocardiographic machine, and so a foetal monitor was modified to obtain Doppler signals. He then measured the velocity of flow across the mitral valve in patients with stenosis and calculated the gradients by an application of the Gorlin formula; the results correlated well with invasive measurements.⁶⁵ Some years later, in an *in vitro* experiment, he confirmed the accuracy of the new methods against pressures that were measured directly.¹⁵³

Independently, and from about 1974, Bjørn Angelsen at the Norwegian Technical University in Trondheim developed a combined pulsed and continuous wave Doppler system^{63,154} and proposed that gradients could be estimated using a simplification of the Bernoulli equation.⁷⁰ Liv Hatle was provided with a system built by Kjell Kristoffersen from Angelsen's group, and their first clinical study was presented by Brubakk at the European Congress of Cardiology in Amsterdam in 1976; it was met with some disbelief but Holen's paper came out shortly afterwards, confirming the results. Seminal publications followed from 1978 on the quantification of mitral stenosis,⁷⁵ aortic stenosis,⁷⁶ tricuspid regurgitation,¹⁵⁵ and right ventricular systolic pressure.¹⁵⁶ Investigators in Japan proposed that mitral and tricuspid flow velocities could be used to estimate left and right ventricular diastolic filling and function.^{85,157}

Colour flow mapping became possible after the development of a multigate pulsed Doppler system, first reported in the late 1970s by the engineer Marco Brandestini from Don Baker's group at the University of Washington in Seattle.^{71,72} His initial prototype superimposed colour flow on M-mode echocardiography, but it was soon followed by colour flow on a 2D display.⁷³ The first commercially available system was developed at the Aloka company in Japan, by the engineer Chihiro Kasai *et al.*, from 1982 and in collaboration with Ryozo Omoto who reported their initial clinical experience in 1984.^{83,84,158} In the same year, Rolf Jenni used a Diasonics multigate Doppler system to reveal varying flow patterns across the human aorta.¹⁵⁹

Myocardial velocity imaging

The proof of concept for recording a Doppler signal from the myocardium came from Isaaz in 1989,⁸⁶ after earlier attempts with related but different techniques by Yoshida¹⁴⁵ and Kostis.¹⁶⁰ The key advance was the development of a method by McDicken and Sutherland which adapted the colour Doppler algorithms for flow in a standard echocardiographic machine preferentially to display the high-amplitude, low-velocity signals from the myocardium.^{89,161} This was soon integrated into commercially available imaging systems by the Acuson company (as 'Doppler myocardial imaging') during the 1990s. A method was proposed for the post-processing of colour Doppler information to derive maps of other features of regional myocardial function,⁹⁰ and then methods were demonstrated for measuring local deformation of the myocardium as strain rate or strain.⁹¹ Doppler myocardial Imaging was introduced into paediatric cardiology from 2002.^{162,163}

Tracking the speckle pattern of ultrasound reflections, to obtain angle-independent images of blood flow and tissue motion, was suggested in 1991 but not feasible for implementation at that time because of insufficient computing capacity.¹⁶⁴ The first practical solution that became commercially available was developed by the General Electric company in Israel by the engineer Peter Lysyansky with clinical colleagues, in 2004.^{92,93} Although now widely applied,

the technique has insufficient temporal resolution to fully resolve regional myocardial strain rates.

Echocardiography in congenital heart disease

Following the introduction of low frequency (2.5 MHz) M-mode echocardiography into adult cardiology in the late 1960s, it was used at higher imaging frequencies (5.0 and 7.5 MHz) to study cardiac structure and function in children with congenital or acquired heart lesions. Whereas the anatomy of the cardiac chambers and vascular connections in most adults is predictable, the geometry of complex congenital malformations posed a great challenge for the M-mode technique. Despite this caveat, early diagnostic studies were reported in 1967¹⁶⁵ and 1971.¹⁶⁶ At that time the morphology of complex congenital cardiac lesions was poorly understood, but certain patterns on M-mode traces were described which could suggest underlying structural malformations such as transposition of the great arteries.¹⁶⁷ Nonetheless, the limitations of the M-mode technique for describing spatially complex lesions rapidly became evident.




Figure 6 Left: 32-element phased-array 5.6 MHz intravascular ultrasound imaging (IVUS) of a basket (1972). Right: Single element rotating 30 MHz IVUS image of an artery containing atherosclerotic plaque (asterisk, and arrowed) (1992). From Bom N, Lancée CT, Rijsterborgh H, ten Hoff H, Roelandt JRTC. From idea to clinical application. *in* Intravascular Ultrasound, Roelandt, Gussenhoven, Bom Eds. Kluwer Academic Publishers, 1993.

Pioneering work on cardiac morphology by the Van Praaghs in the 1960s¹⁶⁸ and the Anderson group in the 1970s¹⁶⁹ was crucial for understanding and defining complex congenital cardiac malformations. By the early 1990s a series of studies had correlated echocardiographic findings with morphology, aided by the introduction of 5.0 and 7.5 MHz mechanical and phased-array 2-D imaging systems and by the development and integration of Doppler ultrasound modalities.^{170,171} Together, these led to the acceptance of cardiac ultrasound as a comprehensive and accurate modality to diagnose complex congenital heart disease.¹⁷²

Paediatric 2D sector scanning had been developed separately and in parallel with pulsed and continuous wave Doppler modalities, during the late 1970s. At first, the most successful systems were the mechanical rotational sector scanners developed by ATL, that imaged at 3.5 to 7.0 MHz. In parallel, Bjørn Angelsen and Kjell Kristoffersen^{63,154} developed their non-imaging pulsed and continuous wave Doppler system (which they called a pulsed-echo Doppler flowmeter, or PEDOF).^{63,154} It was tested clinically by Hatle and colleagues in Trondheim in 1976, and applied for the first non-invasive haemodynamic study of ventricular septal defects.¹⁷³ In 1982, the large Irex 111B duplex scanner was introduced, which for the first time combined 2D sector scanning with pulsed and continuous wave Doppler modalities.

Clinically effective colour flow mapping (CFM) was integrated into paediatric scanners by the mid 1980s, but again by two differing approaches. Vingmed (1986) and ATL based their CFM on rotational mechanical sector scanners, while Aloka (1987) introduced high-frequency phased-array scanners that imaged at 5.0 and 7.5 MHz. By the early 1990s, improvements in transducer ceramic materials allowed more crystals to be mounted, to produce an electronically steered matrix 2D array. Allied with new digital monitors and software-driven digital ultrasound machines, data could be acquired at high transducer frequency and displayed with high temporal and spatial resolution. These developments, combined with commercial considerations, led to the demise of mechanical sector scanners. Improvements in paediatric matrix probes, probe bus data transfer and machine processing speed, and digital displays, enabled real-time 3D transthoracic and transoesophageal echocardiography to be introduced to paediatric practice from the mid 2000s.^{174,175}

Foetal echocardiography

Ultrasound examination of the foetal heart was first described in 1966, using M-mode echocardiography,^{176,177} but it did not come of age until full integrated paediatric 2D ultrasound scanners became available from the late 1970s. Starting in 1980, Lindsey Allan produced a series of innovative reports on the intrauterine diagnosis of congenital heart disease, using both mechanical and phased-array sector scanners.¹⁷⁸ Once initial safety fears for the foetus had been addressed, this led to the widespread acceptance of trans-abdominal and trans-vaginal foetal echocardiography. New ultrasound modalities have been incorporated, including the assessment of intracardiac flows, myocardial deformation, and 3D imaging. Foetal echocardiography has become established as an essential discipline shared with obstetricians.

Intravascular ultrasound

In 1956, Tomasz Cieszyński built an ultrasonic catheter with the goal of applying it for intracardiac investigations, but his initial article reported experimental studies only (*in vitro* and in animals).²⁷ Dean Franklin's group at the University of Washington, Seattle, described an invasive ultrasound flowmeter in 1959, but it was clamped around the aorta rather than being intravascular and it was also assessed in animal experiments.¹⁷⁹ More studies were conducted by Ryozo Omoto *et al.*^{29–31,180} in Japan, while independently in Rotterdam in the early 1970s Bom *et al.*⁵¹ developed their first intravascular phased-array transducer, with 32 elements (Figure 6). Kalmanson recorded intracardiac signals from the right and left heart in 1979 and 1980, using directional Doppler.¹⁵²

After initial enthusiasm, interest in intravascular ultrasound (IVUS) was stalled until the mid 1980s when clinical impetus was provided by the development of percutaneous coronary interventions and by recognition that the X-ray shadow image of the lumen provided too limited information to develop balloon angioplasty, atherectomy, spark erosion, and other techniques safely. For that reason, IVUS was developed further.¹⁸¹ Bom *et al.* made a combined IVUS/spark erosion catheter and demonstrated its feasibility *in vitro* in 1988.¹⁸² Later, it was developed as a standalone IVUS system. In 1989 Paul Yock introduced a clinical rotating IVUS system, initially for imaging peripheral arteries and then for intracoronary imaging.¹⁸³ Its clinical application was confirmed for evaluating atherectomy and laser ablation.¹⁸⁴ Tobis *et al.* evaluated balloon angioplasty *in vitro*, using IVUS.¹⁸⁵ In addition in 1989, Hodgson introduced a clinical intracoronary phased-array imaging system, based on the 1972 patent from Bom and Lancée.¹⁸⁶

Backscatter analysis¹⁸⁷ and lessons learned from the analysis of images obtained *in vitro*¹⁸⁸ have played a major role in aiding the interpretation of IVUS images. Li *et al.*¹⁸⁹ developed semi-automatic lumen detection that was applied to assess the long-term effects of several stenting strategies and to compare the efficacy of statins. Several strategies for tissue identification have emerged, but none has yet been implemented into routine clinical practice. More recently, several 'sound and light combination' catheters have been developed, including an IVUS NIRS catheter (near-infrared spectroscopy) by InfraredX in collaboration with van der Steen and Serruys.¹⁹⁰

Conclusions

Although we have tried to locate and cite as many 'first' publications as possible, any retrospective exercise such as this is fraught with risks of inappropriate attributions or errors of omission. To minimize these, we have consulted the original publications and reviewed their reference lists, and when possible we have confirmed details with senior colleagues. We also reviewed historical accounts that have been published by principal investigators, which have been cited so that they can be consulted for more comprehensive details. Parallel developments in applications of ultrasound in other clinical fields have been reviewed recently by the European Federation of Societies of Ultrasound in Medicine and Biology,¹⁹¹ and other first-hand accounts of specific aspects of the history of echocardiography are available.^{192–194}

This endeavour has reinforced the view that it is often very difficult to establish scientific precedence. Clinical advances in echocardiographic imaging have been absolutely dependent on advances in technology, and when the intellectual climate was ripe and practical tools were available then many engineers and clinicians tackled similar challenges. There have been frequent occasions in the early history of ultrasound imaging when investigators were trying to solve the same problems but communication was less easy than now and publications were less accessible, and so they worked independently. As we have summarized, many individuals who are most prominently associated with particular developments have not been the first in their field. If that was part of the reasoning behind decisions not to award the Nobel prize for medicine to Edler and Hertz, then it may become apparent once the committee's deliberations are made available for review by historians after the usual 50-year embargo.

A second and obvious conclusion is that major advances have come from close collaborations between engineers and clinical scientists, so there is a need to ensure that such environments are developed and appropriately resourced. Although some researchers may be strongly motivated by competition, and careers can now be determined by metrics of academic productivity, in our opinion the most successful innovations have occurred when colleagues from different disciplines and different centres have been working together, preferably with an open and generous exchange of ideas. From an historical perspective what may be most interesting to current researchers is not what was done or by whom, but how the ideas and hypotheses were developed and where the original concepts came from—which is less often documented for posterity.

We have concentrated on describing the history of technological advances rather than clinical applications (*Graphical Abstract*), because that would have been an almost impossible undertaking. For practical reasons also, we have only briefly summarized the first steps in IVUS, which evolved from cardiac imaging but has now developed into an interventional subspecialty, and we have not reviewed vascular ultrasound or the development of hand-held systems. Echocardiography is still operator-dependent but that will lessen as machine learning methods are developed and implemented for acquiring, optimising, identifying and measuring images more accurately and reproducibly. Faster data transfer and processing would enhance the quality of 3D imaging and flow acquisition to such an extent that it could become standard practice, with all 2D, deformation and flow images and measurements being derived during post-processing, together with automated measurement of most parameters. While advances in software and artificial intelligence may transform clinical practice, it is too soon to include them in an historical overview. Similarly in our opinion the clinical utilities of recent technological developments such as high-frame-rate or ultrafast imaging, tissue characterisation by elastography, and the imaging of fluid dynamics, are still uncertain.

For the future, it could be particularly useful to establish some mechanism for expert clinical practitioners to reach a consensus on genuine unmet needs, since that has always been difficult and prone to individuals' expertise, interests and biases. As Henry Light wrote in 1992, what will be used may involve 'surrendering the ultimately desirable for the robustly measurable and eminently useful',¹⁹⁵ which implies a need for more epidemiological and outcomes-based evaluations. And hopefully, dialogue between clinicians and engineers

may overcome the problem identified by Hertz in 1973 that ‘.. different physicians had very different opinions on the relative importance of possible additional features and no clear answer could be given to the designing engineers in industry’.⁹⁶

Acknowledgements

We thank Professor Christoph Dietrich, European Federation of Societies for Ultrasound in Medicine and Biology (EFSUMB), for proposing this historical summary, and we acknowledge our gratitude to the late Professor Jos RTC Roelandt for stimulating our interest in the history of cardiovascular ultrasound. We thank Professors Liv Hatle, Peter Hanrath, and Alessandro Distanto for their helpful suggestions concerning historical details; Professors Nicolaas Bom, Alan Pearlman, and Randolph Martin for reviewing the manuscript; Dr Sayuri Yoshioka, The Cardiovascular Institute Hospital, Tokyo, and Professor Yoshifumi Saijo, Graduate School of Biomedical Engineering, Tohoku University, Sendai, for their support in reviewing Japanese publications; and Professor Piotr Szymański, Clinical Cardiology Centre, Central Clinical Hospital MSWiA, Warsaw, for checking the Polish citation.

Funding

No external funding.

Conflict of interest: None declared.

References

- Bradley J. An account of a new discovered motion of the fix'd stars. *Philos Trans R Soc Lond* 1727;**35**:637–660.
- Bernoulli D. *Hydrodynamica, sive de viribus et motibus fluidorum commentarii*. Basel: Johannis Reinholdi Dulseckeri; 1738.
- Euler L. Principes généraux de l'état d'équilibre d'un fluide. *Mémoires de l'académie des sciences de Berlin (Royal Prussian Academy of Sciences)* 1757;**11**:217–273.
- Euler L. Principia pro motu sanguinis per arterias determinando, 1775. In: Fuss PH and Fuss N (eds.), *Opera posthuma mathematica et physica anno 1844 detecta*: Euler Archive Eneström Number 855; 1862. p814–823.
- Doppler C. Über das farbige Licht der Dopplersterne und einiger anderen Gestirne des Himmels. *Gesellschaft der Wissenschaften* 1843;**2**:465–482.
- Buijs Ballot CHD. Akustische Versuche auf der Niederländischen Eisenbahn, nebst gelegentlichen Bemerkungen zur Theorie des Hrn. Prof. Doppler. *Poggendorff's Annalen der Physik und Chemie* 1845;**66**:321–351.
- Curie J, Curie P. Développement par pression de l'électricité polaire dans les cristaux hémihédres à faces inclinées. *Bull. Soc. Minéral* 1880;**3**:90–93. Summary published in *Comptes rendus hebdomadaires des séances de l'Académie des sciences*. 1880;91:294–295.
- Chilowsky C, Langevin P. Procédés et appareils pour la production de signaux sous-marins dirigés et pour la localisation à distance d'obstacles sous-marins. République Française, Office National de la Propriété Industrielle, Brevet D'Invention (Patent) 502913. Application filed 1916, awarded 29 May 1920.
- Chilowsky C, Langevin P. Production of submarine signals and the location of submarine objects. US Patent 1,471,547: Filed 1917, patented October 23, 1923.
- Sokoloff S. Ultrasonic oscillations and their application. *Techn Physics (USSR)* 1935;**2**:522–544.
- Sokoloff S. Means for indicating flaws in materials. US Patent 2,164,125: Filed 1937; patented June 27, 1939.
- Firestone FA. Flaw detecting device and measuring instrument. US Patent 2,280,226: Filed 1940; patented April 21, 1942.
- Firestone FA. The supersonic reflectoscope, an instrument for inspecting the interior of solid parts by means of sound waves. *J Acoust Soc America* 1946;**17**:287–299.
- Dussik KT. Über die Möglichkeit hochfrequente mechanische Schwingungen als diagnostisches Hilfsmittel zu verwenden. *Zeitschrift für die gesamte Neurologie und Psychiatrie* 1942;**174**:153–168.
- Dussik KT. Ultraschalldiagnostik, insbesondere bei Gehirnkrankungen, mittels Hyperphonographie. *Z. Phys. Therapie (Österr)* 1948;**1**:140–145.
- Keidel WD. Über eine neue methode zur registrierung der volumenänderung des Herzens am Menschen. Der Ultraschall in der Medizin, Kongressbericht der Erlangen Ultraschall-Tagung. S. *Hirzel Verlag Zürich* 1949:p68–70.
- Keidel WD. Über eine neue Methode zur Registrierung der Volumänderungen des Herzens am Menschen. *Zeitschr Kreislaufforschung* 1950;**39**:257–271.
- Wild JJ. The use of ultrasonic pulses for the measurement of biologic tissues and the detection of tissue density changes. *Surgery* 1950;**27**:183–188.
- Wild JJ, Neal D. Use of high-frequency ultrasonic waves for detecting changes of texture in living tissues. *Lancet* 1951;**1**:655–657.
- Wild JJ, Reid JM. Application of echo-ranging techniques to the determination of structure of biological tissues. *Science* 1952;**115**:226–230.
- Howry DH, Bliss WR. Ultrasonic visualization of soft tissue structures of the body. *J Lab Clin Med* 1952;**40**:579–592.
- Howry DH. The ultrasonic visualization of soft tissue structures and disease processes. *J Lab Clin Med* 1952;**40**:812–813.
- Edler I, Hertz CH. The use of ultrasonic reflectoscope for the continuous recording of the movements of heart walls. *Kungliga Fysiografiska Sällskapets i Lund Föreläsningar* 1954;**24**:40–58.
- Donald I, MacVicar J, Brown TG. Investigation of abdominal masses by pulsed ultrasound. *Lancet* 1958;**1**:1188–1195.
- Satomura S, Matsubara S, Yoshioka M. A new method of mechanical vibration measurement and its application. *Mem Inst Sci Ind Res Osaka Univ [in Japanese]* 1956;**13**:125–133.
- Satomura S. Ultrasonic Doppler method for the inspection of cardiac functions. *J Acoust Soc America* 1957;**29**:1181–1185.
- Cieszyński T. Intrakardialna metoda badania budowy serca za pomocą ultradźwięków. [Intracardiac method for the investigation of structure of the heart with the aid of ultrasonics] *Archiwum Immunologii i Terapii Doświadczalnej* 1960;**8**:551–557.
- Edler I, Gustafson A, Karlefors T, Christensson B. Ultrasoundcardiography. *Acta Medica Scandinavica* 1961;**170**(Suppl):1–123.
- Omoto R, Atsumi K, Suma K, Toyoda T, Sakurai Y, Muroi T, et al. Ultrasonic intravenous sonde (The 2nd report). *Med Ultrason (Jpn)* 1963;**1**:11.
- Omoto R, Atsumi K, Suma K, Muroi T, Sugiura M, Saegusa M, et al. Ultrasonic intravenous sonde III. In *Proceedings of the 4th Scientific meeting of Japan Society of ultrasonics in Medicine*; 1964;49–50 (in Japanese).
- Omoto R. Intracardiac scanning of the heart with the aid of ultrasonic intravenous probe. *Jpn Heart J* 1967;**8**:569–581.
- Omoto R. Ultrasonic tomography of the heart: an intracardiac scan method. *Ultrasonics* 1967;**5**:80–83.
- Joyner CR, Reid JM, Bond JP. Reflected ultrasound in the assessment of mitral valve disease. *Circulation* 1963;**27**:503–511.
- Olofsson S. An ultrasonic mirror system. *Acustica* 1963;**13**:361–367.
- Hertz CH, Olofsson S. A mirror system for ultrasonic visualization of soft tissues. In: Kelly E (ed.), *Symposium on Ultrasound in Biology and Medicine. Ultrasonic Energy*. Chicago: University of Illinois Press; 1962, 1965. p322.
- Åsberg A. Ultrasonic cinematography of the living heart. *Ultrasonics* 1967;**5**:113–117.
- Ebina T, Tanaka M, Kikuchi Y, Uchida R, Kosaka S. Ultrasono-cardio-tomography. *Proc Jpn Soc Ultrason Med* 1964:49–50.
- Ebina T, Kikuchi Y, Eng D, Oka S, Tanaka M, Kosaka S, et al. The diagnostic application of ultrasound to the diseases in mediastinal organs. Ultrasono-tomography for the heart and great vessels (the first report). *Sci Rep Res Inst Tohoku Univ Med* 1965;**12**:58–74.
- Ebina T, Oka S, Tanaka M, Kosaka S, Terasawa Y. The ultrasono-tomography for the heart and great vessels in living human subjects by means of the ultrasonic reflection technique. *Jpn Heart J* 1967;**8**:331–353.
- McLeod FD. Directional Doppler demodulation (abstract). *Proc 20th Ann Conf Med Biol Engin* 1967;**27**:1.
- Somer JC. Instantaneous and continuous pictures obtained by a new two-dimensional scan technique with a stationary transducer. In: Kazner E, et al (editors), *Proceedings in Echo-Encephalography, International Symposium on Echo-Encephalography*, Erlangen; 1967:234–238.
- Somer JC. Electronic sector scanning for ultrasonic diagnosis. *Ultrasonics* 1968;**6**:153–159.
- Gramiak R, Shah PM. Echocardiography of the aortic root. *Invest Radiol* 1968;**3**:356–366.
- Kalmanson D, Veyrat C, Chiche P. Le retour veineux droit enregistré par voie transcutanée au niveau de la veine jugulaire interne chez le sujet normal. Interpretation physiologique des courbes. *Bulletin et Mémoires de la Société Médicale des Hôpitaux de Paris* 1968;**119**:873.
- Wells PN. A range-gated ultrasonic Doppler system. *Med Biol Eng* 1969;**7**:641–652.
- Peronneau P, Deloche A, Bui-Mong-Hung, Hinglais J. Débitmétrie ultrasonore – Développements et applications expérimentales. *Eur Surg Res* 1969;**1**:147–156.
- Baker DW. Pulsed ultrasonic Doppler blood-flow sensing. *IEEE Trans Sonics Ultrason* 1970;**17**:170–185.
- Light LH. Non-injurious ultrasonic technique for observing flow in the human aorta. *Nature* 1969;**224**:1119–1121.

49. Bom N, Lancée CT, Honkoop J, Hugenholtz PC. Ultrasonic viewer for cross-sectional analyses of moving cardiac structures. *Biomed Eng* 1971;**6**:500–503,508.
50. Bom N, Lancée CT, van Zwieten G, Kloster FE, Roelandt J. Multiscan Echocardiography I. Technical description. *Circulation* 1973;**48**:1066–1074.
51. Bom N, Lancée CT, Van Egmond FC. An ultrasonic intracardiac scanner. *Ultrasonics* 1972;**10**:72–76.
52. Feigenbaum H. *Echocardiography*. Philadelphia: Lea & Febiger; 1972.
53. Kloster FE, Roelandt J, ten Cate FJ, Bom N, Hugenholz PG. Multiscan Echocardiography II. Technique and initial clinical results. *Circulation* 1973;**48**:1075–1084.
54. Roelandt J, Kloster FE, ten Cate FJ, Bom N, Lancée CT, Hugenholtz PG. Multiscan echocardiography; description of the system and initial results in 100 patients. *Heart Bull* 1973;**4**:51–56.
55. Griffith JM, Henry WL. A real-time system for two-dimensional echocardiography. In: 26th ECEMB. 1973:422.
56. Griffith JM, Henry WL. A sector scanner for real time two-dimensional echocardiography. *Circulation* 1974;**49**:1147–1152.
57. Thurstone FJ, von Ramm OT. A new ultrasound imaging technique employing two-dimensional electronic beam steering. In: Green PS (ed.), *Acoustical Holography (volume 5)*. Plenum Publishing Corporation. New York; 1974. p149–159.
58. von Ramm OT, Thurstone FL. Cardiac imaging using a phased-array ultrasound system I: System design. *Circulation* 1976;**53**:258–262.
59. Kisslo J, von Ramm OT, Thurstone FL. Cardiac imaging using a phased array ultrasound system. II. Clinical technique and application. *Circulation* 1976;**53**:262–267.
60. Barber FE, Baker DW, Nation AWC, Strandness DE, Reid JM. Ultrasonic duplex echo-Doppler scanner. *IEEE Trans Biomed Eng* 1974;**21**:109–113.
61. Dekker DL, Piziali RL, Dong E Jr. A system for ultrasonically imaging the human heart in three dimensions. *Comput Biomed Res* 1974;**7**:544–553.
62. Teichholz LE, Cohen MV, Sonnenblick EH, Gorlin R. Study of left ventricular geometry and function by B-scan ultrasonography in patients with and without asynergy. *N Engl J Med* 1974;**291**:1220–1226.
63. Angelsen BA, Brubakk AO. Transcutaneous measurement of blood flow velocity in the human aorta. *Cardiovasc Res* 1976;**10**:368–379.
64. Frazin L, Talano JV, Stephanides L, Loeb HS, Kopel L, Gunnar RM. Esophageal echocardiography. *Circulation* 1976;**54**:102–108.
65. Hølen J, Aaslid R, Landmark K, Simonsen S. Determination of pressure gradient in mitral stenosis with a noninvasive ultrasound Doppler technique. *Acta Med Scand* 1976;**199**:455–460.
66. Ligetvoet C, Rijsterborgh H, Kappen L, Bom N. Real time ultrasonic imaging with a hand-held scanner. Part I – technical description. *Ultrasound Med Biol* 1978;**4**:91–92.
67. Roelandt J, Wladimiroff JW, Baars AM. Ultrasonic real-time imaging with a hand-held scanner. Part II. Initial clinical experience. *Ultrasound Med Biol* 1978;**4**:93–97.
68. Hisanaga K, Hisanaga A, Nagata K, Yoshida S. A new transesophageal real-time two-dimensional echocardiographic system using a flexible tube and its clinical applications. *Proc Jap Soc Ultrasonics Med* 1977;**32**:43–44.
69. Hisanaga K, Hisanaga A, Hibi N, Nishimura K, Kambe T. High speed rotating scanner for transesophageal cross-sectional echocardiography. *Am J Cardiol* 1980;**46**:837–842.
70. Brubakk AO, Angelsen BAJ, Hatle H. Diagnosis of valvular heart disease using transcutaneous Doppler ultrasound. *Cardiovasc Res* 1977;**11**:461–469.
71. Brandestini M. Topoflow—A digital full range Doppler velocity meter. *IEEE Trans Ultrason* 1978;**25**:287–292.
72. Brandestini MA, Eyer MK, Stevenson JG. M/Q-mode echocardiography: the synthesis of conventional echo with digital multigate Doppler. In: Lancée CT (ed.), *Echocardiography*. The Hague, Netherlands: Martinus-Nijhoff; 1979.
73. Eyers MK, Brandestini M, Phillips DJ, Baker DW. Color digital echo/Doppler image presentation. *Ultrasound Med Biol* 1981;**7**:21–31.
74. Griffith JM, Henry WL. An ultrasound system for combined cardiac imaging and Doppler blood flow measurement in man. *Circulation* 1978;**57**:925–930.
75. Hatle L, Angelsen B, Tromsdal A. Non-invasive assessment of aortic stenosis by Doppler ultrasound. *Br Heart J* 1980;**43**:284–292.
76. Hatle L, Brubakk A, Tromsdal A, Angelsen B. Noninvasive assessment of pressure drop in mitral stenosis by Doppler ultrasound. *Br Heart J* 1978;**40**:131–140.
77. Wann LS, Faris JV, Childress RH, Dillon JC, Weyman AE, Feigenbaum H. Exercise cross-sectional echocardiography in ischemic heart disease. *Circulation* 1979;**60**:1300–1308.
78. Morganroth J, Chen CC, David D, Sawin HS, Naito M, Parrotto C, et al. Exercise cross-sectional echocardiographic diagnosis of coronary artery disease. *Am J Cardiol* 1981;**47**:20–26.
79. Maurer G, Nanda NC. Two dimensional echocardiographic evaluation of exercise-induced left and right ventricular asynergy: correlation with thallium scanning. *Am J Cardiol* 1981;**48**:720–727.
80. Souquet J, Hanrath P, Zitelli L, Kremer P, Langenstein BA, Schlüter M. Transesophageal phased array for imaging the heart. *IEEE Trans Biomed Eng* 1982;**29**:707–712.
81. Schlüter M, Langenstein BA, Polster J, Kremer P, Souquet J, Engel S, et al. Transoesophageal cross-sectional echocardiography with a phased array transducer system. Technique and initial clinical results. *Br Heart J* 1982;**48**:67–72.
82. Angelsen B, Hatle L. *Doppler ultrasound in cardiology*. Philadelphia: Lea & Febiger; 1982.
83. Kasai C, Namekawa K, Koyano A, Omoto R. Real time two dimensional blood flow imaging using an autocorrelation technique. *IEEE Trans Sonics Ultrasonics* 1985;**32**:458–464.
84. Omoto R, Yokote Y, Takamoto S, Kyo S, Ueda K, Asano H, et al. The development of real-time two-dimensional Doppler echocardiography and its clinical significance in acquired valvular diseases. With special reference to the evaluation of valvular regurgitation. *Jpn Heart J* 1984;**25**:325–340.
85. Kitabatake A, Inoue M, Asao M, Tanouchi J, Masuyama T, Abe H, et al. Transmitral blood flow reflecting diastolic behavior of the left ventricle in health and disease – a study by pulsed Doppler technique. *Jpn Circ J* 1982;**46**:92–102.
86. Isazak K, Thompson A, Ethevenot G, Cloez JL, Bremilla B, Pernot C. Doppler echocardiographic measurement of low velocity motion of the left ventricular posterior wall. *Am J Cardiol* 1989;**64**:66–75.
87. von Ramm OT, Smith SW. Real time volumetric ultrasound imaging system. *J Digit Imaging* 1990;**3**:261–266.
88. Flachskampf FA, Hoffmann R, Verlande M, Schneider W, Ameling W, Hanrath P. Initial experience with a multiplane transoesophageal echo-transducer: assessment of diagnostic potential. *Eur Heart J* 1992;**13**:1201–1206.
89. McDicken WN, Sutherland GR, Moran CM, Gordon LN. Colour Doppler velocity imaging of the myocardium. *Ultrasound Med Biol* 1992;**18**:651–654.
90. Brodin LA, van der Linden J, Olstad B. Echocardiographic functional images based on tissue velocity information. *Herz* 1998;**23**:491–498.
91. Heimdal A, Støylen A, Torp H, Skjaerpe T. Real-time strain rate imaging of the left ventricle by ultrasound. *J Am Soc Echocardiogr* 1998;**11**:1013–1019.
92. Leitman M, Lysyansky P, Sidenko S, Shir V, Peleg E, Binenbaum M, et al. Two-dimensional strain – a novel software for real-time quantitative echocardiographic assessment of myocardial function. *J Am Soc Echocardiogr* 2004;**17**:1021–1029.
93. Reiser SA, Lysyansky P, Agmon Y, Mutlak D, Lessick J, Friedman Z. Global longitudinal strain: a novel index of left ventricular systolic function. *J Am Soc Echocardiogr* 2004;**17**:630–633.
94. Sugeng L, Sherman SK, Salgo IS, Weinert L, Shook D, Raman J, et al. Live 3-dimensional transesophageal echocardiography initial experience using the fully-sampled matrix array probe. *J Am Coll Cardiol* 2008;**52**:446–449.
95. Fraser AG. Inge Edler and the origins of clinical echocardiography. *Eur J Echocardiogr* 2001;**2**:3–5.
96. Hertz CH. The interactions of physicians, physicists and industry in the development of echocardiography. *Ultrasound Med Biol* 1973;**1**:3–11.
97. Edler I, Hertz CH. The early work on ultrasound in medicine at the University of Lund. *J Clin Ultrasound* 1977;**5**:352–356.
98. Dussik KT. The ultrasonic field as a medical tool. *Am J Phys Med* 1954;**33**:5–20.
99. Nixdorff U. The inaugurator of transmitted echocardiography: Prof. Dr Wolf-Dieter Keidel. *Eur J Echocardiogr* 2009;**10**:48–49.
100. Ludwig GD. The velocity of sound through tissues and the acoustic impedance of tissues. *J Acoust Soc Amer* 1950;**22**:236.
101. Ballantine HT, Bolt RH, Hueter TF, Ludwig GD. On the detection of intracranial pathology by ultrasound. *Science* 1950;**112**:525–528.
102. Gohr H, Wedekind TH. Der Ultraschall in der Medizin. *Klin Wochenschr* 1940;**19**:25.
103. Edler I, Lindström K. The history of echocardiography. *Ultrasound Med Biol* 2004;**30**:1565–1644.
104. Edler L, Gustafson A. Ultrasonic cardiogram in mitral stenosis; preliminary communication. *Acta Med Scand* 1957;**159**:85–90.
105. Effert S, Domanig E. Diagnostik intraaurikulärer Tumoren und großer Thromben mit dem Ultraschall-Echoverfahren. *Dtsch Med Wochenschr* 1959;**84**:6–8.
106. Effert S, Erkens H, Grosse-Brockhoff F. Über die Anwendung des Ultraschall-Echoverfahrens in der Herzdiagnostik. *Dtsch Med Wochenschr* 1957;**82**:1253–1257.
107. Effert S. Der derzeitige Stand der Ultraschallkardiographie. *Archiv für Kreislaufforschung* 1959;**30**:213–268.
108. Feigenbaum H. Evolution of echocardiography. *Circulation* 1996;**93**:1321–1327.
109. Wild JJ, Crawford HD, Reid JM. Visualization of the excised human heart by means of reflected ultrasound of echography; preliminary report. *Am Heart J* 1957;**54**:903–906.
110. Segal BL, Likoff WV, Echocardiography KB. Clinical application in mitral stenosis. *JAMA* 1966;**195**:161–166.
111. Feigenbaum H. The origin of echocardiography? *Tex Heart Inst J* 2008;**35**:87–88.
112. Feigenbaum H, Popp RL, Wolfe SB, Troy BL, Pombro JF, Haine CL, et al. Ultrasound measurements of the left ventricle. A correlative study with angiography. *Arch Intern Med* 1972;**129**:461–467.

113. Popp RL, Filly K, Brown OR, Harrison DC. Effect of transducer placement on echocardiographic measurement of left ventricular dimensions. *Am J Cardiol* 1975;**35**: 537–540.
114. Hertz CH. Ultrasonic heart investigation. *Med Electron Biol Eng* 1964;**2**:39–45.
115. Hertz CH. Ultrasonic engineering in heart diagnosis. *Am J Cardiol* 1967;**19**:6–17.
116. Tanaka M. Historical perspective of the development of diagnostic ultrasound in cardiology. *IEEE Ultrason Symp* 1998; 1517–1524.
117. Teichholz LE, Kreulen T, Herman MV, Gorlin R. Problems in echocardiographic volume determinations: echocardiographic-angiographic correlations in the presence or absence of asynergy. *Am J Cardiol* 1976;**37**:7–11.
118. Woo J. A short history of the real-time ultrasound scanner. <https://www.ob-ultrasound.net/history-realtime.html> (accessed 1 May 2022).
119. Roelandt JRTC. Ultrasonic two-dimensional imaging of the heart with Multiscan. PhD Thesis. Erasmus University Rotterdam, 1980.
120. Eggleton RC, Feigenbaum H, Johnston KVV, Weyman AE, Dillon JC, Chang S, editors. Visualization of cardiac dynamics with real-time B-mode ultrasonic scanner. In: White D, ed. *Ultrasound in Medicine*. New York, NY: Plenum Publishing Corp; 1975.
121. Wharton CF, Smithen CS, Sowton E. Changes in left ventricular movement after acute myocardial infarction measured by reflected ultrasound. *Brit Med J* 1971;**9**: 75–77.
122. Picano E, Distanto A, Masini M, Morales MA, Lattanzi F, L'Abbate A. Dipyridamole-echocardiography test in effort angina pectoris. *Am J Cardiol* 1985; **56**:452–456.
123. Berthe C, Piérard LA, Hiernaux M, Trotteur G, Lempereur P, Carlier J, et al. Predicting the extent and location of coronary artery disease in acute myocardial infarction by echocardiography during dobutamine infusion. *Am J Cardiol* 1986; **58**:1167–1172.
124. King DL, King DL Jr, Shao MYC. Three-dimensional spatial registration and interactive display of position and orientation of real-time ultrasound images. *J Ultrasound Med* 1990;**9**:525–532.
125. Sugeng L, Weinert L, Thiele K, Lang RM. Real-time three-dimensional echocardiography using a novel matrix array transducer. *Echocardiography* 2003;**20**:623–635.
126. Karagodin I, Addetia K, Singh A, Dow A, Rivera L, DeCara JM, et al. Improved delineation of cardiac pathology using a novel three-dimensional echocardiographic tissue transparency tool. *J Am Soc Echocardiogr* 2020;**33**:1316–1323.
127. Olson RM, Shelton D. A nondestructive technique to measure wall displacement in the thoracic aorta. *J Appl Physiol* 1972;**32**:147–151.
128. Duck FA, Hodson CJ, Tomlin PJ. An esophageal Doppler probe for aortic flow velocity monitoring. *Ultrasound Med Biol* 1974;**1**:233–241.
129. Matsumoto M, Oka Y, Lin YT, Strom J, Sonnenblick EH, Frater RW. Transesophageal echocardiography; for assessing ventricular performance. *N Y State J Med* 1979;**79**:19–21.
130. Matsumoto M, Oka Y, Strom J, Frishman W, Kadish A, Becker RM, et al. Application of transesophageal echocardiography to continuous intraoperative monitoring of left ventricular performance. *Am J Cardiol* 1980;**46**:95–105.
131. Hanrath P, Kremer P, Langenstein BA, Matsumoto M, Bleifeld W. Transösophageale Echokardiographie: Ein neues Verfahren zur dynamischen Ventrikelfunktionsanalyse. *Dtsch Med Wochenschr* 1981;**106**:523–525.
132. Matsumoto M, Hanrath P, Kremer P, Tams C, Langenstein BA, Schlüter M, et al. Evaluation of left ventricular performance during supine exercise by transesophageal M-mode echocardiography in normal subjects. *Br Heart J* 1982;**48**:61–66.
133. Hisanaga K, Hisanaga A, Ichie Y, Nishimura K, Hibi N, Fukui Y, et al. Transoesophageal pulsed Doppler echocardiography. *Lancet* 1979;**1**:53–54.
134. Hanrath P, Schlüter M, Langenstein BA, Poster J, Engel S. Transesophageal horizontal and sagittal imaging of the heart with a phased array system. In: Hanrath P, Bleifeld W, Souquet J (eds.), *Initial clinical results. In Cardiovascular diagnosis by ultrasound/Transesophageal, computerized, contrast, doppler echocardiography*: Martinus Nijhoff Publishers; 1982. p280–288.
135. Orihashi K. The history of transesophageal echocardiography: the role of inspiration, innovation, and applications. *J Anesth* 2020;**34**:86–94.
136. Roelandt JR, Thomson IR, Vletter WVB, Brommersma P, Bom N, Linker DT. Multiplane transesophageal echocardiography: latest evolution in an imaging revolution. *J Am Soc Echocardiogr* 1992;**5**:361–367.
137. Djoa KK, de Jong N, Cromme-Dijkhuis AH, Lancée CT, Bom N. Two decades of transesophageal phased array probes. *Ultrasound Med Biol* 1996;**22**:1–9.
138. Stümper OF, Elzenga NJ, Hess J, Sutherland GR. Transesophageal echocardiography in children with congenital heart disease: an initial experience. *J Am Coll Cardiol* 1990;**16**:433–441.
139. Ritter SB. Transesophageal real-time echocardiography in infants and children with congenital heart disease. *J Am Coll Cardiol* 1991;**18**:569–580.
140. Eden A. *The search for Christian Doppler*. Vienna: Springer Verlag; 1992.
141. Jonkman EJ. Doppler research in the nineteenth century. *Ultrasound Med Biol* 1980; **6**:1–5.
142. Bonnefous O, Pesqué P. Time domain formulation of pulse-Doppler ultrasound and blood velocity estimation by cross correlation. *Ultrason Imaging* 1986;**8**:73–85.
143. Nimura Y. Short history of the development of echocardiography with special reference to that in Japan. *J Echocardiogr* 2003;**1**:46–59.
144. Yoshida T, Mori M, Nimura Y, Okimura M, Hikita G, Nakanishi K, et al. Study on examining the heart with the ultrasonic Doppler method: III. Kinds of Doppler beats. *Jpn Circ J* [in Japanese] 1956;**20**:228.
145. Yoshida T, Mori M, Nimura Y, Hikita G, Takagishi S, Nakanishi K, et al. Analysis of heart motion with ultrasonic Doppler method and its clinical application. *Am Heart J* 1961;**61**:61–75.
146. Kato K, Kido Y, Motomiya M, Kaneko Z, Kotani H. On the mechanism of generation of detected sound in ultrasonic flowmeter. *Memoirs Inst Scient Indust Res Osaka Univ* 1962;**19**:51–57.
147. Coman IM, Popescu BA, Shigeo Satomura: 60 years of Doppler ultrasound in medicine. *Cardiovasc Ultrasound* 2015;**13**:48.
148. Kato K, Izumi T. A new ultrasonic flowmeter that can detect flow direction. *Jap Med Ultrasonics* 1966;**5**:28–30.
149. Rushmer RF, Baker DW, Stegall HF. Transcutaneous Doppler flow detection as a non-destructive technique. *J Appl Physiol* 1966;**21**:554–566.
150. Veyrat C. Une brève histoire du Doppler cardiovasculaire. De la confidentialité à la reconnaissance (1956–1980). *Cardinale* 1997;**9**:52–56.
151. Kalmanson D, Veyrat C, Chiche P. Diagnostic par voie externe des cardiopathies droites et des shunts intra-cardiaques gauche-droite à l'aide du fluxmètre directionnel à effet Doppler. *Presse Méd* 1970;**78**:1053–1056.
152. Veyrat C. Directional Doppler in cardiology: a 50-year journey. *J Am Soc Echocardiogr* 2018;**31**:1308–1322.
153. Holen J, Waag RC, Gramiak R, Violante MR, Roe SA. Doppler ultrasound in orifice flow. In vitro studies of the relationship between pressure difference and fluid velocity. *Ultrasound Med Biol* 1985;**11**:261–266.
154. Matre K. Norway–Technology. In: *EFSUMB History of Ultrasound*, edited Dietrich CF. <https://efsumb.org/wp-content/uploads/2020/12/History-Norway-technology.pdf> (accessed 1 May 2022).
155. Skjaerpe T, Hatle L. Diagnosis and assessment of tricuspid regurgitation with Doppler ultrasound. In: Rijsterborgh H, ed. *Echocardiology*. The Hague: Martinus Nijhoff; 1981. p299–304.
156. Skjaerpe T, Hatle L. Noninvasive estimation of systolic pressure in the right ventricle in patients with tricuspid regurgitation. *Eur Heart J* 1986;**7**:704–710.
157. Fujii J, Yazaki Y, Sawada H, Aizawa T, Watanabe H, Kato K. Noninvasive assessment of left and right ventricular filling in myocardial infarction with a two-dimensional Doppler echocardiographic method. *J Am Coll Cardiol* 1985;**5**:1155–1160.
158. Namekawa K, Kasai C, Tsukamoto M, Koyano A. Imaging of blood flow using auto-correlation. *Ultrasound Med Biol* 1982;**8**:138.
159. Jenni R, Vieli A, Ruffmann K, Krayenbuehl HP, Anliker M. A comparison between single gate and multigate ultrasonic Doppler measurements for the assessment of the velocity pattern in the human ascending aorta. *Eur Heart J* 1984;**5**:948–953.
160. Kostis JB, Fleischmann D, Bellet S. Use of the ultrasonic Doppler method for timing of valvular movement. Application in the differential diagnosis of extra heart sounds. *Circulation* 1969;**40**:197–207.
161. Sutherland GR, Stewart MJ, Groundstroem KW, Moran CM, Fleming A, Guell-Peris FJ, et al. Color Doppler myocardial imaging: a new technique for the assessment of myocardial function. *J Am Soc Echocardiogr* 1994;**7**:441–458.
162. Weidemann F, Eyskens B, Mertens L, Dommke C, Kowalski M, Simmons L, et al. Quantification of regional right and left ventricular function by ultrasonic strain rate and strain indexes after surgical repair of tetralogy of Fallot. *Am J Cardiol* 2002;**90**:133–138.
163. Eyskens B, Weidemann F, Kowalski M, Bogaert J, Dymarkowski S, Bijnens B, et al. Regional right and left ventricular function after the Senning operation: an ultrasonic study of strain rate and strain. *Cardiol Young* 2004;**14**:255–264.
164. Bohs LN, Trahey GE. A novel method for angle independent ultrasonic imaging of blood flow and tissue motion. *IEEE Trans Biomed Eng* 1991;**38**:280–286.
165. Ultan LB, Segal BL, Likoff W. Echocardiography in congenital heart disease. Preliminary observations. *Am J Cardiol* 1967;**19**:74–83.
166. Lundström NR, Edler I. Ultrasoundcardiography in infants and children. *Acta Paediatr Scand* 1971;**60**:117–128.
167. Gramiak R, Chung KJ, Nanda N, Manning J. Echocardiographic diagnosis of transposition of the great vessels. *Radiology* 1973;**106**:187–189.
168. Van Praagh R. Terminology of congenital heart disease. Glossary and commentary. *Circulation* 1977;**56**:139–143.
169. Tynan MJ, Becker AE, Macartney FJ, Jiménez MQ, Shinebourne EA, Anderson RH. Nomenclature and classification of congenital heart disease. *Br Heart J* 1979;**41**: 544–553.
170. Rigby ML, Anderson RH, Gibson D, Jones OD, Joseph MC, Shinebourne EA. Two dimensional echocardiographic categorisation of the univentricular heart. Ventricular morphology, type, and mode of atrioventricular connection. *Br Heart J* 1981;**46**:603–612.

171. Sutherland GR, Godman MJ, Smallhorn JF, Guiterras P, Anderson RH, Hunter S. Ventricular septal defects. Two dimensional echocardiographic and morphological correlations. *Br Heart J* 1982;**47**:316–328.
172. Gutgesell HP, Huhta JC, Latson LA, Huffines D, McNamara DG. Accuracy of two-dimensional echocardiography in the diagnosis of congenital heart disease. *Am J Cardiol* 1985;**55**:514–518.
173. Hatle L, Rokseth R. Noninvasive diagnosis and assessment of ventricular septal defect by Doppler ultrasound. *Acta Med Scand Suppl* 1981;**645**:47–56.
174. Acar P, Abadir S, Paranon S, Latcu G, Grosjean J, Dulac Y. Live 3D echocardiography with the pediatric matrix probe. *Echocardiography* 2007;**24**:750–755.
175. Simpson JM. Real-time three-dimensional echocardiography of congenital heart disease using a high frequency paediatric matrix transducer. *Eur J Echocardiogr* 2008;**9**:222–224.
176. Campbell S. A short history of sonography in obstetrics and gynaecology. *Facts Views Vis Obgyn* 2013;**5**:213–229.
177. Wladimiroff JW, Vosters R, Stewart PA. Fetal echocardiography; basic and clinical considerations. *Ultrasound Med Biol* 1984;**10**:315–327.
178. Allan LD, Tynan MJ, Campbell S, Wilkinson JL, Anderson RH. Echocardiographic and anatomical correlates in the fetus. *Br Heart J* 1980;**44**:444–451.
179. Franklin DL, Ellis RM, Rushmer RF. Aortic blood flow in dogs during treadmill exercise. *J Appl Physiol* 1959;**14**:809–812.
180. Kimoto S, Omoto R, Tsunemoto M, Muroi T, Atsumi K, Uchida R. Ultrasonic tomography of the liver and detection of heart atrial septal defect with the aid of ultrasonic intravenous probes. *Ultrasonics* 1964;**2**:82–86.
181. Bom N, ten Hoff H, Lancée CT, Gussenhoven VJ, Bosch JG. Early and recent intraluminal ultrasound devices. *Int J Card Imaging* 1989;**4**:79–88.
182. Bom N, Slager CJ, van Egmond FC, Lancée CT, Serruys PW. Intra-arterial ultrasonic imaging for recanalization by spark erosion. *Ultrasound Med Biol* 1988;**14**:257–261.
183. Yock PG, Linker DT, Angelsen BA. Two-dimensional intravascular ultrasound: technical development and initial clinical experience. *J Am Soc Echocardiogr* 1989;**2**:296–304.
184. Yock PG, Fitzgerald P, White N, Linker DT, Angelsen BA. Intravascular ultrasound as a guiding modality for mechanical atherectomy and laser ablation. *Echocardiography* 1990;**7**:425–431.
185. Tobis JM, Mallery JA, Gessert J, Griffith J, Mahon D, Bessen M, et al. Intravascular ultrasound cross-sectional arterial imaging before and after balloon angioplasty in vitro. *Circulation* 1989;**80**:873–882.
186. Hodgson JM, Graham SP, Savakus AD, Dame SG, Stephens DN, Dhillon PS, et al. Clinical percutaneous imaging of coronary anatomy using an over-the-wire ultrasound catheter system. *Int J Card Imaging* 1989;**4**:187–193.
187. Linker DT, Yock PG, Grønningsaether A, Johansen E, Angelsen BA. Analysis of backscattered ultrasound from normal and diseased arterial wall. *Int J Card Imaging* 1989;**4**:177–185.
188. Gussenhoven VJ, Essed CE, Frietman P, Mastik F, Lancée C, Slager C, et al. Intravascular echographic assessment of vessel wall characteristics: a correlation with histology. *Int J Card Imaging* 1989;**4**:105–116.
189. Li W, Gussenhoven VJ, Bosch JG, Mastik F, Reiber JHC, Bom N. A computer-aided analysis system for the quantitative assessment of intravascular ultrasound images. *Computers in Cardiology* 1990:333–336.
190. Schultz CJ, Serruys PW, van der Ent M, Ligthart J, Mastik F, Garg S, et al. First-in-man clinical use of combined near-infrared spectroscopy and intravascular ultrasound: a potential key to predict distal embolization and no-reflow? *J Am Coll Cardiol* 2010;**56**:314.
191. Dietrich CF, Duck F, Bolondi L, Evans DH, Ewertsen C, Fraser AG, et al. History of ultrasound in medicine from its birth to date (2022), on occasion of the 50 Years Anniversary of EFSUMB. A publication of the European Federation of Societies for Ultrasound In Medicine and Biology (EFSUMB), designed to record the historical development of medical ultrasound. *Med Ultrason* 2022; May 15. doi:10.11152/mu-3757.
192. Wells PN. Milestones in cardiac ultrasound: echoes from the past. History of cardiac ultrasound. *Int J Card Imaging* 1993;**9**:3–9.
193. Roelandt JR. Seeing the invisible: a short history of cardiac ultrasound. *Eur J Echocardiogr* 2000;**1**:8–11.
194. Bom N, van der Steen AFW, de Jong N, Roelandt JR. Early, recent and future applications of echocardiography. *Clin Physiol Funct Imaging* 2004;**24**:141–146.
195. Light LH. Measures of cardiac output. *Ultrasound Med Biol* 1992;**18**:309–312.