

Topical Zinc Oxide Assessed in Two Human Wound-healing Models

Magnus S. ÅGREN¹⁻³, Natthawut PHOTHONG², Ewa A. BURIAN¹, Mette MOGENSEN¹, Merete HAEDERSDAL^{1,3}, Lars N. JORGENSEN^{2,3}

¹Department of Dermatology and Copenhagen Wound Healing Center, ²Digestive Disease Center, Bispebjerg Hospital, University of Copenhagen, Nielsine Nielsens Vej 11, DK-2400 Copenhagen and ³Department of Clinical Medicine, Faculty of Health and Medical Sciences, University of Copenhagen, Copenhagen, Denmark. E-mail: Sven.Per.Magnus.Aagren@regionh.dk

Accepted May 10, 2021; Epub ahead of print May 18, 2021

Zinc oxide (ZnO) is commonly applied to inflamed and injured skin due to the anti-phlogistic effects of bioactive Zn²⁺ (1, 2). Pretreatment of normal human epidermal keratinocytes (NHEKs) with Zn²⁺ reduced secretion of the proinflammatory cytokine interleukin (IL)-1 α (3). Furthermore, topical administration of ZnO to murine skin increases keratinocyte mitosis (4), which is beneficial in wound healing. Non-invasive monitoring of inflammation and cell proliferation would provide extremely useful information. The aim of this randomized, double-blind, placebo-controlled trial (NCT03221699) was to study the anti-inflammatory and wound-healing effects of topical ZnO (1.1%) in an oil-in-water emulsion, by assessing skin erythema and complete wound closure in 2 standardized wound models. Furthermore, the usefulness of protein biomarkers, of inflammatory processes, IL-1 α , and of epidermal proliferation, keratin 6A (K6A), were assessed (5, 6).

MATERIALS AND METHODS

Participants, study design and flow, randomization, blinding and treatments have been described in our previous publication (7). In 30 Caucasian healthy volunteers, one axilla was randomized to daily application of ZnO and the contra-lateral axilla to daily application of placebo. After 8 days of treatment, duplicate lancet wounds (each 1.5-mm wide and 2.0-mm deep) were made 2 cm apart using a paediatric blood collection device (8) and 1 laser wound was made with an ablative fractional CO₂ laser (7×7 mm and 0.8 mm deep) with a density of 10% and 20 mJ pulse energy (9) in the treated non-hairy axillary fossa. The daily treatments

continued, and inflammation and wound healing were monitored by handyscope postwounding on days 3, 4 and 5. A scab/crust-free wound was considered completely healed. Surface skin proteins were collected with a 5.4-cm² piece of adhesive tape (5) and analysed on IL-1 α and K6A by enzyme-linked immunoassay (ELISA). The relevance of using K6A as biomarker of proliferation was investigated in proliferating vs stratifying NHEKs *in vitro*. Further details of the methods are given in Appendix S1¹.

The area under the erythema-time curve (AUC) was calculated and compared with the *t*-test (10). The IL-1 α data were analysed by analysis of variance (ANOVA) and the K6A levels in NHEKs by the *t*-test. *p* < 0.05 was considered statistically significant.

RESULTS AND DISCUSSION

Erythema was slightly (*p* < 0.05) attenuated by topical application of ZnO around the incisional wounds, but not in laser-induced wounds (Fig. 1). The reason for the lack of effects of ZnO in laser-induced wounds on inflammation is unknown.

On day 5, 16 of the 58 ZnO-treated lancet wounds were healed, compared with 18 of the 58 placebo-treated wounds. The corresponding healing rates for the laser wounds were 5 of 29 ZnO-treated and 4 of 29 placebo-treated wounds. That ZnO did not accelerate wound healing contrasts with previous findings (11). It is noteworthy that the ZnO formulation delivers at least 20-fold higher Zn²⁺ levels than is beneficial for epithelialization with ZnO incorporated in another carrier (7, 12). It is possible

¹<https://doi.org/10.2340/00015555-3829>

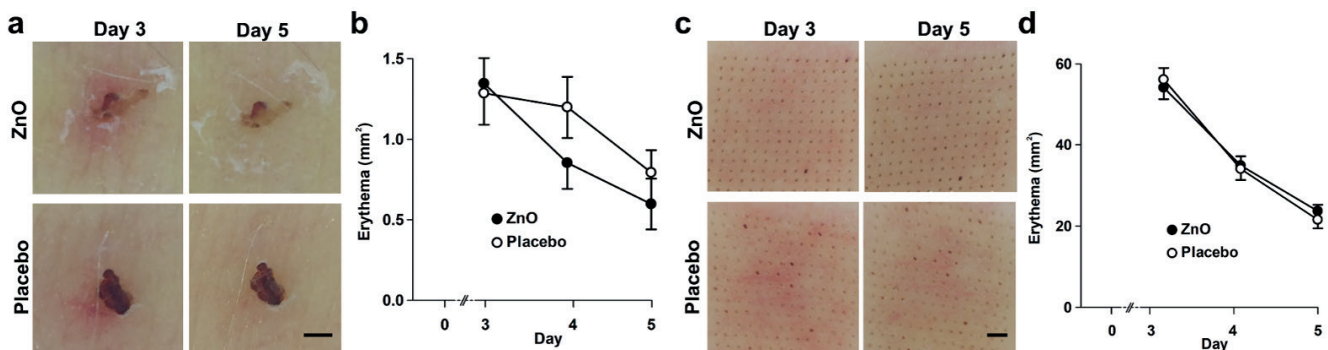


Fig. 1. (a, b) Erythema around lancet-induced wounds and (c, d) in laser wounds. (a, c) Images (20× magnification) were taken with a handyscope and (b, d) the erythematous areas (mm²) were quantified using ImageJ software (NIH, Bethesda, MD, USA). (b) The area under the curve (AUC) between days 3 and 5 decreased in zinc oxide (ZnO)-treated (1.81 ± 0.27 mm² · day) lancet wounds (*p* < 0.05, 1-tailed paired *t*-test) compared with placebo-treated (2.23 ± 0.31 mm² · day) wounds (14 wounds with ecchymosis were excluded). The mean of the areas of the anterior and posterior lancet wounds was used for statistical analyses. (d) The extent of erythema was similar for ZnO and placebo-treated laser wounds. Scale bar: 1 mm. Mean ± standard error of the mean (SEM).

that the placebo alone promoted epithelialization due to its glycerol component, which increases skin hydration (13). MMP inhibitors delay epithelialization and could be included to obtain an idea of the range of detection (10).

Nyman et al. (14) demonstrated enhanced epithelialization of lacerated wounds by intradermal injections of hyaluronic acid; 8 of 9 wounds on the forearm were completely epithelialized (as judged by histology) already on post-wounding day 1 compared with none in the control group. In addition, these authors found that erythema peaked on day 1 using polarized light spectroscopy (14), confirming previous findings with laser Doppler perfusion imaging (8). The current study found that digital photography with the handyscope, followed by image analysis, was convenient. The validity of images acquired with the handyscope for erythema measurements was confirmed using an open macro lens (Appendix S2¹).

The levels of the inflammation biomarker IL-1 α were similar in the ZnO and placebo groups after 8 days of skin treatment and in the laser wounds on day 5, confirming the macroscopic erythema measurements (Fig. 2).

This study searched for a biomarker of keratinocyte proliferation to reproduce the observed mitogenic effect of topical ZnO in the epidermis (4). The cytoskeletal protein K6 is associated with keratinocyte proliferation. However, K6A was undetectable in tape-strips of skin and treated laser wounds. Kinn et al. (6) sampled corneocytes from the forearms with chambers incubated with phosphate-buffered saline (PBS) for 30 min and reported K6 levels exceeding 1,000 pg/ml. This discrepancy was unlikely to be due to the ELISA assay, as the assay performed as expected in NHEKs, which showed increased ($p=0.003$) intracellular K6A contents in proliferating (279 ± 46 pg/ μ g protein) vs differentiating (160 ± 26 pg/ μ g protein) NHEKs, or to extracellular K6A, which was not detected in concentrated (10 \times) conditioned medium.

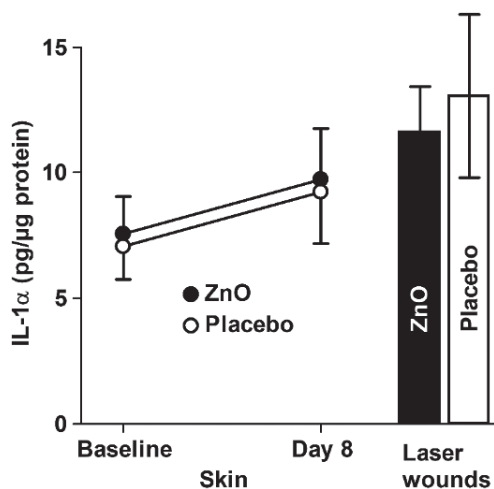


Fig. 2. Interleukin (IL)-1 α in treated skin and day-5 laser wounds in the axilla. IL-1 α was detected in 169 of the 176 tape-strip samples. IL-1 α levels did not differ ($p=0.673$) between the zinc oxide (ZnO) and placebo groups after 8 days of skin treatment or in the laser wounds ($p=0.599$). Mean \pm standard error of the mean (SEM).

Arginase is elevated in psoriatic skin and has been suggested to reflect increased keratinocyte proliferation (15). In general, sampling of skin surface biomarkers by tape stripping is a very valuable method to elucidate physiological and pathophysiological mechanisms and mode of action of therapeutics and cosmetics on the skin.

The authors have no conflicts of interest to declare.

REFERENCES

- Larsen HF, Ahlström MG, Gjerdrum LMR, Mogensen M, Ghathian K, Calum H, et al. Noninvasive measurement of reepithelialization and microvascularity of suction-blister wounds with benchmarking to histology. *Wound Repair Regen* 2017; 25: 984–993.
- Ågren MS, Chafranska L, Eriksen JO, Forman JL, Bjerrum MJ, Schjerling P, et al. Spatial expression of metallothionein, matrix metalloproteinase-1 and Ki-67 in human epidermal wounds treated with zinc and determined by quantitative immunohistochemistry: a randomised double-blind trial. *Eur J Cell Biol* 2021; 100: 151147.
- Isard O, Leveque M, Knol AC, Aries MF, Khammari A, Nguyen JM, et al. Anti-inflammatory properties of a new undecylrhannoside (APRC11) against *P. acnes*. *Arch Dermatol Res* 2011; 303: 707–713.
- Jin L, Murakami TH, Janjua NA, Hori Y. The effects of zinc oxide and diethyldithiocarbamate on the mitotic index of epidermal basal cells of mouse skin. *Acta Med Okayama* 1994; 48: 231–236.
- Perkins MA, Osterhues MA, Farage MA, Robinson MK. A noninvasive method to assess skin irritation and compromised skin conditions using simple tape adsorption of molecular markers of inflammation. *Skin Res Technol* 2001; 7: 227–237.
- Kinn PM, Holdren GO, Westermeyer BA, Abuissa M, Fischer CL, Fairley JA, et al. Age-dependent variation in cytokines, chemokines, and biologic analytes rinsed from the surface of healthy human skin. *Sci Rep* 2015; 5: 10472.
- Ågren MS, Ghathian KSA, Frederiksen AKS, Bjerrum MJ, Calum H, Danielsen PL, et al. Zinc oxide inhibits axillary colonization by members of the genus *Corynebacterium* and attenuates self-perceived malodour: a randomized, double-blind, placebo-controlled trial. *Acta Derm Venereol* 2020; 100: adv00145.
- Varol AL, Anderson CD. A minimally invasive human in vivo cutaneous wound model for the evaluation of innate skin reactivity and healing status. *Arch Dermatol Res* 2010; 302: 383–393.
- Haak CS, Hannibal J, Paasch U, Anderson RR, Haedersdal M. Laser-induced thermal coagulation enhances skin uptake of topically applied compounds. *Lasers Surg Med* 2017; 49: 582–591.
- Ågren MS, Mirastschijski U, Karlsmark T, Saarialho-Kere UK. Topical synthetic inhibitor of matrix metalloproteinases delays epidermal regeneration of human wounds. *Exp Dermatol* 2001; 10: 337–348.
- Lansdown AB, Mirastschijski U, Stubbs N, Scanlon E, Ågren MS. Zinc in wound healing: theoretical, experimental, and clinical aspects. *Wound Repair Regen* 2007; 15: 2–16.
- Ågren MS, Krusell M, Franzén L. Release and absorption of zinc from zinc oxide and zinc sulfate in open wounds. *Acta Derm Venereol* 1991; 71: 330–333.
- Evans RL, Turner GA, Bates S, Robinson T, Arnold D, et al. Human axillary skin condition is improved following incorporation of glycerol into the stratum corneum from an antiperspirant formulation. *Arch Dermatol Res* 2017; 309: 739–748.
- Nyman E, Henricson J, Ghafouri B, Anderson CD, Kratz G. Hyaluronic acid accelerates re-epithelialization and alters protein expression in a human wound model. *Plast Reconstr Surg Glob Open* 2019; 7: e2221.
- Abeyakirithi S, Mowbray M, Bredenkamp N, van Overloop L, Declercq L, Davis PJ, et al. Arginase is overactive in psoriatic skin. *Br J Dermatol* 2010; 163: 193–196.