

Osteoradionecrosis of the jaws: definition, epidemiology, staging and clinical and radiological findings. A concise review

Aristeidis Chronopoulos¹, Theodora Zarra², Michael Ehrenfeld¹ and Sven Otto¹

¹Department of Oral and Maxillofacial Surgery, Ludwig-Maximilians-University of Munich, Munich, Germany; ²Department of Endodontology, Dental School, Aristotle University of Thessaloniki, Thessaloniki, Greece.

Osteoradionecrosis (ORN) of the jaws is a pernicious complication of radiation therapy for head and neck tumours. This article aims to provide an update on data related to the definition, epidemiology, staging, and clinical and radiological findings of ORN of the jaws. Using certain keywords, an electronic search was conducted spanning the period from January 1922 to April 2014 to identify the available related investigations. Pooled data were then analysed. ORN is described as exposed irradiated bone that fails to heal over a period of 3 months without evidence of persisting or recurrent tumour. The prevalence of ORN varies in the literature. Several staging or scoring systems of ORN have been proposed. Clinical findings include ulceration or necrosis of the mucosa with exposure of necrotic bone. Radiological findings are not evident in the early stages of ORN. Furthermore ORN may not be apparent in imaging even when the disease is advanced. Taking into account the severity of ORN and the difficulties in diagnosing it early and accurately, the clinician should be aware of this complex entity in order to prevent its appearance or the development of more severe complications.

Key words: Clinical findings, epidemiology, jaw, osteoradionecrosis, radiation therapy

INTRODUCTION

Osteoradionecrosis (ORN) is a pernicious complication of radiotherapy in head and neck cancer. It was first described by Regaud¹ in 1922 and is still a clinical challenge. According to the most recent literature, ORN of the jaws is defined as exposed irradiated bone that fails to heal over a period of 3 months without any evidence of persisting or recurrent tumour^{2–4}. The mechanism of pathogenesis is still under investigation. However, the most frequently reported reason is radiation arteritis. Radiation arteritis leads to the development of a hypocellular, hypovascular and hypoxic environment, which results in a pathological outcome⁵.

The purpose of this paper is to explore the current theories on the definition and staging systems of ORN of the jaws. In addition, the epidemiology and the clinical and radiological findings of ORN of the jaws, are critically reviewed based on the available literature.

Finally, critical issues and considerations are discussed and pathways for future research are proposed.

METHODS

An electronic search of three databases (PubMed, Scopus and the Cochrane Library) was performed using the keywords ‘osteoradionecrosis’, ‘radiotherapy’, ‘osteonecrosis’, ‘osteoradionecrosis’ and ‘mandible’, ‘osteoradionecrosis’ and ‘jaw’, ‘osteoradionecrosis’ and ‘radiotherapy’, ‘osteoradionecrosis’ and ‘staging’, ‘osteoradionecrosis’ and ‘clinical findings’, ‘osteoradionecrosis’ and ‘radiological findings’, to identify literature published in English and German between January 1922 and April 2014 (Table 1). Abstracts were obtained for all the titles identified during the electronic search. Two reviewers (A.C. and T.Z.) independently screened titles and abstracts to eliminate articles that were completely off-topic. No other exclusion criteria were utilised. Following exclusion of

Table 1 Example of electronic search strategy in PubMed

Search strategy	Results
Osteoradionecrosis	1,980
Radiotherapy	286,652
Osteonecrosis	15,087
Osteoradionecrosis and mandible	636
Osteoradionecrosis and jaw	738
Osteoradionecrosis and radiotherapy	1,332
Osteoradionecrosis and staging	76
Osteoradionecrosis and clinical findings	177
Osteoradionecrosis and radiological findings	30

the articles irrelevant to the topic and the removal of duplicating papers, the remaining articles were carefully reviewed and their findings were critically analysed.

RESULTS

Definition

Several attempts have been made in order to define ORN. Ewing⁶ was the first to use the term ‘radiation osteitis’ to describe changes in bone after radiotherapy. In the following years, several terms were used to name these changes in bone, such as radiation osteitis, ORN and avascular bone necrosis⁷. In 1974, Guttenberg⁸ proposed the term ‘septic ORN of the mandible’ to describe the stage of necrosis when irradiated bone becomes superficially infected, ending up with a high risk of involvement of deeper structures.

In 1983, Marx⁵ defined ORN as ‘an area >1 cm of exposed bone in a field of irradiation that failed to show any evidence of healing for at least 6 months’. Marx also reported that superficial contamination and no interstitial infection was present. In 1987, Marx and Johnson³ suggested the definition of ORN as: ‘The exposure of nonviable bone which fails to heal without intervention’. Epstein *et al.*⁹ defined ORN as ‘an ulceration or necrosis of the mucous membrane, with exposure of necrotic bone for more than 3 months’.

Widmark *et al.*¹⁰ described ORN as ‘a non-healing mucosal or cutaneous ulcer with denuded bone, lasting for more than 3 months’. Both Widmark and Marx excluded from their definition conditions with necrotic bone for which the mucosa and skin were intact. Store and Boysen¹¹ reported that exposed bone is sporadically present; radiological findings are evident in all cases of ORN. In 1997, Wong *et al.*¹² defined ORN as ‘a slow-healing radiation-induced ischemic necrosis of variable extent occurring in the absence of local primary tumor necrosis, recurrence or metastatic disease’.

According to the literature published in the last 15 years, ORN of the jaws is defined as exposed irradiated bone that fails to heal over a period of

3 months without evidence of persisting or recurrent tumour^{2-4,13-15}. At the time of diagnosis, the necrosis might involve the bone superficially or deeply. It might be a process that progresses slowly or an active progressive state that can lead to a pathological fracture¹⁶⁻¹⁸.

Epidemiology

The prevalence of ORN varies widely in the literature (Table 2)^{16,17,19-48} and ranges from 0.4% to 56%^{19,20,22,24,30-33,36,49}. ORN usually affects patients over 55 years of age^{14,36,50,51}. However, the most frequently reported prevalence rate is 5–15%^{7,36,52}. In up to 20% of patients with persistent ORN which does not respond to aggressive treatment, bone damage is reported to be caused by recurrent disease or a second primary tumour^{16,53}.

Staging

Several staging or scoring systems of ORN have been proposed (Table 3)^{2,11,32,54-59}. These systems are based on response to hyperbaric oxygen (HBO) therapy, degree of bone damage, clinical–radiological findings, duration of bone exposure and treatment required.

Coffin⁵⁵ divided cases of ORN into two groups: minor and major. Morton and Simpson⁵⁶ subdivided ORN into three groups – ‘minor’, ‘moderate’ and ‘major’. In 1983, Marx² proposed a three-stage system for ORN. According to his protocol, patients are categorised as Stage I if they exhibit exposed bone in a field of radiation that has failed to heal for at least 6 months and do not have a pathological fracture, cutaneous fistula or osteolysis to the inferior border. In Stage I, all patients receive 30 sessions of HBO at 2.4 atmospheres absolute for 90 minutes at depth. Patients who respond to HBO alone (Stage I responder) demonstrate a softening of the radiated tissues and spontaneous sequestration of exposed bone with formation of granulation tissue. Each Stage I responder undergoes an additional 10 HBO sessions and then the tissues are allowed to heal completely. Stage II patients are those who do not respond to the 30 sessions of HBO. This group is characterised by a large amount of non-viable bone that makes resorption and sequestration from HBO-induced angiogenesis alone impossible. Consequently, careful surgical debridement is required. Stage II patients undergo transoral resection with limited soft-tissue reflection. In particular, surgical treatment includes extraction of involved dentition and a non-continuity bone resection to clinically bleeding bone. Wound flaps are closed primarily and the patient is given 10 postsurgical sessions of HBO. Tissues that heal without

Table 2 Incidence of osteoradionecrosis (ORN) in different studies

Study	Year	Period	Total number of patients	Prevalence of ORN (%)	Mean irradiation dose
Watson and Scarborough ²⁰	1938	1930–1937	1,819	12.9	
Martin and Sugarbaker ²¹	1940		103	25	
MacComb ²²	1962	1952–1959	251	37.1	
MacDougall <i>et al.</i> ²³	1963		364	5	
Grant and Fletcher ²⁴	1966	1954–1962	176	37.5	10,000*
Rahn and Drane ²⁵	1967	1960–1962	120	44.2	
Rankow and Weissman ²⁶	1971		176	6.3	5,000*
Wang ²⁷	1972		262	5.8	
Cheng and Wang ²⁸	1974		76	17.1	2,500*
Marciani and Plezia ²⁹	1974		220	10.5	
Bedwinek <i>et al.</i> ³⁰	1976	1966–1971	381	14.2	7,000*
Murray <i>et al.</i> ³¹	1980	1966–1975	653	21.1	5,000*
Morrish <i>et al.</i> ¹⁹	1981	1971–1977	100	22	7,500*
Epstein <i>et al.</i> ³²	1987	1977–1984	1,000	2.7	6,000*
Withers <i>et al.</i> ³³	1995	1976–1985	676	4.7	65 [†]
Turner <i>et al.</i> ³⁴	1996	1980–1987	333	5.9	55 [†]
Thorn <i>et al.</i> ¹⁶	2000	1992–1998	80	74	60 [†]
Storey <i>et al.</i> ³⁵	2001	1965–1995	83	6	60 [†]
Reuther <i>et al.</i> ³⁶	2003	1969–1999	830	8.2	60 [†]
Oh <i>et al.</i> ³⁷	2004	1989–2004	81	4.9	52.6 [†]
Studer <i>et al.</i> ³⁸	2004	1980–1998	268	12.5	60 [†]
Ben-David <i>et al.</i> ³⁹	2007	1996–2005	176	0	65 [†]
Jham <i>et al.</i> ⁴⁰	2008	2003–2005	207	5.5	58.9 [†]
Katsura <i>et al.</i> ⁴¹	2008	1996–2003	39	15	60.7 [†]
Gomez <i>et al.</i> ⁴²	2009	2000–2006	35	5	60 [†]
Lee <i>et al.</i> ⁴³	2009	1990–2000	198	6.6	60 [†]
Stenson <i>et al.</i> ⁴⁴	2010	1994–2008	27	18.4	62 [†]
Gomez <i>et al.</i> ⁴⁵	2011	2000–2007	168	1.2	67.9 [†]
Monnier <i>et al.</i> ¹⁷	2011	2000–2007	73	40	66 [†]
Crombie <i>et al.</i> ⁴⁶	2012	2000–2007	54	36	69.7 [†]
Niewald <i>et al.</i> ⁴⁷	2013	1993–2001	99	12	72
Tsai <i>et al.</i> ⁴⁸	2013	2000–2008	402	7.5	70 [†]

*Radiation dose given in rads.

[†]Radiation dose given in Grays (Gy).

complication are treated with a prosthesis when required, similarly to Stage I responders. Stage III patients are characterised by having a large quantity of non-viable bone and/or soft tissue unable to be managed by HBO-induced angiogenesis alone or HBO combined with local sequestrectomy. In addition to 30 presurgical HBO treatments, each Stage III patient requires a continuity resection, stabilisation and 10 postsurgical sessions of HBO, and are scheduled for later (usually 3 months) reconstruction (Stage III-R). Stage III patients are therefore those who fail to respond to Stage I and Stage II treatment and those who initially present with a pathological fracture, cutaneous fistula or osteolysis to the inferior border^{2,60}.

Epstein *et al.*³² suggested a new staging system for ORN with three tiers based on clinical findings. Glanzmann and Gratz⁵⁷ proposed a system based on the duration of bone exposure and necessity of treatment. Clayman⁵⁴ introduced a classification of ORN related to the integrity of the overlying mucosa. According to this classification, type I includes cases of ORN in which bone lysis occurs under intact gingiva or mucosa. Type II includes more aggressive cases of ORN in which soft tissues break down and

the bone is exposed to saliva, causing secondary contamination. This is defined as radiation osteomyelitis. Type I cases heal with conservative therapy; type II cases do not. In 2000, Store and Boysen¹⁶ introduced a new classification of ORN that is based on the presence or absence of clinical and radiological signs.

The most recently designed staging systems are these of Schwartz and Kagan⁵⁸ and Notani *et al.*⁵⁹ The system of Schwartz and Kagan⁵⁸ is based on clinical and radiological findings. Notani *et al.*⁵⁹ divided the cases into three grades based on the extent of the ORN lesion. Grade I is defined as ORN confined to the alveolar bone. Grade II is defined as ORN limited to the alveolar bone and/or the mandible above the level of the mandibular alveolar canal. In Grade III the ORN extends to the mandible under the level of the mandibular alveolar canal and a skin fistula and/or a pathological fracture is present.

Clinical findings

Clinical signs and symptoms of ORN include ulceration or necrosis of the mucosa with exposure of necrotic bone for longer than 3 months, pain, trismus and suppuration in the area (*Figure 1a*)^{32,61–64}.

Table 3 Classification systems of osteoradionecrosis (ORN)

Study	Stages	Description of stages	Basis of stage	
Coffin ⁵⁵	2	Minor	A series of small sequestra which separate spontaneously after varying periods of weeks or months. These areas cannot be demonstrated radiologically	Clinical and radiological findings
		Major	Necrosis occurring to an extent that involves the entire thickness of the jaw, and a pathological fracture is inevitable. This form can be obviously seen radiologically	
Marx ²	3	Stage I	Exposed alveolar bone without pathologic fracture, which responds to HBO therapy	Response to HBO therapy
		Stage II	Disease does not respond to HBO therapy, and requires sequestrectomy and saucerisation	
		Stage III	Full-thickness bone damage or pathological fracture, usually requires complete resection and reconstruction with free tissue	
Morton and Simpson ⁵⁶	3	Minor	Ulceration with exposed bone and a history of bony spicules that healed spontaneously over a period of months	Clinical findings and response to treatment
		Moderate	Exposed bone and small sequestra limited in nature and healing spontaneously with conservative treatment within 6–12 months	
		Major	Large areas of exposed bone, with formation of large sequestra, possible fracture and sinus formation. These cases often require radical treatment	
Epstein <i>et al.</i> ³²	3	Stage I	Resolved, healed	Disease progression
		Ia	No pathological fracture	
		Ib	Pathological fracture	
		Stage II	Chronic, persistent non-progressive	
		IIa	No pathological fracture	
		IIb	Pathological fracture	
Glanzmann and Gratz ⁵⁷	5	Stage 1	Bone exposure without signs of infection and persisting for at least 3 months	Duration of bone exposure and treatment necessity
		Stage 2	Bone exposure with signs of infection or sequester and without the signs of Grades 3–5	
		Stage 3	Bone necrosis treated with mandibular resection with a satisfactory result	
		Stage 4	Bone necrosis with persisting problems despite mandibular resection	
		Stage 5	Death from ORN	
Clayman ⁵⁴	2	Type I	Bone lysis occurs under intact gingiva or mucosa	Clinical findings
		Type II	A more aggressive type in which soft tissues break down, exposing the bone to saliva, and causing secondary contamination	
Store and Boysen ¹¹	4	Stage 0	Mucosal defects only	Combination of radiological and clinical parameters
		Stage 1	Radiological evidence of necrotic bone with intact mucosa	
		Stage 2	Positive radiological findings with denuded bone intra-orally	
		Stage 3	Clinically exposed radionecrotic bone, verified by imaging techniques, along with skin fistulae and infection	
Schwartz and Kagan ⁵⁸	3	Stage I	Minimal soft-tissue ulceration and limited exposed cortical bone. Patients are treated with conservative management	Imaging and clinical findings
		Stage II	Localised involvement of the mandibular cortex and underlying medullary bone	
		IIa	Minimal soft tissue ulceration	
		IIb	Presence of an oro-cutaneous fistula and mild soft-tissue necrosis	
Notani <i>et al.</i> ⁵⁹	3	Stage I	ORN confined to alveolar bone	Clinical findings
		Stage II	ORN limited to the alveolar bone and/or mandible above the level of the inferior alveolar canal	
		Stage III	ORN involving the mandible below the level of the inferior alveolar canal and/or skin fistula and/or pathological fracture	

HBO, hyperbaric oxygen.

Neurological symptoms, such as pain, dysaesthesia or anaesthesia, as well as fetor oris, dysgeusia and food impaction in the area, are also usually present. Exposure of rough and irregular bone can result in physical irritation of adjacent tissues. Progression of ORN may lead to pathological fractures, intra-oral or extra-oral fistulae and local or systemic infection. Difficulties in mouth opening, mastication and speech frequently arise^{9,65–67}. In patients treated with external beam

radiation therapy (EBRT), osseous alterations usually appear in the body of the mandible (premolar and molar regions), whereas in those managed with brachytherapy, the lingual or buccal surfaces are affected⁶⁸.

The diagnosis of septic ORN appears to be easier. Marked pain is the primary symptom. A thorough clinical examination will reveal intra- or extra-oral draining fistulae, ulcerations of the mucous

membrane, exposed devitalised bone, haemorrhage, cellulitis or pathological fractures. A biopsy is mandatory for final diagnosis in order to exclude metastatic cancer⁸.

Radiological findings

Radiographs, computed tomography (CT) scans, magnetic resonance imaging (MRI), Doppler ultrasound, nuclear medicine and near-infrared spectroscopy are often indicated in order to detect ORN¹⁸.

ORN is not usually detectable radiographically in early stages⁶⁹. Imaging features are not correlated to the severity of ORN^{8,23,70,71}. The described radiographic features range from normal appearance, to localised osteolytic areas, extensive osteolytic areas, sequestra and fracture (*Figure 1b*). Radiolucencies indicating post extraction sockets will often remain visible for longer than 12 months (*Figure 2a*). The most definitive radiographic alterations in early disease are increased radiodensity, as well as a mixed radio-opaque/radiolucent lesion in which radiolucent areas represent bone destruction (*Figure 2b*)⁸.

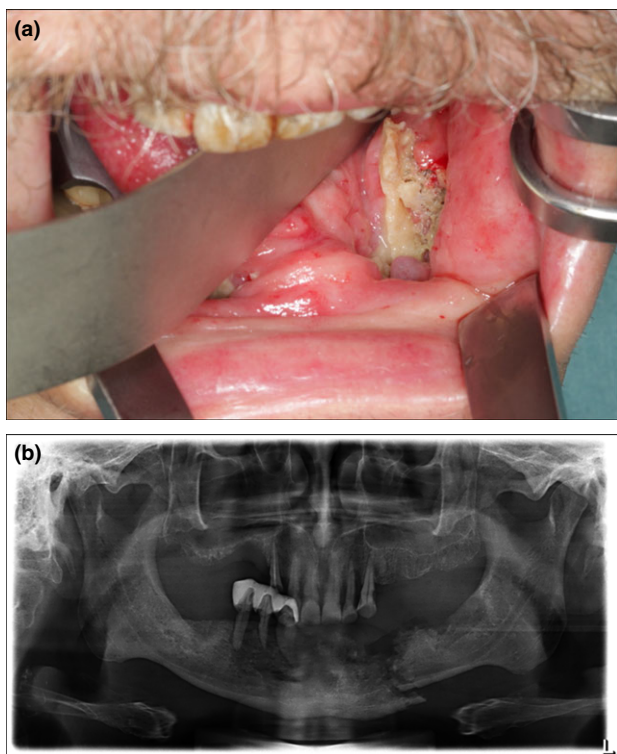


Figure 1. A 69-year-old man presented with pain and a non-healing wound in the left lower jaw. The patient was an active smoker, suffered from pharynx cancer and had received radiotherapy (external beam radiotherapy with standard field sizes, conventional fractionation and mean dose 64 Gy) and chemotherapy. Clinically, exposed necrotic bone in the left lower jaw, inflammation, swelling and inferior alveolar nerve hypesthesia was present (a). The orthopantomogram revealed pathologic fracture of the left lower jaw (b). The patient was diagnosed with osteoradionecrosis of the lower jaw and was scheduled to be treated surgically.

Orthopantomogram (OPT) is the most frequently used imaging method for the diagnosis of ORN and is usually supplemented with other extra-oral or intra-oral radiographs. In an OPT, ORN is depicted as an undefined radiolucency, without sclerotic demarcation, which surrounds necrotic zone. Radiopaque areas can be identified when bone sequestra are formed. In order to be visible in an OPT, a substantial alteration in mineral content and extensive involvement of bone is required and this only occurs in later stages of ORN⁹. Ardran⁷² noted that a 30% loss of bone mineral content is necessary before any radiographic change can be seen.

CT⁷³ shows osseous abnormalities, such as focal lytic areas, cortical interruptions and loss of the spongiosa trabeculation on the symptomatic side, frequently accompanied by soft-tissue thickening. Such a picture may cause difficulties in differential diagnosis between ORN and recurrent tumour⁶⁸. In MRI with gadolinium administration, an abnormal marrow signal, cortical destruction and slight-to-mild irregular enhancement is demonstrated^{35,74-76}. MRI has the advantage of excellent tissue contrast and high spatial resolution⁷⁷.

Bone scintigraphy permits estimation of the extension and location of the lesion. It shows high sensitivity (up to 100%) but low specificity (about 60%) for the diagnosis of ORN⁷⁷. Scintigraphy using ^{99m}Tc-

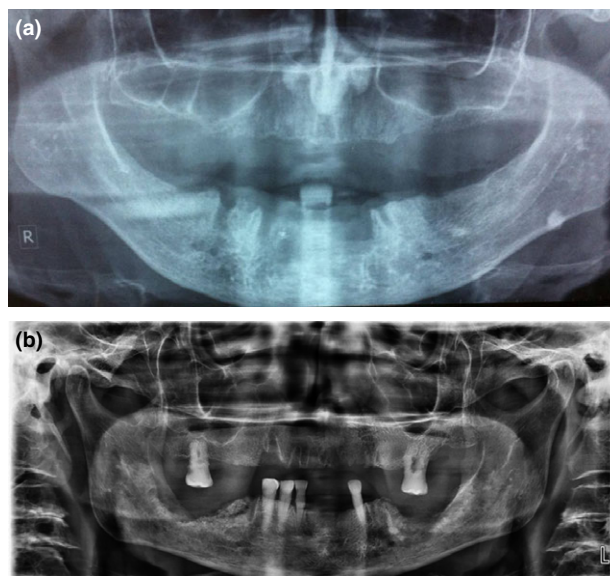


Figure 2. Orthopantomograms of patients who have received radiotherapy (external beam radiotherapy with standard field sizes, conventional fractionation and mean dose 64 Gy) for oropharyngeal cancers. The patients underwent extractions of teeth of the lower jaw after completion of radiotherapy. The orthopantomogram revealed radiolucencies indicating post extraction sockets, which remained visible for longer than 12 months (a), as well as increased radiodensity with mixed radio-opaque/radiolucent lesions, where the radiolucent areas represent bone destruction (b).

marked diphosphonates (^{99m}Tc -MDP) allows highly sensitive depiction of mandibular lesions as a result of their altered phosphate metabolism. Pathophysiological changes in bone can be identified sooner when using ^{99m}Tc -MDP than when using conventional radiography because scan changes reflect osteoblastic activity and good blood flow⁷⁸. Low spatial resolution and over-projection by soft tissues are the major disadvantages of the method, which can be overcome with the use of single photon emission computed tomography (SPECT)⁷⁷. Finally, positron emission tomography (PET), which is a promising method for pretherapeutic assessment of the spread of squamous cell carcinomas, has been advocated as being efficient for differentiating between ORN and tumour recurrence⁷⁹.

Discussion and Conclusion

Irradiation of bone is the main prerequisite for development of ORN. A differential diagnosis is required to exclude recurrence of tumour and bisphosphonate-related osteonecrosis of the jaws. In contrast to the findings of Store and Boysen¹¹, mucosal breakdown or failure of healing is necessary for the diagnosis of ORN^{3,9,10}.

The duration of bone exposure is still a matter of controversy. Some authors did not state the period of time that bone was exposed⁷¹. Other authors recommended a 2-month period of exposed bone before diagnosis^{73,80,81}, or even 3^{19,82,83} to 6^{2,5} months. There are also cases in which a late diagnosis is present. Berger and Symington⁸⁴ reported two late presentations: one 45 years after radium implant therapy; and the other 38 years after external beam treatment.

A very short waiting period can lead to over-diagnosis as mucosal radionecrosis can occur without ORN. Moreover, any surgery and/or extraction usually takes up to 1 month to heal. On the other hand, monitoring a trauma for a longer period (such as 6 months) is contraindicated; intervention prior to this time is certainly needed. For the aforementioned reasons, in order to diagnose ORN, recent literature^{2-4,13-15} indicates that bone exposure should be at least 3 months in duration.

The variability in prevalence of ORN can probably be attributed to differences in the study populations observation periods and existence of pretreatment dental assessment and dental management of cohorts. The literature reports numerous factors which are associated with the risk of ORN development and also affect its prevalence. Total radiation dose, brachytherapy, fractionation, poor oral hygiene, alcohol, tobacco use, dental extractions, tumour size and location, staging and chemotherapy have been highlighted^{7,19,36,44,47,53,85-90}.

The late onset of ORN can be attributed to the late occurrence of oropharyngeal cancers (OPCs) and their complications (mean age of patients over 60 years). This can be explained by the fact that oral tissues tend to undergo prolonged exposure to potential carcinogens with advancing age. In addition, aging cells may be more susceptible to DNA damage. ORN is predominant in the mandible (the ratio between ORN in the mandible and ORN in the maxilla is 24:1)⁹¹. The reason for this could be that the mandible has a restricted localised blood supply, which is often completely within the radiation field, whereas the maxilla has many anastomoses located outside the area of irradiation. Furthermore, mandibular bone density is different from maxillary bone density, and the mandible absorbs a higher amount of radiation during radiotherapy.

The prevalence of ORN has decreased since the 1990s⁹². Recent studies have shown a decrease in the prevalence of ORN to levels lower than 5%. According to Clayman⁵⁴, the application of megavoltage therapy resulted in a significant reduction of the overall prevalence of ORN from 11.8% before 1968 to 5.4% after this time. Wahl⁹³ described similar results and noted a prevalence of ORN of 3% during the period 1997 to 2006. Lee *et al.*⁴³ found that the frequency of ORN was 6.6% among 198 patients with either oral cavity or OPCs treated with radiation between 1990 and 2000. The overall reduction of ORN can be attributed to the advent of megavoltage radiotherapy, improved dental-preventive care and improved radiation techniques, including three-dimensional conformal radiotherapy (3D-CRT) and intensity-modulated radiotherapy (IMRT)^{7,36,38}.

Marx's staging system² is based on the use of, and response to, HBO. The advantages of this protocol include selection of patients who are able to respond to less aggressive treatments, use of minimal levels of HBO, resolution of the disease and preparation of patients' tissues for reconstruction without further HBO^{2,60}.

Even though Marx's staging system is the one still used by surgeons, it has been used less frequently from the mid-1990s to date. The reasons for this are that HBO is nowadays recommended for use as adjuvant therapy, its effectiveness has been questioned and most cases of ORN can be managed successfully without HBO according to the most recent literature^{58,94-96}. The staging system of Epstein *et al.*³² is an improvement, but it is focussed on the presence or absence of a pathological fracture⁵⁸.

The classification system of Notani *et al.*⁵⁹ seems to be more accurate as it is based on: (i) the presence or absence of clinical and radiological signs, in contrast to other systems that are non-specific and are partly based on patients' subjective interpretation; and (ii) pretreatment evaluation, not on treatment response or

refractoriness. It is also simple and easily recalled⁹⁷. (For review see Chronopoulos⁹⁸.)

During the past 80 years, a number of theories about the origin of ORN have been proposed. Despite the controversy, the majority of authors agree that prerequisites for the diagnosis of ORN are: (i) previous irradiation of the affected bone; (ii) absence of recurrent tumour; (iii) presence of mucosal breakdown or failure of healing, resulting in bone exposure; and (iv) 'necrosis' of the overlying bone. The presence of pathological fracture, fistula formation or cellulitis is not necessary for the diagnosis. Mandibular ORN is predominant over maxillary ORN. ORN can lead to pain, fracture and sequestration of the bone, as well as to fistulae. Although the prevalence of ORN has decreased to levels lower than 5%, it still remains a pernicious complication of radiotherapy and a challenge to the clinician because of difficulty in its management. Owing to the severity of ORN and the difficulties in its early and accurate diagnosis and treatment, increased awareness of this complex entity among clinicians is desirable, with the aim to prevent its appearance or the development of severe complications. Further research is required in order to clarify its complex etiology, and guide new treatment strategies.

Acknowledgements

This review is included in the doctoral thesis of the first author, entitled 'Clinical presentation and risk factors of osteoradionecrosis'.

Patient data were anonymised and de-identified before analysis. The clinical photograph and three radiographs were derived from the archive of the Department of Oral and Maxillofacial Surgery in Munich (LMU).

Conflicts of interest

We wish to confirm that there are no known conflicts of interest associated with this publication and there has been no significant financial support for this work that could have influenced its outcome. There was no funding received for this study.

REFERENCES

1. Regaud C. Sur la sensibilité du tissu osseux normal vis-a-vis des rayons X et gamma et sur la mecanisme de l'osteoradionecrose. *CR Soc Boil* 1922 87: 629-932.
2. Marx RE. Osteoradionecrosis; a new concept of its pathophysiology. *J Oral Maxillofac Surg* 1983 41: 283-288.
3. Marx RE, Johnson RP. Studies in the radiobiology of osteoradionecrosis and their clinical significance. *Oral Surg Oral Med Oral Pathol* 1987 64: 379-390.
4. Teng MS, Futran ND. Osteoradionecrosis of the mandible. *Curr Opin Otolaryngol Head Neck Surg* 2005 13: 217-221.
5. Marx RE. A new concept in the treatment of osteoradionecrosis. *J Oral Maxillofac Surg* 1983 41: 351-357.
6. Ewing J. Radiation osteitis. *Acta Radiol* 1926 6: 399-412.
7. Jereczek-Fossa BA, Orecchia R. Radiotherapy-induced mandibular bone complications. *Cancer Treat Rev* 2002 28: 65-74.
8. Guttenberg SA. Osteoradionecrosis of the jaw. *Am J Surg* 1974 127: 326-332.
9. Epstein JB, Rea G, Wong FL *et al.* Osteonecrosis-study of the relationship of dental extractions in patients receiving radiotherapy. *Head Neck Surg* 1987 10: 48-54.
10. Widmark G, Sagne S, Heikel P. Osteoradionecrosis of the jaws. *Int J Oral Maxillofac Surg* 1989 18: 302-306.
11. Store G, Boysen M. Mandibular osteoradionecrosis: clinical behavior and diagnostic aspects. *Clin Otolaryngol* 2000 25: 378-384.
12. Wong JK, Wood RE, McLean M. Conservative management of osteoradionecrosis. *Oral Surg Oral Med Oral Pathol Oral Radiol Endod* 1997 84: 16-21.
13. London SD, Park SS, Gampper TJ *et al.* Hyperbaric oxygen for the management of radionecrosis of bone and cartilage. *Laryngoscope* 1998 108: 1291-1296.
14. Pitak-Arnop P, Sader R, Dhanuthai K *et al.* Management of osteoradionecrosis of the jaws: an analysis of evidence. *Eur J Surg Oncol* 2008 34: 1123-1134.
15. Khojastepour L, Bronoosh P, Zeinalzade M. Mandibular bone changes induced by head and neck radiotherapy. *Indian J Dent Res* 2012 23: 774-777.
16. Thorn JJ, Hansen HS, Specht L *et al.* Osteoradionecrosis of the jaws: clinical characteristics and relation to the field of irradiation. *J Oral Maxillofac Surg* 2000 58: 1088-1093.
17. Monnier Y, Broome M, Betz M *et al.* Mandibular osteoradionecrosis in squamous cell carcinoma of the oral cavity and oropharynx: incidence and risk factors. *Otolaryngol Head Neck Surg* 2011 144: 726-732.
18. Chrcanovic BR, Reher P, Sousa AA *et al.* Osteoradionecrosis of the jaws—a current overview—part 1: Physiopathology and risk and predisposing factors. *Oral Maxillofac Surg* 2010 14: 3-16.
19. Morrish RB, Chan E, Silverman S *et al.* Osteoradionecrosis in patients irradiated for head and neck carcinoma. *Cancer* 1981 47: 1980-1983.
20. Watson WL, Scarborough JE. Osteoradionecrosis in intraoral cancer. *Am J Roentgenol* 1938 40: 524-534.
21. Martin HE, Sugarbaker EL. Cancer of the floor of the mouth. *Surg Gynecol Obstet* 1940 71: 347-359.
22. MacComb WS. Necrosis in treatment of intraoral cancer by radiation therapy. *Am J Roentgenol Radium Ther Nucl Med* 1962 87: 431-440.
23. MacDougall JA, Evans AM, Lindsay RK. Osteoradionecrosis of the mandible and its treatments. *Am J Surg* 1963 106: 816-818.
24. Grant BP, Fletcher GH. Analysis of complications following megavoltage therapy for squamous cell carcinomas of the tonsillar area. *Am J Roentgenol Radium Ther Nucl Med* 1966 96: 28-36.
25. Rahn AO, Drane JB. Dental aspects of the problems, care and treatment of the irradiated oral cancer patient. *J Am Dent Assoc* 1967 74: 957-966.
26. Rankow RM, Weissman B. Osteoradionecrosis of the mandible. *Ann Otol Rhinol Laryngol* 1971 80: 603-611.
27. Wang CC. Management and prognosis of squamous cell carcinoma of the tonsillar region. *Radiology* 1972 104: 667-671.
28. Cheng VST, Wang CC. Osteoradionecrosis of the mandible resulting from external megavoltage radiation therapy. *Radiology* 1974 112: 685-689.

29. Marciani RD, Plezia RA. Osteoradionecrosis of the mandible. *J Oral Surg* 1974 32: 435–440.
30. Bedwinek JM, Shukovsky LJ, Fletcher GH *et al.* Osteoradionecrosis in patients treated with definite radiotherapy for squamous cell carcinoma of the oral cavity and naso- and oropharynx. *Radiology* 1976 119: 665–667.
31. Murray CG, Herson J, Daly TE *et al.* Radiation necrosis of the mandible: a 10 year study. Part I. Factors influencing the onset of necrosis. *Int J Radiat Oncol Biol Phys* 1980 6: 543–548.
32. Epstein JB, Wong FLW, Stevenson-Moore P. Osteoradionecrosis: clinical experience and a proposal for classification. *J Oral Maxillofac Surg* 1987 45: 104–110.
33. Withers HR, Peters LJ, Taylor JM *et al.* Late normal tissue sequelae from radiation therapy for carcinoma of the tonsil: patterns of fractionation study of radiobiology. *Int J Radiat Oncol Biol Phys* 1995 33: 563–568.
34. Turner SL, Slevin NJ, Gupta NK *et al.* Radical external beam radiotherapy for 333 squamous carcinomas of the oral cavity—evaluation of late morbidity and a watch policy for the clinically negative neck. *Radiother Oncol* 1996 41: 21–29.
35. Storey MR, Garden AS, Morrison WH *et al.* Postoperative radiotherapy for malignant tumors of the submandibular gland. *Int J Radiat Oncol Biol Phys* 2001 51: 952–958.
36. Reuther T, Schuster T, Mende U *et al.* Osteoradionecrosis of the jaws as a side effect of radiotherapy of head and neck tumour patients—a report of a thirty year retrospective review. *Int J Oral Maxillofac Surg* 2003 32: 289–295.
37. Oh HK, Chambers MS, Garden AS *et al.* Risk of osteoradionecrosis after extraction of impacted third molars in irradiated head and neck cancer patients. *J Oral Maxillofac Surg* 2004 62: 139–144.
38. Studer G, Gratz KW, Glanzmann C. Osteoradionecrosis of the mandibula in patients treated with different fractionations. *Strahlenther Onkol* 2004 180: 233–240.
39. Ben-David MA, Diamante M, Radawski JD *et al.* Lack of osteoradionecrosis of the mandible after intensity – modulated radiotherapy for head and neck cancer: likely contributions of both dental care and improved distributions. *Int J Radiat Oncol Biol Phys* 2007 68: 396–402.
40. Jham BC, Reis PM, Miranda EL *et al.* Oral health status of 207 head and neck cancer patients before, during and after radiotherapy. *Clin Oral Invest* 2008 12: 19–24.
41. Katsura K, Sasai K, Sato K *et al.* Relationship between oral health status and development of osteoradionecrosis of the mandible: a retrospective longitudinal study. *Oral Surg Oral Med Oral Pathol Oral Radiol Endod* 2008 105: 731–738.
42. Gomez DR, Zhung JE, Gomez J *et al.* Intensity-modulated radiotherapy in postoperative treatment of oral cavity cancers. *Int J Radiat Oncol Biol Phys* 2009 73: 1096–1103.
43. Ij Lee, Koom WS, Lee CG *et al.* Risk factors and dose-effect relationship for mandibular osteoradionecrosis in oral and oropharyngeal cancer patients. *Int J Radiat Oncol Biol Phys* 2009 75: 1084–1091.
44. Stenson KM, Kunnavakkam R, Cohen EE *et al.* Chemoradiation for patients with advanced oral cavity cancer. *Laryngoscope* 2010 120: 93–99.
45. Gomez DR, Estilo CL, Wolden SL *et al.* Correlation of osteoradionecrosis and dental events with dosimetric parameters in intensitymodulated radiation therapy for head-and-neck cancer. *Int J Radiat Oncol Biol Phys* 2011 81: 207–213.
46. Crombie AK, Farah C, Tripcony L *et al.* Primary chemoradiotherapy for oral cavity squamous cell carcinoma. *Oral Oncol* 2012 48: 1014–1018.
47. Niewald M, Fleckenstein J, Mang K *et al.* Dental status, dental rehabilitation procedures, demographic and oncological data as potential risk factors for infected osteoradionecrosis of the lower jaw after radiotherapy for oral neoplasms: a retrospective evaluation. *Radiat Oncol* 2013 8: 227.
48. Tsai CJ, Hofstede TM, Sturgis EM *et al.* Osteoradionecrosis and radiation dose to the mandible in patients with oropharyngeal cancer. *Int J Radiat Oncol Biol Phys* 2013 85: 415–420.
49. Daly TE, Drane JB, MacComb WS. Management of problems of the teeth and jaw in patients undergoing irradiation. *Am J Surg* 1972 124: 539–542.
50. Grötz KA, Riesenbeck D, Brahm R *et al.* Chronic radiation effects on dental hard tissue (radiation caries). Classification and therapeutic strategies. *Strahlenther Onkol* 2001 177: 96–104.
51. Almazroo SA, Woo SB. Bisphosphonate and non-bisphosphonate-associated osteonecrosis of the jaw: a review. *J Am Dent Assoc* 2009 140: 864–875.
52. Mendenhall WM. Mandibular osteoradionecrosis. *J Clin Oncol* 2004 22: 4867–4868.
53. Hao SP, Chen HC, Wei FC *et al.* Systematic management of osteoradionecrosis in the head and neck cancer. *Laryngoscope* 1999 109: 1324–1327.
54. Clayman L. Management of dental extractions in irradiated jaws: a protocol without hyperbaric oxygen therapy. *J Oral Maxillofac Surg* 1997 55: 275–281.
55. Coffin F. The incidence and management of osteoradionecrosis of the jaws following head and neck radiotherapy. *Br J Radiol* 1983 56: 851–885.
56. Morton ME, Simpson W. The management of osteoradionecrosis of the jaws. *Br J Oral Maxillofac Surg* 1986 24: 332–341.
57. Glanzmann C, Gratz KW. Radionecrosis of the mandibula: a retrospective analysis of the incidence and risk factors. *Radiother Oncol* 1995 36: 94–100.
58. Schwartz HC, Kagan AR. Osteoradionecrosis of the mandible: scientific basis for clinical staging. *Am J Clin Oncol* 2002 25: 168–171.
59. Notani K, Yamazaki Y, Kitada H *et al.* Management of mandibular osteoradionecrosis corresponding to the severity of osteoradionecrosis and the method of radiotherapy. *Head Neck* 2003 25: 181–186.
60. Peleg M, Lopez EA. The treatment of osteoradionecrosis of the mandible: the case for hyperbaric oxygen and bone graft reconstruction. *J Oral Maxillofac Surg* 2006 64: 956–960.
61. Baker SR. Management of osteoradionecrosis of the mandible with myocutaneous flaps. *J Surg Oncol* 1983 24: 282–289.
62. Nakatsuka T, Harii K, Yamada A *et al.* Surgical treatment of mandibular osteoradionecrosis: versatility of the scapular osteocutaneous flap. *Scand J Plast Reconstr Hand Surg* 1996 30: 291–298.
63. Saha AR, Cordeiro PG, Hidalgo DA *et al.* Resection and immediate microvascular reconstruction in the management of osteoradionecrosis of the mandible. *Head Neck* 1997 19: 406–411.
64. Oh HK, Chambers MS, Martin JW *et al.* Osteoradionecrosis of the mandible: treatment outcomes and factors influencing the progress of osteoradionecrosis. *J Oral Maxillofac Surg* 2009 67: 1378–1386.
65. Jacobson AS, Buchbinder D, Hu K *et al.* Paradigm shifts in the management of osteoradionecrosis of the mandible. *Oral Oncol* 2010 46: 795–801.
66. Mücke T, Konen M, Wagenpfeil S *et al.* Low-dose preoperative chemoradiation therapy compared with surgery alone with or without postoperative radiotherapy in patients with head and neck carcinoma. *Ann Surg Oncol* 2011 18: 2739–2747.
67. Mücke T, Koschinski J, Wagenpfeil S *et al.* Functional outcome after different oncological interventions in head and neck cancer patients. *J Cancer Res Clin Oncol* 2011 138: 371–376.

68. Hermans R, Fossion E, Ioannides C *et al.* CT findings in osteoradionecrosis of the mandible. *Skeletal Radiol* 1996 25: 31–36.
69. Miles DA. Imaging inflammatory disorders of the jaw: simple osteitis to generalised osteomyelitis. *Oral Maxillofac Surg Clin North Am* 1992 1: 207–221.
70. Niebel HH, Neeman EW. Dental aspects of osteoradionecrosis. *Oral Surg Oral Med Oral Pathol* 1957 10: 1011–1024.
71. Epstein JB, Wong FLW, Dickens A *et al.* Bone and gallium scans in postradiotherapy osteonecrosis of the jaw. *Head Neck* 1992 14: 288–292.
72. Ardran G. Bone destruction not demonstrable by radiography. *Br J Radiol* 1951 24: 107–109.
73. Tobias JS, Thomas PRM. *Current Radiation Oncology*. London: Arnold; 1996. p. 144–177.
74. Fujita M, Harada K, Masaki N *et al.* MR imaging of osteoradionecrosis of the mandible following radiotherapy for head and neck cancers. *Nihon Igaku Hoshasen Gakkai Zasshi* 1991 51: 892–900.
75. Rabin BM, Meyer JR, Berlin JW *et al.* Radiation-induced changes in the central nervous system and head and neck. *Radiographics* 1996 16: 1055–1072.
76. Yoshioka H, Nakano T, Kandatsu S *et al.* MR imaging of radiation osteitis in the sacro-iliac joints. *Magn Reson Imaging* 2000 18: 125–128.
77. Bachmann G, Rossler R, Klett R *et al.* The role of magnetic resonance imaging and scintigraphy in the diagnosis of pathologic changes of the mandible after radiation therapy. *Int J Oral Maxillofac Surg* 1996 25: 189–195.
78. Alexander JM. Radionuclide bone scanning in the diagnosis of lesions of the maxillofacial region. *J Oral Surg* 1976 34: 249–256.
79. Minn H, Aitasalo K, Happonen RP. Detection of cancer recurrence in irradiated mandible using positron emission tomography. *Eur Arch Otorhinolaryngol* 1993 250: 312–315.
80. Beumer J, 3rd, Curtis T, Harrison RE. Radiation therapy of the oral cavity: sequelae and management, part 2. *Head Neck Surg* 1979 1: 392–408.
81. Hutchinson IL, Colpe M, Delpy DT *et al.* The investigation of osteoradionecrosis of the mandible by near infrared spectroscopy. *Br J Oral Maxillofac Surg* 1990 28: 150–154.
82. Beumer J, 3rd, Harrison R, Sanders B *et al.* Pre-radiation dental extractions and the incidence of bone necrosis. *Head Neck Surg* 1983 5: 514–521.
83. Harris M. The conservative management of osteoradionecrosis of the mandible with ultrasound therapy. *Br J Oral Maxillofac Surg* 1992 30: 313–318.
84. Berger RP, Symington JM. Long-term clinical manifestation of osteoradionecrosis of the mandible: report of two cases. *J Oral Maxillofac Surg* 1990 48: 82–84.
85. Kluth EV, Jain PR, Stuchell RN *et al.* A study of factors contributing to the development of osteoradionecrosis of the jaws. *J Prosthet Dent* 1988 59: 194–201.
86. Jeremic B, Shibamoto Y, Milicic B *et al.* Hyperfractionated radiation therapy with or without concurrent low-dose daily cisplatin in locally advanced squamous cell carcinoma of the head and neck: a prospective randomized trial. *J Clin Oncol* 2000 18: 1458–1464.
87. Denis F, Garaud P, Bardet E *et al.* Late toxicity results of the GORTEC 94-01 randomized trial comparing radiotherapy with concomitant radiochemotherapy for advanced-stage oropharynx carcinoma: comparison of LENT/SOMA, RTOG/EORTC, and NCI-CTC scoring systems. *Int J Radiat Oncol Biol Phys* 2003 55: 93–98.
88. Cooper JS, Pajak TF, Forastiere AA *et al.* Postoperative concurrent radiotherapy and chemotherapy for high-risk squamous-cell carcinoma of the head and neck. *N Engl J Med* 2004 350: 1937–1944.
89. Budach V, Stuschke M, Budach W *et al.* Hyperfractionated accelerated chemoradiation with concurrent fluorouracil-mitomycin is more effective than dose-escalated hyperfractionated accelerated radiation therapy alone in locally advanced head and neck cancer: final results of the radiotherapy cooperative clinical trials group of the German Cancer Society 95-06 Prospective Randomized Trial. *J Clin Oncol* 2005 23: 1125–1135.
90. Semrau R, Mueller RP, Stuetzer H *et al.* Efficacy of intensified hyperfractionated and accelerated radiotherapy and concurrent chemotherapy with carboplatin and 5-fluorouracil: updated results of a randomized multicentric trial in advanced head-and-neck cancer. *Int J Radiat Oncol Biol Phys* 2006 64: 1308–1316.
91. Perrier M, Moeller P. Osteoradionecrosis. A review of the literature. *Schweiz Monatsschr Zahnmed* 1994 104: 271–277.
92. Berger A, Bensadoun RJ. Normal tissue tolerance to external beam radiation therapy: the mandible. *Cancer Radiother* 2010 14: 295–300.
93. Wahl MJ. Osteoradionecrosis prevention myths. *Int J Radiat Oncol Biol Phys* 2006 64: 661–669.
94. Annane D, Depondt J, Aubert P *et al.* Hyperbaric oxygen therapy for radionecrosis of the jaw—a randomized, placebo-controlled, double-blind trial from the ORN96 study group. *J Clin Oncol* 2004 22: 4893–4900.
95. Bessereau J, Annane D. Treatment of osteoradionecrosis of the jaw: the case against the use of hyperbaric oxygen. *J Oral Maxillofac Surg* 2010 68: 1907–1910.
96. Pitak-Arnnop P, Hemprich A, Dhanuthai K *et al.* A systematic review in 2008 did not show value of hyperbaric oxygen therapy for osteoradionecrosis. *J Oral Maxillofac Surg* 2010 68: 2644–2645.
97. Shaw RJ, Dhanda J. Hyperbaric oxygen in the management of late radiation injury to the head and neck. Part I: Treatment. *Br J Oral Maxillofac Surg* 2011 49: 2–8.
98. Chronopoulos A. (2015). Clinical presentation and risk factors of osteoradionecrosis (Doctoral dissertation). Available from: <https://edoc.ub.uni-muenchen.de/18089/> and https://edoc.ub.uni-muenchen.de/18089/1/Chronopoulos_Aristeidis.pdf (Persistent Identifier URN: urn:nbn:de:bvb:19-180892). Accessed 15 April 2015.

Correspondence to:
 Aristeidis Chronopoulos, DDS, Oral Surgeon, PhD,
 Panagiotou Kaisari 19, Kalamata 24133, Greece.
 Emails: arisx8@hotmail.com,
 ar.chronopoulos@gmail.com