



Since January 2020 Elsevier has created a COVID-19 resource centre with free information in English and Mandarin on the novel coronavirus COVID-19. The COVID-19 resource centre is hosted on Elsevier Connect, the company's public news and information website.

Elsevier hereby grants permission to make all its COVID-19-related research that is available on the COVID-19 resource centre - including this research content - immediately available in PubMed Central and other publicly funded repositories, such as the WHO COVID database with rights for unrestricted research re-use and analyses in any form or by any means with acknowledgement of the original source. These permissions are granted for free by Elsevier for as long as the COVID-19 resource centre remains active.



## Review article

# Multiple sclerosis relapse after COVID-19 vaccination: A case report-based systematic review

Fardin Nabizadeh<sup>a,b</sup>, Elham Ramezannezhad<sup>a,c</sup>, Kimia Kazemzadeh<sup>d,e</sup>, Elham Khalili<sup>f,g</sup>,  
Elham Moases Ghaffary<sup>h</sup>, Omid Mirmosayyeb<sup>h,\*</sup>

<sup>a</sup> Neuroscience Research Group (NRG), Universal Scientific Education and Research Network (USERN), Tehran, Iran

<sup>b</sup> School of Medicine, Iran University of Medical Sciences, Tehran, Iran

<sup>c</sup> School of Medicine, Isfahan University of Medical Sciences, Isfahan, Iran

<sup>d</sup> Students' Scientific Research Center, Tehran University of Medical Sciences, Tehran, Iran

<sup>e</sup> Universal Scientific Education and Research Network (USERN), Tehran, Iran

<sup>f</sup> Student Research Committee, Faculty of Medicine, Hormozgan University of Medical Sciences, Bandar Abbas, Iran

<sup>g</sup> Universal Scientific Education and Research Network (USERN), Bandar Abbas, Hormozgan, Iran

<sup>h</sup> Isfahan Neurosciences Research Center, Isfahan University of Medical Sciences, Isfahan, Iran



## ARTICLE INFO

## Keywords:

Multiple sclerosis  
COVID-19 vaccination  
Relapse  
Exacerbation

## ABSTRACT

**Background:** Concerns about vaccination increased among patients with multiple sclerosis (MS) regarding side effects, efficacy, and disease exacerbation. Recently there were reports of MS relapses after the COVID-19 vaccination, which emerged the safety concerns. Therefore, we aimed to perform a systematic review of case reports and case series studies to investigate the MS relapses after COVID-19 vaccination with most details.

**Methods:** We systematically searched three databases, including PubMed, Scopus, and Web of Science, in February 2022. Case reports and case series which reported relapse after COVID-19 vaccination in MS patients were eligible to include in our study.

**Results:** Seven studies were included in our systematic review after the abstract and full-text screening with a total of 29 cases. The mean duration between COVID-19 vaccination and relapse appearance was  $9.48 \pm 7.29$  days. Among patients, 22 cases experienced relapse after their first dosage of the COVID-19 vaccine, one after the second dose, and five after the booster dose. The type of vaccine was unknown for one patient. The most common symptoms of relapses were sensory deficits (paresthesia, numbness, dysesthesia, and hypoesthesia) and weakness.

**Conclusion:** Overall, the COVID-19 vaccination may trigger relapses in some MS patients, but as the infection itself can stimulate relapse, the benefit of vaccination outweighs its risk in this population, and mass vaccination against COVID-19, especially in MS patients, should be continued and encouraged.

## 1. Introduction

The severe acute respiratory syndrome coronavirus 2 (SARS-CoV-2), which is responsible for coronavirus infection, was declared a worldwide pandemic by the World Health Organization (WHO) in March 2020 [1]. Vaccination against COVID-19 is the primary long-term strategy to stop this pandemic globally [2]; thus, worldwide initiatives were done to develop vaccines against this pandemic which has claimed over 6 million lives and affected over 500 million people as of April 2022 [3]. Patients with comorbidities, especially autoimmune diseases, have been considered at higher risk to develop a more severe form of the disease

[4]. A systematic review and meta-analysis in 2021 showed the pooled prevalence of suspected covid-19 in patients with multiple sclerosis (MS) was 4%, hospitalization was 10%, and death in hospitalized patients was 4% [5].

MS is the most prevalent disabling permanently neurological disease among young adults and is associated with high socioeconomic cost and diminished quality of life [6]. Infectious diseases are the leading cause of death and a common cause of comorbidity among patients with MS and may cause the exacerbation of MS symptoms; thus, vaccination in patients with MS should be purposed as a general policy to decrease the risk of infections [6].

\* Corresponding author.

E-mail address: [omid.mirmosayyeb@gmail.com](mailto:omid.mirmosayyeb@gmail.com) (O. Mirmosayyeb).

<https://doi.org/10.1016/j.jocn.2022.08.012>

Received 2 June 2022; Accepted 14 August 2022

Available online 19 August 2022

0967-5868/© 2022 Elsevier Ltd. All rights reserved.

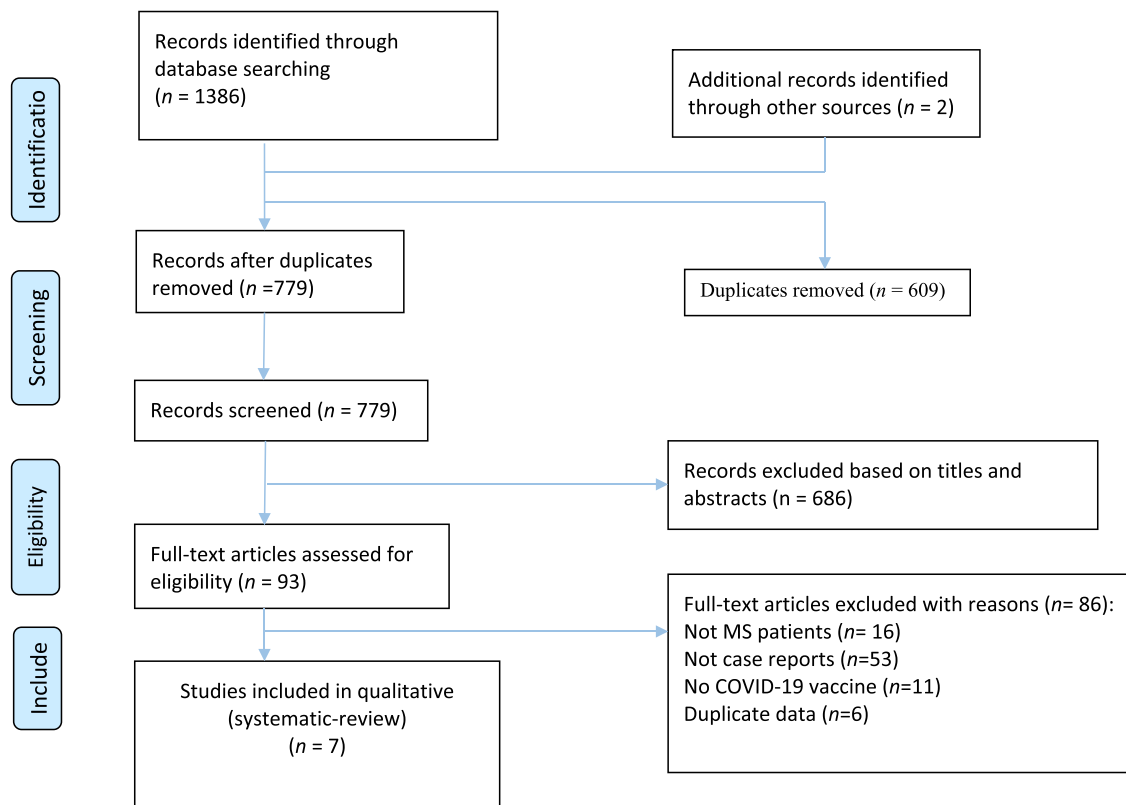


Fig. 1. PRISMA flow diagram depicting the flow of information through the different phases of a systematic review.

Concerns about vaccination increased among health care providers and patients with MS regarding side effects, efficacy, and disease exacerbation [7]. Neurological manifestations are rare complications of COVID-19 infection and vaccination [8]. Among neurological manifestations, autoimmune disorders which affect the nervous system are rare (<0.1%) after COVID-19 vaccination [9]. In another study, after the first dose of Pfizer BioNTech and AstraZeneca vaccines, the most common complications were Guillain-Barré syndrome and Bell's palsy [10]. Recently there were reports of MS relapses after the COVID-19 vaccination, which emerged safety concerns [11–13]. A study by Fragoso et al. revealed that patients with no evidence of MS activity and no change in their medications developed a new relapse with new lesions on magnetic resonance imaging (MRI) along with increased disability following their first dose of AstraZeneca vaccine for COVID-19 [14]. Therefore, we aimed to perform a systematic review of case reports and case series studies to investigate the MS relapses after COVID-19 vaccination with most details.

## 2. Methods

This study was conducted following preferred reporting items for systematic reviews and meta-analyses (PRISMA) guideline [15].

### 2.1. Search strategy

We systematically searched three databases, including PubMed, Scopus, and Web of Science, in February 2022. Our search strategy included the following terms: (Multiple sclerosis) AND (COVID-19 OR SARS-COV-2 OR corona virus OR Coronavirus Disease OR 2019-nCoV Disease) AND (Vaccination OR Vaccine OR immunization).

### 2.2. Eligibility criteria

All case reports and case series which reported relapse after COVID-

19 vaccination in MS patients were eligible to include in our study. The non-English article, studies with other vaccination for another virus, review papers, and other types of original studies (cohorts, case-control, and clinical trials) were excluded.

### 2.3. Study selection

Two independent reviewers (F.N, K.K) screened the title and abstracts and excluded irrelevant studies. Then the same reviewers checked the full text of the remaining articles to evaluate their eligibility to include in our study.

### 2.4. Data extraction

The same investigators (F.N, K.K) extracted the following information based on a predesigned datasheet: Study the demographic, type of MS, age, sex, MS duration, clinical presentation before relapse, MRI findings, type of COVID-19 vaccination, vaccine dosage, the interval between relapse and vaccination, the clinical presentation of relapse, treatments, and outcomes.

### 2.5. Quality assessments

The quality of included studies was assessed using the Joanna Briggs Institute Critical Appraisal tools for Case Reports independently by two reviewers (F.N, K.K) [16]. The answer to the questions was based on “Yes” or “No” and the score ranged from 0 to 8.

## 3. Results

Our initial search yielded 1386 studies (Fig. 1). After duplicate removing, 779 papers were screened. At this step, 686 articles were excluded via title and abstract evaluation, and the remaining studies underwent full-text review. Finally, seven studies entered our systematic

**Table 1**  
Demographical and clinical findings of the included studies.

Study	Country	Type of MS	Age	Sex	MS disease duration	Clinical presentation of MS before relapse	DMTs	MRI Findings	Type COVID-19 vaccine	Vaccine dosage	Time interval between vaccination and relapse	Relapse clinical presentations	Treatments	Outcome
Lagosz et al. 2022	Poland	NR	64	M	NR	NR	NR	A hypodense lesion in the left frontal-parietal area	NR	NR	1 day	Feeling numbness, worsened mobility in the arms and fatigue	Glucocorticoids	Recovered
Kataria et al. 2022	USA	NR	57	F	6 years	NR	Interferon-beta	Multiple confluent and distinct hyperintense white matter enhancing lesions in both hemispheres on T2-weighted and diffusion-weighted images. Spine MRI was normal.	BNT162b2/PfizerBioNTech	2nd	18 days	Fatigue, involuntary eye movements, numbness, tingling, stiffness in her left upper and lower limbs	Intravenous methylprednisolone and physiotherapy , baclofen	Recovered
Etemadifar et al. 2021	Iran	RRMS	34	F	13 years	optic neuritis and bilateral lower limb paresthesia / paraparesis	Interferon-beta 1a.	Several new periventricular, juxtacortical and brainstem lesions on T2	Sputnik	1st	3 days	Severe right hemiplegia and ataxia	Oral methylprednisolone for 3 weeks	Recovered
Ahadi et al. 2021	Iran	RRMS	42	F	20 years	optic neuritis/ hemiparesis and monoparesis/ paraparesis	Interferon-beta 1b.	Showed numeral periventricular, anterior medullary white matter hyperintensities	Sinopharm	1st	2 days	Progressive paraparesis without paresthesia	Intravenous methylprednisolone	Recovered
Maniscalco et al. 2021	Italy	NR	31	F	5 years	Tinnitus and dizziness	Fingolimod	Three new voluminous enhancing lesions	BNT162b2/PfizerBioNTech	1st	48 hours	Paraesthesia and weakness in her left arm and limbs	Intravenous methylprednisolone	Recovered
Fragoso et al. 2021	Brazil	RRMS	22	F	5 years	NR	Fingolimod	Non-Gd tumefactive lesion	Oxford/AstraZeneca	1st	7 days	Facial paralysis, hemiparesis, ataxia	Pulsotherapy methylprednisolone	Not yet recovered
		RRMS	32	F	2 years	NR	Dimethyl fumarate	New Gd + lesions in the left eye	Oxford/AstraZeneca	1st	10 days	Loss of vision and papillitis in the left eye	Pulsotherapy methylprednisolone	Partial recovered
		SPMS	35	M	3 years	NR	Natalizumab	High lesion load , new lesions	Oxford/AstraZeneca	1st	7 days	Worsening of disability, could not walk, severe weakness of both legs	Oral prednisone	Not yet recovered
		RRMS	30	F	1 year	NR	Natalizumab	New Gd + lesions	Oxford/AstraZeneca	1st	25 days	Right hemiparesis	Pulsotherapy methylprednisolone	Recovered
		RRMS	42	F	3 years	NR	Fingolimod	New Gd+ lesions in spinal cord, T2 level	Oxford/AstraZeneca	1st	15 days	Rapidly progressive weakness in both arms , grade III at its worst	Pulsotherapy methylprednisolone	Recovered
RRMS	35	M	4 years	NR	NR	Teriflunomide	New Gd+ lesions in brainstem	Oxford/AstraZeneca	1st	20 days	Incoordination of right arm and hand	Pulsotherapy methylprednisolone	Not yet recovered	

(continued on next page)

Table 1 (continued)

Study	Country	Type of MS	Age	Sex	MS disease duration	Clinical presentation of MS before relapse	DMTs	MRI Findings	Type COVID-19 vaccine	Vaccine dosage	Time interval between vaccination and relapse	Relapse clinical presentations	Treatments	Outcome
		PPMS	51	M	2 years	NR	NR	New Gd+ lesions in cervical cord	Oxford/AstraZeneca	1st	25 days	Hypoesthesia in both arms	No treatment	Not yet recovered
		RRMS	32	F	6 years	NR	Glatiramer acetate	New Gd+ lesions+ new lesions	Oxford/AstraZeneca	1st	7 days	Motor and sensitive deficits in right leg and foot	Pulsotherapy methylprednisolone	Not yet recovered
Nistri et al. 2021	Italy	NR	48	F	New diagnosis	visual acuity deficit from right eye	NR	Enhancing lesion in the corpus callosum, multiple white matter unenhanced lesions and lesions in the occipital lobe were detected	Oxford/AstraZeneca	1 st	8 days	Visual acuity deficit from right eye	High dose of intravenous methylprednisolone	Recovered
		NR	45	M	9 years	NR	Ocrelizumab	Two new lesions in the temporal gyri and a new spinal cord lesion at T3 level	Oxford/AstraZeneca	1st	3 weeks	Dysesthesia in both legs	Steroids	NR
		NR	54	F	28 years	NR	NR	One enhancing lesion in the spinal cord	Oxford/AstraZeneca	1 st	3 days	Developed hypoesthesia below the T6 level	Intravenous methylprednisolone	Recovered
		NR	66	F	New diagnosis	visual disturbance and postural instability on the right limbs	NR	Multiple white matter lesions, four of them enhancing in the left paratrigonal and periventricular white matter	Oxford/AstraZeneca	1 st	1 week	Visual disturbance and postural instability on the right limbs	Intravenous methylprednisolone	Partial recovered
		NR	42	F	2 years	progressive weakness on the right side of body	Ocrelizumab	Enhancing brain lesion in the right corona radiata	Moderna	1 st	2 weeks	Slight weakness of the left upper limb	NR	NR
		NR	57	M	20 years	NR	NR	Enhancing pontine lesion	Moderna	booster	2 weeks	Severe motor deficit in both legs	Intravenous methylprednisolone	Partial recovered
		NR	49	F	8 years	NR	Dimethyl fumarate	A periventricular lesion and a spinal lesion at C3 level, both enhancing	BNT162b2/PfizerBioNTech	1 st	5 days	Numbness on the left hand and left side of her head	Intravenous methylprednisolone	Recovered
		NR	39	M	7 years	hypoesthesia on left side	Dimethyl fumarate	Three new lesions, two of which were enhancing in the left parietal lobe and in the periventricular white matter	BNT162b2/PfizerBioNTech	1st	10 days	Paresthesia on left leg	Oral steroids	Partial recovered
		NR	39	F	New diagnosis	NR	NR	A new enhancing lesion in the mesencephalon	BNT162b2/PfizerBioNTech	1st	3 days	Dysesthesia on her right hand and foot	Intravenous methylprednisolone	Recovered

(continued on next page)

Table 1 (continued)

Study	Country	Type of MS	Age	Sex	MS disease duration	Clinical presentation of MS before relapse	DMTs	MRI Findings	Type COVID-19 vaccine	Vaccine dosage	Time interval between vaccination and relapse	Relapse clinical presentations	Treatments	Outcome
		NR	60	F	23 years	NR	Dimethyl fumarate	One enhancing brain lesion in the left periventricular white matter	BNT162b2/PfizerBioNTech	1st	2 days	Fatigue and numbness in both legs	NR	NR
		NR	30	F	3 years	optic neuritis	Cladribine	Two enhancing brain lesions, one in the right corona radiata and one with conspicuous oedema in the left centrum semiovale	BNT162b2/PfizerBioNTech	booster	20 days	Language disturbance	NR	NR
		NR	58	F	21 years	NR	NR	A new area with ring enhancement in the white matter of the left frontal lobe	BNT162b2/PfizerBioNTech	1st	3 days	Headache, balance disturbance, urinary incontinence, difficulties in walking and dysphagia	Intravenous methylprednisolone	Recovered
		NR	34	F	3 months	numbness and hyposthenia on her right hand	NR	Three brain enhancing lesion (one right posterior paraventricular and two in the left periventricular white matter) and a new unenhanced lesion on spinal cord	BNT162b2/PfizerBioNTech	booster	4 days	Neck pain and hypoesthesia on right arm	NR	NR
		NR	35	F	16 years	NR	Dimethyl fumarate	Three enhancing lesions in the left temporal lobe and left centrum semiovale	BNT162b2/PfizerBioNTech	booster	1 day	Paresthesia on the left side of body	NR	NR
		NR	54	M	18 years	NR	Teriflunomide	Two ring-enhancing lesions located in the left periventricular white matter	bNT162b2/PfizerBioNTech	1st	1 week	Right hemiparesis	Intravenous methylprednisolone	Recovered
		NR	37	M	2 years	NR	Dimethyl fumarate	A new tumefactive contrast-enhancing lesion in the left fronto-parietal white matter	BNT162b2/PfizerBioNTech	booster	11 days	Weakness on right limbs	Intravenous methylprednisolone	Partial recovered

Abbreviations: NR, Not Reported, RRMS, relapsing remitting multiple sclerosis; SPMS, secondary progressive multiple sclerosis; PPMS, primary progressive multiple sclerosis, DMTs, disease modifying therapies.

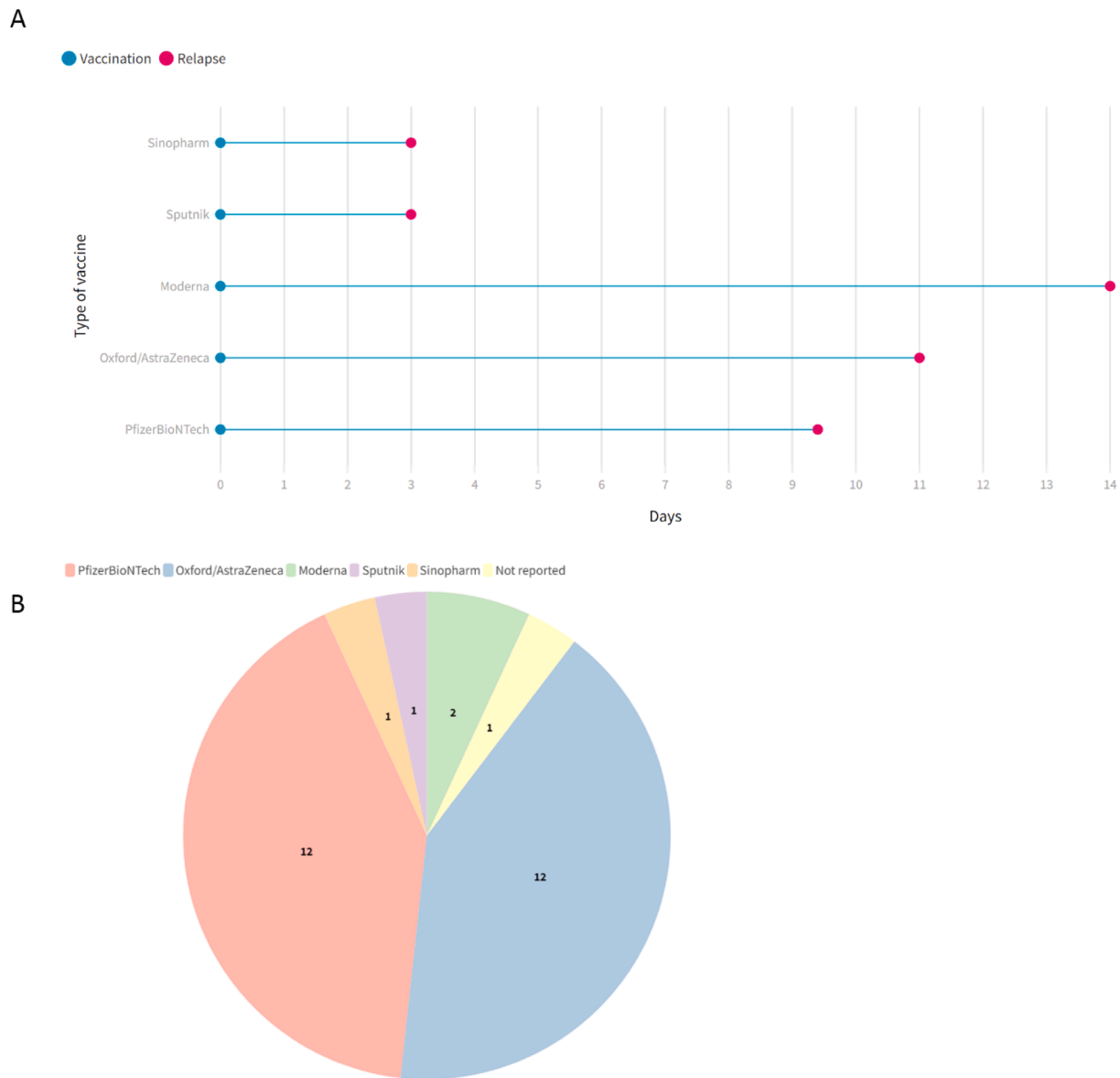


Fig. 2. The mean duration between vaccination and relapse based on type of vaccine (A), and type of COVID-19 vaccine used among cases (B).

review [11–14,17–19]. The demographical and clinical characteristics of included studies are detailed in Table 1. A total of 29 cases with a mean age of  $43.2 \pm 11.5$  and a range [22–66] were included in our study. 68% of the patients were female, and eight cases were reported as RRMS. The mean duration between COVID-19 vaccination and relapse appearance was  $9.48 \pm 7.29$  days (Fig. 2). Twelve patients received Oxford/AstraZeneca, twelve received PfizerBioNTech, two Moderna, and each one received Sputnik and Sinopharm (Fig. 2). Among patients, 22 cases experienced relapse after their first dosage of the COVID-19 vaccine, one after the second dose, and five after the booster dose. The type of vaccine was unknown for one patient. The most common symptoms of relapses were sensory deficits ( $n = 14$ ) (paresthesia, numbness, dysesthesia, and hypoesthesia) and weakness ( $n = 6$ ). After relapse, most of the patients received glucocorticoids, and 13 patients recovered, five partially recovered, and five patients not yet recovered until the end of the study follow-up (see Fig. 3).

The result of the quality assessment using JBI criteria revealed that six studies scored more than 7, and only one study scored 5 (Table 2). The mean JBI score for all included studies was 7.28.

#### 4. Discussion

Although mass vaccination against COVID-19 is the preferred way of controlling the disease, concerns around the long-term safety of these vaccines have remained unclear, in particular in patients with underlying comorbidities [20]. Autoimmune disorders comprise a group of these comorbidities for which vaccination may trigger undesired responses. Post-vaccination relapses in neurological autoimmune disorders such as MS and Guillen Barre have been previously reported with HBV, Influenza, polio, and tetanus vaccines [21,22]. Available COVID-19 vaccines are no exception, and reports of Bell’s palsy, transverse myelitis, Guillen Barre syndrome and MS relapses have emerged [23].

To the current time point, there is no contraindication for COVID-19 vaccination in MS patients except for living attenuated vaccines in patients under immunosuppressive or immunomodulatory regimens [24]. In addition, no vaccine is favored for MS patients [14]. However, reports of relapses after either first or booster doses of COVID-19 vaccines indicate an association between disease pathophysiology and vaccination. In an interval ranging from one to 25 days after vaccination, a portion of MS patients manifested neurological symptoms, with the most common ones being paralysis, visual loss, weakness, and motor deficits.

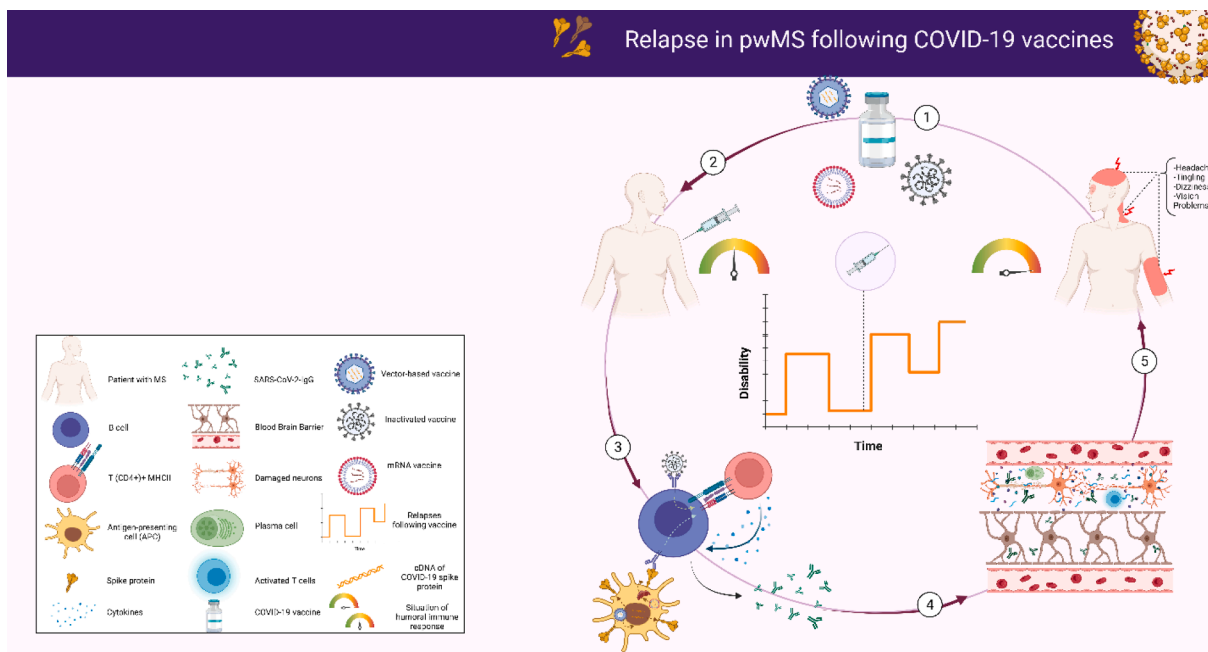


Fig. 3. Mechanism of relapse in patients with MS following COVID-19 vaccination, by BioRender.

**Table 2**  
The Joanna Briggs Institute Critical Appraisal tools for Case Reports.

	Lagosz et al. 2022	Kataria et al. 2022	Etemadifar et al. 2021	Ahadi et al. 2021	Maniscalco et al. 2021	Fragoso et al. 2021	Nistri et al. 2021
Were patient’s demographic characteristics clearly described?	No	Yes	Yes	Yes	Yes	Yes	Yes
Was the patient’s history clearly described and presented as a timeline?	No	No	Yes	Yes	Yes	Yes	No
Was the current clinical condition of the patient on presentation clearly described?	Yes	Yes	Yes	Yes	Yes	Yes	Yes
Were diagnostic tests or assessment methods and the results clearly described?	Yes	Yes	Yes	Yes	Yes	Yes	Yes
Was the intervention(s) or treatment procedure(s) clearly described?	No	Yes	Yes	Yes	Yes	Yes	Yes
Was the post-intervention clinical condition clearly described?	Yes	Yes	Yes	Yes	Yes	Yes	Yes
Were adverse events (harms) or unanticipated events identified and described?	Yes	Yes	Yes	Yes	Yes	Yes	Yes
Does the case report provide takeaway lessons?	Yes	Yes	Yes	Yes	Yes	Yes	Yes
Total rank	5	7	8	8	8	8	7

The extent of immune response in MS patients depends on both individual genetic susceptibility, and the type of vaccine used [13,25].

Cross-reactivity and bystander activation are well-established theories justifying autoimmunity after vaccination. Depending on the vaccine type, one of these mechanisms may be more relevant. In the case of Pfizer, which is an RNA virus coding for spike proteins in lipid membrane without any adjuvant, cross-reactivity may explain the situation as the COVID-19 spike protein antibody is structurally similar to myelin basic protein [25]. Besides, the interaction between spike proteins and Angiotensin-Converting Enzyme 2 (ACE2) receptors located in the Blood-Brain Barrier (BBB) and spinal neurons have been reported in several *in vivo* studies [26]. This is true for Coronavirus itself, as it can cross BBB either with transcytosis using ACE2 receptors or reach brain parenchyma via the olfactory bulb [14]. However, autoimmunity after the AstraZeneca vaccine is less likely to happen because of this cross-reactivity. AstraZeneca has an adjuvant (MF59) that has clearly been shown to induce inflammation by secretion of cytokines, including IL-6, IL-8, chemokine CCL-2, CCL-3, and CCL-4 [27]. The adjuvant can activate the Toll-Like Receptor (TLR) that per se prompts nuclear factor kappa B (NF-κB) phosphorylation. NF-κB is a transcription factor of up to

1500 inflammatory genes, including cytokines and chemokines. These molecules supply T and B cells with adequate stimuli to recognize their specific antigen and initiate clonal activation. In MS patients, these inflammatory molecules can interfere with control over self-reacting clones and activate unrelated lymphocytes, something that is called bystander activation [28,29]. In this way, clonal expansion occurs, and the disease relapses.

Despite the fact that these relapses were temporally associated with vaccine administration, with current studies, it is impossible to disentangle post-vaccination relapses from the relapses that would have manifested regardless of COVID-19 vaccination [13]. In a study on 555 MS patients, 2.1% of patients receiving the first dose and 1.6% with the second dose experienced relapses; however, no difference in the relapse rate was highlighted when the results were compared to previous years [30]. This study was limited to a short follow-up period and therefore its results should be interpreted with caution. More studies are warranted to show a causal association.

Overall, the COVID-19 vaccination may trigger relapses in some MS patients but as the infection itself can stimulate relapse, the benefit of vaccination outweighs its risk in this population, and mass vaccination



against COVID-19 especially in MS patients should be continued and encouraged [31]. In the meanwhile, most of the relapsed cases were fully recovered after receiving methylprednisolone showing the relapse can be controlled without consequences [11,13,14,17,18].

## Funding

We do not have any financial support for this study.

## Ethical approval

Since the data in this paper were obtained from the PPMI database ([ppmi.loni.usc.edu](http://ppmi.loni.usc.edu)), it does not include any research involving human or animal subjects.

## Availability of data and material

The datasets analyzed during the current study are available upon request with no restriction.

## Consent for publication

This manuscript has been approved for publication by all authors.

## Author contributions

All the authors listed in the manuscript have participated actively in preparing the final version of this case report.

## Declaration of Competing Interest

The authors declare that they have no known competing financial interests or personal relationships that could have appeared to influence the work reported in this paper.

## References

- [1] Hassaniyad M, Farshidi H, Gharibzadeh A, Bazram A, Khalili E, Noormandi A, et al. Efficacy and safety of favipiravir plus interferon-beta versus lopinavir/ritonavir plus interferon-beta in moderately ill patients with COVID-19: A randomized clinical trial. *J Med Virol* 2022;94(7):3184–91.
- [2] Huang Y, Rodgers WJ, Middleton RM, Baheerathan A, Tuite-Dalton KA, Ford DV, et al. Willingness to receive a COVID-19 vaccine in people with multiple sclerosis – UK MS Register survey. *Multiple Scler Related Disorders* 2021;55:103175.
- [3] Hu B, Guo H, Zhou P, Shi ZL. Characteristics of SARS-CoV-2 and COVID-19. *Nat Rev Microbiol* 2021;19(3):141–54.
- [4] Fang L, Karakiulakis G, Roth M. Are patients with hypertension and diabetes mellitus at increased risk for COVID-19 infection? *Lancet Respir Med* 2020;8(4):e21.
- [5] Moghadasi AN, Mirmosayyeb O, Barzegar M, Sahraian MA, Ghajarzadeh M. The prevalence of COVID-19 infection in patients with multiple sclerosis (MS): a systematic review and meta-analysis. *Neurol Sci* 2021;42(8):3093–9.
- [6] Persson R, Lee S, Ulcickas Yood M, Wagner CM, Minton N, Niemcryk S, et al. Infections in patients diagnosed with multiple sclerosis: a multi-database study. *Mult Scler Relat Disord* 2020;41:101982.
- [7] Yazdani A, Mirmosayyeb O, Ghaffary EM, Hashemi MS, Ghajarzadeh M. COVID-19 vaccines and patients with multiple sclerosis: willingness, unwillingness and hesitancy: a systematic review and meta-analysis. *Neurol Sci* 2022;43(7):4085–94.
- [8] Patone M, Handunnetthi L, Saatci D, Pan J, Katikireddi SV, Razvi S, et al. Neurological complications after first dose of COVID-19 vaccines and SARS-CoV-2 infection. *Nat Med* 2021;27(12):2144–53.
- [9] Thomas SJ, Moreira ED, Kitchin N, Absalon J, Gurtman A, Lockhart S, et al. Safety and efficacy of the BNT162b2 mRNA covid-19 vaccine through 6 months. *N Engl J Med* 2021;385(19):1761–73.
- [10] Baden LR, El Sahly HM, Essink B, Kotloff K, Frey S, Novak R, et al. Efficacy and safety of the mRNA-1273 SARS-CoV-2 vaccine. *N Engl J Med* 2021;384(5):403–16.
- [11] Etemadifar M, Sigari AA, Sedaghat N, Salari M, Nouri H. Acute relapse and poor immunization following COVID-19 vaccination in a rituximab-treated multiple sclerosis patient. *Hum Vaccin Immunother* 2021;17(10):3481–3.
- [12] Kataria H, Hart CG, Alizadeh A, Cossoy M, Kaushik DK, Bernstein CN, et al. Neuregulin-1 beta 1 is implicated in pathogenesis of multiple sclerosis. *Brain* 2021;144(1):162–85.
- [13] Nistri R, Barbuti E, Rinaldi V, Tufano L, Pozzilli V, Ianniello A, et al. Case report: multiple sclerosis relapses after vaccination against SARS-CoV2: a series of clinical cases. *Front Neurol* 2021;12:765954.
- [14] Fragoso YD, Gomes S, Gonçalves MVM, Mendes Junior E, Oliveira BES, Rocha CF, et al. New relapse of multiple sclerosis and neuromyelitis optica as a potential adverse event of AstraZeneca AZD1222 vaccination for COVID-19. *Mult Scler Relat Disord* 2022;57:103321.
- [15] Moher D, Liberati A, Tetzlaff J, Altman DG. Preferred reporting items for systematic reviews and meta-analyses: the PRISMA statement. *BMJ*. 2009;339: b2535.
- [16] M P. Moola S MZ, Tufanaru C, Aromataris E, Sears K, Sfetcu R, Currie M, Lisy K, Qureshi R, Mattis P. *JB Manual for Evidence Synthesis*. JBI Manual for Evidence Synthesis. 2020.
- [17] Łagosz P, Biegus J, Gruszka E, Zymliński R. The surprising course of multiple sclerosis relapse in a patient after SARS-CoV-2 vaccination. *Kardiol Pol* 2022;80(2): 237–8.
- [18] Maniscalco GT, Manzo V, Di Battista ME, Salvatore S, Moreggia O, Scavone C, et al. Severe multiple sclerosis relapse after COVID-19 vaccination: a case report. *Front Neurol* 2021;12:721502.
- [19] Seyed Ahadi M, Ghadiri F, Ahraian MA, Naser Moghadasi A. Acute attack in a patient with multiple sclerosis 2 days after COVID vaccination: a case report. *Acta Neurol Belg* 2021.
- [20] Knoll MD, Wonodi C. Oxford-AstraZeneca COVID-19 vaccine efficacy. *Lancet* 2021; 397(10269):72–4.
- [21] Confavreux C, Suissa S, Sadding P, Bourdès V, Vukusic S. Vaccinations and the risk of relapse in multiple sclerosis. *N Engl J Med* 2001;344(5):319–26.
- [22] Geier MR, Geier DA, Zahalsky AC. Influenza vaccination and Guillain Barre syndrome. *Clin Immunol* 2003;107(2):116–21.
- [23] Li X, Raventós B, Roel E, Pistillo A, Martínez-Hernandez E, Delmestri A, et al. Association between covid-19 vaccination, SARS-CoV-2 infection, and risk of immune mediated neurological events: population based cohort and self-controlled case series analysis. *BMJ*. 2022;376:e068373.
- [24] Dema M, Eixarch H, Villar LM, Montalban X, Espejo C. Immunosenescence in multiple sclerosis: the identification of new therapeutic targets. *Autoimmun Rev* 2021;20(9):102893.
- [25] Langer-Gould A, Qian L, Tartof SY, Brara SM, Jacobsen SJ, Beaver BE, et al. Vaccines and the risk of multiple sclerosis and other central nervous system demyelinating diseases. *JAMA Neurol* 2014;71(12):1506.
- [26] Farez MF, Correale J, Armstrong MJ, Rae-Grant A, Gloss D, Donley D, et al. Practice guideline update summary: vaccine-preventable infections and immunization in multiple sclerosis: report of the guideline development, dissemination, and implementation subcommittee of the american academy of neurology. *Neurology* 2019;93(13):584–94.
- [27] Ko EJ, Kang SM. Immunology and efficacy of MF59-adjuvanted vaccines. *Hum Vaccin Immunother* 2018;14(12):3041–5.
- [28] Amaral MP, Branco LM, Strasser A, Dixit VM, Bortoluci KR. Paradise revealed III: why so many ways to die? Apoptosis, necroptosis, pyroptosis, and beyond. *Cell Death Differ* 2020;27(5):1740–2.
- [29] Taniguchi K, Karin M. NF-κB, inflammation, immunity and cancer: coming of age. *Nat Rev Immunol* 2018;18(5):309–24.
- [30] Achiron A, Dolev M, Menascu S, Zohar D-N, Dreyer-Alster S, Miron S, et al. COVID-19 vaccination in patients with multiple sclerosis: What we have learnt by February 2021. *Mult Scler* 2021;27(6):864–70.
- [31] Diem L, Friedli C, Chan A, Salmen A, Hoepner R. Vaccine hesitancy in patients with multiple sclerosis: preparing for the SARS-CoV-2 vaccination challenge. *Neurol Neuroimmunol Neuroinflamm* 2021;8(3):e991.