

Rare pathogenic mutation in the thymidine phosphorylase gene (TYMP) causing mitochondrial neurogastrointestinal encephalomyelopathy

Syed Asfand Yar Shah,¹ Hassan Abdullah Shakeel ,² Wajih UI Hassan¹

To cite: Shah SAY, Shakeel HA, Hassan WU. Rare pathogenic mutation in the thymidine phosphorylase gene (TYMP) causing mitochondrial neurogastrointestinal encephalomyelopathy. *BMJ Neurology Open* 2022;4:e000287. doi:10.1136/bmjno-2022-000287

Accepted 13 July 2022

ABSTRACT

Background Mitochondrial neurogastrointestinal encephalopathy (MNGIE) disease is a rare multisystem disorder that mainly affects the digestive and nervous systems. Key features of the disease include cachexia, ptosis, external ophthalmoplegia, peripheral neuropathy and leucoencephalopathy. Symptoms most often begin by age 20 and overlap several other Metabolic and endocrine disorders making the diagnosis challenging. It has been determined that MNGIE is caused by mutations in the gene-encoding thymidine phosphorylase (TP; previously known as endothelial cell growth factor 1).

Case We herein present the clinical, neuroimaging and molecular findings in a patient with MNGIE caused by a novel homozygous variant of TYMP gene c.1048C>T, which is predicted to result in a premature protein termination (p.Gln350*). TYMP is a gene on chromosome 22q13.33 that encodes TP.

Conclusion This case highlights the importance of good understanding and early recognition of a rare condition like MNGIE, so that the suffering from unnecessary interventional procedures can be avoided and better multidisciplinary care can be implemented for the symptomatic management of the patient.

INTRODUCTION

Mitochondrial neurogastrointestinal encephalopathy (MNGIE) is a multiorgan mitochondrial disease that particularly affects the digestive system and nervous system. It is characterised by early satiety, nausea, dysphagia, gastroesophageal reflux, episodic abdominal pain and/or distention, diarrhoea, cachexia, ophthalmoplegia, leucoencephalopathy, paraesthesias and symmetric distal limb weakness. The order in which manifestations appear is unpredictable. The prevalence of MNGIE worldwide is estimated to be <10 in a million, with around 200 patients with MNGIE identified in the world.¹ MNGIE has a limited prognosis; the mean age at death ranges between 35 and 37 years; survival is 100% before 19 years and <5% after 50 years.²

WHAT IS ALREADY KNOWN ON THIS TOPIC

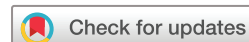⇒ Mitochondrial neurogastrointestinal encephalomyelopathy (MNGIE) was first reported in 1976. Since then, there has been extensive research on the molecular basis and pathophysiology of the disease. But, there is limited data available when it comes to the definitive treatment of the disease. Also, over time, scientists have reported numerous variants of the gene mutation that can cause MNGIE.

WHAT THIS STUDY ADDS

⇒ In this paper, we have reported the case of a young lady who presented with neurological and gastrointestinal disturbance. She was found to have mitochondrial neurogastrointestinal encephalomyelopathy (MNGIE) with a rare mutation in the TYMP gene. That mutation has never been described before. Besides that, the patient enrolled herself in an ongoing clinical trial for stem cell transplant treatment for the disease.

HOW THIS STUDY MIGHT AFFECT RESEARCH, PRACTICE OR POLICY

⇒ It may help scientists understand the genetic basis of MNGIE. Furthermore, it is of great educational value for clinical purposes to raise awareness regarding this rare disorder that is often misdiagnosed and patients have to undergo extensive unnecessary invasive investigations and procedures.



© Author(s) (or their employer(s)) 2022. Re-use permitted under CC BY-NC. No commercial re-use. See rights and permissions. Published by BMJ.

¹Medicine, Nishtar Medical College and Hospital, Multan, Pakistan

²Neurology, Nishtar Medical College and Hospital, Multan, Pakistan

Correspondence to

Dr Hassan Abdullah Shakeel; hassanas260@gmail.com

of abdominal pain, diarrhoea and intestinal blockage. These gastrointestinal problems lead to extreme weight loss and reduced muscle mass (cachexia). Abnormalities of the nervous system include peripheral neuropathy, progressive external ophthalmoplegia, droopy eyelids (ptosis), diffuse leucoencephalopathy seen on MRI of the brain (usually asymptomatic) and hearing loss in some cases.

CASE PRESENTATION

A 25-year-old Saudi Arabian woman presented with reports of chronic progressive abdominal pain, fullness, nausea, vomiting and significant weight loss for the past year. She also reported dysphagia to big tablets over the past 10 months. Furthermore, she had bilateral foot numbness that started 4–5 months ago with associated walking difficulty. Her previous medical history revealed frequent hospitalisations for the management of severe idiopathic gastroparesis, septic shock, lactic acidosis, gastrointestinal (GI) blood loss, ascites and pleural effusions. She had extensive diagnostic workup in the past, including laparoscopies, CT enterography, multiple endoscopies, invasive testing for coeliac disease and received empirical treatment for suspected vasculitis without significant success. Family history revealed that the patient had consanguineous parents. Two of her brothers deceased in early childhood under unknown circumstances. No history of severe GI problems was found in the extended pedigree.

On physical examination, she was cachectic with severe muscle wasting, her weight was 22.7 kg, and her body mass index (BMI) was 9.36. Her ophthalmological examination was normal. On admission, electrocardiogram (EKG) revealed sinus tachycardia but no cardiac abnormalities. Laboratory investigations were consistent with severe malnutrition, zinc and copper deficiency. The patient was found to have elevated blood lactate 4.7 (normal 2.2 mmol/L) and elevated blood pyruvate levels. Urine organic acids were submitted to a biochemical laboratory for analysis. It revealed the presence of uracil and thymine. Furthermore, the blood deoxyuridine (dUrd) level was elevated. However, the deoxythymidine (dTd) level was normal. Liver function tests, renal function tests and muscle enzymes were normal. An audiogram showed no loss of hearing.

Nerve conduction studies showed mild length-dependent mixed axonal and demyelinating sensorimotor peripheral neuropathy. MRI brain with and without IV contrast demonstrated relatively symmetric diffuse white matter T2 hyperintensities compatible with leucoencephalopathy and scattered inflammatory changes in the paranasal sinuses, greatest in the sphenoid sinus and right posterior ethmoid air cells (figure 1).

At that time, the differentials were mitochondrial diseases, gastrointestinal disorders and inherited metabolic and genetic diseases such as leucodystrophies. The appearance of severe gastrointestinal dysmotility symptoms with a demyelinating sensorimotor polyneuropathy, MRI finding and pertinent labs suggested a mitochondrial disorder, specifically MNGIE. Patients with MNGIE typically have normal

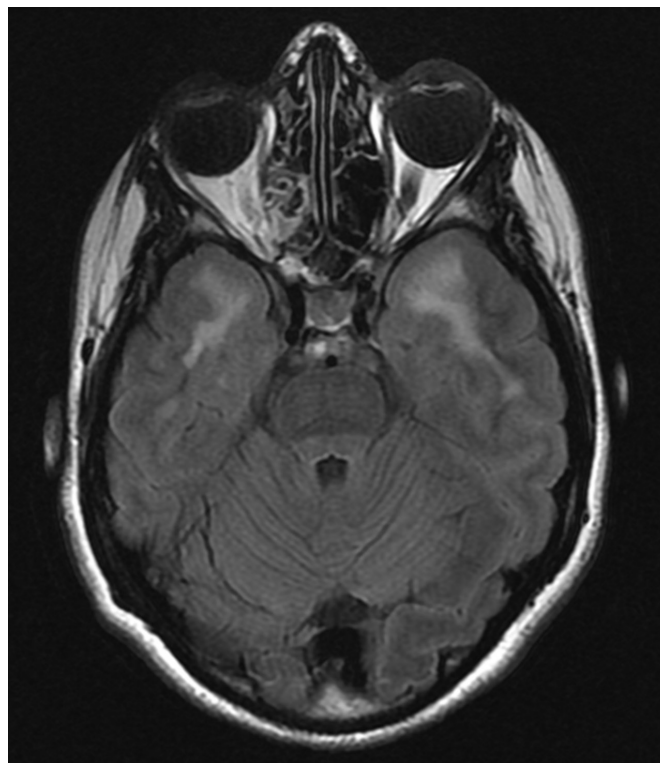


Figure 1 Stable, bilaterally symmetric leucoencephalopathy within the cerebral hemispheres with inflammatory changes in the right posterior ethmoid air cells.

learning abilities and do not present with seizures or cardiac involvement; leucoencephalopathy is usually asymptomatic.

She underwent genetic testing, which revealed a homozygous likely pathogenic variant in the *TYMP* gene denoted at the DNA level as c.1048C>T. This nucleotide change is predicted to result in premature protein termination (p.Gln350*). In addition, the deletion/duplication assay for the *TYMP* gene was negative.

She was started on coenzyme Q10 600 mg in two divided doses, carnitine 3 g in two divided doses and riboflavin 100 mg/day and was asked to follow-up. After careful consideration of all the available treatment modalities, an allogeneic stem cell transplantation was suggested as a definitive treatment to correct biochemical abnormalities in the blood by restoring TP activity. She enrolled herself in an ongoing clinical trial for that.

DISCUSSION

MNGIE was first reported in 1976 as a congenital oculoskeletal myopathy with abnormal muscle and liver mitochondria.⁴ Since then, it has been registered under various names, including myoneurogastrointestinal encephalopathy syndrome, mitochondrial encephalomyopathy with sensorimotor polyneuropathy, ophthalmoplegia and pseudo-obstruction; and polyneuropathy, ophthalmoplegia, leucoencephalopathy and intestinal pseudo-obstruction.

In a retrospective cohort study comprising data from 102 MNGIE patients, collected from 1988 to 2011, the mortality rate was high between the ages of 20 and 40 years.⁵ In 1999,

Nishino *et al* identified homozygous or compound heterozygous mutations in the TP gene as a cause of MNGIE.³ Currently, greater than 80 such mutations have been reported in patients from different ethnicities.⁶

We report a 25-year-old patient with a novel homozygous variant of TYMP gene c.1048C>T. In 2020, the Biochemical Molecular Genetic Laboratory, King Abdulaziz Medical City, Saudi Arabia, reported a novel mutation that was found in our patient to the National Institute of Health's genetic database.⁷ However, in this manuscript, the authors described the same patient's detailed history, the clinical course of the disease, treatment, follow-up and the eventual decision to be enrolled in Dr. Hirano's ongoing clinical trial entitled, 'MNGIE Allogeneic Hematopoietic Stem Cell Transplant Safety Study (MASS)' (trial registration number: NCT02427178).

Different therapeutic modalities have been suggested for patients with MNGIE syndrome. As per the new Bologna consensus statement developed by the MNGIE international network, MNGIE treatment can be divided into two broad categories; short-term treatments effective in temporarily restoring the biochemical imbalance and effective treatments that permanently restore the biochemical imbalance.² Short-term measures, including platelet transfusion, haemodialysis and peritoneal dialysis, are used in patients with MNGIE to remove the circulating thymidine and dUrd.^{8–10} On the other hand, allogeneic and haematopoietic stem cell transplantation is a well-documented treatment modality for MNGIE.^{11 12} It aims at permanently restoring TP, which results in the long-term clearance of dUrd and dThd. However, it has many limitations, such as finding compatible donors, high rates of graft failure and risk of graft-versus-host disease. Liver transplantation has also shown promising results by repleting the TP level in the body.¹³ Whether liver transplantation will change the outcome of the disease and improve the quality of life of patients with MNGIE syndrome is still questionable. The current literature suggests that a high mortality rate in MNGIE patients approximating half to two-thirds of the patients died due to complications of a combination of the therapy and the disease.¹²

CONCLUSION

We conclude that the appearance of severe gastrointestinal dysmotility symptoms with a demyelinating sensorimotor polyneuropathy should raise the suspicion of MNGIE. MNGIE mimics many GI disorders, considering the differential diagnosis of refractory GI symptoms with peripheral neuropathy and asymptomatic leucoencephalopathy. It may result from many types of mutations: our patient was found to have a homozygous likely pathogenic variant in the TYMP gene denoted at the DNA level as c.1048C>T. Understanding this medical condition well in advance is crucial to avoid suffering from unnecessary interventional procedures and prevent severe disease impacts before the disease advances to its irreversible stage.

Twitter Wajih UI Hassan @Wajihul56274612

Acknowledgements The authors wish to thank their patient and her family for their support and permission to publish this case study. The authors also want to thank Dr. Stephanie L. Hansel, M.D. for her kind mentorship regarding this case.

Contributors SAYS was involved in the clinical care of the patient. The initial draft of the manuscript was prepared by SAYS and HAS, which was edited by HS and WUH. All authors were involved in the review of the literature, revising the manuscript and approving the final draft.

Funding The authors have not declared a specific grant for this research from any funding agency in the public, commercial or not-for-profit sectors.

Competing interests No, there are no competing interests.

Patient consent for publication Consent obtained directly from patient(s)

Ethics approval Not applicable.

Provenance and peer review Not commissioned; externally peer reviewed.

Data availability statement Data sharing not applicable as no datasets generated and/or analysed for this study. N/A.

Open access This is an open access article distributed in accordance with the Creative Commons Attribution Non Commercial (CC BY-NC 4.0) license, which permits others to distribute, remix, adapt, build upon this work non-commercially, and license their derivative works on different terms, provided the original work is properly cited, appropriate credit is given, any changes made indicated, and the use is non-commercial. See: <http://creativecommons.org/licenses/by-nc/4.0/>.

ORCID iD

Hassan Abdullah Shakeel <http://orcid.org/0000-0003-2045-1119>

REFERENCES

- Hirano M, Nishigaki Y, Martí R. (MNGIE): a disease of two genomes. *Neurologist* 2004;10:8–17.
- Hirano M, Carelli V, De Giorgio R, *et al*. Mitochondrial neurogastrointestinal encephalomyopathy (MNGIE): position paper on diagnosis, prognosis, and treatment by the MNGIE international network. *J Inher Metab Dis* 2021;44:376–87.
- Nishino I, Spinazzola A, Hirano M. Thymidine phosphorylase gene mutations in MNGIE, a human mitochondrial disorder. *Science* 1999;283:689–92.
- Okamura K, Santa T, Nagae K, *et al*. Congenital ocular skeletal myopathy with abnormal muscle and liver mitochondria. *J Neurol Sci* 1976;27:79–91.
- Garone C, Tadesse S, Hirano M. Clinical and genetic spectrum of mitochondrial neurogastrointestinal encephalomyopathy. *Brain* 2011;134:3326–32.
- Habibzadeh P, Silawi M, Dastsooz H, *et al*. Clinical and molecular characterization of a patient with mitochondrial neurogastrointestinal encephalomyopathy. *BMC Gastroenterol* 2020;20:142.
- ClinVar [Internet]. Bethesda (MD), National Library of Medicine (US), National Center for Biotechnology Information. Accession No. NM_001953.5(TYMP):c.1048C>T (p.Gln350Ter) AND Mitochondrial DNA depletion syndrome 1, [2020]. Available: <https://www.ncbi.nlm.nih.gov/clinvar/RCV001027995/> [Accessed 15 May 2021].
- Lara MC, Weiss B, Illa I, *et al*. Infusion of platelets transiently reduces nucleoside overload in MNGIE. *Neurology* 2006;67:1461–3.
- Röeben B, Marquetand J, Bender B, *et al*. Hemodialysis in MNGIE transiently reduces serum and urine levels of thymidine and deoxyuridine, but not CSF levels and neurological function. *Orphanet J Rare Dis* 2017;12:135.
- Yavuz H, Özel A, Christensen M, *et al*. Treatment of mitochondrial neurogastrointestinal encephalomyopathy with dialysis. *Arch Neurol* 2007;64:435.
- Hirano M, Martí R, Casali C, *et al*. Allogeneic stem cell transplantation corrects biochemical derangements in MNGIE. *Neurology* 2006;67:1458–60.
- Halter JP, Michael W, Schüpbach M, *et al*. Allogeneic haematopoietic stem cell transplantation for mitochondrial neurogastrointestinal encephalomyopathy. *Brain* 2015;138:2847–58.
- Kripps K, Nakayuenyongsuk W, Shayota BJ, *et al*. Successful liver transplantation in mitochondrial neurogastrointestinal encephalomyopathy (MNGIE). *Mol Genet Metab* 2020;130:58–64.