

## Case Image

# Iatrogenic abdominal hematoma and severe anemia due to cosmetic liposuction

Hitomi Chinen,<sup>1</sup> Satoshi Yoshimura,<sup>2</sup> Masayasu Takegawa,<sup>3</sup> Nobuhiro Miyamae,<sup>2</sup> and Yasuyuki Sumida<sup>2</sup>

<sup>1</sup>Department of Dermatology, Rakuwakai Otowa Hospital, Kyoto-shi, Japan, <sup>2</sup>Department of Emergency Medicine, Rakuwakai Otowa Hospital, Kyoto-shi, Japan, and <sup>3</sup>Department of Plastic Surgery, Rakuwakai Otowa Hospital, Kyoto-shi, Japan

**Key words:** Anemia, complication, cosmetic surgery, hematoma, liposuction

A 40-year-old woman presented with a 3-day history of lightheadedness after tumescent liposuction of the buttocks and abdomen at a private clinic. The patient had undergone the same operation on her upper arms and thighs several months ago. The aspirate fluid collected during the second surgery was bloodier than that collected during the first surgery (Fig. 1A,B). Disseminated purpura was identified on her abdomen (Fig. 1C,D) with a hemoglobin level of 5.0 g/dL. Computed tomography revealed a hematoma in the subcutaneous fat of the abdomen (Fig. 1E,F). After red blood cell transfusion, the patient was discharged on day 3 with a hemoglobin level of 7.2 g/dL and symptoms improved. The patient was healthy and had no recurrence of anemia at the 6-month follow-up. Anemia is a common post-liposuction complication, with a rate of 2.4% in the United States.<sup>1</sup> Although a life-threatening bleeding case has been recently reported in Japan,<sup>2</sup> there is no clinical database for liposuction. In the present case, the amount of liposuction, 2.8 L, is a risk factor for significant hemorrhage.<sup>1,3</sup> Evaluating the risks and developing a clinical database for monitoring and investigating this complication are needed to improve patient safety.

Satoshi Yoshimura is the guarantor of the clinical content of this submission.

**Corresponding:** Satoshi Yoshimura MD, MPH, Department of Emergency Medicine, Rakuwakai Otowa Hospital; 2 Chinjicho, Otowa, Yamashina-ku, Kyoto-shi, Japan. E-mail: yoshimura.satoshi.s34@kyoto-u.jp.

Received 21 Jun, 2022; accepted 7 Aug, 2022

**Funding statement**  
None.

## DISCLOSURE

Approval of the Research Protocol: Not applicable (clinical image).

Informed Consent: We obtained the informed consent from the patient for the publication of the report.

Registry and the Registration No. Of the Study/Trial: Not applicable.

Animal Studies: Not applicable.

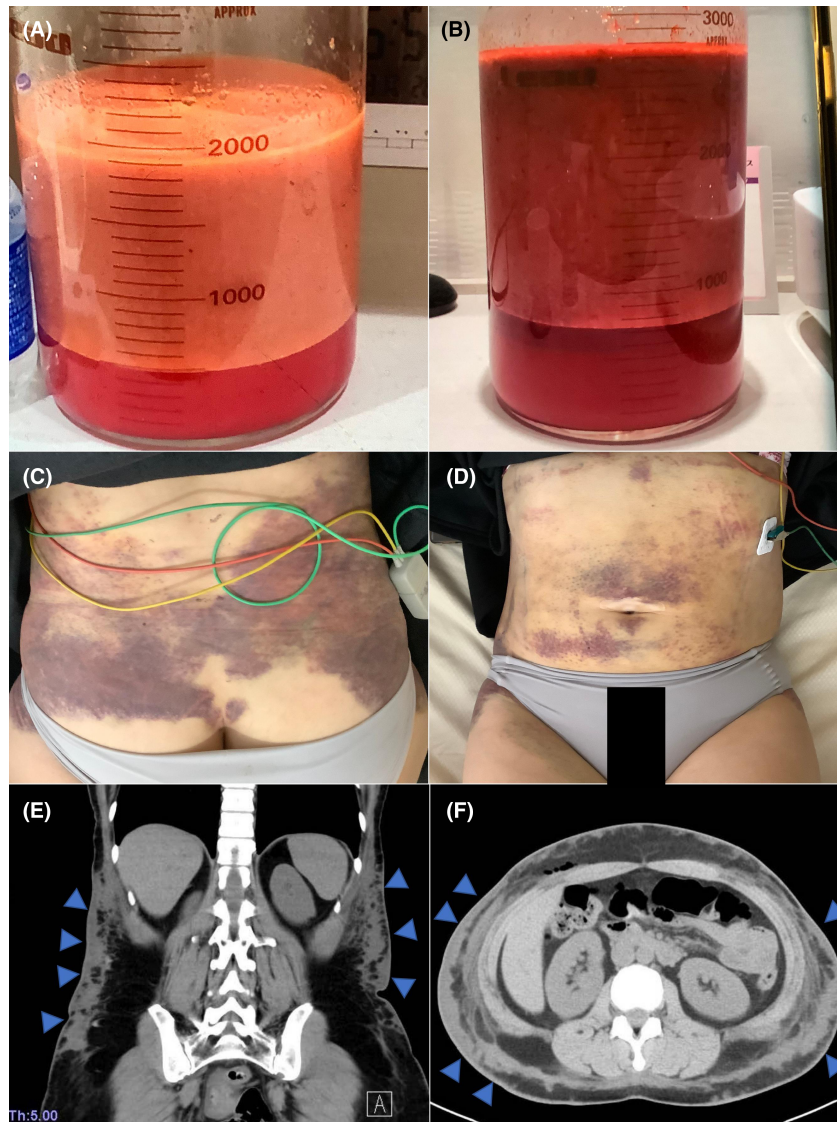
Conflicts of Interest: None declared.

## ACKNOWLEDGEMENTS

WE ALSO THANK Drs. Hideta Sakemi and Nobuhiro Ikeda for their helpful discussions and comments on this manuscript.

## REFERENCES

- 1 Kaoutzanis C, Gupta V, Winocour J *et al.* Cosmetic liposuction: preoperative risk factors, major complication rates, and safety of combined procedures. *Aesthet. Surg. J.* 2017; 37: 680–94.
- 2 Miyazaki M, Kobayashi K, Yamamoto M *et al.* A report of four cases requiring emergency hospitalization and treatment due to postoperative complications after liposuction. *Nippon Kyukyu Igakkai Kanto Chihokai Zasshi* 2020; 41: 392–5 (Japanese Only).
- 3 Lehnhardt M, Homann HH, Daigeler A, Hauser J, Palka P, Steinau HU. Major and lethal complications of liposuction: a review of 72 cases in Germany between 1998 and 2002. *Plast. Reconstr. Surg.* 2008; 121: 396e–403e.



**Fig. 1.** (A) The collected fluids at the first surgery. (B) The collected bloody fluids at the secondary surgery, which was bloodier than the previous one. (C,D) Diffuse purpuras were identified around the abdomen. (E,F) Computed tomography showing diffused hematomas all over the abdomen (arrowheads).