



The Brazilian Journal of INFECTIOUS DISEASES

www.elsevier.com/locate/bjid



Case report

Nocardia veterana: disseminated infection with urinary tract infection



Elodie Poisnel^a, Jean-Baptiste Roseau^b, Cécile Landais^a, Veronica Rodriguez-Nava^d, Emmanuel Bussy^e, Tiphaine Gaillard^{c,*}

^a Department of Medicine, Hospital Sainte Anne, Toulon, France

^b Department of Pneumology, Hospital Sainte Anne, Toulon, France

^c Department of Microbiology, Hospital Sainte Anne, Toulon, France

^d Center for Microbial Ecology, Nocardiosis French Observatory, School of Pharmacy, University Claude Bernard Lyon 1, Lyon, France

^e Department of Nuclear Medicine, Hospital Sainte Anne, Toulon, France

ARTICLE INFO

Article history:

Received 30 July 2014

Accepted 12 November 2014

Available online 28 January 2015

Keywords:

Nocardia veterana

Urinary tract infection

MALDI-TOF MS system

16S rDNA gene sequencing

ABSTRACT

Nocardia spp. are a group of aerobic actinomycetes widely distributed in soil, and associated with severe opportunistic infections, essentially pulmonary infections.

We report the first case of disseminated infection associated with urinary tract infection caused by *Nocardia veterana*. The diagnosis was difficult; despite the presence of pulmonary nodules, the lung biopsies remained negative while only one aerobic blood culture and the urine culture were positive for *N. veterana*, identified after a 16S rDNA gene sequence analysis.

Few cases of clinical importance due to *N. veterana* have been published since its characterization. The bacteriological diagnosis of nocardiosis can be difficult to establish because of the delayed growth and the specific techniques that are required. This case illustrates the necessity of performing specific investigations in immunocompromised patients who present with infectious disease because the severity of this infection requires early diagnosis and quick initiation of appropriate antibiotic therapy.

© 2015 Elsevier Editora Ltda. All rights reserved.

Case presentation

A 51-year-old man was admitted to the hospital to investigate his chest pain and weight loss (8 kg in two months). His

past medical history included a grade 4 left temporal glioblastoma, diagnosed 11 months before, and multicystic kidney disease. The patient underwent surgery and radiation therapy, followed by first line chemotherapy with temozolomide and second line chemotherapy with lomustine, vincristine,

Abbreviations: CAPD, continuous ambulatory peritoneal dialysis; BAL, bronchoalveolar lavage; CT, computed tomography; FDG, deoxyglucose labeled with fluorine 18; PAS, periodic acid Schiff; PCR, polymerase chain reaction; MALDI-TOF MS, matrix-assisted laser desorption/ionization time-of-flight mass spectrometry.

* Corresponding author at: Department of Microbiology, Hospital Sainte Anne, Boulevard Sainte Anne, BP 20545, 83041 Cedex 09 Toulon, France.

E-mail address: tiphaine.rousselgaillard@gmail.com (T. Gaillard).

<http://dx.doi.org/10.1016/j.bjid.2014.11.003>

1413-8670/© 2015 Elsevier Editora Ltda. All rights reserved.

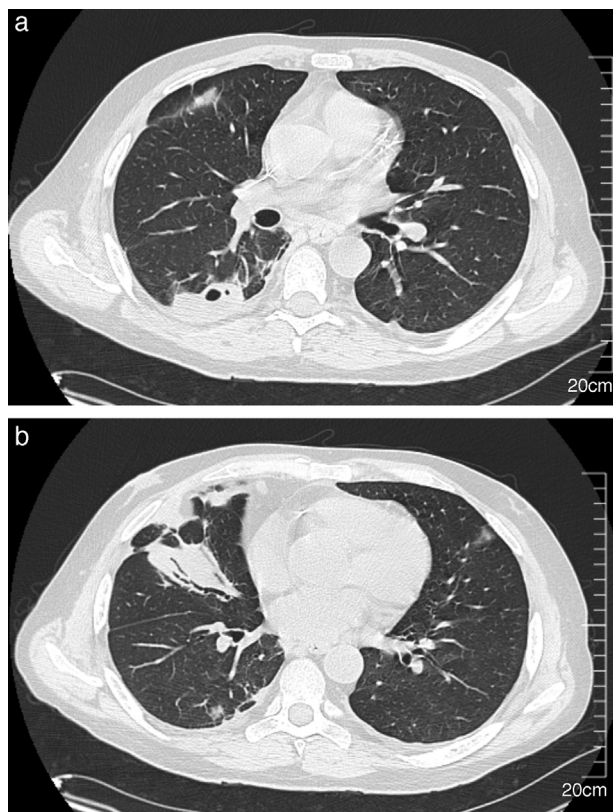


Fig. 1 – Chest CT scan showing right-sided multiple pulmonary nodules with cavitation (A) and parenchymal consolidation in the middle lobe (B).

and procarbazine, due to disease progression. He was given 32 mg of methylprednisolone per day starting at the beginning of the chemotherapy. Multicystic kidney disease caused renal terminal insufficiency, which required continuous ambulatory peritoneal dialysis (CAPD) for more than four months. The patient presented with a progressive shortness of breath, right-sided chest pain, and dysuria. He had no fever, and a physical exam showed right basal crackles. The laboratory test results were as follows: hemoglobin 9.7 g/dL; neutrophils $12 \times 10^9/L$; lymphocytes $4.2 \times 10^9/L$ with a CD4 lymphocyte count of $1.64 \times 10^9/L$; serum creatinine 630 $\mu\text{mol/L}$, and C-reactive protein 113.5 mg/L (reference value $<10 \text{ mg/L}$). Additionally, two sets of blood cultures and urine culture were performed. Urine analysis revealed 1.3×10^6 leukocytes/mL (normal range $<10^3/\text{mL}$) and Gram-positive short bacilli at microscopic examination. Chest computed tomography (CT) showed multiple sub-pleural nodules in the right lower lobe that were adjacent to pleural thickening without pleural effusion, and consolidation in the middle lobe (Fig. 1). One of the nodules was excavated. The PET imaging performed to demonstrate deep infection showed an intense and diffuse accumulation of the deoxyglucose labeled with fluorine 18 (FDG) in the prostate (Fig. 2) revealing prostatitis.

A bronchoalveolar lavage (BAL) and a CT-guided needle lung biopsy of the posterior nodule were performed. In the laboratory, tissue analysis found acute suppurative inflammation, with negative PAS, Grocott and Giemsa staining.

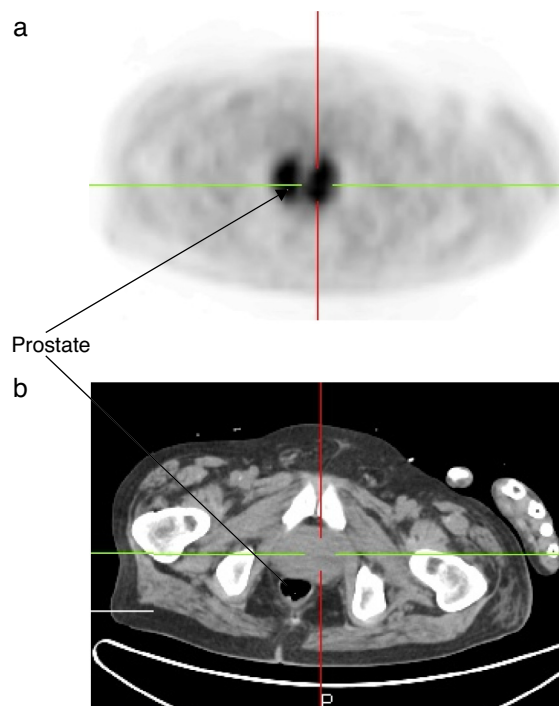


Fig. 2 – PET scan showing an intense and diffuse accumulation of the FDG in the prostate (A: PET imaging; B: scanned imaging of the prostate).

Gram and acid-fast staining were processed and were negative on both samples. Standard culture performed on BAL was non-contributive, with polymicrobial non-pathogenic nasopharyngeal flora; mycobacterial and mycological cultures remained negative. Standard culture was not undertaken on the pulmonary biopsy because of its insufficient amount. Both samples were tested for tuberculosis using polymerase chain reaction (PCR) on the MTB/RIF test platform (GenExpert[®]; Cepheid, Sunnyvale, CA, USA) and were negative. PCR amplification and sequencing of 16S rDNA and 18S rDNA for the detection of bacteria and fungi, respectively, were performed on the pulmonary biopsy after dewaxing, and were negative. Four days after the patient's admission, growth was identified in one aerobic blood culture using the BacT Alert 3D[®] culture system (BioMérieux, Marcy l'Etoile, France). The bacterium was a non-motile, Gram-positive organism with branching filaments. Small, chalky white, rough colonies grew within 48 h when inoculated on boiled blood agar plates that were incubated at 37 °C in 5% CO₂. They were partially acid-fast and were considered to likely represent *Nocardia* spp. A Gram-positive bacterium was observed simultaneously in the urine culture, with more than 100,000 colonies/mL. The two strains, from blood and urine cultures, were identified to the genus level as *Nocardia* spp. using the MALDI-TOF MS (matrix-assisted laser desorption-ionization time-of-flight mass spectrometry) system (Bruker Daltonik, Bremen, Germany) after an extraction procedure. The identification to the species level as *Nocardia veterana* was obtained using a 16S rDNA gene sequence analysis (99.9% sequence matching with the type strain *N. veterana* DSM 44445^T).

Prior to the isolation of *Nocardia*, the patient was empirically treated with intravenous trimethoprim-sulfamethoxazole (400 mg/80 mg, twice daily) and ceftriaxone (750 mg twice daily). Doses were adapted to renal function, with hemodialysis performed three times per week. Antimicrobial susceptibility was assessed by the French Observatory of Nocardiosis (Lyon, France) by broth microdilution according to the Clinical and Laboratory Standards Institute (CLSI) methods and breakpoints.¹ The profile revealed resistance to amoxicillin + clavulanate (MIC of 32/16 µg/mL), ciprofloxacin (MIC >4 µg/mL) and doxycycline (MIC = 8 µg/mL); intermediate susceptibility to gentamicin (MIC of 8 µg/mL) and minocycline (MIC = 2 µg/mL); and susceptibility to cefotaxime (\leq 4 µg/mL), ceftriaxone (MIC = 8 µg/mL), imipenem (MIC \leq 2 µg/mL), trimethoprim-sulfamethoxazole (MIC \leq 1/19 µg/mL) and linezolid (MIC \leq 4 µg/mL). After initiation of treatment, the respiratory symptoms slowly improved, and dysuria was completely resolved. The biological inflammatory syndrome decreased gradually, and a chest CT scan performed after one month of antibiotic therapy showed a moderate decrease in nodules size. Accordingly, the urinary and blood culture controls showed no remaining *Nocardia*. Unfortunately, due to glioblastoma progression, the patient's neurological status declined, and he died two months after the initial admission.

Nocardiosis infections are caused by the saprophytic aerobic, Gram-positive, branching and filamentous bacilli belonging to the genus *Nocardia*. The identification of *Nocardia* isolates at the species level is critical for defining the spectrum of diseases that are caused by each species and to predict antimicrobial susceptibility.² To date, approximately 90 species have been described (NCBI taxonomy for *Nocardia*), and a third of them have been implicated in human disease.³ If isolates grow well on blood agar plates, the routine identification of *Nocardia* strains using conventional phenotypical methods is a fastidious and time-consuming process that is now restricted to reference centers.² In recent years, 16S rDNA gene sequence analysis has become accessible to clinical laboratories for definitive species identification.⁴ In our case, the strain of *N. veterana* was confirmed at the species level by almost complete 16S rDNA gene sequencing (1315 nt) by using SQ1 (5'-AGAGTTGATCMTGGCTCAG-3') and SQ6 (5'-CGGTGTGTACAAGGCC-3') primers, according to previous published data.⁵ The sequences obtained presented a 99.9% sequence similarity (one difference out of 1315 nt, excluding the primers) to the type strain *N. veterana* DSM 44445^T. The MALDI-TOF MS identification systems are based on the comparison of the tested isolate mass spectrum with reference databases. Previous studies reported that the Bruker MALDI-TOF MS system accurately identified species from the genus *Nocardia* spp.⁶ but a preliminary extraction step was mandatory to obtain satisfactory results. In our case, the identification was obtained to the genus level after an extraction procedure in two steps (boiling followed by ethanol-formic acid extraction). At first, the identification by the direct colony method failed to identify the bacterium, although it has been recently published with other MALDI-TOF MS systems.⁷

N. veterana is a species that was characterized in 2001.⁸ The difficulties in the identification of this species, until recently, may imply that it is more common as a human pathogen than previously reported.⁹ Indeed, little is known about *N.*

veterana because few cases of clinical importance have been published. One isolate was from a brain abscess¹⁰; three were reported in patients with pulmonary infections^{2,11-14}; one isolate was recovered in a bowel abscess and was associated with colon carcinoma¹⁵; two cases of mycetomas from Japan were published^{16,17}; one isolate has been recovered from ascitic fluid,⁸ one was responsible for an endogenous endophthalmitis,¹⁸ and recently, a case of *N. veterana* causing nodular lymphangitis was reported.¹⁹ Bloodstream infection due to *N. veterana* is a rare condition. In our case, this pathogen was isolated from blood and urine cultures, and this is the first reported case of urinary tract infection due to *N. veterana*. This implies that the infectious spectrum of *N. veterana* could be relatively broad.

Like other species of *Nocardia* spp., *N. veterana* causes infections mainly in immunocompromised hosts. As predisposing factors, the patient was administered long-term corticosteroid and chemotherapy (including temozolomide) for neoplastic disease. However, in a recent study of nocardiosis and AIDS, it was shown that despite deep immunodepression, nocardiosis was an uncommon complication. Trimethoprim-sulfamethoxazole, which is used in primary prophylaxis for toxoplasmosis, could be effective against nocardiosis as well.

It is unclear how our patient became infected by *N. veterana*. Pulmonary infection is the most common site of nocardiosis, and it is usually acquired by inhalation of sporulated fragmented nocardial mycelia found in the environment.^{11,20} Most of the time, diagnosis is based on the isolation of *Nocardia* from respiratory samples. In our case, we identified a disseminated *N. veterana* infection with the presence of this bacterium in peripheral blood culture and urine. The hypothesis of airborne contamination, with an infection that was initially limited to the lung and a secondary hematological dissemination, sometimes to the central nervous system and soft tissue,⁸ may be considered. However, we have not proved the presence of *N. veterana* in the chest, although there were several indications of its presence, including the patient's pulmonary presentation, chest CT scan features with nodules and parenchymal consolidation¹² (Fig. 1) and the negativity of all bacteriological chest sampling for other pathogens. The contamination of the BAL by non-pathogenic nasopharyngeal flora of the upper respiratory tract could have interfered with culturing of *Nocardia* spp. We have no explanation for the negativity of PCR amplification of 16S rDNA performed on the pulmonary biopsy after dewaxing; the low sensitivity of PCR amplification could explain the result. Furthermore, the role of CAPD must be considered, as several cases of peritoneal nocardiosis have been reported.²¹ Our patient had daily home- and self-made CAPD, which could have been a predisposing factor for this infection because of non-optimal skills. We did not perform bacteriological testing of ascitic fluid because our patient had no abdominal pain, which makes the hypothesis of CAPD-induced contamination less likely.

The antimicrobial agents to be used against *N. veterana* remain controversial due to discrepancies regarding methodological variations, differences in interpretations concerning breakpoints and, therefore, susceptibilities. Based on limited *in vitro* studies of antimicrobial agents against this microorganism, the empiric drug of choice for this pathogen would be trimethoprim-sulfamethoxazole^{9,22} at a dose of

10–15 mg/kg daily. In our case, *N. veterana* remained sensitive to trimethoprim-sulfamethoxazole and ceftriaxone, which was the initial empirical treatment. The treatment of nocardiosis must be extended by considering many factors, such as the severity of infection or the immunizing status. In the previously published cases, the duration of treatment ranged from a few weeks to a number of years based on expert opinion on the treatment of other *Nocardia* infections.¹⁰ Because the patient died two months after the initial admission, we could not evaluate his response to the antibiotic treatment.

Conclusion

In conclusion, this is the first reported case of urinary tract infection due to *N. veterana*. Nocardiosis due to *N. veterana* is a rare disease, but its incidence will most likely increase in the coming years because of the growing population of immunocompromised hosts. This case illustrates the difficulty of establishing a bacteriological diagnosis of nocardiosis and the necessity of performing specific investigations in immunocompromised patients who present with infectious disease because the severity of this infection requires early diagnosis and quick initiation of appropriate antibiotic therapy.

Conflicts of interest

The authors declare no conflicts of interest.

REFERENCES

- Clinical and Laboratory Standards Institute Document M-A. Susceptibility testing of mycobacteria, nocardiae and other aerobic actinomycetes – approved standard. CLSI document. 2nd ed; 2011.
- Liu W, Lai C, Hsiao C, et al. Bacteremic pneumonia caused by *Nocardia veterana* in an HIV-infected patient. *Int J Infect Dis.* 2011;15:430–2.
- Kong F, Wang H, Zhang E, et al. *secA1* gene sequence polymorphisms for species identification of *Nocardia* species and recognition of intraspecies genetic diversity. *J Clin Microbiol.* 2010;48:3928–34.
- Wellinghausen N, Pietzcker T, Kern WV, Essig A, Marre R. Expanded spectrum of *Nocardia* species causing clinical nocardiosis detected by molecular methods. *Int J Med Microbiol.* 2002;292:277–82.
- Rodríguez-Nava V, Couble A, Molinard C, Sandoval H, Boiron P, Laurent F. *Nocardia mexicana* sp. nov., a new pathogen isolated from human mycetomas. *J Clin Microbiol.* 2004;42:4530–5.
- Verroken A, Janssens M, Berhin C, et al. Evaluation of matrix-assisted laser desorption ionization-time of flight mass spectrometry for identification of *Nocardia* species. *J Clin Microbiol.* 2010;48:4015–21.
- farfour E, Leto J, Barritault M, et al. Evaluation of the Andromas matrix-assisted laser desorption ionization-time of flight mass spectrometry system for identification of aerobically growing Gram-positive bacilli. *J Clin Microbiol.* 2012;50:2702–7.
- Godreuil S, Didelot M, Perez C, et al. *Nocardia veterana* isolated from ascitic fluid of a patient with human immunodeficiency virus infection. *J Clin Microbiol.* 2003;41:2768–73.
- Conville P, Fischer S, Cartwright C, Witebsky F. Identification of *Nocardia* species by restriction endonuclease analysis of an amplified portion of the 16S rRNA gene. *J Clin Microbiol.* 2000;38:158–64.
- Arends J, Stermerding A, Vorst S, de Neeling A, Weersink A. First report of a brain abscess caused by *Nocardia veterana*. *J Clin Microbiol.* 2011;49:4364–5.
- Anderson M, Kuzniar TJ. Pulmonary nocardiosis in a patient with chronic obstructive pulmonary disease – case report and literature review. *Pneumonol Alergol Pol.* 2012;80:565–9.
- Tsujimoto N, Saraya T, Kikuchi K, et al. High-resolution CT findings of patients with pulmonary nocardiosis. *J Thorac Dis.* 2012;4:577–82.
- Gürtler V, Smith R, Mayall B, Pötter-Reinemann G, Stackebrandt E, Kroppenstedt R. *Nocardia veterana* sp. nov., isolated from human bronchial lavage. *Int J Syst Evol Microbiol.* 2001;51:933–6.
- Pottumarthy S, Limaye A, Prentice J, Houze Y, Swanzy S, Cookson B. *Nocardia veterana*, a new emerging pathogen. *J Clin Microbiol.* 2003;41:1705–9.
- Schlebusch S, Nimmo G, Carter R. Bowel abscess with *Nocardia veterana* associated with colon carcinoma. *Pathology.* 2010;42:306–7.
- Kashima M, Kano R, Mikami Y, et al. A successfully treated case of mycetoma due to *Nocardia veterana*. *Br J Dermatol.* 2005;152:1349–52.
- Kano R, Hattori Y, Murakami N, et al. The first isolation of *Nocardia veterana* from a human mycetoma. *Microbiol Immunol.* 2002;46:409–12.
- Scott M, Mehta S, Rahman HT, Grossniklaus HE, Yeh S. *Nocardia veterana* endogenous endophthalmitis in a cardiac transplant patient. *J Ophthalmic Inflamm Infect.* 2013;3:44.
- Dua J, Clayton R. First case report of *Nocardia veterana* causing nodular lymphangitis in an immunocompromised host. *Australas J Dermatol.* 2014;55:48–50.
- Al-Tawfiq J, Al-Khatti A. Disseminated systemic *Nocardia farcinica* infection complicating alefacept and infliximab therapy in a patient with severe psoriasis. *Int J Infect Dis.* 2010;14:153–7.
- Kendrick-Jones J, Ratanjee S, Taylor S, Marshall M. *Nocardia asteroides* peritoneal dialysis-related peritonitis: a case of successful treatment and return to peritoneal dialysis. *Nephrol Dial Transplant.* 2008;23:2693–4.
- Ansari S, Safdar A, Han X, O'Brien S. *Nocardia veterana* bloodstream infection in a patient with cancer and a summary of reported cases. *Int J Infect Dis.* 2006;10:483–6.