



The Brazilian Journal of INFECTIOUS DISEASES

www.elsevier.com/locate/bjid



Case report

Extra-pulmonary *Pneumocystis jiroveci* infection: a case report



Mehrdad Bakhshayesh Karam^a, Leila Mosadegh^{b,*}

^a Pediatric Respiratory Diseases Research Center, National Research Institute of Tuberculosis and Lung Diseases (NRITLD), Shahid Beheshti University of Medical Sciences, Tehran, Iran

^b Clinical Tuberculosis and Epidemiology Research Center, National Research Institute of Tuberculosis and Lung Diseases (NRITLD), Shahid Beheshti University of Medical Sciences, Tehran, Iran

ARTICLE INFO

Article history:

Received 22 January 2014

Accepted 20 May 2014

Available online 19 July 2014

Keywords:

Extrapulmonary

HIV

Pneumocystis jiroveci

ABSTRACT

In physical examination abdominal tenderness, gait disturbance and penile herpetic lesions were detected. Decreased disc height at T11–T12 level was detected in chest X-ray. Abdominal sonography and CT scan revealed hypo dense lesions in Lt left Lobe of liver and multiple hypo dense splenic and pancreatic lesions, ascitis, Lt left sided pleural effusion, thickening of jejuneal mucosa and edema of bowel wall. Vertebral body lesion and paravertebral abscess, bony calvarial involvement and adjacent extra axial brain lesion were observed in imaging were other findings. RNA analysis for HIV was positive. Vertebral lesion biopsy and aspiration of splenic lesion were performed and pathology revealed *Pneumocystis jirovecii* suggestive of extra pulmonary *Pneumocystis carinii* infection.

© 2014 Published by Elsevier Editora Ltda. Este é um artigo Open Access sob a licença de [CC BY-NC-ND](http://creativecommons.org/licenses/by-nc-nd/4.0/)

Introduction

A 46-year old man complaining of dyspnea and abdominal pain since 10 days ago that exacerbated in last 4 days is presented. He mentioned prolonged fever of 39°C, 0.5–1h each night during the last 6 months. The patient was in good general condition. The patient had previously been prescribed anti-TB treatment for suspected tuberculosis in another center based on caseating granuloma found in bone marrow aspiration by pathology and fever had subsided after 48h; however PPD and PCR for TB was not conclusive and HIV test was negative. Besides, there was history of chest

wall mass resection reporting well defined capsular structure full of necrotic material destroying underlying bones. On physical examination abdominal tenderness in right upper quadrant, gait disturbance and penile herpetic lesion were detected. He was under treatment with levothyroxin for hypothyroidism and acyclovir for herpetic lesions. CD4 count was 1.8 cells/mm³. Laboratory test results are presented in [Tables 1 and 2](#).

Regarding imaging assessment, abdominal sonography demonstrated ascitis (free fluid in abdomen and pelvic), hypoechoic lesions, calcified lesions and lesions with calcified rim in liver, two similar lesions in pancreas and similar lesions in spleen beside splenomegaly and a 5 mm stone and two calcified cyst containing debris in spleen. In chest X-ray (CXR) decreased disk height at T11–T12 level with collapsed T11 vertebral body and paravertebral soft tissue were observed. Abdominal CT showed small sized hypodense lesions in left

* Corresponding author at: 1988884516, Tehran, Iran.

E-mail address: bestlala@yahoo.com (L. Mosadegh).

<http://dx.doi.org/10.1016/j.bjid.2014.05.013>

1413-8670/© 2014 Published by Elsevier Editora Ltda.

Este é um artigo Open Access sob a licença de [CC BY-NC-ND](http://creativecommons.org/licenses/by-nc-nd/4.0/)

Table 1 – General biochemistry and hematology tests.

<i>General biochemistry</i>	
Blood sugar	93 mg/dL
Urea	64 mg/dL
Creatinine	1.5 mg/dL
SGOT	23 IU/L
SGPT	18 IU/L
LDH	566 IU/L
CPK	46 mcg/L
Alk-phosphatase	572 IU/L
Bilirubin total	0.7 mg/dL
Calcium	7.3 mg/dL
Phosphorus	4 mg/dL
Sodium	138 mg/dL
Magnesium	1.9 mg/dL
<i>General hematology</i>	
WBC	7.4 cells/ μ L
RBC	3.95 cells/ μ L
Hemoglobin	10.3 g/dL
Hematocrit	31.3%
Platelet-count	168 $\times 10^3$ / μ L
Neutrophil	85.7%
Lymphocyte	10%
Mixed Mono and Eos	4.3%
ESR	130 mm/h

lobe of liver (Fig. 1), multiple hypodense splenic (Fig. 2) and pancreatic lesions (Fig. 3), left sided pleural effusion, thickening of jejuneal mucosa and edema of bowel wall and ascites (Fig. 4). Vertebral body lesion and paravertebral abscess (Fig. 5), bony calvarial involvement and adjacent extra-axial brain lesion (Fig. 6) are other findings.

Finally, vertebral lesion biopsy and aspiration of splenic lesion were performed and pathology revealed *Pneumocystis jiroveci* suggestive of extra-pulmonary *Pneumocystis* infection.

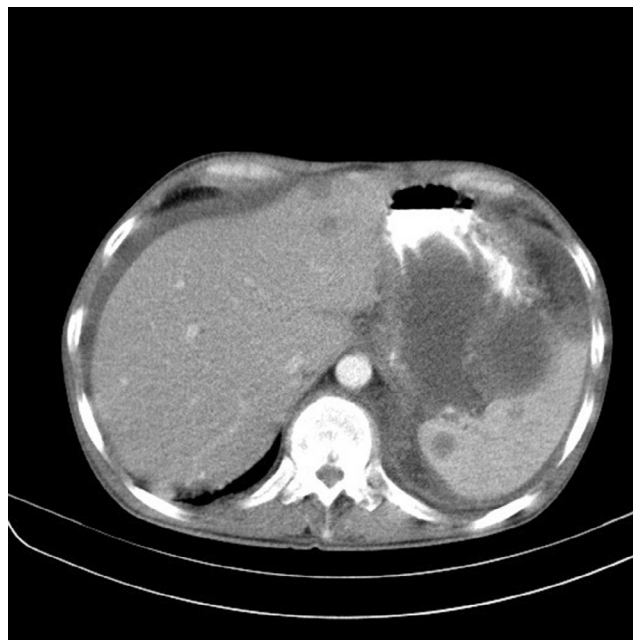During admission anti TB treatment, HIV treatment and other antibiotics including Ceftriaxone, Metronidazole, Co-trimoxazole, Imipenem and Vancomycin were ordered and Co-trimoxazole, Lamivudine, Zidovudine and Efavirenz were prescribed at discharge.

Discussion

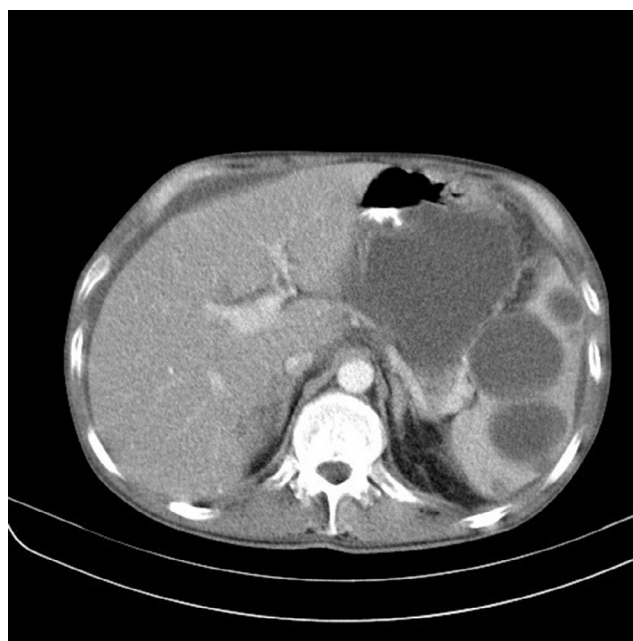Pneumocystis pneumonia (PCP) is the most common opportunistic infection in HIV-infected patients caused by *P. jiroveci*. This is a life threatening infection in advanced AIDS patients.¹ PCP mostly presents as interstitial pneumonia with symptoms

Table 2 – Body fluid, blood culture and immunology tests.

<i>Body fluid analysis</i>	
Specimen	Ascites fluid
Appearance	Turbid
RBC	Many
WBC	Many
Sugar	89 mg/dL
Protein	3.9 g/dL
LDH	1571 U/L
<i>Blood culture</i>	
Anti HIV I and II Ag/Ab	No growth after 10 days Positive

**Fig. 1 – Multiple cystic lesions in liver.**

like fever, cough, and dyspnea. CXR appearances are mostly seen as bilateral diffuse symmetric finely granular/reticular interstitial/airspace infiltration and most common CT features are patchy work pattern (56%), bilateral asymmetric patchy mosaic appearance.^{2,3} However, negative CT does not rule out the diagnosis. While PCP is the most prevalent severe pulmonary infection in HIV-infected patients, extra-pulmonary pneumocystosis is almost rare. Extra-pulmonary *Pneumocystis* infection occurs in HIV-infected patients on pentamidine prophylaxis or in advanced HIV infection without prophylaxis, even without pulmonary involvement. It can affect all organs

**Fig. 2 – Multiple cystic lesions in spleen.**

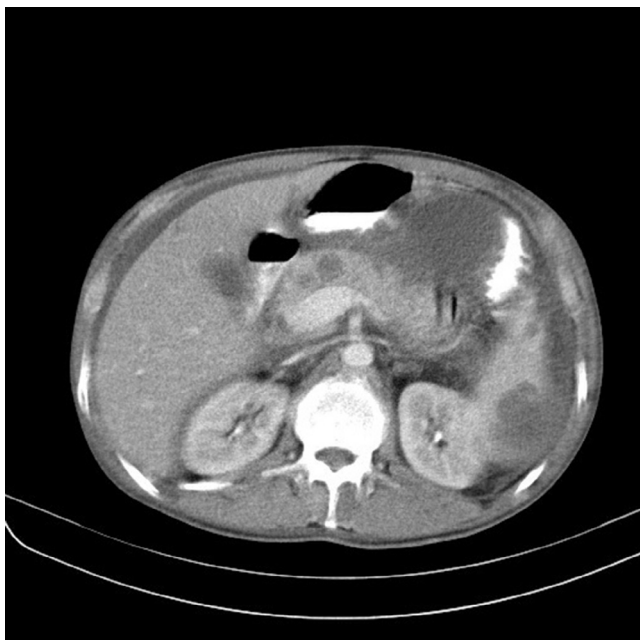

Fig. 3 – Multiple cystic lesions in pancreas.

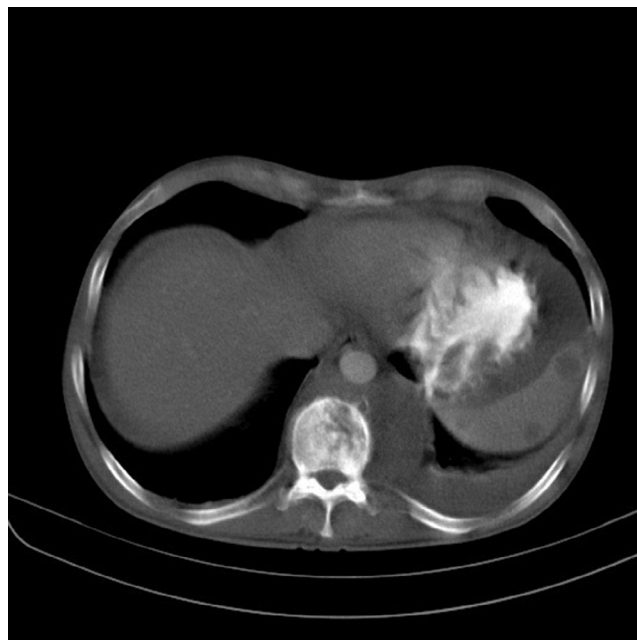


Fig. 5 – Vertebral lytic destructive lesions.

including central nervous system, bone marrow, lymph node, eye, gastrointestinal tract and thyroid.⁴ It is mentioned that as a consequence of inadequate concentration of aerosolized pentamidine to suppress systemic infection, it is a contributing factor for extra-pulmonary *Pneumocystis* infection and as a prophylaxis is insufficient to suppress dissemination.^{5,6} Low CD4 count, history of other infections, PCP and aerosolized pentamidine prophylaxis are risk factors of extra-pulmonary infection in HIV-infected patients. Extra-pulmonary infection can occur as a complication of PCP.^{7,8}

What makes our case interesting is that he was not recognized as HIV-infected until this infection broke out and only symptoms like fever brought him to the hospital and led to the diagnosis of HIV infection. Even at first laboratory test in other center, the HIV test result was negative. In this previously unrecognized HIV-infected patient, lack of important risk factors like aerosolized pentamidine or previous PCP alongside with absence of any pulmonary imaging findings made diagnosis more difficult.

To best of our knowledge, several extra-pulmonary *Pneumocystis* cases have been reported in which mostly aerosolized

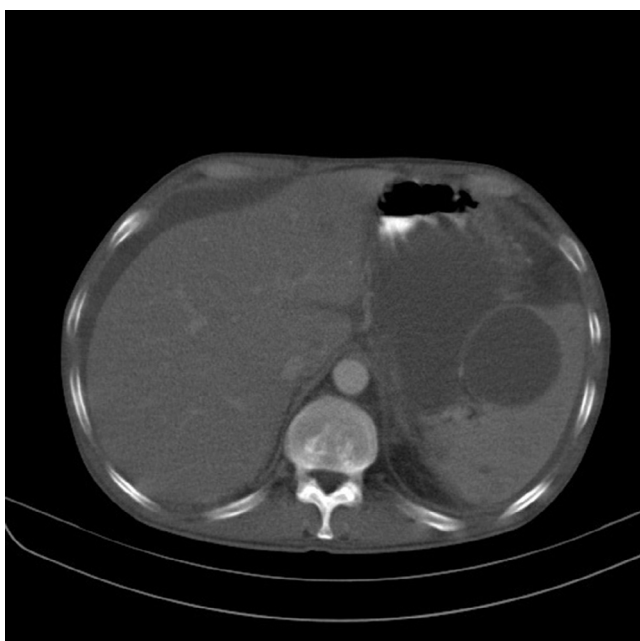

Fig. 4 – Ascitis, free intra peritoneal fluid.

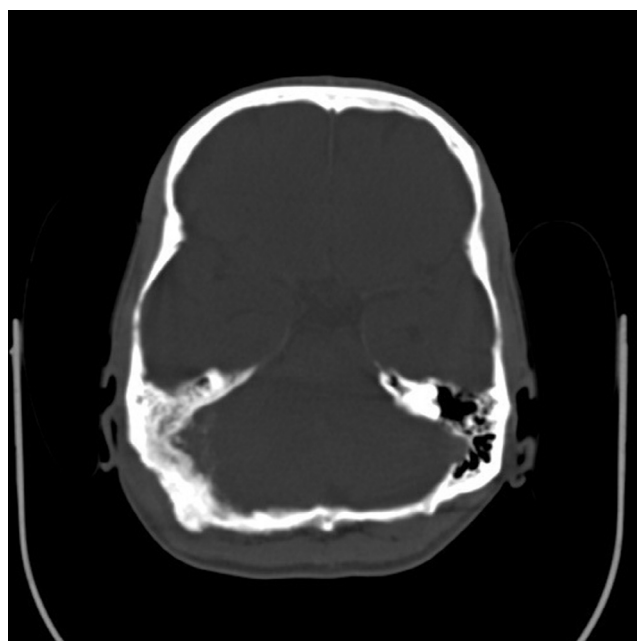


Fig. 6 – Lytic changes in right posterior occiput.

pentamidine was noted as a contributory risk factor. It is also described that recurrent PCP in patients on aerosolized pentamidine is frequent and leads to abnormalities in CXR other than interstitial infiltrate.⁹⁻¹² In Morlat study, PCP lead to diagnosis of HIV infection in 29 out of 80 patients³ but in this case extra-pulmonary disease without pulmonary findings led to HIV diagnosis. Two extra-pulmonary *Pneumocystis* infections were reported by Witt et al.,¹⁰ one disseminate to liver, spleen and kidney and the other had wide dissemination. Furthermore, Edelstein et al.¹² reported that out of 13 cases with history of PCP and on pentamidine prophylaxis, 4 cases showed recurrent PCP and one wide extra-pulmonary dissemination.

The patient presented here had no history of PCP and it was an initial appearance of *P. jiroveci* infection without any pulmonary imaging findings. Some reports of extra-pulmonary cases without pulmonary involvement are available. Region and colleagues reported an isolated thyroid pneumocystosis without any history of PCP but that case was also known to be HIV infected and on pentamidine prophylaxis.⁹ Another pneumocystis thyroiditis without pentamidine prophylaxis presented with a neck mass.¹³ Also, another case of rectal ulcer as initial manifestation of extra-pulmonary disease who was on aerosolized pentamidine and was treated with IV pentamidine. They concluded that low concentration of aerosolized than IV to suppress systemic infection is contributory parameter for extra-pulmonary *Pneumocystis*.⁵

An article review which evaluated 37 extra-pulmonary cases of *Pneumocystis* infection demonstrated that most cases had history of PCP or AIDS related infections. Pathological evaluation suggests that most cases had hematogenous and lymphatic dissemination from the lung.¹⁴ Considering cases similar to ours, in 2007 a patient with multiskeletal and gastrointestinal involvement was reported. There was a pulmonary mass of which cytology was unrevealing and the diagnosis of *P. jiroveci* was made from sternal aspiration cytology. Another HIV-infected case complaining of fever was also reported with extra-pulmonary *P. jiroveci* infection detected at the spleen without any pulmonary involvement.¹⁵ Considering bone and gastric tract involvement in our case and similar cases, like the case reported in 2007 by Panos,¹⁶ the diagnosis of pneumocystosis should be kept in mind as a differential diagnosis when these symptoms come together. Lymphadenopathy also is assumed not uncommon in extra-pulmonary *Pneumocystis*. In 2007, a 9-year old HIV-infected boy presented with generalized lymphadenopathy and fine needle aspiration cytology showed extra-pulmonary *Pneumocystis* infection.^{7,15}

P. jiroveci infection, the most common severe infection and particularly lethal in HIV-infected patients, should be carefully observed. Although diagnosing and treating PCP is not difficult, in case of dissemination survival is particularly poor, possibly because clinicians are unaware of complications of delayed treatment.⁶ Hematogenous and lymphatic dissemination from lung, reactivation of latent infection in extra-pulmonary sites or primary infection of those sites are identified as dissemination pathways based on pathology as reported by Cohen and Stoeckle¹⁴ in a study of 37 cases.

The key to diagnosis of extra-pulmonary pneumocystosis is the support of clinical microbiology and pathology. A histologi-

cal examination that reveals an eosinophilic, foamy substance surrounding cyst walls and/or trophozoites in affected tissues is generally regarded as the primary diagnostic method for extra-pulmonary pneumocystosis.¹⁵ Diagnostic imaging usually can diagnose *P. jiroveci* in lung and CT should be quite useful in diagnosing extra-pulmonary infections as the incidence of extra-pulmonary *Pneumocystis* is increasing.¹⁷

Some presentations of extra-pulmonary pneumocystosis are focal low attenuation splenic lesions that becomes progressively calcified; punctuate calcification in the liver, renal cortex and adrenal glands; lymph node calcification, and pleural and peritoneal effusion with subsequent calcification in the surface¹⁸ Enlarged heterogeneous spleen with innumerable, low attenuation, hypodense lesions; hepatomegaly; gallbladder wall thickening are some findings reported in extrapulmonary pneumocystosis, as well.¹⁵ CXR of our case demonstrated decreased disk height at T11-T12 level with collapsed T11 vertebral body and paravertebral soft tissue. Abdominal CT findings of our case consisted of small sized hypodense lesions in left lobe of liver and multiple hypodense splenic and pancreas lesions, ascitis and left sided pleural effusion, thickening of jejuneal mucosa and edema of bowel wall and ascitis. Vertebral body lesion and paravertebral abscess, bony calvarial involvement and adjacent extra-axial brain lesion are other findings.

However it is hypothesized that PCP and extra-pulmonary *Pneumocystis* infection are caused by genetic variants of *P. jiroveci* that may potentially differ in their susceptibility to therapeutic regimens; nonetheless, the standard of treatment for extra-pulmonary infection remains similar to that of PCP.¹⁵

To sum up, in face of increasing HIV epidemic and consequently *P. jiroveci* infection in our country and role of early diagnosis in survival of disseminated cases, it is very important for radiologists to be aware of suspicious imaging findings of extra-pulmonary pneumocystosis when it comes to differential diagnosis especially in HIV-infected cases. However, as it happened in our case, it can be the initial manifestation leading to HIV diagnosis, surprisingly.

Conflicts of interest

The authors declare no conflicts of interest.

REFERENCES

1. Bennett NJ. *Pneumocystis (carinii) jiroveci* pneumonia overview of PCP. Available from: <http://emedicine.medscape.com/article/225976-overview>
2. *Pneumocystis carinii* pneumonia (PCP). Learning Radiology.com. Available from: <http://www.learningradiology.com/notes/chestnotes/pneumocytispage.htm>
3. Morlat P, Bartou C, Ragnaud JM, et al. *Pneumocystis carinii* pneumonia in AIDS: retrospective analysis of 80 documented cases (1985-1993). *Rev Med Interne*. 1996;17:25-33.
4. Bennett NJ. Clinical presentation of PCP. Available from: <http://emedicine.medscape.com/article/225976-overview#aw2aab6b7>

5. Yoshida EM, Filipenko D, Phillips P, et al. AIDS-related extrapulmonary *Pneumocystis carinii* infection presenting as a solitary rectal ulcer. *Can J Gastroenterol*. 1996;10:401-4.
6. Coker RJ, Clark D, Claydon EL, et al. Disseminated *Pneumocystis carinii* infection in AIDS. *J Clin Pathol*. 1991;44:820-3.
7. Anuradha, Sinha A. Extrapulmonary *Pneumocystis carinii* infection in an AIDS patient: a case report. *Acta Cytol*. 2007;51:599-601.
8. Ng VL, Yajko DM, Hadley WK. Extrapulmonary pneumocystosis. *Clin Microbiol Rev*. 1997;10:401-18.
9. Ragni MV, Dekker A, DeRubertis FR, et al. *Pneumocystis carinii* infection presenting as necrotizing thyroiditis and hypothyroidism. *Am J Clin Pathol*. 1991;95:489-93.
10. Witt K, Nielsen TN, Junge J. Dissemination of *Pneumocystis carinii* in patients with AIDS. *Scand J Infect Dis*. 1991;23:691-5.
11. de Jong MD, Lange JM, Smits NJ, et al. *Pneumocystis carinii* infection during prophylaxis with nebulized pentamidine in a patient with AIDS. *Ned Tijdschr Geneesk*. 1991;135:424-7.
12. Edelstein H, McCabe RE. Atypical presentations of *Pneumocystis carinii* pneumonia in patients receiving inhaled pentamidine prophylaxis. *Chest*. 1990;98:1366-9.
13. Danahey DG, Kelly DR, Forrest LA. HIV-related *Pneumocystis carinii* thyroiditis: a unique case and literature review. *Otolaryngol Head Neck Surg*. 1996;158-61. Available from: <http://oto.sagepub.com/content/114/1/158.extract>
14. Cohen OJ, Stoeckle MY. Extrapulmonary *Pneumocystis carinii* infections in the acquired immunodeficiency syndrome. *Arch Intern Med*. 1991;151:1205-14.
15. O'Neal CB, Ball SC. Splenic pneumocystosis: an atypical presentation of extrapulmonary *Pneumocystis* infection. *AIDS Reader*. 2008;18:503-8. Available from: <http://www.theaidsreader.com/display/article/1145619/1362062>
16. Panos GZ, Karydis I, Velakoulis SE, et al. Multi-skeletal *Pneumocystis jiroveci* (*carinii*) in an HIV-seropositive patient. *Int J STD AIDS*. 2007;18:134-7.
17. Birnbaum BA, Megibow AJ, Balthazar EJ, et al. Extrapulmonary *Pneumocystis carinii* infection in AIDS: CT findings. *Radiology*. 1990;174:157-60. Available from: <http://www.readabstracts.com/Health/Extrapulmonary-Pneumocystis-carinii-infection-in-AIDS-CT-findings.html>
18. Lubat E, Megibow AJ, Balthazar EJ, Goldenberg AS, Birnbaum BA, Bosniak MA. Extrapulmonary *Pneumocystis carinii* infection in AIDS: CT findings. *Radiology*. 1990;174:157-60.