



# The Brazilian Journal of INFECTIOUS DISEASES

[www.elsevier.com/locate/bjid](http://www.elsevier.com/locate/bjid)



## Letter to the Editor

# Staphylococcal scalded skin syndrome in an adult, immunocompetent patient



Dear Editor,

An 87-year old female patient, with history of chronic obstructive pulmonary disease, was referred to our hospital with rash and septic shock. She was obese (body mass index 46 kg/m<sup>2</sup>) and had a recent history of left shin cellulitis, for which she had received clindamycin. The patient's main clinical findings on presentation were hypotension, tachypnea, anuria and severe exfoliation of the skin affecting the entire body (Fig. 1). Nikolsky sign was elicited on patient's physical examination (Fig. 2). The diagnosis of Staphylococcal scalded skin syndrome (SSSS) was clinically established and empiric therapy with vancomycin was started as well as supportive care with fluids and oxygen. The patient died 24 h after admission, after having developed multiple organ dysfunction syndrome.

SSSS, also known as Pemphigus neonatorum or Ritter's disease, is caused by exotoxins released by *Staphylococcus aureus*, which act as proteases breaking down desmosomes.<sup>1</sup> This results in the separation of the epidermis beneath the granular cell layer and the appearance of the disease's characteristic red rash. The condition is commonest in children and infants, where prognosis is considered to be favorable if appropriate therapy is given. On the other hand, SSSS is rare in adults, but the mortality rate is significantly higher (greater than 60%).<sup>2</sup> It is mainly observed among immunosuppressed individuals or subjects with severe chronic diseases. Laboratory or imaging studies are of limited diagnostic use of the syndrome. Nevertheless, *S. aureus* can be isolated from blood cultures. Nikolsky sign, named after Russian physician Pyotr Nikolsky who first described it in 1896, is present when the top layer of the skin slips off with rubbing or on gentle pressure.<sup>3</sup> The sign is elicited in patients with SSSS, as well as in other conditions, with toxic epidermal necrolysis being the most identifiable. Treatment options in SSSS include supportive measures, such as fluids and antipyretic drugs. However, the key point is the control of the underlying staphylococcal infection with appropriate antibiotic therapy. Intensive care unit support is often a necessity for patients with SSSS.

In conclusion, despite being uncommon in adults, SSSS represents a therapeutic challenge for any physician, because of its significantly higher mortality rate.

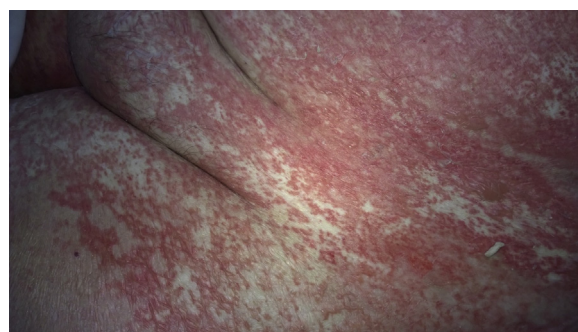


Fig. 1 – Severe exfoliation of the skin in patient's abdomen.

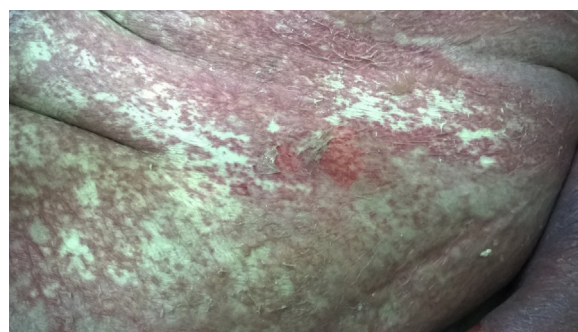

Fig. 2 – Positive Nikolsky sign.

## Conflicts of interest

The authors declare no conflicts of interest.

## REFERENCES

- Hayakawa Y, Hashimoto N, Imaizumi K, Kaidoh T, Takeuchi S. Genetic analysis of exfoliative toxin A-producing *Staphylococcus aureus* isolated from mastitic cow's milk. *Vet Microbiol.* 2001;78:39-48.

2. Patel GK, Finlay AY. Staphylococcal scalded skin syndrome: diagnosis and management. *Am J Clin Dermatol*. 2003;4:165–75.
3. van Gijn J, Gijssels J, Nikolsky and his sign. *Ned Tijdschr Geneeskd*. 2011;155:A2846.

Theocharis Koufakis\*, Ioannis Gabranis,  
Konstantinos Karanikas

*Department of Internal Medicine, General Hospital of Larissa,  
Larissa, Greece*

\*Corresponding author at: 49 Ioustinianou Street,  
P.C. 41223 Larissa, Greece.  
E-mail address: [thkoyfak@hotmail.com](mailto:thkoyfak@hotmail.com) (T. Koufakis).

Received 6 December 2014

Accepted 10 December 2014

Available online 18 February 2015

<http://dx.doi.org/10.1016/j.bjid.2014.12.011>

1413-8670/© 2015 Elsevier Editora Ltda. All rights reserved.