

# Myxoid Dermatofibrosarcoma Protuberans of the Scrotum: Rare Tumor in an Uncommon Location

Hamdi Mohamed Isse <sup>1</sup>, Senai Goitom Sereke <sup>1</sup>, Geoffrey Erem<sup>1,2</sup>

<sup>1</sup>Department of Radiology and Radiotherapy, School of Medicine, Makerere University College of Health Sciences, Kampala, Uganda; <sup>2</sup>Department of Radiology, Nsambya Hospital, Kampala, Uganda

Correspondence: Hamdi Mohamed Isse, Department of Radiology and Radiotherapy, Makerere University College of Health Sciences, Kampala, Uganda, Tel +256-701512600, Email drhamdisom@gmail.com

**Background:** Dermatofibrosarcoma protuberans (DFSP) is an uncommon tumor that involves the skin with a low metastatic rate; however, this tumor has a tendency to recur locally. Myxoid DFSP is a rare variant, with a few cases mentioned in the literature, and may present diagnostic difficulties on histopathological examination.

**Case Presentation:** We present a 9-year-old male with a history of a left scrotal mass for 3 years. An enhanced computed tomography (CT) scan of the pelvis showed a heterogeneously enhancing mass in the scrotum with extension into both inguinal regions. Histology showed spindle-shaped cells forming a storiform pattern in the hypercellular area and myxoid stroma with prominent thin-walled vessels. Immunohistochemically, the cluster of differentiation 34 (CD34) was positive. The mass was removed by surgical excision with negative resection edges, and then adjuvant radiotherapy of 60 Gy was given. The patient had a good outcome with treatment and was doing well on follow-up.

**Conclusion:** This variant of sarcoma is rare and often presents a diagnostic challenge. Early detection is crucial to prevent both undertreatment and overtreatment.

**Keywords:** dermatofibrosarcoma, myxoid, scrotum, computed tomography

## Background

Dermatofibrosarcoma protuberans (DFSP) is a rare dermal tumor. It encompasses around 1% of soft tissue sarcomas, with frequently slow growth and a likelihood of regional/distant metastases of less than 2–3%.<sup>1,2</sup> DFSP often affects patients aged 20–50 years. According to the literature review, the predicted incidence of DFSP is approximately 3–4.2 cases per million people per year, with equal gender distribution.<sup>3,4</sup> Although DFSP may have been mentioned in the literature at the beginning of 1890, Hoffman properly formulated the word dermatofibrosarcoma protuberans in 1925.<sup>5</sup>

DFSP can start as a small hard area of the skin or it can look like a blemish or birthmark.<sup>6</sup> DFSP is a slow-growing tumor which commonly originates on the torso but can also be seen on the arms, legs, head, and neck.<sup>7</sup> Approximately 90% of DFSP cases are low-grade sarcomas,<sup>8</sup> while 10% are mixed with a high-grade sarcomatous component (DFSP-FS); hence, they are regarded as intermediate-grade sarcomas.<sup>7,8</sup> Over 90% of DFSP cases have chromosomal translocation t(17;22).<sup>7</sup>

DFSP is locally aggressive but rarely metastasizes to local lymph nodes or distant sites.<sup>9</sup> Several histological variants are recognized, and myxoid DFSP expresses a rare structural variant with foremost myxoid stromal changes that may lead to substantial diagnostic challenges, especially in the differentiation from other aggressive myxoid mesenchymal tumors.<sup>10</sup> The pathognomic feature of DFSP is a characteristic arrangement of spindle-shaped tumor cells<sup>11</sup> with positive staining for CD34 on immunohistochemistry.<sup>12</sup> The diagnosis of DFSP is reached with a biopsy.<sup>8</sup> Herein, we report the case of a 9-year-old child with histologically and immunohistochemically confirmed myxoid DFSP.

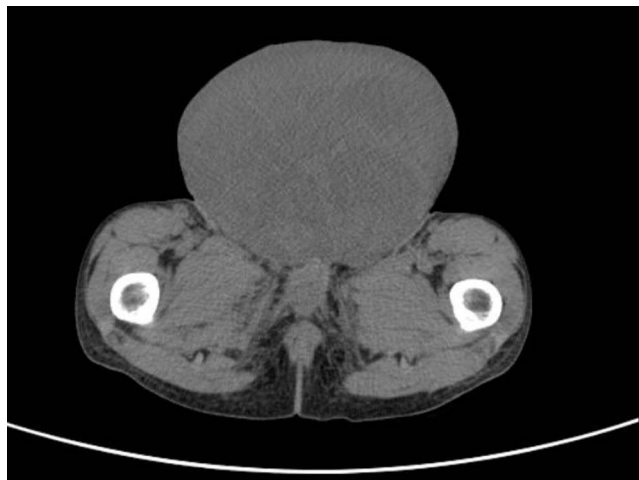
## Case Presentation

A 9-year-old male patient presented to the Urology Department of Mulago National Referral Hospital with a history of a painless scrotal mass, which was initially small in size and had gradually increased in size over 3 years. As a baby, he was fairly well until the scrotal swelling ensued. His early childhood was unremarkable.

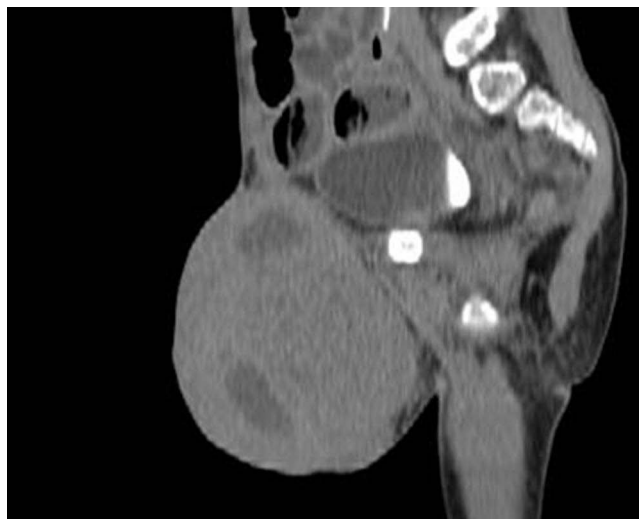Physical examination revealed a non-tender fixed-left scrotal mass of 5 cm in diameter. The overlying skin was intact. No palpable regional lymph nodes seen.

A complete blood count showed hemoglobin of 12.3 g/dL and a white blood cell count of 7600 cells/mm<sup>3</sup>. The liver and renal function tests were within normal limits.

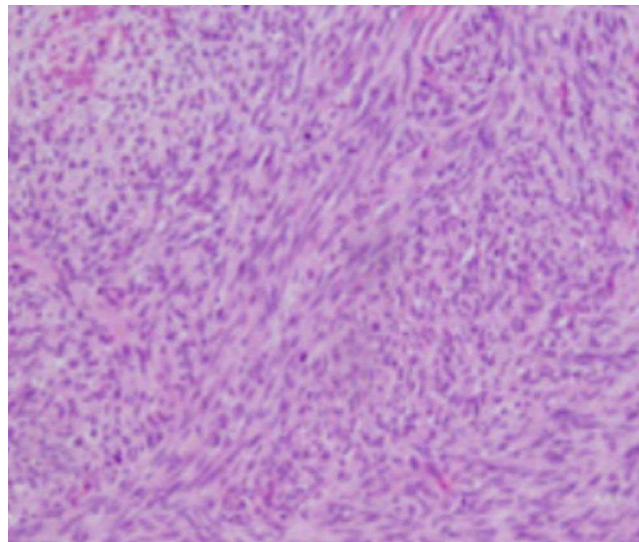
An enhanced computed tomography (CT) scan of the abdomen and pelvis for local staging and assessment of distant metastasis demonstrated a heterogeneously enhancing mass (30–55 HU), occupying the region of the scrotum extending into both inguinal regions and the pelvis, making it difficult to delineate the testicles (Figures 1 and 2). No bone erosion was detected. The abdomen was negative for metastasis. The chest X-ray was also unremarkable.



**Figure 1** Axial enhanced CT scan of the pelvis showing a heterogeneously enhancing mass occupying the scrotum region.



**Figure 2** Sagittal reformatted enhanced CT scan of the pelvis showing a heterogeneously enhancing mass occupying the scrotum region.



**Figure 3** H&E stained section showing a relatively hypercellular area consisting of spindle-shaped cells forming a storiform pattern.

An ultrasound-guided Tru-Cut biopsy was carried out and the sample was sent for histopathological and immunohistochemical examination.

In the histopathological review, the hematoxylin and eosin-stained section revealed a tumor composed of sheets of bland cells with spindle-shaped nuclei and pale eosinophilic cytoplasm forming a storiform pattern and diffusely infiltrating the underlying adipose tissue. Myxoid stroma with prominent thin-walled vessels was seen (Figure 3). The tumor cells were diffusely and vigorously positive for CD34.

Surgical removal was performed, with negative resection edges, and the patient was placed on adjuvant radiotherapy. He received a total dose of 60 Gy using conventional external beam radiotherapy with a cobalt-60 machine, in fractions of 2 Gy per day, using direct anterior fields to the primary tumor site. He completed the treatment with no immediate or late complications and good tolerance. The patient was doing well on follow-up.

## Discussion

DFSP is an uncommon tumor of the skin. It generally behaves as a benign tumor, with metastasis in 2–5% of cases.<sup>13</sup> The growth of DFSP is indolent; however, this tumor has a tendency to recur locally owing to its vigorous ability to infiltrate subcutaneous tissue, fascia, and underlying muscle.<sup>14</sup> The first case of the rare myxoid variant of DFSP was published in 1983 by Frierson and Cooper.<sup>15</sup> Hong et al<sup>16</sup> revealed another case of this clinical form infrequently mentioned in the literature, with noticeable myxoid stroma changes. Tantcheva-Poor et al<sup>17</sup> described a vascular histological variant of DFSP. A review of the literature revealed 23 cases of myxoid variant of DFSP emerging in different areas, with the foremost site being the extremities, accompanied by the head and neck, but no cases in the scrotum, as in our case.<sup>18</sup>

The age and sex distribution of myxoid DFSP are close to those of DFSP, with roughly equal sex distribution and an extensive age distribution, ranging from 9 months to 72 years (median 40 years).<sup>19</sup> Mentzel et al published eight cases of the myxoid variant of DFSP, with a median age of 51 years, with the majority affecting the inguinal region.<sup>20</sup> The case presented in this report, with an age at presentation of 9 years, contrasts with the previous studies.

Reimann and Fletcher described myxoid DFSP as DFSP with myxoid stroma of more than 50%.<sup>18</sup> In concurrence with this report, greater than 60% of myxoid DFSP in the presented case showed prominent myxoid stromal changes. Immunohistochemically, the majority of the dermatofibrosarcoma stains positive for CD34,<sup>12</sup> Similarly, in our case it was also positive. The histopathological differential diagnosis of myxoid DFSP is varied, and includes benign and malignant tumors.<sup>6</sup> Among the benign types of DFSP, superficial angiomyxoma, myxoid neurofibroma, superficial acral fibromyxoma, nodular fasciitis, and solitary fibrous tumor should be considered.<sup>21</sup> Some tumors, such as

superficial angiomyxoma, can be difficult to differentiate from myxoid DFSP, as both neoplasms have a myxoid stroma rich in blood vessels and express CD34 on their cells.<sup>22</sup> However, superficial angiomyxomas are less cellular and have a lobular shape, rather than the infiltrative pattern seen in myxoid DFSP, and 25% of the cases contain epithelial structures as well as neutrophils.<sup>23</sup> The most common site of metastasis is the lung, but metastasis to the brain, bone, heart, lymph nodes, pancreas, orbit, and testis has also been reported.<sup>24</sup> In this case, no metastasis was seen.

DFSP has non-specific features on imaging.<sup>25</sup> Radiological imaging plays a crucial role in assessing the primary tumor and diagnosing metastatic lesions for appropriate management of the patient.<sup>26</sup> CT scanning is desirable if direct bone involvement or metastasis is suspected.<sup>5</sup> The diagnosis of DFSP is confirmed by histology.<sup>27</sup>

The mainstay of management for DFSP is primarily surgical, with neoadjuvant chemotherapy and radiotherapy generally used.<sup>28</sup> Radiation may be delivered either preoperatively (50 Gy in 25 fractions) or postoperatively (60 Gy in 30 fractions, with higher doses up to 66 Gy in 33 fractions for patients with positive surgical operation margins).<sup>29</sup> Our patient received 60 Gy in 30 fractions of external beam radiotherapy with radical intent, and had negative resection margins. The patient had a good outcome with treatment and was doing well on follow-up.

## Conclusions

Myxoid DFSP is rare in the scrotum and often presents a diagnostic challenge. Early recognition is crucial to prevent both undertreatment and overtreatment. The increased recurrence rate warrants continual follow-up of both clinical and radiological assessment.

## Abbreviations

CD, cluster of differentiation; CT, computed tomography; DFSP, dermatofibrosarcoma protuberans.

## Data Sharing Statement

The data utilized and/or analyzed during this case report are available from the corresponding author on reasonable request.

## Ethics Approval and Consent to Participate

No institutional endorsement was required to publish the case details. The parents of the child gave informed written consent to participate in the study of their child's condition.

## Consent for Publication

The parents of the child gave informed written consent for this case to be published in a peer-reviewed journal.

## Acknowledgments

We would like to acknowledge the patient and his parents, and the staff of the urology and radiology departments of Mulago National Referral Hospital, for active participation during the process of data collection and follow-up updates on the patient.

## Author Contributions

All authors made a crucial contribution to the work reported, whether that's within the conception, study design, execution, acquisition of data, analysis, and interpretation, or in all these areas; took part in drafting, revising, or critically reviewing the article; gave final approval of the version to be published; have concurred on the journal to which the article has been submitted; and concur to be responsible for all angles of the work.

## Funding

There is no funding to report.

## Disclosure

The authors declare that they have no competing interests.

## References

1. Chang CK, Jacobs IA, Salti GI. Outcomes of surgery for dermatofibrosarcoma protuberans. *Eur J Surg Oncol*. 2004;30(3):341–345. doi:10.1016/j.ejso.2003.12.005
2. Laskin WB. Dermatofibrosarcoma protuberans. *CA Cancer J Clin*. 1992;42(2):116–125. doi:10.3322/canjclin.42.2.116
3. Simon MP, Pedeutour F, Sirvent N, et al. Deregulation of the platelet-derived growth factor B-chain gene via fusion with collagen gene COL1A1 in dermatofibrosarcoma protuberans and giant-cell fibroblastoma. *Nat Genet*. 1997;15(1):95–98. doi:10.1038/ng0197-95
4. Monnier D, Vidal C, Martin L, et al. Dermatofibrosarcoma protuberans: a population-based cancer registry descriptive study of 66 consecutive cases diagnosed between 1982 and 2002. *J Eur Acad Dermatol Venereol*. 2006;20(10):1237–1242. doi:10.1111/j.1468-3083.2006.01780.x
5. Lemm D, Mügge L-O, Mentzel T, Höflken K. Current treatment options in dermatofibrosarcoma protuberans. *J Cancer Res Clin Oncol*. 2009;135(5):653–665. doi:10.1007/s00432-009-0550-3
6. Brooks J, Ramsey ML. Dermatofibrosarcoma protuberans. In: *StatPearls [Internet]*. Treasure Island (FL): StatPearls Publishing; 2022. Available from: <http://www.ncbi.nlm.nih.gov/books/NBK513305/>. Accessed August 12, 2022.
7. Sirvent N, Maire G, Pedeutour F. Genetics of dermatofibrosarcoma protuberans family of tumors: from ring chromosomes to tyrosine kinase inhibitor treatment. *Genes Chromosomes Cancer*. 2003;37(1):1–19. doi:10.1002/gcc.10202
8. Patel KU, Szabo SS, Hernandez VS, et al. Dermatofibrosarcoma protuberans COL1A1-PDGFB fusion is identified in virtually all dermatofibrosarcoma protuberans cases when investigated by newly developed multiplex reverse transcription polymerase chain reaction and fluorescence in situ hybridization assays. *Hum Pathol*. 2008;39(2):184–193. doi:10.1016/j.humpath.2007.06.009
9. Sardesai VR, Patil RM, Agarwal TD. Dermatofibrosarcoma Protuberans at an Uncommon Site. *Indian J Dermatol*. 2014;59(6):635. doi:10.4103/0019-5154.143602
10. Dupree WB, Langloss JM, Weiss SW. Pigmented dermatofibrosarcoma protuberans (Bednar tumor). A pathologic, ultrastructural, and immunohistochemical study. *Am J Surg Pathol*. 1985;9(9):630–639. doi:10.1097/00000478-198509000-00002
11. Taylor HB, Helwig EB. Dermatofibrosarcoma protuberans. A study of 115 cases. *Cancer*. 1962;15:717–725. doi:10.1002/1097-0142(196207/08)15:4<717::AID-CNCR2820150405>3.0.CO;2-2
12. Mentzel T, Beham A, Katenkamp D, Dei Tos AP, Fletcher CD. Fibrosarcomatous (“high-grade”) dermatofibrosarcoma protuberans: clinicopathologic and immunohistochemical study of a series of 41 cases with emphasis on prognostic significance. *Am J Surg Pathol*. 1998;22(5):576–587. doi:10.1097/00000478-199805000-00009
13. Mendenhall WM, Zlotecki RA, Scarborough MT. Dermatofibrosarcoma protuberans. *Cancer*. 2004;101(11):2503–2508. doi:10.1002/cncr.20678
14. Pack GT, Tabah EJ. Dermatofibrosarcoma protuberans: a report of thirty-nine cases. *AMA Arch Surg*. 1951;62(3):391–411. doi:10.1001/archsurg.1951.01250030397008
15. Frierson HF, Cooper PH. Myxoid variant of dermatofibrosarcoma protuberans. *Am J Surg Pathol*. 1983;7(5):445–450. doi:10.1097/00000478-198307000-00007
16. Hong YJ, Choi YW, Myung KB, Choi HY. A case of myxoid dermatofibrosarcoma protuberans. *Ann Dermatol*. 2011;23(3):379–381. doi:10.5021/ad.2011.23.3.379
17. Tancheva-Poor I, Marathovouniotis N, Kutzner H, Mentzel T. Vascular congenital dermatofibrosarcoma protuberans: a new histological variant of dermatofibrosarcoma protuberans. *Am J Dermatopathol*. 2012;34(4):e46–e49. doi:10.1097/DAD.0b013e318234e704
18. Reimann JDR, Fletcher CDM. Myxoid dermatofibrosarcoma protuberans: a rare variant analyzed in a series of 23 cases. *Am J Surg Pathol*. 2007;31(9):1371–1377. doi:10.1097/PAS.0b013e31802ff7e7
19. Gorlick R, Anderson P, Andrulis I, et al. Biology of childhood osteogenic sarcoma and potential targets for therapeutic development: meeting summary. *Clin Cancer Res*. 2003;9(15):5442–5453.
20. Mentzel T, Schärer L, Kazakov DV, Michal M. Myxoid dermatofibrosarcoma protuberans: clinicopathologic, immunohistochemical, and molecular analysis of eight cases. *Am J Dermatopathol*. 2007;29(5):443–448. doi:10.1097/DAD.0b013e318145413c
21. Zou Y, Billings SD. Myxoid cutaneous tumors: a review. *J Cutan Pathol*. 2016;43(10):903–918. doi:10.1111/cup.12749
22. Abdulfatah E, Chaudhry R, Bandyopadhyay S, Qureshi F. Myxoid dermatofibrosarcoma protuberans of the scrotum: a rare diagnosis in an unreported location. *Hum Pathol*. 2016;6:40–44.
23. Calonje E, Guerin D, McCormick D, Fletcher CD. Superficial angiofibroma: clinicopathologic analysis of a series of distinctive but poorly recognized cutaneous tumors with tendency for recurrence. *Am J Surg Pathol*. 1999;23(8):910–917. doi:10.1097/00000478-199908000-00008
24. Chrysogonidis I, Vorkas G, Papadopoulos C, Lytras C. Testicular metastasis of dermatofibrosarcoma protuberans: a case report - An Ultrasonography approach. *Arch Oncol*. 2002;10(1):33–34. doi:10.2298/AOO0201033C
25. Zhang L, Liu Q, Cao Y, Zhong J, Zhang W. Dermatofibrosarcoma protuberans: computed tomography and magnetic resonance imaging findings. *Medicine*. 2016;94(24):e1001. doi:10.1097/MD.0000000000001001
26. Hao X, Billings SD, Wu F, et al. Dermatofibrosarcoma protuberans: update on the diagnosis and treatment. *J Clin Med*. 2020;9(6):1752. doi:10.3390/jcm9061752
27. Garcia C, Clark RE, Buchanan M. Dermatofibrosarcoma protuberans. *Int J Dermatol*. 1996;35(12):867–871. doi:10.1111/j.1365-4362.1996.tb05053.x
28. Wiesmueller F, Agaimy A, Perrakis A, et al. Dermatofibrosarcoma protuberans: surgical management of a challenging mesenchymal tumor. *World J Surg Oncol*. 2019;17(1):90. doi:10.1186/s12957-019-1627-3
29. Castle KO, Guadagnolo BA, Tsai CJ, Feig BW, Zagars GK. Dermatofibrosarcoma protuberans: long-term outcomes of 53 patients treated with conservative surgery and radiation therapy. *Int J Radiat Oncol Biol Phys*. 2013;86(3):585–590. doi:10.1016/j.ijrobp.2013.02.024

**International Medical Case Reports Journal**

Dovepress

**Publish your work in this journal**

The International Medical Case Reports Journal is an international, peer-reviewed open-access journal publishing original case reports from all medical specialties. Previously unpublished medical posters are also accepted relating to any area of clinical or preclinical science. Submissions should not normally exceed 2,000 words or 4 published pages including figures, diagrams and references. The manuscript management system is completely online and includes a very quick and fair peer-review system, which is all easy to use. Visit <http://www.dovepress.com/testimonials.php> to read real quotes from published authors.

Submit your manuscript here: <https://www.dovepress.com/international-medical-case-reports-journal-journal>