


CASE REPORT

Open Access



# Duplication of *SOX3* in an *SRY*-negative 46,XX male with prostatic utricle: case report and literature review

Jiansheng Wei<sup>\*</sup> , Changrong Liu, Minyan Zhang, Shen Liu, Junjie Fu and Peng Lin

## Abstract

**Background:** 46,XX male disorders of sex development are rare. Approximately 80% of cases of testicular tissue differentiation may be due to translocation of *SRY* to the X chromosome or an autosome. *SRY*-negative 46,XX males show overexpression of pro-testis genes, such as *SOX9* and *SOX3*, or failure of pro-ovarian genes, such as *WNT4* and *RSPO1*, which induces testis differentiation, however, almost all testicles exhibit dysgenesis. Following inadequate exposure to androgens during the embryo stage, remnants of the Mullerian duct and incomplete closure of the urogenital sinus lead to enlargement of prostatic utricles. This condition is associated with proximal hypospadias and disorders of sex development. Many cases are asymptomatic, but show increased rates of postoperative complications and surgical failure.

**Case presentation:** A 5-year-old Chinese boy with scrotal hypospadias and bilateral cryptorchidism with prostatic utricles was presented. Gonadal histology showed ovo-testicular tissue on the right side and testicular tissue on the left side; all testicular tissue exhibited dysgenesis. Furthermore, chromosome karyotype analysis revealed 46,XX and, the presence of *SRY* was ruled out by polymerase chain reaction analysis. Whole-genome analysis showed the boy has a 1.4-Mb duplication in the Xq27.1q27.2 region (arr[hg19]Xq27.1q27.2:139585794–140996652) involving *SOX3*. No *SOX3* duplication was observed in the parents, who had a normal phenotype.

**Conclusions:** We report the first case of an *SRY*-negative 46 XX male with prostatic utricle caused by *SOX3* duplication. *SOX3* duplication may cause sex reversal, and all 46,XX *SRY*-negative males should be screened for *SOX3* mutations. Gonadal biopsy is recommended to evaluate ovarian and testicular tissue development. Testicular dysgenesis and low exposure to male hormones during fetal development can lead to enlarged prostatic utricles. Thus endoscopic examination should be performed preoperatively to detect prostatic utricles in *SRY*-negative 46,XX males to determine the surgical plan and reduce postoperative complications.

**Keywords:** Disorder of sex development, *SOX3*, Prostatic utricle, Case report

## Background

Ovotesticular male disorders of sex development (OT-DSD) are rare worldwide. These disorders show differing prevalence and karyotypes; however, the 46,XX

karyotype is the most common (65–90%) [1]. This presentation results from the translocation of *SRY* to the X chromosome or, more rarely, to the autosomes. The *SRY*-negative phenotype is rare and can be explained by two different mechanisms: overexpression of pro-testis genes, such as *SOX9* and *SOX3*, and failure of pro-ovarian genes, such as *WNT4* and *RSPO1* [2]. *SOX3* mutation-induced sex reversal may be driven by the shared analogous function of *SOX3* and *SRY*, cooperation with SF1 to

\*Correspondence: wjs0831169@outlook.com

Department of Pediatric Urology, Fuzhou Children's Hospital of Fujian Province, 145 Ba-yi-qi road, Fuzhou, Fujian Province, China



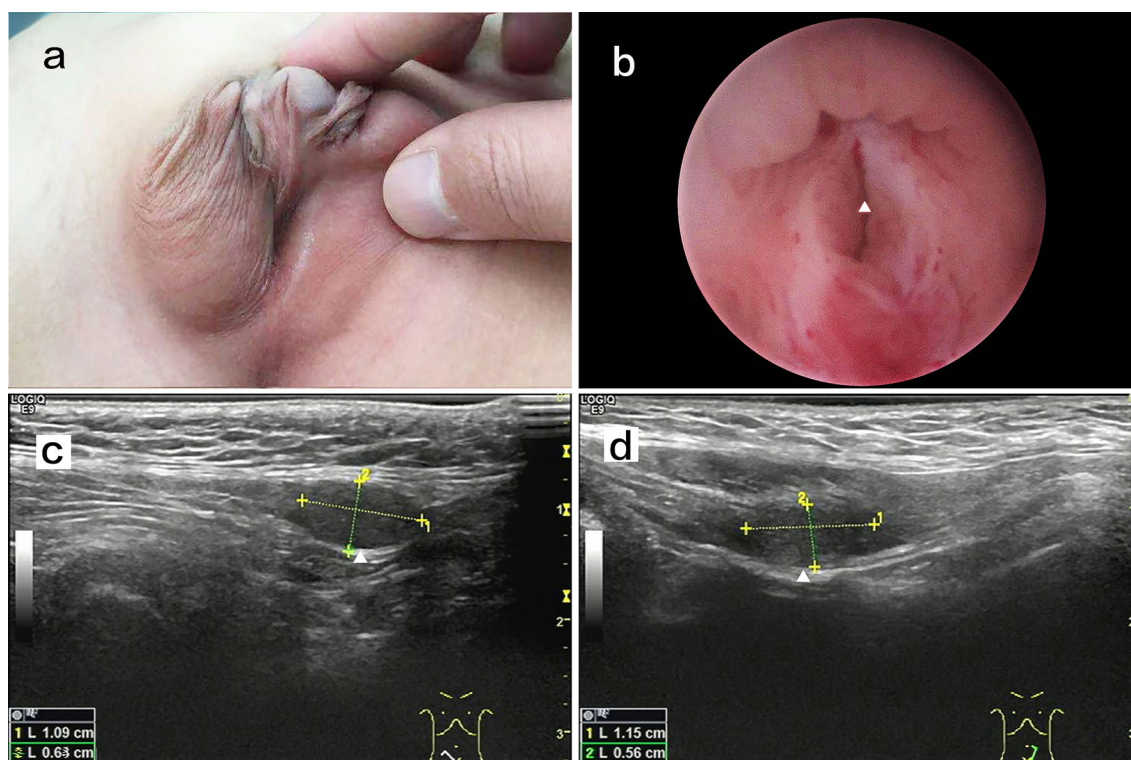
© The Author(s) 2022. **Open Access** This article is licensed under a Creative Commons Attribution 4.0 International License, which permits use, sharing, adaptation, distribution and reproduction in any medium or format, as long as you give appropriate credit to the original author(s) and the source, provide a link to the Creative Commons licence, and indicate if changes were made. The images or other third party material in this article are included in the article's Creative Commons licence, unless indicated otherwise in a credit line to the material. If material is not included in the article's Creative Commons licence and your intended use is not permitted by statutory regulation or exceeds the permitted use, you will need to obtain permission directly from the copyright holder. To view a copy of this licence, visit <http://creativecommons.org/licenses/by/4.0/>. The Creative Commons Public Domain Dedication waiver (<http://creativecommons.org/publicdomain/zero/1.0/>) applies to the data made available in this article, unless otherwise stated in a credit line to the data.

upregulate *SOX9* expression, and induction of Sertoli cell differentiation in the bipotential gonad ridges [2]. A previous study reported cases of hypospadias, bilateral cryptorchidism, and kidney abnormality [3]. In our case, we additionally observed an enlarged prostatic utricle, which to our knowledge is the first instance of this phenotype observed in this specific type of DSD. The embryological origin of the prostatic utricle remains controversial. It was previously considered as a remnant of the Müllerian ducts, however, a recent study showed it to be derived from the urogenital sinus [4]. Either way, the prostatic utricle dilates when exposure to male hormones is low during fetal development [5]. In an *SRY*-negative 46,XX male, lack of the Y chromosome results in inadequate differentiation of the testis, an insufficient hormone dosage during critical periods, induction of remnant Mullerian ducts and incomplete closure of the urogenital sinus [6].

### Case presentation

The patient was 5 years old and was referred to our department for ambiguous sex; he was the second child of a non-consanguineous couple. His parents and sister were healthy. The patient's birth weight was 3.5 kg and length was 50 cm, which were within normal ranges; his

intelligence was normal, and he had no pertinent medical history. At 5 years old, the patient's height was 117 cm and weight was 20.5 kg. Physical examination revealed scrotal hypospadias and bilateral cryptorchidism (Fig. 1a). The bilateral gonads (approximately 1.0 × 0.6 cm) were palpated in the upper inguinal region. Ultrasonography indicated bilateral cryptorchidism with a normal testicular morphology (Fig. 1c, d). Abdominal ultrasound did not show internal female genitalia, and echocardiogram results were normal. Hormonal laboratory tests showed low basal levels of testosterone (T; <2.5 ng/dL); the post-3-day human chorionic gonadotropin stimulation test showed an increase in T to 62.90 ng/dL, and the post-human chorionic gonadotropin test showed a normal level of double hydrogen testosterone (80.37 pg/mL). Thus, there was a good T response to human chorionic gonadotropin stimulation. Luteinizing hormone was low (<0.1 IU/L) and follicle stimulating hormone was normal (0.4 IU/L). Anti-Müllerian hormone (48.48 ng/mL), prolactin (4.87 ng/mL), and 17- $\alpha$ -hydroxyprogesterone (0.8 nmol/L) levels were also normal (Table 1). As patient growth and development were normal, we did not screen for growth hormone or adreno-cortico-tropic hormone.



**Fig. 1** **a** Physical examination revealed scrotal hypospadias and bilateral cryptorchidism. **b** Pre—operation cystoscopy showing an orifice in the prostatic urethra; the white arrow indicates the prostatic urethra orifice. **c** Ultrasonography showing that the right testicle is in the inguinal canal; the morphology was normal. **d** Ultrasonography showing that the left testicle is in the inguinal canal; the morphology was normal

**Table 1** Hormonal laboratory tests

Hormonal laboratory tests	Result	Reference range
testosterone		
basal	< 2.5 ng/dl	
Post HCG	62.90 ng/dl	
		T difference value > 10 ng/dl
Post HCG DHT	80.37 pg/ml	
		T/DHT < 10
AMH	48.48 ng/ml	Male(> 4 years):37.88–298.52 ng/ml Female(> 4years):0.05–7.02 ng/ml
LH	< 0.1 IU/L	0– 4.10 IU/L
FSH	0.4 IU/L	0–1.90 IU/L
Prolactin	4.87 ng/ml	2.00–43.00 ng/ml
17- $\alpha$ -hydroxyprogesterone	0.8 nmol/l	0–11.5 nmol/l

HCG: Human Chorionic Gonadotropin. DHT: Double Hydrogen Testosterone. AMH: Anti-Mullerian hormone. LH: Luteinizing Hormone. FSH: Follicle Stimulating Hormone

The chromosome karyotype was 46,XX, and the presence of SRY was ruled out by polymerase chain reaction analysis. Therefore, we performed whole-genome analysis for genetic detection. Genomic DNA was extracted from blood samples using the DNeasy Blood & Tissue Kit (Qiagen, Hilden, Germany). The DNA quantity of sequencing library was assessed by Qubit 2.0 fluorometer (Thermo Fisher Scientific, Massachusetts, United States). The quality and size of libraries were measured by 2100 Bioanalyzer High Sensitivity DNA Assay (Agilent Technologies, California, United States). The qualified libraries were sequenced using the 2 × 150-bp paired-end sequencing on the Illumina NovaSeq platform (Illumina, San Diego, USA). FASTQ files were aligned to the human reference genome (hg19/ GRCh37) using BWA v0.7.13. Variants (single nucleotide variants and indels) were genotyped from recalibrated BAM files using GATK 4.0 and annotated against multiple databases, including HGVS variant description, population frequency, disease or phenotype and variant functional prediction, using ANNOVAR. Variants were classified as pathogenic, likely pathogenic, variant of unknown significance, likely benign, or benign following the American College of Medical Genetics (ACMG) guidelines. Copy number variants were called by DNACopy R package, filtered classified as per the ACMG guidelines, and manually checked by using the Integrative Genomics Viewer. Target capture area was 50 M, detection range capture rate 99.9%, detection data volume 10G, average sequencing depth  $\geq 100\times$ , and the proportion of Q30 was not less than 90%. The results revealed no pathogenic or likely pathogenic single-nucleotide variation or insertion-deletion variant related to sexual development, but revealed a 1.4-Mb duplication in the Xq27.1q27.2 region (arr[hg19]Xq27

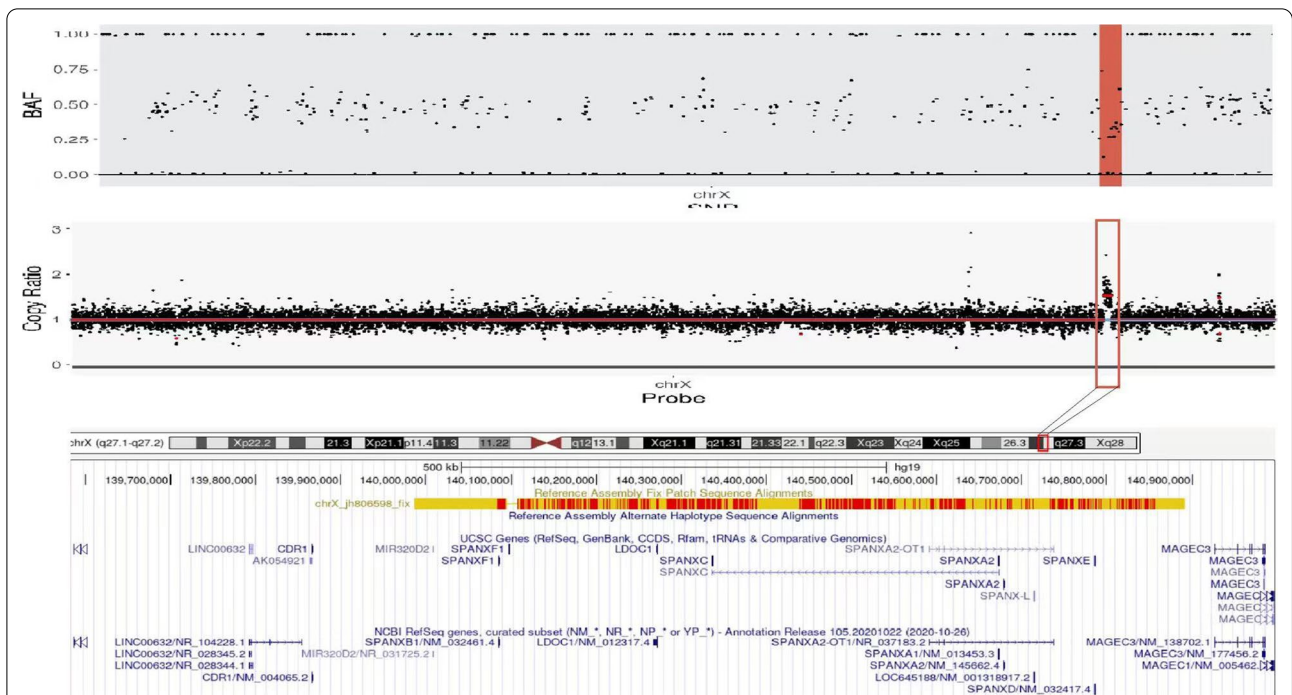
.1q27.2:139,585,794–140,996,652). The duplication contained *CDR1*, *SOX3*, and *SPANXA1* (Fig. 2). According to the ACMG, this duplication is of uncertain significance. The parents did not show *SOX3* duplication and had normal phenotypes.

After clinical consultation, the family decided to raise the child as a male. The patient underwent surgical procedures for the correction of hypospadias and gonad biopsy, followed by orchiopexy. Preoperative cystoscopy showed an orifice in the prostatic urethra. Upon probing with a camera, enlarged prostatic utricles were observed (Fig. 1b). The bilateral gonads were biopsied, followed by orchiopexy. Gonadal histology showed ovotesticular tissue on the right side and testicular tissue on the left side; both testicular tissues exhibited features of testicular dysgenesis. The ovarian tissue had primordial and primary follicles (Fig. 3a, b). Owing to this complicated condition, we performed penile straightening and planned to perform urethroplasty 6 months later. After degloving of the penis, the corpus cavernosum was well developed and the penis length and diameter were 4.5 and 1.5 cm, respectively.

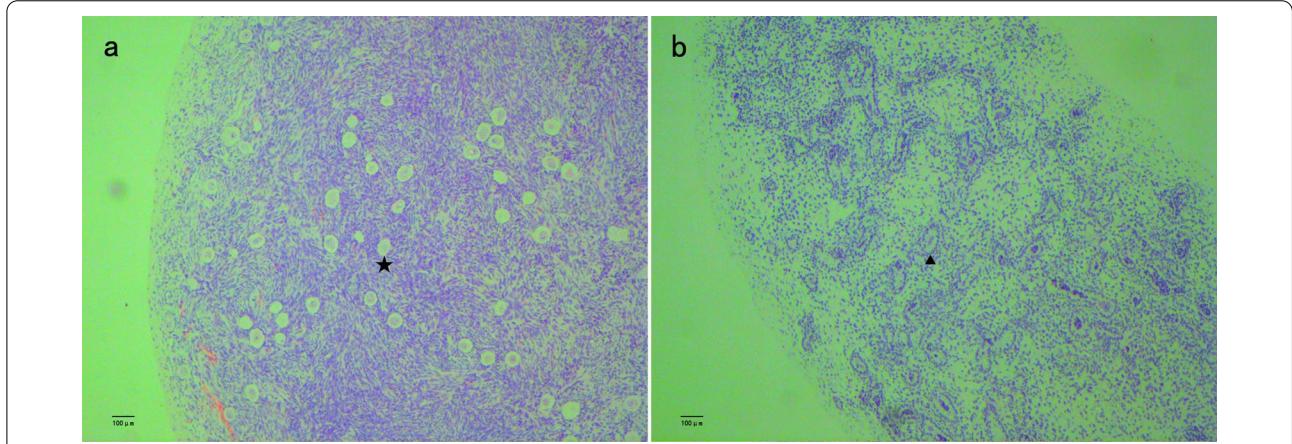
### Discussion and conclusion

*SOX3* is a single exon gene located in Xq27.1 and is required for normal brain, pituitary and craniofacial development in humans. Recent reports showed that mutation of *SOX3* can cause developmental delay or intellectual disturbance [7, 8]. Although *SOX3* is not required for normal sex development, it affects testis differentiation and oocyte development [9]. Mutation of *SOX3* induces *SRY*-negative 46,XX male sex reversal has been confirmed by previous reports [10]. However, the mechanism underlying *SOX3* mutation





**Fig. 2** Whole genome analysis showing 1.4-Mb duplication in the Xq27.1q27.2 region (arr[hg19]Xq27.1q27.2:139,585,794–140,996,652). The duplication contained *CDR1*, *SOX3*, and *SPANXA1*



**Fig. 3** Hematoxylin and eosin staining of bilateral gonadal sample. **a:** The right side showing ovotesticular tissue; the ovarian tissue had primordial and primary follicle(star). **b:** The left side showing testicular dysgenesis(arrow). These images were obtained using the following equipment: microscope DM300 and camera DFC450(leica, Germany). Scanner Hamamatsu, Nanozoomer S210-NDP. View 2 version 2.9.29, was used as acquisition software and the measurement resolution was 1200dpi

inducing *SRY*-negative 46 XX male sex reversal was not well understood. Through a literature review, we found 10 similar cases (Table 2) [2,3,10–15]. Seven of these cases contained *SOX3* duplication mutations, ranging from 550 kb to 6 Mb. The mechanism may involve over-expression of *SOX3* to upregulate *SOX9* expression and induce testis differentiation [1]. Our patient had a 1.4-Mb

duplication in the Xq27.1q27.2 region, which contained *SOX3*, supporting this prediction. In three of the cases, the condition was associated with rearrangements in the regulatory region of *SOX3*, which may weaken the inhibition of *SOX3* [15]. Our patient’s bilateral gonads were biopsied, and histological analysis showed that the testicular component

**Table 2** Cases of SOX3 related XX male reversal

	Suttou et. al Patients A	Suttou et. al Patients B	Suttou et. al Patients C	4: Moalen et. al	5: Haines et al	6: Vetro. et	7: Grisponetal. et	8: Tasic et	9: Zhuang J et	10: Qin,S et	Our patient
Disorders of sex development	XX male reversal	XX male reversal	XX male reversal	XX male reversal	OT-DSD	XX male reversal	OT-DSD	XX male reversal	OT-DSD	XX male reversal	OT-DSD
Age	30 years	Endocrine:19 years histology:26 years	1.5 years	1 years	1.5 months	8 years	2.5 years	11 years	7 years	31 years	5 years
Growth and development issues	Normal	Developmental delay:microcephaly	Developmental delay:microcephaly	Normal	normal	Mild intellectual disability	Normal	Normal	Normal	Normal	Normal
Hormone analysis	FSH:22.0mIU/ml LH:11.0IU/L Prolactin 17.9ug/l Free T:1.92 ng/dl	FSH:69.0 mIU/ml LH:35.0 IU/L Prolactin 3.0ug/l Free T:0.86 ng/dl	Unknow	FSH/ LH/T:normal	T:9.2 nmol/L Post-HCG:T:2.1 → 24.6 nmol/l DHT:2.0 → 7.5 nmol/l Androstenedione:0.6 → 1.1 nmol/l	Unknow	T(nmol/l) Basal: < 0.35 Post-HCG:1.05 AMH:2.16 LH: < 0.1 FSH:0.73	Post HCG: T:146 ng/ml A:T: < 1 T:DHT was 5.6	LH: < 0.2mIU/ml FSH:1.21 mIU/ml T: < 0.1 ng/ml Serum progesterone/ prolactin:normal	T:1.75 ng/ml Progesterone:0.11 ng/ml Prolactin:208.44uIU/ml LH:29.32mIU/ml FSH:37.88mIU/ml	LH:0.4 IU/L FSH:0.1 IU/L Prolactin:4.87 ng/ml T: < 2.5 ng/dl AMH:48.48 ng/ml Post-HCG:T:62.9 ng/dl
Genitals	Unknown	penile development with small testis:Shaft length, 10.2 cm; shaft diameter, 2.6 cm	Right testicles appear smaller than left;Hypoplastic scrotum:testes are retractile and can be brought down	Left cryptorchidism	Bifid scrotum; small phallus; distal hypopadias	Normal	Hypospadias and bilateral cryptorchidism	Moderate coronal hypospadias	Hypospadias and bilateral cryptorchidism	Normal	Scrotal hypospadias and bilateral cryptorchidism
Gonadal Histology	No details	Testicular dysgenesis	No details	No details	Right:ovotesticular	No details	The testicular tissue and ovarian tissue all exist. And testicular dysgenesis	No details	The ovotesticular tissue on the left side and the testicular tissue on the right side	No details	Right:ovotesticular tissue; Left: testicular tissue Testicular dysgenesis
Associated anomalies	-	-	-	Normal	Fallopian tube, hemiteruterus and hemivagina on the right gonads	-	-	Kidney hypodysplasia	-	-	Prostatic utricle
Genotypes	SRY negative Two microdeletions were observed the first of which spanned the entire sox3 gene	Single 343-kb microdeletion on the X-chromosome immediately upstream of SOX3	SRY negative 6 Mb duplication that encompasses sox3 and at least 18 additional distally located genes	SRY negative 0.494 Mb copy number gain in region Xq27.1 which contains the SOX3, RP1-177G6.2, CDRI	SRY negative carries 774 kb insertion translocation from chromosome 1 into a 82 kb distal to SOX3	A 5.6 Mb duplication of the long arm of a chromosome X, involving the SOX3 gene	SRY negative, duplicated region was around 0.5 Mb, and encompassed the SOX3 gene	A unique 550 kb duplication involving SOX3	SRY negative 2.2 Mb duplication that encompasses SOX3 gene	SRY negative heterozygous deletion in Xq27.1, located at 104 kb downstream of SOX3	SRY negative 1.4 Mb duplication that encompasses SOX3,CDRI,SPANXA1

was dysgenetic and that ovarian tissue was present. Therefore, the diagnosis was revised to OT-DSD. Haines et al. [12], Grisponetal et al. [10], and Zhuang et al. [14] also performed gonadal biopsy and obtained similar results. The development of testicular tissue and ovarian tissue may influence the sex assignment of patients with DSD. If the patients are raised as males, then the ovarian portion must be removed before pubertal age to avoid gynecomastia and cyclic hemorrhage. If the patients are raised as females, testicular tissue must be removed to avoid virilization during puberty [1]. Therefore, at any age, when the patient is diagnosed with an *SRY*-negative 46 XX karyotype, the gonads must be biopsied.

Our case involved duplication of *SOX3* in an *SRY*-negative 46,XX male associated with an enlarged prostatic utricle, which has not been reported previously. Tasicet et al. [3] reported patients with congenital anomalies of the kidneys. Haines et al. [12] reported patients with fallopian tubes, hemiuterus, and hemivagina on the right gonads, which were removed through surgery. Such patients must also be screened for abnormalities in other organs. Our patient also underwent an ultrasound, but the results were normal. We routinely perform cystoscopic pre-operation in patients with proximal hypospadias, which revealed an enlarged prostatic utricle in the current patient. Ultrasonography and retrograde urethrography can detect the prostatic utricle, but it is difficult to detect a small prostatic utricle using ultrasonography, and retrograde urethrography is not useful because of the slit-like utricular opening [16]. Thus, endoscopy is suitable for detecting the prostatic utricle. An enlarged prostatic utricle can cause recurrent urinary tract infection, epididymo-orchitis, fistulas after urethroplasty, and calculi or malignancy [17]. Early diagnosis is important for providing support for individualized plans and reducing postoperative complications [18]. Therefore, endoscopic examination should be performed in *SRY*-negative 46,XX males with hypospadias, as recommended previously [6].

Our patient has a 1.4-Mb duplication in the Xq27.1q27.2 region. The duplication contained *CDRI*, *SOX3*, and *SPANXA1*. Cerebellar degeneration-related antigen 1 (*CDRI*) is expressed in the nervous system, human epidermis, and cancer tissues, but its function is unclear [19]. *SPANXA1* is expressed in the tumors or testis [20], but has not been reported to be associated with sexual reversal. Therefore, the relationship between these two genes and sex determination requires further analysis.

*SOX3* duplication may causes sex reversal, and all 46,XX *SRY*-negative males should be screened for *SOX3* mutations. Gonadal biopsy is recommended to determine the presence of ovarian and testicular tissue development. Testicular dysgenesis and low exposure

to male hormones during fetal development can lead to enlarged prostatic utricles. Thus, endoscopic examination should be performed preoperatively to detect prostatic utricles in *SRY*-negative 46,XX males to guide the surgical plan and reduce postoperative complications.

#### Abbreviations

DSD: Disorders of sex development; OT-DSD: Ovotesticular male disorders of sex development; T: Testosterone.

#### Acknowledgements

The authors are grateful to the staff of Fuzhou Children's Hospital of Fujian Province, who were responsible for the management of patients included in the study. We are also grateful to the patients and their families who participated in this study.

#### Author contributions

JW: Project design, data acquisition and analysis, and manuscript writing. CL: Data acquisition and analysis. MZ: Data acquisition and analysis, SL: Data acquisition and analysis, JF: Data Acquisition and Analysis, and PL: Data acquisition and analysis. All authors contributed to the editorial changes in the manuscript. All authors read and approved the final manuscript.

#### Funding

The study was supported by the Key Clinical Specialty Discipline Construction Program of Fuzhou, Fujian, P.R.C(2018-56). The funding bodies played no role in the design of the study and collection, analysis, and interpretation of data and in writing the manuscript.

#### Availability of data and materials

The datasets (whole-genome analysis, polymerase chain reaction results, hormonal laboratory tests) used and/or analyzed during the current study are available from the corresponding author on reasonable request. The sequencing data has been deposited in NCBI Bioproject database, The data is accessible via the accession number: PRJNA864577 (<https://www.ncbi.nlm.nih.gov/sra/PRJNA864577>). The following databases are used in this study: Human Reference Genome (hg19/ GRCh37) (<https://www.ncbi.nlm.nih.gov/projects/genome/guide/human/index.shtml>) GATK (<https://www.broadinstitute.org/gatk/>) ANNOVAR(<https://annovar.openbioinformatics.org/en/latest/>).

#### Declarations

##### Ethics approval and consent to participate

The study protocol was reviewed and approved by the Ethics Committee of the Fuzhou Children's Hospital of Fujian Province (Approval Number: FCHFJ-2022-11). All analyses were conducted in accordance with the tenets of the Declaration of Helsinki. The patient and his parents provided written informed consent to participate in this study.

##### Consent for publication

All subjects who participated in this study signed written informed consent for publishing their own and their children's genetic data and relevant information.

##### Competing interests

The authors declare that they have no competing interests.

Received: 16 December 2021 Accepted: 1 September 2022

Published online: 05 September 2022

#### References

1. Grispon RP, Rey RA. Disorders of sex development with testicular differentiation in *SRY*-negative 46, XX individuals: clinical and genetic aspects. *Sex Dev.* 2016;10(1):1–11.

2. Sutton E, Hughes J, White S, Sekido R, Tan J, Arboleda V, et al. Identification of *SOX3* as an XX male sex reversal gene in mice and humans. *J Clin Invest*. 2011;121(1):328–41.
3. Tasic V, Mitrotti A, Riepe FG, Kulle AE, Laban N, Polenakovic M, et al. Duplication of the *SOX3* gene in an Sry-negative 46, XX male with associated congenital anomalies of kidneys and the urinary tract: case report and review of the literature. *Balkan J Med Genet*. 2019;22(1):81–8.
4. Shapiro E, Huang H, McFADDEN DE, Masch RJ, Ng E, Lepor H, Wu XR. The prostatic utricle is not a Müllerian duct remnant: immunohistochemical evidence for a distinct urogenital sinus origin. *J Urol*. 2004;172:1753–6.
5. Furuya S, Hisasue S, Kato H, Shimamura S. Novel insight for midline cyst formation in prostate: the involvement of decreased prenatal testosterone suggested by second-to-fourth digit ratio study. *Int J Urol*. 2015;22(11):1063–7.
6. Hester AG, Kogan SJ. The prostatic utricle: an under-recognized condition resulting in significant morbidity in boys with both hypospadias and normal external genitalia. *J Pediatr Urol*. 2017;13(5):492.e1–5.
7. Woods KS, Cundall M, Turton J, Rizotti K, Mehta A, Palmer R, et al. Over- and underdosage of *SOX3* is associated with infundibular hypoplasia and hypopituitarism. *Am J Hum Genet*. 2005;76(5):833–49.
8. Du C, Wang F, Li Z, Zhang M, Yu X, Liang Y, et al. Xq26.3-q27.1 duplication including *SOX3* gene in a Chinese boy with hypopituitarism: case report and two years treatment follow up. *BMC Med Genom*. 2022;15(1):19.
9. Weiss J, Meeks JJ, Hurley L, Raverot G, Frassetto A, Jameson JL, et al. *Sox3* is required for gonadal function, but not sex determination, in males and females. *Mol Cell Biol*. 2003;23(22):8084–91.
10. Grinspon RP, Nevado J, Alvarez MDLÁM, Del Rey G, Castera R, Venara M, et al. 46, XX ovotesticular DSD associated with a *SOX3* gene duplication in a SRY-negative boy. *Clin Endocrinol*. 2016;85(4):673–5.
11. Moalem S, Babul-Hirji R, Stavropoulos DJ, et al. XX male sex reversal with genital abnormalities associated with a de novo *SOX3* gene duplication. *Am J Med Genet A*. 2012;158(7):1759–64.
12. Haines B, Hughes J, Corbett M, Shaw M, Innes J, Patel L, et al. Interchromosomal insertional translocation at Xq26.3 alters *SOX3* expression in an individual with XX male sex reversal. *J Clin Endocrinol Metab*. 2015;100(5):E815–20.
13. Vetro A, Dehghani MR, Kraoua L, et al. Testis development in the absence of SRY: chromosomal rearrangements at *SOX9* and *SOX3*. *Eur J Hum Genet*. 2015;23(8):1025–32.
14. Zhuang J, Chen C, Li J, Jiang Y, Wang J, Wang Y, et al. The 46, XX ovotesticular disorder of sex development With Xq27.1q27.2 duplication involving the *SOX3* gene: a rare case report and literature review. *Front Pediatr*. 2021;9:682846.
15. Qin S, Wang X, Wang J. Identification of an SRY-negative 46, XX infertility male with a heterozygous deletion downstream of *SOX3* gene. *Mol Cytogenet*. 2022;15(1):2.
16. Kojima Y, Hayashi Y, Maruyama T, Sasaki S, Kohri K. Comparison between ultrasonography and retrograde urethrography for detection of prostatic utricle associated with hypospadias. *Urology*. 2001;57(6):1151–5.
17. Şalvarcı A, İstanbulluoğlu O. Monosymptomatic persistent hematospermia due to rarely encountered prostatic utricle stones. *Urol Int*. 2015;95(3):370–2.
18. Gupta A, Khosa J, Barker A, Samnakay N. Clinical spectrum and management options for prostatic utricle in children. *J Pediatr Surg*. 2022. <https://doi.org/10.1016/j.jpedsurg.2022.01.013>.
19. Wang LL, Gschwandtner M, Eckhart L, Tschachler E. Cerebellar degeneration-related antigen 1 is ubiquitously expressed in human epidermis and dermis. *Curr Med Sci*. 2020;40(3):570–3.
20. Zendman AJ, Zschocke J, van Kraats AA, de Wit NJW, Kurpisz M, et al. The human *SPANX* multigene family: genomic organization, alignment and expression in male germ cells and tumor cell lines. *Gene*. 2003;309(2):125–33.

## Publisher's Note

Springer Nature remains neutral with regard to jurisdictional claims in published maps and institutional affiliations.

Ready to submit your research? Choose BMC and benefit from:

- fast, convenient online submission
- thorough peer review by experienced researchers in your field
- rapid publication on acceptance
- support for research data, including large and complex data types
- gold Open Access which fosters wider collaboration and increased citations
- maximum visibility for your research: over 100M website views per year

At BMC, research is always in progress.

Learn more [biomedcentral.com/submissions](https://biomedcentral.com/submissions)

