



CASE REPORT

Acquired stenosis of external auditory canal secondary to paraneoplastic manifestation of renal cancer[☆]



Estenose adquirida do conduto auditivo externo secundária a manifestação paraneoplásica de neoplasia renal

Loraine Entringer Falqueto^a, Marcos Lyra Kaddoum^b, Marcio Maia Lamy de Miranda^a, Henrique Faria Ramos^{a,*}

^a Universidade Federal do Espírito Santo (UFES), Vitória, ES, Brazil

^b Universidade Federal do Espírito Santo (UFES), Hospital Cassiano Antônio de Moraes, Departamento de Urologia, Vitória, ES, Brazil

Received 1 August 2015; accepted 22 October 2015

Available online 5 February 2016

Introduction

Acquired stenosis of the external auditory canal (EAC) is uncommon,¹ with several related causes. However, no reports exist of acquired stenosis of EAC secondary to paraneoplastic syndrome. This is the first report of auricular pyoderma gangrenosum manifesting as paraneoplastic syndrome of renal clear cell carcinoma, evolving to stenosis of the EAC.

[☆] Please cite this article as: Falqueto LE, Kaddoum ML, Miranda MM, Ramos HF. Acquired stenosis of external auditory canal secondary to paraneoplastic manifestation of renal cancer. Braz J Otorhinolaryngol. 2018;84:249–51.

* Corresponding author.

E-mail: henriquefariamos@terra.com.br (H.F. Ramos).

Peer Review under the responsibility of Associação Brasileira de Otorrinolaringologia e Cirurgia Cérvico-Facial.

Case report

Male, 56, presenting with an ulceration on the right auricular concha for 45 days, with poor response to topical and systemic antibiotics, associated with otorrhea, hearing loss, otalgia and fever. Otoscopy revealed an ulcerated lesion in the auricle and edema of the EAC, preventing appropriate visualization of the tympanic membrane.

Computed tomography (CT) of the temporal bones (Fig. 1A) showed obliteration of the EAC without regional bone involvement. Due to the possibility of malignant external otitis, the patient was treated with Piperacillin and Tazobactam for 21 days. The lesion improved after two weeks, evolving to scar stenosis of the EAC. The patient was discharged after 21 days with antibiotic therapy (Ciprofloxacin 750 mg, 21 days) and office follow-up for possible surgery for stenosis correction.

After 3 months, the patient presented with severe bilateral otalgia associated with otorrhea, and necrosis of the auricular concha, tragus and intertragic incisure

<https://doi.org/10.1016/j.bjorl.2015.10.018>

1808-8694/© 2016 Associação Brasileira de Otorrinolaringologia e Cirurgia Cérvico-Facial. Published by Elsevier Editora Ltda. This is an open access article under the CC BY-NC-ND license (<http://creativecommons.org/licenses/by-nc-nd/4.0/>).

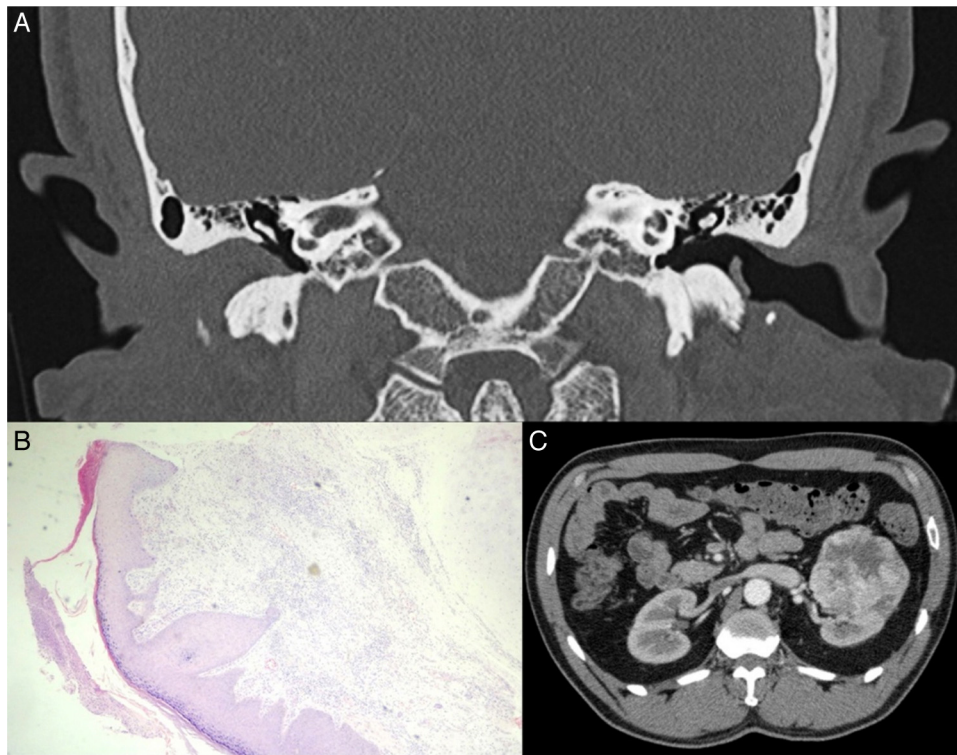


Figure 1 (A) Temporal bone tomography (CT) showing obliteration of right EAC. (B) Photomicrograph of the external ear biopsy suggestive of pyoderma gangrenosum (Hematoxylin and eosin staining; 10 \times). (C) Contrast abdominal CT showing the tumor in the left kidney.

bilaterally. Histopathologic examination revealed nonspecific chronic inflammation affecting the dermis and the perichondrium with focal ulceration of the skin, suggestive of pyoderma gangrenosum (Fig. 1B). Multisensitive *Acinetobacter baumannii* was isolated in the culture. Inflammatory markers, C3, C4, p-ANCA, c-ANCA and ANA were normal.

An isodense mass was observed in an abdominal CT, located in the middle third of the left kidney, heterogeneous, with peripheral contrast uptake of 6 cm \times 6.4 cm \times 6 cm (Fig. 1C). The patient subsequently underwent a left nephrectomy with histological diagnosis of a clear cell variant of renal carcinoma.

Discussion

Stenosis of the EAC is rare, with an incidence of 0.6 cases per 100,000 inhabitants.² The most common cause is chronic external otitis. However, recurrent or persistent suppurative otitis media, foreign body, trauma, radiation, tumors are also reported.¹

Chronic ulcerated lesions affecting the EAC and auricles can be secondary to several diseases, including malignant external otitis, skin infection (fungal, mycobacterial or viral), insect bites, lymphoma, cutaneous primary tumor, metastasis, perichondritis, vasculitis, Wegner's granulomatosis, artifact dermatitis, neurodermatitis and pyoderma gangrenosum.³

In 50% of cases, pyoderma gangrenosum (PG) is associated with neoplasm, illicit drugs, systemic inflammatory diseases (ulcerative colitis, Behcet's disease, Crohn's disease, Wegner's granulomatosis and rheumatoid arthritis) and myeloproliferative diseases.⁴ The pathogenesis of PG remains unclear, but a dysfunction of neutrophil chemotaxis might be involved.^{3,5}

PG is a diagnosis of exclusion as the histopathologic findings are not specific. A biopsy including the border of the ulcer and the adjacent skin is necessary to exclude vasculitis, malignancy and infection. Histologic features of the untreated ulcer usually include dense neutrophilic dermal infiltrates and necrosis of the overlying epidermis.⁶ Investigation of the underlying cause is performed with laboratory exams, such as serum protein electrophoresis, anti-nuclear antibodies and anti-neutrophil cytoplasmic antibodies, and colonoscopy.³

The clear cell renal carcinoma is the third most common type of neoplasm in the genitourinary system.⁷ Paraneoplastic syndrome is the initial manifestation in about 40% of cases.⁸ This is the first described case of pyoderma gangrenosum as paraneoplastic syndrome related to this type of neoplasm.⁹

This patient presented with no other signs suggesting systemic involvement. In view of a negative serology and inflammatory markers and disease recurrence after empirical treatment of malignant external otitis, imaging tests were performed to exclude relapsing polychondritis and neoplasms. With total gross removal of the tumor, there was no recurrence.

Final comments

Acquired EAC stenosis is uncommon. It is important to diagnose the underlying related disease. Among the disease possibilities, the paraneoplastic disease should be considered.

Conflicts of interest

The authors declare no conflicts of interest.

References

1. Luong A, Roland PS. Acquired external auditory canal stenosis: assessment and management. *Curr Opin Otolaryngol Head Neck Surg.* 2005;13:273–6.
2. Becker BC, Tos M. Postinflammatory acquired atresia of the external auditory canal: treatment and results of surgery over 27 years. *Laryngoscope.* 1998;108:903–7.
3. Gameiro A, Pereira N, Cardoso JC, Gonçalo M. Pyoderma gangrenosum: challenges and solutions. *Clin Cosmet Investig Dermatol.* 2015;8:285–93.
4. Chin RY, Nguyen TB. Synchronous malignant otitis external and squamous cell carcinoma of the external auditory canal. *Case Rep Otolaryngol.* 2013;2013:837169.
5. Braswell SF, Kostopoulos TC, Ortega-Loayza AG. Pathophysiology of pyoderma gangrenosum (PG): an updated review. *J Am Acad Dermatol.* 2015;73:691–8.
6. Ruocco E, Sangiuliano S, Gravina AG, Miranda A, Nicoletti G. Pyoderma gangrenosum: an updated review. *J Eur Acad Dermatol Venereol.* 2009;23:1008–17.
7. Dos Santos Sousa MC, Lima Lemos EF, Oliveira de Morais O, Silva Leite Coutinho AS, Martins Gomes C. Pyoderma gangrenosum leading to bilateral involvement of ears. *J Clin Aesthet Dermatol.* 2014;7:41–3.
8. Kim HL, Belldegrün AS, Freitas DG, Bui MH, Han KR, Dorey FJ, et al. Paraneoplastic signs and symptoms of renal cell carcinoma: implications for prognosis. *J Urol.* 2003;170:1742–6.
9. Palapattu GS, Kristo B, Rajfer J. Paraneoplastic syndromes in urologic malignancy: the many faces of renal cell carcinoma. *Rev Urol.* 2002;4:163–70.