

Gunshot Wounds: Ballistics, Pathology, and Treatment Recommendations, with a Focus on Retained Bullets

Gracie R Baum ¹, Jaxon T Baum ², Dan Hayward², Brendan J MacKay¹

¹Department of Orthopedic Hand Surgery, Texas Tech University Health Sciences Center, Lubbock, TX, USA; ²School of Medicine, Texas Tech University Health Sciences Center, Lubbock, TX, USA

Correspondence: Brendan J MacKay, Department of Orthopedic Hand Surgery, Texas Tech University Health Sciences Center, 808 Joliet Ave Suite 310, Lubbock, TX, 79415, USA, Tel +1 806 743 4600, Email brendan.j.mackay@ttuhsc.edu

Abstract: As the epidemic of gunshot injuries and firearm fatalities continues to proliferate in the United States, knowledge regarding gunshot wound (GSW) injury and management is increasingly relevant to health-care providers. Unfortunately, existing guidelines are largely outdated, written in a time that high-velocity weapons and deforming bullets were chiefly restricted to military use. Advances in firearm technology and increased accessibility of military grade firearms to civilians has exacerbated the nature of domestic GSW injury and complicated clinical decision-making, as these weapons are associated with increased tissue damage and often result in retained bullets. Currently, there is a lack of literature addressing recent advances in the field of projectile-related trauma, specifically injuries with retained bullets. This review aims to aggregate the available yet dispersed findings regarding ballistics, GSW etiology, and treatment, particularly for cases involving retained projectiles.

Keywords: ballistics, gunshot injuries, retained bullets, orthopedic surgery, trauma

Introduction

The civilian use of firearms is a common cause of traumatic injury in the United States. It is estimated that an average of 120,232 firearm injuries occurred yearly from 2009 to 2017.¹ Knowledge regarding gunshot wound (GSW) injury and management was chiefly derived from experience garnered during the major wars of the 20th century. Existing guidelines were written when high velocity firearms and deforming rounds, which create more extensive tissue damage, were predominantly restricted to the military. However, advances in weapons technology and the increased accessibility of military grade firearms to civilians has changed the nature of domestic GSW injury, thereby complicating clinical decision-making.^{2,3}

Despite the prevalence of GSWs, especially in high volume trauma centers, treatment decisions are still largely driven by anecdotal beliefs. A common myth is that the heat produced by gun powder ignition during firearm discharge is sufficient to sterilize the bullet.⁴ Wolf et al disproved this notion by coating bullets with a small amount of *S. aureus*, firing into sterile ballistics blocks, and culturing the same *S. aureus* from the bullet tracts.⁵ A GSW creates an open path of entry in which projectiles and their components can transport bacteria and debris from the skin flora, clothing, environment, or other intermediate targets directly into a wound.^{4,6,7} Despite the evolution of understanding with regard to possible infection, historical misconceptions have likely played a role in the lack of lucid consensus on antibiotic use in GSWs.^{8–10}

Additionally, the literature lacks large data pools and comprehensive guidelines regarding the management of retained bullets. According to a 2022 survey, only 14.5% of participating surgeons reported having institution policies for bullet removal.¹¹ Many clinicians believe that bullet removal and thorough debridement is indicated in all cases. Yet, specific tissue involvement and injury presentation vary widely and dictate the method and degree of intervention. Often, bullet

removal and formal debridement are unnecessary and can lead to additional tissue damage or complications such as infection, iatrogenic neurovascular injury, deep vein thrombosis, and bleeding. Contrary to common belief, risk of lead toxicity is uncommon, unless bullets have come to rest within synovial fluid or an intervertebral disk.¹²

Currently, there is no comprehensive review that provides adequate information covering projectile ballistics, pathology, and management. Further, there is a dearth of literature addressing recent advances in the field of projectile-related trauma, specifically injuries resulting in retained bullets. We aim to aggregate the available yet dispersed findings regarding GSW etiology and treatment, particularly for retained bullet cases. We will also discuss the importance of interventions (eg, prophylactic antibiotic use and debridement) that minimize complication risk, while also reducing care induced harm.

Materials and Methods

The authors performed a comprehensive review of the PubMed, MEDLINE, and EMBASE databases using an extensive combination of keywords outlined in [Table 1](#). The literature search focused on clinical evidence-based data regarding GSW and retained bullet ballistics, complications, and treatment recommendations to present the current understanding of GSW and retained bullet management.

Table 1 PubMed Search Terms Used by Section

Section	Search Terms
Ballistics and projectile pathology	Wound ballistics, firearm ballistics, gunshot wound ballistics, ballistic injuries, firearm injuries, low velocity gunshot wounds, low velocity gunshot injuries, high velocity gunshot wounds, high velocity gunshot injuries, gunshot fractures, gunshot fracture treatment
Initial evaluation, non-operative management, and surgical treatment	Gunshot wound imaging, gunshot injury imaging, gunshot wound antibiotics, gunshot injury antibiotics, gunshot wound treatment, gunshot injury treatment, gunshot wound management, gunshot injury management, gunshot wound infection, gunshot injury infection, gunshot wound debridement, gunshot injury debridement, gunshot wound surgery, gunshot injury surgery
Retained bullet removal	Retained bullets, retained projectiles, retained bullets orthopedics, retained projectiles orthopedics, retained bullet management, retained projectile management, bullet removal, retained bullet removal, projectile removal, retained projectile removal, bullet removal orthopedics, projectile removal orthopedics, intraarticular bullet removal, bullet debridement, arthroscopic bullet removal, arthroscopic gunshot treatment, retained bullet hip, retained bullet knee, retained bullet ankle, retained bullet extremity, retained bullet limb, retained bullet hand, retained bullet spine, retained bullet arm, upper extremity gunshot wound, upper extremity gunshot injury
Retained bullet complications	Lead poisoning retained bullets, lead poisoning gunshot wound, lead poisoning gunshot injury, lead toxicity retained bullets, lead toxicity gunshot wound, lead toxicity gunshot injury, lead arthropathy, migrating bullets, bullet migration, projectile migration, bullet spontaneous migration

Ballistics

The characteristic path of a bullet originating from a firearm, exhibiting projectile flight, and striking an object, can be described by applying the principles internal, external, and terminal ballistics. Firearms can be categorized in many ways including shape, action, and ammunition type. While there are countless factors that can be applied and dissected to fully understand the behavior of projectiles originating from firearms, we will only present what we have found to be most pertinent to the understanding of GSW etiology and treatment.

Categorization

Firearms responsible for GSWs are commonly stratified by the velocity of the expelled projectile. High-velocity projectile injuries are typically from firearms with a muzzle velocity greater than 2000 ft/s (commonly rifle calibers) and are associated with more substantial tissue damage.¹³ Low-velocity projectile injuries are caused by firearms with muzzle velocities less than 2,000 ft/s (commonly pistol calibers).¹³ Shotguns are a common example of a low-velocity

firearm (1,000–1,500 ft/s), but they provide a unique ballistics pattern that differs from the behavior of a single projectile.^{14–17}

While categorizing firearms by projectile velocity alone is convenient, this neglects much of the nuanced outcomes of wound ballistics. For example, when a low-velocity shotgun is fired at close range, a high-velocity type wound results, due to increased energy transfer.¹⁸ Alternatively, a physician may unnecessarily excise viable tissue simply because the wound came from a high velocity round.¹⁹

Instead of evaluating wounds as high or low velocity calibers, consideration of the amount of kinetic energy ($KE = 1/2 MV^2$) possessed by a projectile at the time of impact is much more important. The efficiency of energy transfer is dependent on multiple factors including the trajectory stability, distance traveled, entrance profile of the projectile, and the amount of yaw (the angle of deviation from the projectile's long-axis).^{17,18} The caliber and material of the bullet, the tissue type impacted, mechanism of tissue disruption, and trajectory within the body, also contribute to the projectile's energy transfer.^{17,18} Therefore, in the setting of wound ballistics, designating the implicated bullet in a GSW as “high-energy” and “low-energy” is a more useful categorization method for describing the extent and nature of multi-tissue damage than velocity alone.

Internal Ballistics

Internal ballistics describe the path a projectile takes within a gun, from the breech to the muzzle, which can be seen in [Figure 1A](#). Internal ballistics are influenced by factors such as the type of gun powder, primer, and other characteristics of the ammunition, as well as the chamber, rifling, choke (constriction), barrel length, and other engineered properties of firearms. Technical advancements regarding internal ballistics have allowed for the increased projectile velocity, energy, and accuracy.

Bullets are available in a wide variety and differ in material, size, shape, and other design aspects that affect flight behavior, yaw, KE, penetration capability, and wounding potential ([Figure 2](#)). Bullets are primarily composed of lead due to its high density, mass, and thus KE, although when shot at over 2,000 ft/s, high barrel temperature can cause them to deform.^{20,21} To mitigate temperature induced deformation, bullets are commonly produced with lead alloys or are encased with a copper or copper alloy jacket.^{20,21}

External Ballistics

The course taken by the bullet between exiting the firearm and contacting a target is explained using external ballistics, which can be seen in [Figure 1B](#). The bullet type, casing, length, and caliber (diameter) are central components that

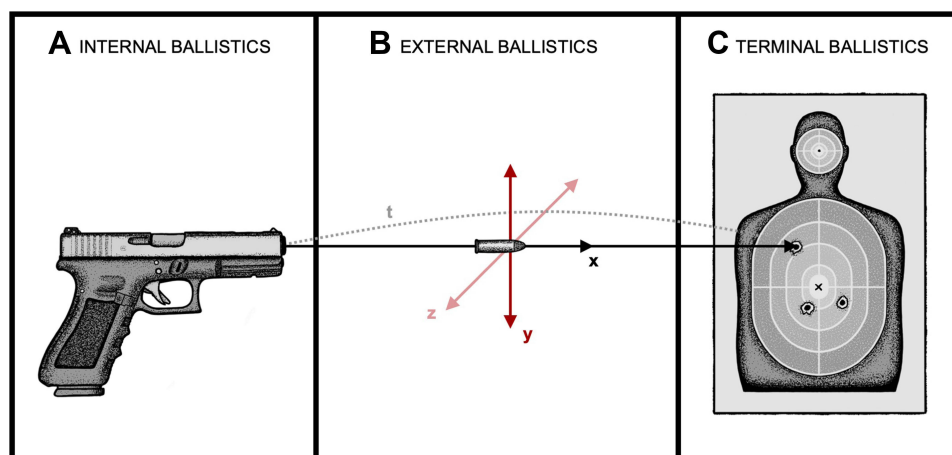


Figure 1 Phases of Ballistics.

Notes: (A) Internal Ballistics occur within the firearm. (B) External Ballistics describe the period that occurs after the projectile departs from the firearm and before it reaches the target. The projectile trajectory (t) can vary along its flight path direction (x) if the nose of the bullet deviates on its vertical axis, which is known as pitch (y), or the horizontal axis, known as yaw (z). (C) Terminal or Wound Ballistics describe the effect of the projectile once it has struck a target or victim.

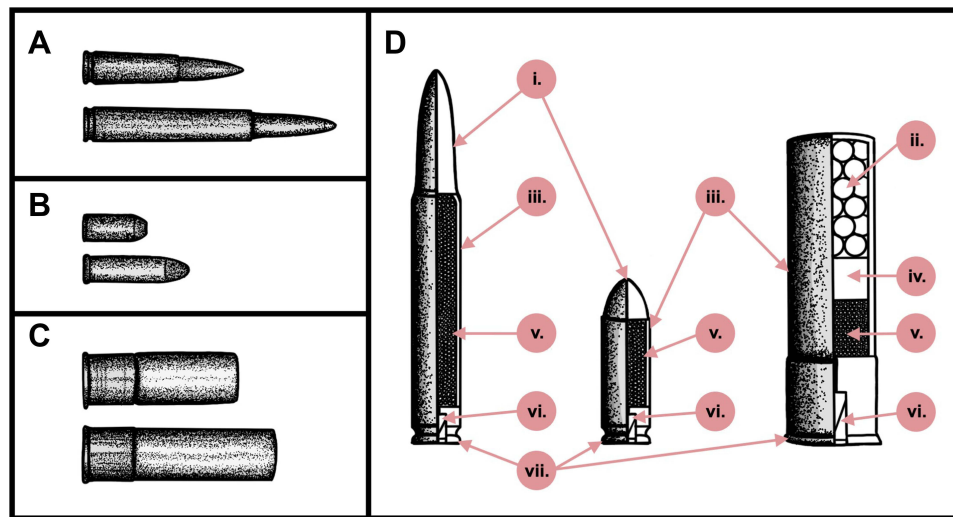


Figure 2 Ammunition Anatomy.

Notes: Simplified sketches showcasing the general appearance of different kinds of ammunition, cartridges, rounds, or shells. **(A)** High velocity/energy cartridges, typically fired from rifles, are designed for long range use for hunting or armed conflict. **(B)** Low velocity/energy rounds, typically used in handguns. The sketches depict one round with a hollow point and one with a round point. **(C)** Shotgun ammunition, typically used in muzzle loading rifles, designed for short-range targets. **(D)** Ammunition generally consists of the following: (i) Bullet (projectile); (iii) Casing; (v) Propellant; (vi) Primer; (vii) Rim. Uniquely, shotgun shells contain (ii) Pellets (projectiles) and (iv) Wadding.

influence external ballistics. Additionally, the rotation caused by the rifling of the barrel, which improves flight stability and accuracy, and external forces such as gravity and drag act on the projectile determining its flight path.

The distance between a firearm and its target, as well as its initial projectile velocity, both play a significant role in wounding potential. High-velocity weapons retain a significant amount of KE at a short distance, while low-velocity projectiles quickly lose substantial energy. However, at a close range, both high- and low-velocity projectiles may retain a high percentage of their KE.¹⁵

The drag force can be altered by the shape, size, and behavior exhibited by a bullet throughout its projectile trajectory. An ideal, aerodynamic bullet experiences minimal yaw, tumbling or roll, and has a low drag coefficient, which leads to a flattened projectile trajectory and maximizes the amount of kinetic energy retained when contacting its target.^{22,23} Increased yaw and the presence of tumbling (the complete loss of gyroscopic stability) both cause the drag force on the bullet to increase and its KE to decrease.²⁴

Terminal (Wound) Ballistics

Terminal ballistics, represented in [Figure 1C](#), describe the effect projectiles induce on their target upon contact, which, in the case of this paper, is living tissue.¹⁵ This specific subordinate of terminal ballistics is termed wound ballistics and characterizes how diverse projectiles create wounds and how living tissues react to projectile injury, which is depicted in [Figure 3](#).¹⁸ Bullets can be broadly classified by whether they are deforming (expanding) or non-deforming (non-expanding). Non-deforming and partially deforming bullets remain intact and typically result in greater penetration yet result in less collateral tissue damage than deforming projectile GSWs ([Figure 3A](#) and [C](#)).^{20,21} Due to their greater penetration, non-deforming rounds, such as full metal jackets, round noses, wadcutters, and semi-wadcutters, are more likely to create exit wounds.²⁵ In contrast, deforming and fragmenting bullets immediately expand on impact, increasing the total contact area between bullet and tissue, which results in a larger wound cavity ([Figure 3B](#) and [D](#)). This expansion causes a braking effect, transferring all of the bullets KE to the target, maximizing tissue damage, and rarely exiting the body.^{20,25,26} Therefore, deforming rounds, such as hollow points, soft points, frangible bullets, and slugs cause extensive tissue damage and disruption.^{14,18,25,27–31} These properties led to the Hague Convention of 1899 to prohibit the use of expanding, deformable bullets in wartime. Despite this, many law enforcement agencies have adopted hollow point handgun bullets due to their “stopping power” which prevents unintentional collateral damage.^{14,18} Shotgun shells

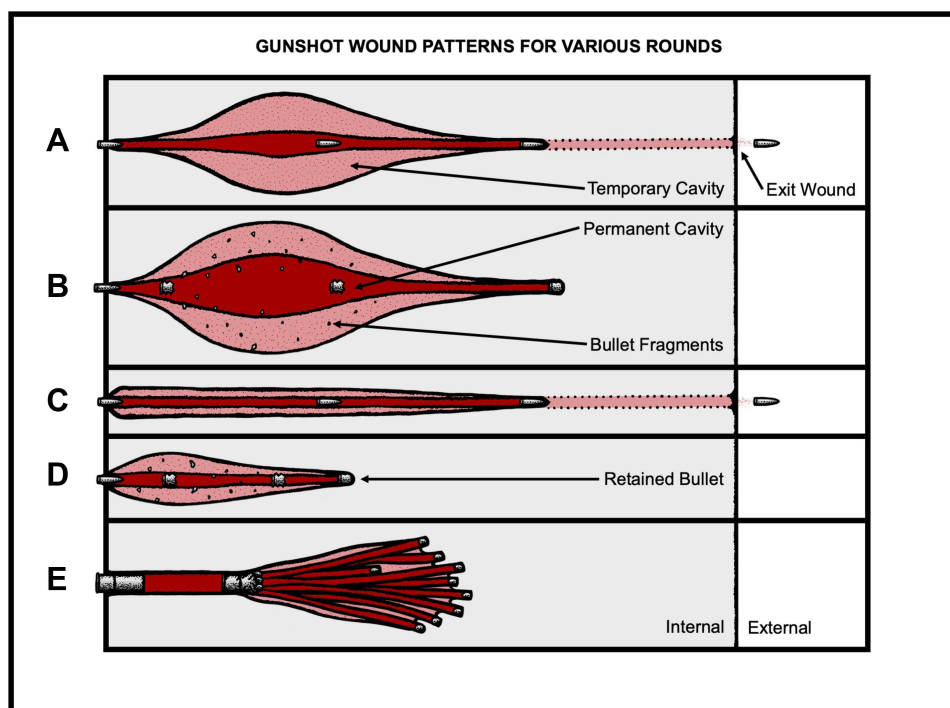


Figure 3 Gunshot Wound Patterns for Various Rounds.

Notes: Simplified sketches showcasing the typical internal wound patterns caused by classes of commonly used projectiles. The permanent cavity and temporary cavity of each wound are shown in red and pink, respectively. Non-deforming rounds (**A** and **C**) may be retained or exit the body. While deforming rounds (**B**, **D** and **E**) can exit the body, they are more likely to be retained. (**A**) High-energy wound from a non-deforming round. (**B**) High-energy wound from a deforming round. (**C**) Low-energy wound from a non-deforming round. (**D**) Low-energy wound from a deforming round. (**E**) Low-energy wound from a shotgun shell (deforming round).

behave uniquely and demonstrate complex ballistic patterns, due to the fact that they are made up of varying numbers of small metal pellets which disperse when fired (Figure 3E).^{16,17,29,32}

Penetrating GSWs

The offending bullet of a GSW will either become retained within the body or exit just after entering. If the projectile exits, only a fraction of the KE is transferred to the body, decreasing the potential energy that can be converted to tissue damage. Exit wounds tend to occur when projectiles are non-deforming, excessively powerful, or fired at a short range, or if the bullet encounters tissue that is minimal in thickness or density.^{18,33} In general, exit wounds tend to be larger and more irregularly shaped than corresponding entrance wounds, especially if the projectile is traveling at a high velocity, experiences expansive deformation, or tumbles and travels off-axis from its lengthwise orientation.^{18,33} Determining exit sites may be further complicated if bullets become fragmented or ricochet off dense material, such as bone.^{13,15,34} Therefore, it is advised to treat the wounds as they present and avoid labeling sites, as they are often misclassified.^{13,15}

Retained Bullet GSWs

In contrast to exiting projectiles, retained bullets transfer the total remaining KE present at impact to the tissue encountered. Retained bullets can come to rest intact, if they remain in soft tissue, or they could strike bone or a metal implant resulting in fragmentation.^{25,35} Despite yaw, most intact bullets typically come to rest in tissue at 0° (nose-forward) or 180° (base-forward), causing tissue destruction no larger than the bullet's caliber.^{36,37} If bullet yaw is equal to 90° on contact, the resultant tissue damage can be greater than three times as extensive.³⁶ Internal bodily impact may result in simultaneous bullet disintegration and bone fragmentation, forming numerous secondary missiles causing additive damage, increasing the cavitation volume and severity of the wound.^{20,24,36} Fragments of less than a gram can penetrate a depth of up to 10–15 cm within soft tissue. As an additional complication, fragmentation can result in a mix of a partially retained bullet with accompanying exit wounds.^{13,38}

All the above factors described by ballistics interact to cause variable injury patterns that cannot simply be predicted by projectile velocity. Thus, Cooper and Ryan recommend that treatment should be indicated by wound presentation, rather than the weapon implicated.³⁹

Projectile Pathology

While the KE transferred at impact determines penetrating capacity, the wounding potential depends on the structures impacted by the projectile.¹⁸ Gunshot injuries commonly result in diffuse soft-tissue damage, volumetric muscle loss, hemorrhage, fracture, and severe pain.⁴⁰ Tissue structure varies by specific gravity or density and elasticity, which contribute to wounding potential causing inconsistent energy dissipation and tissue disruption along a bullet's track.^{14,41}

As a bullet enters the skin, tissue accelerates radially and is displaced centrifugally.⁴² The size of the entry wound is transiently larger than the caliber of the bullet, but typically the defect reversibly contracts to a diameter smaller than the cross-sectional area of the bullet due to the highly elastic properties of skin.⁴² Additionally, entry wound defects can differ depending on the shape of the implicated bullet.⁴² The effects of penetration are further complicated by the presence of intermediary targets such as clothing, glass, or wood, which can alter the shape, fragmentation, or trajectory of the projectile.^{43,44}

Internally, bullets cause crushing or laceration injury leaving “permanent” tissue cavitation along their course.^{19,24,45} The magnitude of this permanent cavity is determined by the bullet caliber and its deformation or fragmentation within the body.^{24,46} A small and intact bullet traveling at a lower velocity will create a permanent cavity similar to its caliber or entry orientation.^{37,47} Additionally, a “temporary” cavity is created surrounding the primary cavity as the bullet stretches and strains tissues past their elastic limit.^{18,19,24,45,48} This continued, radial acceleration and the extent of damage are primarily determined by the bullet's velocity and the tensile properties of implicated tissues.^{24,46} High-energy projectiles are associated with temporary cavities reaching up to 10–30 times the size of the permanent cavity, while lower-energy projectiles create temporary cavities that are relatively the same size as the permanent cavity.^{24,46} Additionally, the amount of yaw demonstrates a positive relationship to temporary cavity size.^{24,46} In all, GSWs from high-energy projectiles tend to result in greater and more diffuse damage, whereas low-energy projectile damage is typically restricted to the path of bullets and secondary missile fragments.^{24,46}

Fractures

Bone is anisotropic and viscoelastic, meaning it shares the properties of both a solid and liquid to some extent. While soft tissues respond to impact by “crushing and stretching” bone reacts to similar trauma by fracturing.⁴⁹ Bone can fracture to varying degrees depending on impact energy and location.^{17,39,47,50,51} As expected, the greater the energy a bullet delivers, the more complex fracturing pattern and comminution will occur at bony entry and exit sites.⁴⁷ At a velocity of just 195–200 ft/s a bullet can fracture cortical bone.^{7,22} Additionally, projectile contact with bone can result in secondary missiles that are propelled along the periphery of the temporary cavity, causing more extensive injury.¹⁷ Bullets can also damage the connective tissue surrounding and attaching to bone at joints.

Soft Tissue Injuries

Firearm wounds in the extremities most frequently afflict the musculoskeletal tissues but can result in more complex injuries due to the proximity with neurovascular structures, often cohabitating in a confined space.⁵² The temporary wound cavity from high-energy missiles can rupture capillaries and other small blood vessels, while larger arteries and nerve trunks seem to be injury resistant.^{17,18} Skeletal muscle appears to be especially susceptible to permanent cavitation causing cytoplasmic clotting, interstitial extravasation of blood, striation damage, and swelling of muscle fibers up to five times their normal size.¹⁷ Together, these effects can cause localized edematous response, contributing to compartment syndrome and further damaging adjacent soft tissue.⁵³

Initial Evaluation

When GSW injury victims are assessed, details regarding the proximity and position of the shooter, number of shots fired, and the type of firearm should be collected, if possible. All bullets and fragments should be accounted for and used

to determine the necessity of surgery. If the total number of entrance wounds does not equal exit wounds plus retained bullets, fragmentation, embolization, ricochet, or migration to an unsuspected location may have occurred. While the patient's history and account can be helpful for management, they may be unknown or difficult to collect, thus it is best to "treat the wound, not the weapon".⁵⁴

Diagnostics

It is strongly recommended to obtain radiograph imaging of the affected extremity, as well as one body cavity above and below the wound.¹⁷ Plain film radiography taken with multiple views, can show bullet components, identify fractures, and reveal information about the bullet's internal track.^{7,55} Magnetic resonance imaging (MRI) is contraindicated given the metallic nature of common projectiles.⁵⁶

Careful examination for the presence of other foreign materials should be completed, as it is difficult to capture clothing fragments, wadding, and certain metal jacket casings on plain film. Indicators of possible clothing infiltration can include evidence of an irregular bullet, a larger entrance wound than estimated by caliber and range, or the absence of clothing near the entrance site. CT scans offer multiple views with a higher resolution and greater sensitivity, which allows for detection of radiolucent materials, such as the fiber, paper, or plastic used in the bullet design.⁵⁷ Imaging may also aid in the detection of distance injuries due to stray fragments resulting from impact, which could undergo arterial or venous embolization. Vascular injuries can be identified using digital subtraction angiography or CT angiography.⁵⁸ Multiple detector CT angiography constructs a three-dimensional image that can better detect and localize vascular and soft tissue injuries in addition to bullet components and fracture details.⁷

If there is evidence of joint violation or intracapsular bullet material, plain radiographic imaging or joint aspiration results can provide valuable diagnostic information.⁵⁹ In uncomplicated cases, arthroscopy can aid in diagnostics but the most sensitive test is a fluoroscopically assisted arthrogram.^{59,60} If the results are inconclusive, or the intended method of imaging is not feasible, a CT scan can be obtained.¹⁷ Whenever migration is suspected, ultrasound or intraoperative fluoroscopy should be performed to visualize the exact location of the projectile before an incision is made.^{61–64}

Prophylactic Antibiotics

By disrupting the skin and other organs, GSWs allow microbes to be transported to damaged tissue from external and internal sources, such as the surrounding environment, clothing, the gastrointestinal and genitourinary systems, or the projectile itself.^{4,7–10} Both superficial and deep infections can occur due to penetrating GSW injury, with one Level I trauma center reporting infection rates as high as 15.7%.⁶⁵ High energy GSWs appear to be more likely to develop infection, as a greater amount of tissue is devitalized and host defenses may be diminished.⁶⁶ Following a GSW, aerobic and anaerobic organisms can rapidly multiply if introduced to tissue by the projectile.⁶⁷ Specific GSW injury regions such as the hand, hip, foot, and distal tibia are associated with an increased infection risk.^{59,68–72} Perforation of vascular, gastrointestinal, or genitourinary tissues can also dramatically increase the risk of infection and sepsis.^{73–75} Additionally, nonviable, anaerobic musculature can provide an ideal growth medium for various bacterial species, including *Clostridium* spp.⁶⁷

In the case of traumatic projectile injuries, prophylactic antibiotics are used to prevent localized infection and progression to osteomyelitis or sepsis.⁷⁶ A systematic review by Sathiyakumar et al identified that 10 out of 11 studies providing "high-quality" data on antibiotic administration recommended prophylactic antibiotics for high-energy GSW injuries.¹⁰ For low-energy GSWs, four of eight studies in which patients were treated non-operatively and four of six studies with both operative and non-operative patients definitively recommended prophylactic antibiotic use.¹⁰ Although antibiotics are a mainstay of GSW treatment, there is a lack of consensus in the literature regarding the dosage, duration, route, and type of antibiotics used for preventing infection.^{9,10,77–79} In a recent questionnaire completed by Orthopaedic Trauma Association (OTA) members, responses exhibited wide variability in standard antibiotic treatment practices by administration route or usage at all.⁷⁹ Interestingly, less experienced providers (≤ 5 years in practice) tended to be more aggressive in antibiotic treatment.⁷⁹

Recommendations of antibiotic type vary depending on the wound presentation, level of gross contamination, bacterial species identified in culture, and patient demographics or comorbidities. Among those commonly cited are

benzyl penicillin, oral fluoroquinolone, IV cephalosporins (first or third generation), aminoglycoside, and/or gentamicin.^{13,45,72,76,80,81} Prompt administration of antibiotics is recommended.^{13,82} While short courses have demonstrated positive clinical outcomes in many studies, the recommended duration varies from 24 to 72 hours depending on the author or specifics of the case.^{13,15,59,76,78,81,82} It should be noted that antibiotics are never to be used as a substitute for surgical debridement in soft-tissue injury.¹⁸ Nevertheless, it is important to consider the bullet contaminated and treat the tract with similar antibiotic prophylaxis as other penetrating wounds.

Non-Operative Management

In general, low-energy GSWs are uncomplicated injuries with little to no bullet fragmentation, soft-tissue disruption, or bone comminution outside of the primary cavitation.⁸³ Most low-energy GSW fractures can be treated nonoperatively according to standard closed fracture protocols in an outpatient setting.¹⁷ Non-operative intervention is also favored as surgery could unnecessarily increase risk of infection, disruption of local blood supply, and further damage soft tissue, with minimal added benefit. Superficial debridement is an acceptable substitute for surgical irrigation and debridement when the patient is negative for wound contamination, vascular injury, large soft-tissue defects, and compartment syndrome and does not require surgical fracture stabilization.¹⁰ Additionally, some cases of intra-articular GSW that lack evident pathology can be treated non-operatively.^{65,84}

Potentially Contaminated Low-Energy GSWs

The lack of consistent antibiotic recommendations is more pronounced for low-energy GSW treatment with and without osseous involvement.^{9,10} Many of the studies conducted assessing superficial and deep infection rates did not demonstrate statistical significance, possibly due to less devitalized tissue in low-energy wounds.^{39,66,68} Additionally, some concluded that appropriate debridement and immobilization of minor, low-energy GSW can negate the need for antibiotics.⁸⁵ However, in an OTA questionnaire, 86% of members reported to routinely prescribing first generation cephalosporins for low-velocity ballistic fractures, despite only 26% reporting having set protocols for antibiotic use at their institution.⁷⁷

A handful of studies have demonstrated that antibiotics reduce infection risk in low-energy GSW patients and minimize or eradicate the development of osteomyelitis and deep infections.^{10,65,73,86} Most of these studies used a first-generation cephalosporin, such as cefazolin.^{10,65,73,86} Meanwhile, various other studies have found no significant statistical difference in infection rates for patients who received antibiotics and those who did not.^{9,68,85} Marcus et al did note that the patients who did not receive antibiotics developed more severe infections.⁸⁵ Additional studies assessed the differences in outcomes of low-energy GSW patients, with or without fractures, who received antibiotics through variable administration routes. These authors concluded that IV cephalosporin, IM cephalosporin, and oral fluoroquinolone were equally effective in this setting.^{66,70,71} Likewise, no differences in infection morbidity between IV cefazolin or IV ceftriaxone was observed.⁸⁷ Interestingly, one study found that there was no additional reduction in infection risk between patients who received one or multiple doses of IV cephalosporin (first generation), following low-energy GSWs with osseous involvement.⁷³ These mixed findings further complicate the creation of specific guidelines.

In non-complicated cases such as many low-energy GSWs, entrance wound excision and bullet track irrigation are sufficient.^{10,45,54,68,88} A length of saline-soaked gauze can be passed through the wound to identify the bullet track, which should then receive irrigation.⁸⁹ Following superficial debridement, it is advised to avoid immediate primary closure of the bullet wound as this could lead to contamination. The wound should be left open and covered with sterile dressing for delayed primary closure or healing by secondary intention.^{38,90}

A study by Shultz et al, which retrospectively assessed the outcomes of 46 patients with low-energy GSWs, found that there was no statistically significant difference in infection risk for patients that received antibiotics, primarily cefazolin, and non-operative wound care versus those who received antibiotics and formal irrigation and debridement (I&D).⁹¹ However, it was noted that if I&D is conducted in patients with minimal soft tissue damage and minor wound contamination, it may lead to additional tissue damage and exacerbate joint stiffness.⁹¹ Additionally, a prospective, randomized clinical trial by Brunner and Fallon, comparing I&D to bedside wound care for low-energy GSWs, found similarly low rates of superficial infection in both groups.⁹² Thus, for traumatic low-energy GSW, conservative treatment such as bedside I&D are recommended. Additionally, most agree that routine prophylaxis is recommended

in all low-energy GSWs, as contamination is not always obvious.^{70,81,87,93,94} Omid et al recommended that the degree of soft-tissue injury should be the main determining factor when deciding on duration, type of antibiotics, and need for debridement.¹³

Surgical Intervention

Recent research has better established indications for surgical intervention in management of both high and low energy GSWs, including presence of considerable tissue damage, major vascular injury, progressive neurologic deficits, obvious contamination, joint involvement, compartment syndrome, unstable fractures, tendon injuries, superficial fragments in the palm, and patients presenting at least 8 hours after injury.^{95,96} Of note, complex extremity GSWs with involvement of more than one organ system should be treated by a team lead by an orthopedic surgeon.⁹⁷

Formal Irrigation & Debridement

The efficacy of surgical debridement in preventing infection has limited published data available and has historically been debated.⁷⁴ Watters et al showed debridement did not make a significant difference unless there was concomitant gastrointestinal injury from the bullet tract.⁷⁴ Shultz et al showed no statistical difference in knee infections when GSWs were treated operatively with irrigation and debridement versus nonoperatively with antibiotics and wound care.⁹¹ A debridement procedure along the bullet track may be beneficial to excise necrotic tissue and stimulate growth factor activity,⁹⁸ but the specific utility after a GSW remains unclear in the literature.

In general, formal surgical debridement is recommended in cases of extensive soft-tissue damage, fascial tissue violation, necrosis, contamination, compartment syndrome, periarticular fractures with joint involvement, GI tract involvement, vascular or spinal cord injury, or advancing neurologic deficits.^{10,17,83,97,99} Additionally, surgical debridement is often required if the wound is in a location with increased infection risk, such as the hand, pelvis, distal tibia, or foot.⁸¹ If significant tissue disruption is present, debridement of all contaminated, devitalized, and necrotic tissue should begin promptly, ideally within 6–8 hours following injury, to reduce infection risk and promote proper wound healing.^{17,82,100,101} Patients presenting more than 8 hours after injury may be better candidates for surgical debridement than local wound care, as the risk of more extensive ischemia, necrosis, or infection can increase over this time.¹⁷

Assessing tissue viability can be exceedingly difficult in extensively contused or lacerated tissue in the early post-injury period, with the most important factor is determining damage being the experience of the surgeon.^{17,39,50,100,102} To determine if muscle tissue requires excision, the “four C’s”, which are color, consistency, contractility, and capacity to bleed, can be applied.²³ If muscle tissue is dark, noncontractile, and non-bleeding, this can be seen as indicative of necrosis and prompt excision.⁸² However, if muscle viability is unclear, it can be preserved and reevaluated later to avoid excessive debridement and avoidable damage to associated vasculature.^{17,100} In such cases, Riddez et al recommends an early second exploration within 24 hours, if needed.⁸²

To excise any residual marginal tissue, subsequent I&D can be implemented regularly 2–10 days following injury, depending on the state of the patient and their wounds. Following proper debridement, wounds should be left open for delayed primary closure. Sterile wound dressings should be applied and replaced every 3–5 days if there is no indication of infection. During excision and exploration, it is also crucial to excise excess debris because any foreign material, such as clothing or shotgun wadding retained within the body is subject to abscess formation and chronic wound drainage.¹⁰³ If debris excision is incomplete, contrast imaging can assist in locating foreign bodies before further exploration.³⁸

Negative pressure wound therapy, a standard treatment method for soft-tissue defects and deep wounds, should be used as it can reduce dead space and infection.^{83,104,105} Wound closure should be conducted in the first 10 days, as the skin edges are more mobile, making approximation less difficult.¹⁰³ If wounds remain uncontaminated, early closure can be implemented with the benefits of reduced scar contracture, joint stiffness, infection risk, and length of stay in the hospital.^{89,103}

Contaminated Complex GSWs

While there are minimal data concerning debridement practices for high-energy ballistic injuries, the existing literature promotes formal irrigation and debridement, immobilization, and delayed primary wound closure.¹⁰ High-energy GSWs require more extensive or serial irrigation and debridement due to characteristic bone combination, bullet fragmentation, and significant tissue disruption, cavitation, and necrosis.^{38,90,106,107}

In addition to formal debridement, soft-tissue reconstruction may be necessary. High-energy injuries typically have margins ranging 1–5 mm across, although if significant tissue devitalization is present or extensive debridement is conducted, the wound size may increase requiring coverage or grafting.⁵¹ If tension is needed for wound closure, skin grafting is the most desirable option, but if neurovascular repair, osseous reconstruction, or amputation are necessitated, local rotation flaps or free tissue transfer are advised.^{14,22,108,109}

Despite relatively few high-quality studies regarding the administration of antibiotics for high-energy and intra-articular GSWs, they remain a mainstay in treatment due to the high infection rates associated. Meade et al recommended that patients requiring surgical intervention should receive antibiotics pre-, peri-, and postoperative.⁵² In line with these findings, 48–72 hours of IV antibiotic administration is recommended for high-energy injury.¹⁵

If obvious contamination by foreign materials (eg, clothing), fractures requiring operative stabilization, and GSWs with intra-articular involvement are present in a low-energy injury, formal surgery may be indicated.⁹¹ Additionally, if there is any uncertainty of the involvement or extent of soft tissue damage or vascular injury is present, surgical exploration is advised, as the risk of infection is increased.^{67,110} If a low-energy GSW presents with an intra-articular fracture, a fracture requiring stabilization, or obvious contamination, IV cephalosporin with the possible addition of an aminoglycoside are indicated before and following surgical intervention.^{59,78,81}

Further, Kobbe et al recommended that any highly contaminated wound or any intra-articular GSW should be given antibiotics irrespective of energy transfer.¹¹⁰ Cases presenting with gross wound contamination, major tissue devitalization, sizable wounds, treatment delays, or the presence of multiple injuries, are also indications for antibiotic administration.⁷⁷

Treatment of Concomitant Injuries

High-energy fractures are often analogous to open fractures due to the significant soft tissue damage.^{17,93,108} Unstable fracture patterns that require internal fixation necessitate surgical intervention for stabilization.^{17,81,111–113} Consulting a GSW injury guide such as the one created by Kobbe et al, which organizes low-energy (type I or II) and high-energy (type III) fractures using Gustilo-Anderson classification system, can be used to guide treatment decisions.^{110,114}

In a retrospective study assessing treatment of femur fractures from projectiles primarily treated with an intramedullary nail, 50% of the patients with high-energy wounds developed deep infections and required serial debridement.¹¹⁵ Due to the elevated incidence of contamination with high-energy wounds, primary stabilization with an external fixator is advised to allow continued access for wound care.¹¹⁰ Stabilization can be converted to definitive osteosynthesis within 14 days after soft tissue recovery.¹¹⁰

If there is vascular damage, repair is ideally performed after fracture stabilization. Although there is a debate over the ideal timing for exploration and repair of peripheral nerve damage following trauma, there is consensus that nerve reconstruction, in addition to mending fractures, should be considered early in treatment.^{109,116–118} A recent review by MacKay et al recommended that after blunt trauma or GSW, if the zone of injury is clearly established, immediate exploration and peripheral nerve repair may be warranted as to avoid long-term nervous insufficiency.¹¹⁹ The advantages of early exploration include improved outcomes and shorter graft length requirements, which may be attributable to avoiding dense scar tissue formation and intraneural edema. Ultimately, the decision is subject to clinical judgment and individual patient/injury characteristics. However, when the zone of injury is unclear, a wait time of 2 to 3 weeks is advised.¹¹⁹

Penetrating injuries that result in vascular injury above the knee and fracture to the proximal tibia are at high risk of causing compartment syndrome.¹²⁰ Fascia and skin may only need limited debridement except in cases of perforation

where they must cut open to provide exposure to the underlying damaged tissue. In addition, any suspicion of compartment syndrome warrants fasciotomy.

Retained Bullet Removal

Bullets from nonfatal GSWs are not always removed during index admission, resulting in retained bullets or bullet fragments.¹²¹ Clinical and radiographic photographs of GSWs with retained bullets or bullet fragments in various locations are included in [Figures 4–7](#). While removal is not indicated in all cases, it is reported that GSW patients who do not have the projectile extracted are at increased risk of repeat visit to the emergency department within 6 months.¹²² Over a 1-year period, a trauma registry identified 344 patients who were admitted for a GSW, of which 298 were nonfatal. Of these cases, 75.5% had a retained bullet fragment. 10.2% had complete removal at index admission, 15.6% had partial removal, and 74.2% had no removal. The primary indication for removal was immediate intraoperative accessibility (67.2%) and the most common location for a retained fragment was in soft tissue (58.7%). 116 of 202 patients discharged with a fragment presented for follow-up, and 11.2% returned with a retained bullet-related complication at a mean time of 130.2 days with four patients requiring removal.¹²¹

When considering bullet removal, prevention of arthritis, infection, plumbism, vascular emboli, and spontaneous migration are the main focus of treatment.^{17,69,123,124} Prophylactic removal is typically only recommended when a bullet is located intra-articular, intra-bursal, or on a weight-bearing surface such as the palm or sole of the foot after swelling resolves.³⁸ If intra-articular fragments, either osteoarticular or metallic, are appreciated in imaging or by physical exam, surgical removal is also indicated.^{60,91}

If a bullet cannot be felt with palpation or is positioned in soft tissue without joint involvement, it should generally be left alone.³⁸ Since projectiles located in soft tissue are swiftly enclosed by avascular scar tissue, the risk of lead poisoning and infection is low.³⁸ In these cases, surgical removal can cause more soft-tissue trauma than the GSW itself.^{110,125} Therefore, low energy retained bullets will not routinely be removed because formal exploration and debridement are

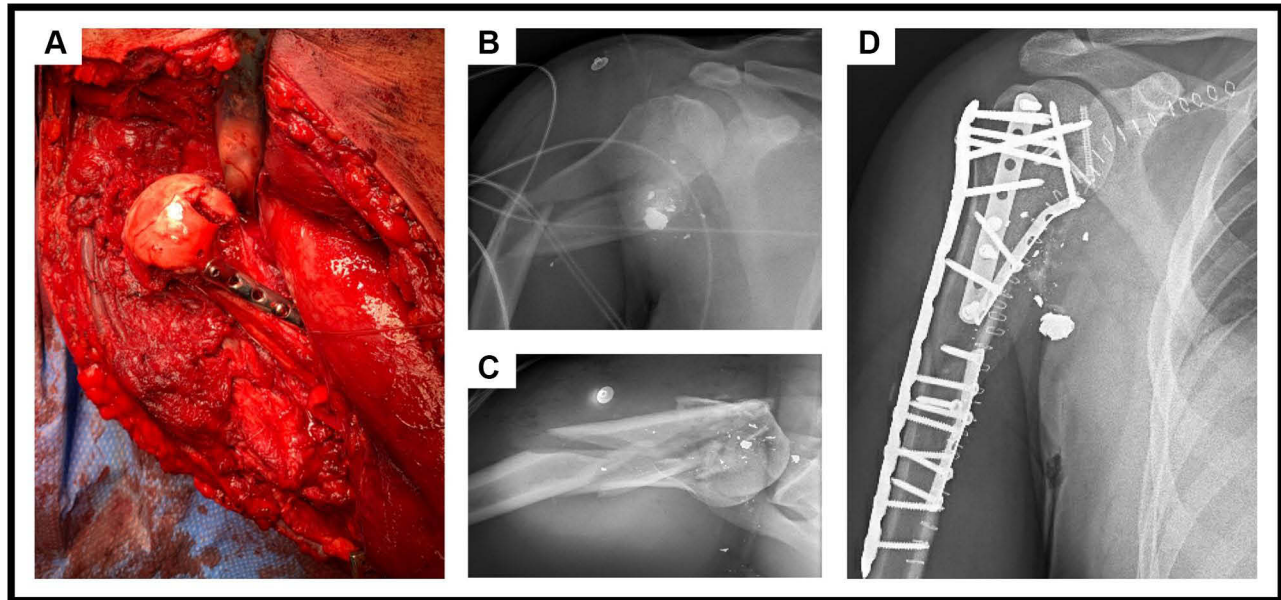


Figure 4 Hollow Point Gunshot Injury to the Shoulder.

Notes: (A) There was evidence of an acute comminuted burst fracture of the humerus including the head, neck, and proximal metadiaphysis with extensive pectoralis muscle damage, a partial laceration to the cephalic vein, and a large missing bone void of the humeral head. On radiograph, multiple free-floating metallic bullet fragments were found with the largest metallic bullet fragment measuring 1.5 cm (B and C). The wound was irrigated, and all free-floating bone fragments and necrotic or loose tissue were removed. (D) The humeral shaft fragments, articular fragments, and proximal humerus fracture were reduced. An extended Synthes small fragment plate was placed spanning both the humeral neck and shaft fractures and bone graft was applied into the bone void of the neck.

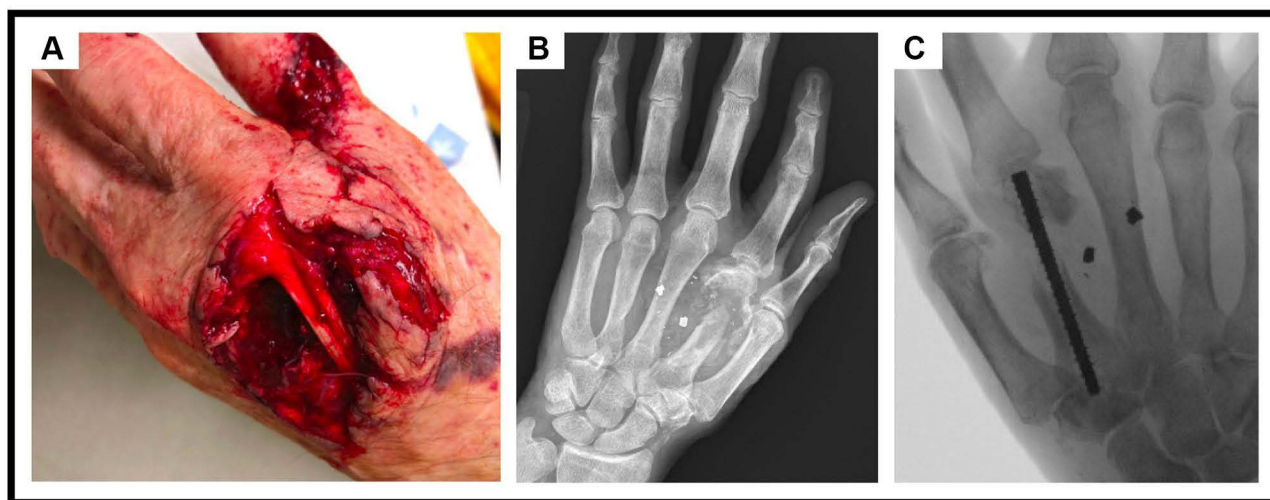


Figure 5 Gunshot Injury to the Hand from a 9 mm Pistol.

Notes: (A) Initial clinical photograph reveals a 9×5 cm wound from the gunshot injury. (B) The patient sustained a comminuted fracture of the second metacarpal with segmental bone loss and two accompanying bullet fragments. The fracture site was treated with an intramedullary headless nail and a combination of crushed bone allograft, demineralized bone matrix (DMX) putty, and bone venous blood. (C) Radiographs eight months after the injury show persistent retained fragments.

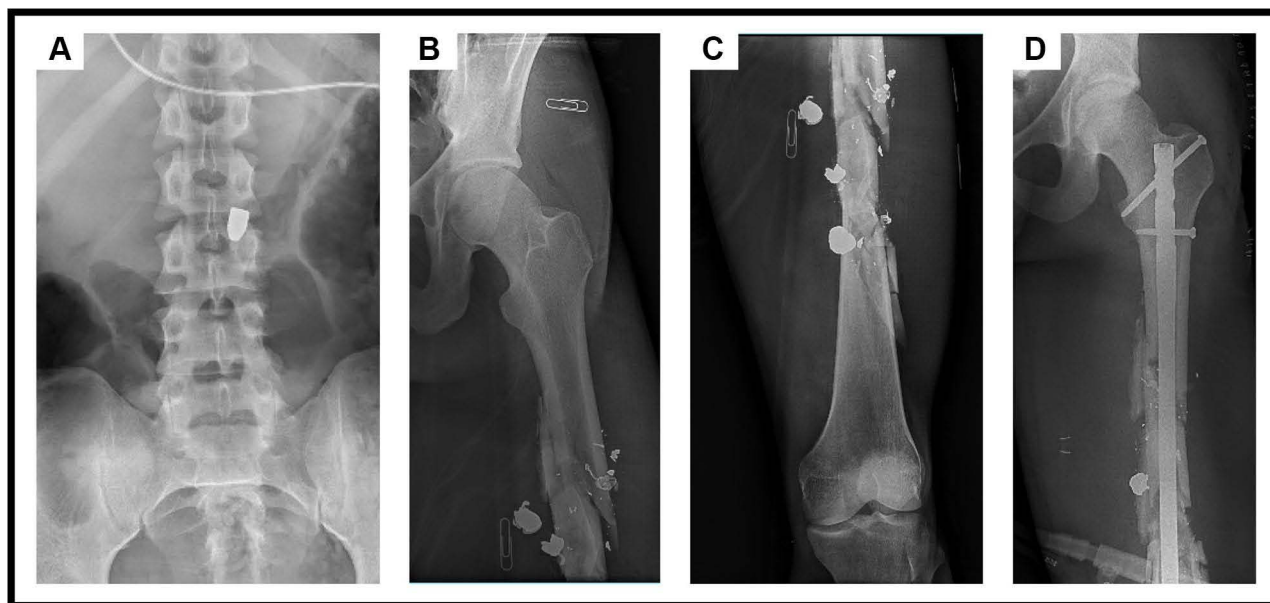


Figure 6 Multiple Gunshot Injuries to the Torso and Thigh.

Notes: (A) The gunshot injury to the abdomen was retained anterior to L3 vertebra with accompanying comminuted fractures of the L3 and left lateral L4 vertebrae. One bullet notably struck the femoral shaft, resulting in comminuted fracture of the midshaft with multiple bullet fragments. Entry and exit wounds on radiographs are indicated with paperclips (B and C). (D) The femoral fracture was fixated with an intramedullary nail.

generally not needed. Since high-energy wounds typically require debridement anyways, bullet removal will not cause significant additional damage and is therefore indicated to reduce sepsis risk. If there are high energy bullet fragments positioned away from the site of wound exploration removal will predominantly depend on the location.

Despite several techniques available to retrieve bullets and bullet fragments, there is little to no existing data to elucidate optimal treatment. A small number of studies propose that bullets with intra- and peri-articular involvement, require arthroscopic, arthrotomy, or open debridement, though this is not yet widely agreed upon.^{10,60} Arthroscopy possesses potential benefits over open procedures including minimal invasiveness, reduced blood-loss, decreased surgical

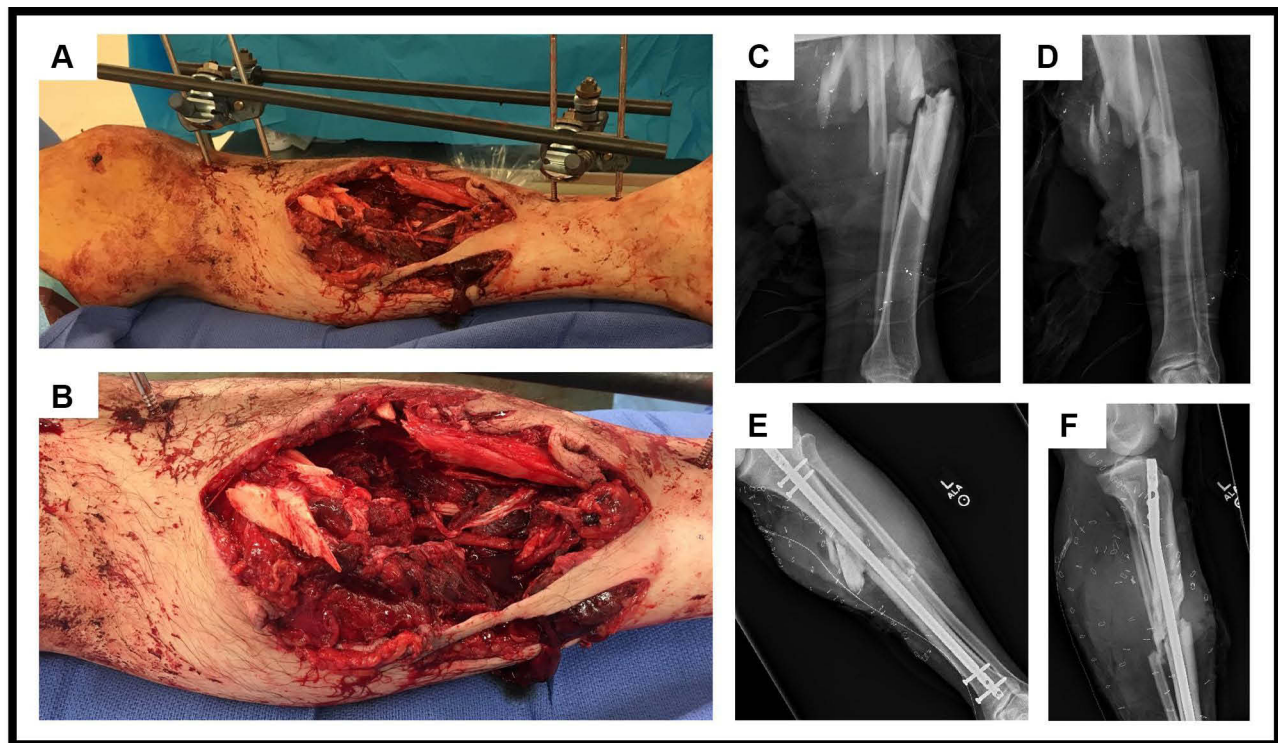


Figure 7 Gunshot Injury to the Lower Extremity from a High-powered Assault Rifle.

Notes: Clinical photographs show a traumatic wound measuring 16×16 cm with significant muscular, fascial, nervous and vascular injury (A and B). Comminuted and markedly displaced fractures through the mid diaphysis of the tibia and fibula with extensive shrapnel are evident on initial radiographs (C and D). A total of 16 operations were performed for this injury. During the initial operation, small pieces of fabric, bone, and metallic objects were removed, the tibial nerve was repaired, ligation of posterior tibial artery and vein was performed, and a tibial external fixator was placed. Five repeat I&D procedures were performed before the tibia was fixed with an intramedullary nail and a latissimus dorsi free flap was placed and then skin grafted (E and F). Later operations included repeat I&D and treatment of the tibial nonunion with bone grafting.

morbidity to surrounding structures, and enhanced visualization to locate and retrieve fragments.^{60,126–130} A 2020 systematic review identified 31 studies with 62 patients that underwent arthroscopically assisted bullet removal.¹²⁸ All 62 patients underwent successful bullet removal and only one patient was reported to have a complication which was compartment syndrome. Open arthrotomy can likely achieve similar outcomes; however, there are no established indications and outcomes for joint-specific arthroscopy versus arthrotomy.^{12,128–137}

In this scope of this review, we examine considerations for retained bullet removal in the upper extremity, lower extremity, and spine.

Upper Extremity Injury

Shoulder

Many studies have reported success with arthroscopic removal of bullet and bullet fragments from the shoulder, with the added benefit of using arthroscopy to treat concomitant injuries such as a subacromial impingement¹³⁸ and rotator cuff tear.¹³⁴ These reports include removal of bullet from the glenoid,¹³⁹ the glenohumeral joint,^{131,136} the subacromial space,^{134,136} the supraspinatus compartment,¹³⁸ and the scapulothoracic joint.¹⁴⁰ Guevara et al found that even with the challenge of removing large projectiles, the benefits of arthroscopy were worthwhile, including unmatched visualization and fluid irrigation throughout all joint spaces, while decreasing potential operative morbidity compared to open procedures.¹³⁹ Their case was unique in which the bullet was large and embedded in the glenoid bone rather than being free-floating like the other studies included.^{131,134,136,138–140}

Elbow

One case involving the elbow was identified in which a bullet had entered over the dorsum of the joint and lodged intra-articularly, causing interference with elbow range of motion. When arthroscopy was performed, the pellet was found anterior to the coronoid process of the ulna in the anterior recess of the joint. After removal, the patient was a symptom-free with full range of movement at follow-up.¹⁴¹

Hand

Hand injuries typically require bullet removal and warrant added attention, given the complex neurovascular networks contained within a relatively small space and increased infection risk.^{13,81} Due to the tight spaces, retained bullets can lead to complex injuries that involve a combination of tissue types including nerve, bone, tendon, and vessel injury.^{13,143} Sensory and motor nerve deficits ranging from neuropraxia to complete transection are the most common long-term concerns in patients with GSWs to the hand.¹⁴³ Additionally, retained fragments can lead to arthropathy and tenosynovitis.¹³ A recent literature review by Turker and Capdarest suggested the most important goal after GSW trauma to the hand is functional recovery, and the best management involves early debridement, antibiotic prophylaxis, reconstruction, and physical rehabilitation.⁹⁵

Omid et al recommended that upper extremity retained bullets restricting motion, causing nerve impingement, located within a vessel, or located subcutaneously within the hand or wrist, should all be removed.¹³

Lower Extremity Injury

Hip/Pelvis

GSWs in the hips or pelvis are often complex, involving vascular, visceral, or urogenital injuries.^{144–146} Retained bullet fragments within this area have high potential for osteoarthritis, synovitis, infection, lead toxicity, and systemic effects, thus warranting extraction.^{81,90,147–150} Further, hip or pelvis GSWs that transverse transabdominally, piercing the gastrointestinal system, may be contaminated by bowel contents, increasing risk for infection.⁸¹ Available literature indicates that transabdominal GSWs with intra-articular contamination should be treated immediately with I&D and bullet removal. In cases of extra-articular transabdominal GSW with stable fractures, non-operative management with observation and empiric antibiotics can be employed.¹⁵¹

Numerous techniques have been described to remove bullets in the hip and pelvis region including arthroplasty, arthroscopy, and arthrotomy with or without surgical dislocation.^{126,127,137,145,152–158} Yet, no single approach seems to be superior for all cases. Sacroiliac joint involvement make extraction difficult, as arthroscopy and arthrotomy cannot successfully access the joint, yet a percutaneous minimally invasive removal has been successfully performed in this location.¹⁵⁹ Arthroplasty is an effective treatment modality in cases of resultant post-traumatic arthritis with intra-articular gunshot or shell-fragments, as documented in a retrospective study including 26 patients.¹⁶⁰ In these cases, total hip arthroplasty successfully reduced pain and improved joint function.¹⁶⁰

Overall, arthroscopy appears to be a safe and effective technique for the removal of intra-articular bullets in the hip. At a single institution, 11 patients with retained intra-articular projectiles in the knee (n = 6), hip (n = 4), or sacroiliac (n = 1) joints were treated with arthroscopically assisted extraction. Overall, the authors reported a 90.9% success rate of bullet extraction, with the only complication involving a knee. Howse et al described an arthroscopic surgical technique that was efficacious in 4 patients who each had a diverse bullet trajectory and associated pathology.¹²⁶ In all, we identified thirteen case studies in which arthroscopic removal of bullets and other foreign bodies from the hip joint were performed with good outcomes and minimal complications.^{127,132,137,145,153,154,156,161–166} Two interesting cases included arthroscopic removal of a bullet at the site of a primary total hip arthroplasty¹⁶³ and two different bullets from the acetabulum, which had traveled transabdominally perforating bowel tissue (rectum, small bowel, and sigmoid colon) before settling.^{163,164} Despite these propitious results, there may be cases where hip arthroscopy is not a sufficient option.¹²⁶

In one case, a 32-year-old male sustained a low-velocity GSW that traversed the femoral neck and lodged in the acetabular side of his hip joint.¹⁶⁷ Two years after arthroscopic removal, the patient experienced groin pain and underwent arthrotomy with safe surgical dislocation to treat the femoral chondral defect.¹⁶⁷ His resolution of symptoms suggests that arthrotomy may be beneficial when further complications arise.¹⁶⁷ Delaney et al documented a case in

which a bullet was removed from the femoral head by arthrotomy with surgical dislocation. In this case, an open approach was utilized because the bullet appeared embedded inside the posterior aspect of the femoral head and the femoral head fracture exhibited multiple fragments that could possibly require fixation.¹⁵² Further, the authors believe it would have been difficult to achieve the same result via arthroscopy or arthrotomy without dislocation.¹⁵² Maungo et al reported a case series of 10 patients in which surgical hip dislocation with trochanteric osteotomy was used for bullet removal.¹⁵⁵ They found that the unrestricted view of the acetabulum and femoral head and neck improved visualized and allowed for successful removal in 9 of the 10 patients.¹⁵⁵

Knee

Najibiet al found approximately 50% of GSW cases involved the extremities and that the knee was the most commonly involved joint.¹⁶⁸ Knee injuries are generally treated with irrigation and debridement via arthroscopy.^{130,133,169–171} Decreased length of hospital stay and increased range of motion have been demonstrated following knee arthroscopy compared with arthrotomy.¹³⁵

Oladipo et al reported 13 cases in which intra-articular GSWs were treated arthroscopically within 24 hours of injury.¹³³ They reported concomitant injuries including fractures requiring internal fixation, cruciate ligament tears, meniscal damage, and avulsion fractures. Despite the complex nature of the cases, the authors reported no infections or operative complications.¹³³ As described prior, the study by Lee et al saw a 90.9% success rate of arthroscopically assisted intraarticular bullet extraction from various lower extremity joints. Of the 6 knee cases included, only one case required conversion to an open approach to avoid iatrogenic osseous damage to the posterior aspect of the femoral condyle.¹⁷² Arthroscopic removal has also been performed to effectively extract a bullet from the infra-articular fat pad,¹⁶⁹ multiple shotgun bb's from the synovium,¹³⁰ and in a bilateral knee joint GSW injury, from the popliteus tendon and the medial condyle of the femur.¹⁷³ In addition, a GSW to the knee with traumatic intra-articular defect was successfully treated with arthroscopic I&D through both standard anterior portals and existing entry and exit wounds. This allowed for thorough debridement of the entire missile path and successful removal of all bullet fragments.¹⁷⁴

Tornetta et al examined the difference between radiographic and arthroscopic findings in 33 patients with a GSW through the knee.⁶⁰ They found 5 chondral and 14 meniscal injuries not seen on plain films. Importantly, 7 patients with negative plain films were found to have intraarticular pathology during arthroscopy. They concluded that a lack of radiographic findings does not rule out intraarticular debris, chondral injury, or meniscal pathology and plain films should not govern the need for arthroscopic evaluation. The authors recommended arthroscopic bullet retrieval, along with meniscal and/or chondral repair at the time of arthroscopy. However, there is a small risk of compartment syndrome development secondary to arthroscopy if the articular capsule is ruptured.¹⁷⁵

Ankle

Retained bullet fragments in the distal lower extremity are poorly tolerated due to the insignificant soft-tissue envelope surrounding the foot and increased infection risk.⁸¹ Thus, in cases with superficial retainment, removal is likely the best option.¹²⁰ Additionally, bullets located in the tibiotalar and subtalar intra-articular spaces should be removed.

Ankle arthroscopy has been shown to successfully remove bullets in these regions, including two cases in the subtalar region.^{176,177} One case involved a 33-year-old woman who did not have the fragments removed on initial presentation then returned 9-months later with persistent pain. She was treated arthroscopically and had complete resolution of pain at one-week postop.¹⁷⁶ The second case had a retained bullet fragment distant from the entry wound, found within the subtalar joint and extending into the calcaneus.¹⁷⁷ An arthroscopic drill and tap approach was used to successfully remove the fragment.

Another case involved the delayed removal of a bullet, 49 years after the initial GSW to the ankle. The patient presented with significantly elevated blood lead levels and severe tibiotalar lead arthropathy. Initial treatment included preoperative chelator therapy with arthroscopic debridement, bullet fragment excision, and partial synovectomy. These interventions failed to resolve the patient's pain and elevated blood levels, so subsequent arthroscopic ankle arthrodesis with preoperative chelator therapy was carried out.¹⁷⁸

Spinal Injury

GSWs are the third most common mechanism of spine injury and account for 13–17% of spinal cord injuries (SCI) each year.^{63,179,180} Spinal GSWs provide many opportunities for complications, including retained bullets lodging in intervertebral disks causing plumbism,^{181,182} and migrating bullets causing cauda equina syndrome.^{61,63,64,183} Depending on the spinal level involved in injury and amount of nerve transection, variable symptoms and outcomes can present. Injuries located in and cranially to the thoracic spine are associated with poorer outcomes, especially cervical injuries, which can result in abysmal recovery and detrimental effects, such as ventilator dependence.^{184,185} Accordingly, cases caudal to T12 have shown better surgical outcomes following bullet removal compared to those cranial/rostral to T12.^{180,186} These findings are likely correlated with the prevalence of complete SCIs associated with cervical and thoracic injuries.¹⁸⁰

The goal of surgical bullet removal from the spine is to mitigate complications or encourage neurological recovery.^{63,185–187} Patient symptoms and neurological status are key guiding factors in determining whether to choose conservative or operative treatment, thus serial neurological examinations and imaging are imperative so that any changes can be promptly detected and treated.⁶⁴ Timely removal of intra-canalicular bullets in the case of incomplete SCI can allow for axonal regeneration and has been observed to allow for meaningful neurologic recovery and symptom improvement.^{63,188} However, removal of bullet fragments for complete, static SCI are not associated with significant restoration of neurologic function.^{180,189–192}

Overall, if progressive neurological changes, lead intoxication, spinal instability, persistent cerebrospinal fluid leak or infection are identified, the literature supports surgical intervention.^{61,63,184–187,189} Escamilla et al reported that of their 54 cases, the chief indications for surgery were instability secondary to vertebral body burst fracture, and bullet removal when it was lodged in the spinal canal.⁹⁹ The authors noted that if a dural lesion is present, projectile extraction is recommended, as removal can decrease risk of CNS exposure to lead or other toxic metals.⁹⁹ However, if concomitant lower GI tract perforation is seen with an SCI lesion, surgical intervention may be contraindicated or temporarily delayed, as this combination increases the probability of surgical site infection.⁹⁹ Due to the potential severity of neurologic and systemic symptoms that can present in the course of spinal GSW injury and surgical intervention, further research is needed to assess when bullet removal is beneficial to patient recovery.

Retained Bullet Complications

Multiple studies state that retained intraarticular bullet fragments can increase the risk of heavy metal absorption and toxicity.^{91,125,193} Additionally, contaminated bullets or fragments retained in the joint space can lead to cartilage damage, joint sepsis, and rapid chondrolysis.^{73,147} Isolated cases of retained intra- or pericapsular bullets have been observed to limit joint mobility, impinge neurovasculature, and lead to synovitis and osteoarthritis.^{46,147} Long-term complications with retained bullets, such as infection, chronic pain, and bullet migration have also been documented.¹⁹⁴

Lead Toxicity

Injuries which result in retained bullet fragments carry a small but identifiable risk for plumbism or lead toxicity, defined as blood lead ≥ 10 $\mu\text{g}/\text{dL}$, which have been reported to occur within 2 days to 40 years of GSW.^{148,195,196} Unfortunately, lead toxicity can be difficult to predict and diagnose.^{197,198} Symptoms including headache, fatigue, nausea, abdominal discomfort, anemia, kidney failure, encephalopathy, and neuropathy typically only occur at serum lead levels of >24 $\mu\text{g}/\text{dL}$.^{125,199}

Plumbism is more likely if fragments are retained within a joint space, bone, or intervertebral disk, though the latter is less common.^{17,89,181,182,200–202} Lead is highly soluble in synovial fluid, thus retained bullets in intra-articular spaces can lead to both local and systemic effects.¹⁴⁷ After dissolving in synovial fluid, the lead can become deposited in sub-synovial tissue, resulting in foreign body reactions, arthritis, chronic irritation and inflammation, and absorption into the systemic circulation.²⁰² Mechanical forces inside the joint can crush the bullet and lead to secondary damage by abrading the joint surface.^{110,136} Plumbism has been found to be positively, and separately, associated with the number of retained fragment, the presence of bony fractures, and formation of cysts.^{203–205} A study of 48 patients with retained bullet

fragments found that time after injury was statistically associated with increased blood lead levels and this was even more pronounced in the presence of a concomitant bony fracture.^{199,206} Fortunately, bullet and fragment removal, even decades after GSW incidence, has been shown to reduce blood lead concentration from elevated levels in specific cases.^{178,205}

Lead toxicity and systemic uptake is less likely if bullet fragments are retained in soft tissue, because avascular fibrotic tissue quickly envelopes the foreign bodies.²⁰² It is commonly accepted that the formation of fibrous scar tissue creates a barrier around the lead, averting systemic absorption.¹⁹⁹ However, risk of plumbism is still present with extraarticular bullet fragments. If a fluid-filled cyst forms around the bullet fragments, rather than scar tissue, this may permit the release of lead by macrocytic phagocytosis which can then absorb into the bloodstream, causing systemic dissemination.²⁰⁷ Although overt lead toxicity is still uncommon, lead levels should be monitored in these cases due to the dangerous and at times permanent consequences of chronic or acute lead toxicity.¹⁹⁹

Plumbism may lead to neurotoxicity, cognitive dysfunction, peripheral neuropathy, anemia, chronic fatigue, emesis and nausea, decreased fertility, abnormal menstrual cycles, abdominal colic, and renal disease.^{196,202,208} Even in asymptomatic adults, long-term exposure of low amounts of lead, may still bring about lasting consequences in renal, cardiovascular, cognitive function.¹⁹⁹ While only 0.3% of US adults with elevated blood lead levels can be attributed to retained bullet fragments, high levels ≥ 80 μdL are more likely to occur in these persons.¹⁹⁶ Additionally, bullets may contain other neurotoxic metals including copper, which can trigger local inflammation, necrosis, and erosion of soft tissue.²⁰⁹ Aluminum, nickel, and zinc can also be present and induce a similar inflammatory response in soft tissue.²⁰⁹

Spontaneous Migration

Rare cases of 'wandering' bullets have been observed to seed diffusely throughout the body, including the head and neck, spine, extremities, kidneys, lungs, pericardial space, portal system, and urinary tract.^{22,123} Of the documented wandering bullet cases, 0.22-caliber bullets are the most common perpetrators.¹²⁴ Depending on the eventual location of the bullet, various symptoms can arise due to impingement or occlusion.

Spinal Migration

Although bullet migration is rare, it can cause serious neurological deficit when lodged intrathecally.⁶³ Neurological symptoms may arise months or years after GSW due to late migration or epidural fibrosis around the impacted bullet.⁶³ Thus, delayed clinical symptoms in a patient with a history of retained spinal bullet fragments should make the clinician highly suspicious of migration.²¹⁰ While there remains debate, many authors recommend surgical removal of intradural bullets or larger fragments to prevent or minimize migration and resultant deterioration of neurologic functioning due to mass effect, meningitis, reactionary epidural fibrosis, lead toxicity, and risk of dystrophic intramedullary calcification.^{61,63,211}

Isolated cases have been documented and hence compiled into various reviews. One such review consisted of 29 patients ranging from 1982 to 2016 who had spinal GSWs.⁶³ Patients in this review and other cases presented with symptoms ranging from cauda equine syndrome, claudication, Lhermitte's sign, meningitis, numbness, anesthesia, hemianesthesia, hypesthesia, hemiparesis, paraparesis, paraplegia, quadriplegia, pain, sensory reduction or loss, foot drop, muscle weakness, radiculopathy, and urinary hesitancy, incontinence, and urgency.^{63,64} Additionally, one patient was found to be asymptomatic.⁶³ The primary entry points in these cases included the cranium, chest, abdomen, and cervical, thoracic, and lumbar spine.⁶³ Of those that reported the location of the bullet initial and during operation, some were found at the same spinal level, whereas others had migrated long distances from the cervical or thoracic spine to the sacrum.⁶⁴ Caudal movement appears to be much more common, although migration in the cephalad direction is possible. Caudal migration is understood to be abetted by gravity, respiration, and cerebrospinal fluid circulation.^{63,211} Cephalad migration has been observed to occur when a patient is prone during surgery or recovery.⁶³

Of the 29 patients reviewed, 22 received a laminectomy and/or a hemilaminectomy.⁶³ Four received conservative treatment and two initially received conservative treatment followed by laminectomy.⁶³ One patient died during thoracotomy and laparotomy.⁶³ Of the patients who received laminectomy or hemilaminectomy, 12 (54.5%) had a complete recovery, 2 (9.1%) had a near complete recovery, 5 (22.7%) had a partial recovery, and 3 (13.6%) saw no

change in symptoms.⁶³ Of the four patients who received conservative treatment only, two saw partial recovery, one saw complete recovery, and one had no change.⁶³ Of the two that received laminectomies after conservative treatment, they either had a complete or partial recovery.⁶³ Due to the rarity of cases, patients should receive individualized management based on hemodynamic factors, associated injuries, extent of neurological injury, and location of the bullet.^{63,183}

Two recent cases of spontaneous migration documented bullets that entered the spinal column at L2-L3 and migrated caudally to the level of S1 or S2, resulting in cauda equina syndrome.^{63,64} In one of these cases, 48-hour repeat plain films demonstrated caudal migration to S1 and development of urinary retention and diffuse allodynia to bilateral lower extremities.⁶⁴ This prompted the decision to proceed with surgical decompression and bullet removal and the patient had immediate resolution of paresthesia and urinary retention at her two-week follow-up appointment.⁶⁴ In the second patient, imaging of the lumbosacral spine three days after injury revealed that the bullet had migrated behind the S1 vertebral body.⁶³ By the next day, the bullet had migrated upwards to the level of L4, as seen by intraoperative fluoroscopy.⁶³ The bullet was then removed and upon follow-up, the patients' bilateral foot paresthesia, perianal numbness, and bowel continence were resolved.⁶³

Extremity Migration

Retained bullets in the extremities are capable of migration and should be considered for removal if similar delayed onset neurovascular symptoms or pain arises. In a case report, a 20-year-old male sustained a GSW wherein a deformed bullet was retained in the soft tissue between the middle and distal third of the thigh, close to the femur anteromedially.²¹² The bullet was left in place and the patient returned to full activities. However, 54 months after injury, the patient reported catching and locking in his knee with normal flexion and extension and radiographs revealed the bullet had migrated within the intercondylar notch. The bullet was removed arthroscopically and two weeks postop, the patient returned to full activities with complete relief of symptoms.²¹² Meena et al reported a case of a 24-year-old man who initially presented with a retained bullet near the midshaft humerus without complications.⁶² However, approximately 3 months after injury, the patient developed pain and tingling in the forearm and radiographs demonstrated that the bullet had migrated to the proximal end of the forearm. The migrated bullet was removed via ultrasound-guided extraction and within one week, the patient had resolution of symptoms.

Treatment Recommendations

Initially, bullets, bullet fragments, and other foreign materials should be accounted for with careful physical examination and imaging. The internal bullet track should be determined to identify implicated tissue and the extent of damage. If a fracture is present, a GSW injury guide, like the Gustilo-Anderson classification system, can be consulted based on low-energy and high-energy projectiles to guide treatment decisions for fractures. An external fixator is advised to allow continued access for wound care if infection risk is present. Regardless of wound characteristics, 24–72 hours of prophylactic antibiotics is recommended.

For low-energy GSW, bedside I&D is acceptable when the patient is negative for large soft-tissue defects, wound contamination, vascular injury, and compartment syndrome and does not require surgical fracture stabilization. If there is any uncertainty of the involvement or extent of soft tissue damage or intraarticular involvement, surgical exploration is advised. Low-energy GSW fractures can generally be treated nonoperatively according to standard closed fracture protocols. Additionally, low energy retained bullets are not routinely be removed if formal exploration and debridement are not needed.

In the case of extensive soft tissue damage, fascial tissue violation, necrosis, contamination, compartment syndrome, periarticular fractures with joint involvement, GI tract involvement, vascular or spinal cord injury, or advancing neurologic deficits, formal surgical debridement is recommended. Additionally, surgical debridement should be considered if the wound is in a location with increased infection risk, such as the hand, pelvis, distal tibia, or foot. Debridement of all contaminated, devitalized, and necrotic tissue should begin within 6–8 hours following injury. Following debridement, wounds should be left open for delayed primary closure. Sterile wound dressings should be applied and replaced every 3–5 days if there is no indication of infection and negative pressure wound therapy can be employed.

For high-energy GSW, surgical exploration with formal I&D and bullet removal are typically necessary. High-energy fractures are often analogous to open fractures due to the significant soft tissue damage and should be treated accordingly. Since high-energy wounds typically require debridement and operative fracture fixation, bullet removal does not cause significant additional damage and is thus recommended to reduce sepsis risk. If there are high energy bullet fragments, positioned away from the site of wound exploration, removal depends predominantly on the location. In these cases, 48–72 hours of IV antibiotic administration is recommended.

Prophylactic bullet removal is typically endorsed if a bullet or fragment is located intra-articular, intra-bursal, or on a weight-bearing surface such as the palm or sole of the foot. If a bullet cannot be felt with palpation or is positioned in soft tissue without joint involvement, it should generally be left alone. However, removal may be indicated, if a retained projectile is restricting motion, causing nerve impingement, or is located within a vessel. Arthroscopy can be used to remove bullets with intra- and peri-articular involvement. Open arthrotomy has been shown to achieve similar outcomes, however there are no reputable indications and outcomes for joint-specific arthroscopy versus arthrotomy. In the spine, bullet removal is indicated to prevent or minimize migration and resultant deterioration of neurologic functioning.

Conclusion

Management of GSW patients with retained bullet fragments has become increasingly important as the number of GSW injuries continues to rise. Historically, high energy firearms with expanding projectiles were primarily used by military personnel, but technological advances, commercial production, and increased availability of firearms has led to more cross-over between typical military vs civilian weapons. Therefore, the incidence of complex GSWs with retained bullets has risen in recent years while existing treatment protocols are decades old.

The existing literature addressing GSW and retained bullet treatment are predominantly small, low powered studies. As firearms continue to evolve, it is necessary to ensure that clinical management knowledge co-evolves through well controlled cohort studies, multicenter trials, and updated guidelines.

Acknowledgments

Cameron T Cox for help with manuscript editing. All original artwork in figures by Jaxon T Baum.

Disclosure

The authors report no conflicts of interest in this work.

References

1. Kaufman EJ, Wiebe DJ, Xiong RA, Morrison CN, Seamon MJ, Delgado MK. Epidemiologic trends in fatal and nonfatal firearm injuries in the US, 2009–2017. *JAMA Intern Med.* 2021;181(2):237–244. doi:10.1001/jamainternmed.2020.6696
2. Adibe OO, Caruso RP, Swan KG. Gunshot wounds: bullet caliber is increasing, 1998–2003. *Am Surg.* 2004;70(4):322–325.
3. Simpson BM, Grant RE. A synopsis of urban firearm ballistics: Washington, DC Model. *Clin Orthop Relat Res.* 2003;408:12–16. doi:10.1097/00003086-200303000-00003
4. Grosse Perdekamp M, Kneubuehl BP, Serr A, Vennemann B, Pollak S. Gunshot-related transport of micro-organisms from the skin of the entrance region into the bullet path. *Int J Legal Med.* 2006;120(5):257–264. doi:10.1007/s00414-005-0073-7
5. Wolf AW, Benson DR, Shoji H, Hoepflich P, Gilmore A. Autosterilization in low-velocity bullets. *J Trauma.* 1978;18(1):63. doi:10.1097/00005373-197801000-00012
6. Hafertepen SC, Davis JW, Townsend RN, Sue LP, Kaups KL, Cagle KM. Myths and misinformation about gunshot wounds may adversely affect proper treatment. *World J Surg.* 2015;39(7):1840–1847. doi:10.1007/s00268-015-3004-x
7. Pinto A, Russo A, Reginelli A, et al. Gunshot wounds: ballistics and imaging findings. *Semin Ultrasound CT MRI.* 2019;40(1):25–35. doi:10.1053/j.sult.2018.10.018
8. Lichte P, Oberbeck R, Binnebösel M, Wildenauer R, Pape H-C, Kobbe P. A civilian perspective on ballistic trauma and gunshot injuries. *Scand J Trauma Resusc Emerg Med.* 2010;18(1):35. doi:10.1186/1757-7241-18-35
9. Papasoulis E, Patzakis MJ, Zalavras CG. Antibiotics in the treatment of low-velocity gunshot-induced fractures: a systematic literature review. *Clin Orthop Relat Res.* 2013;471(12):3937–3944. doi:10.1007/s11999-013-2884-z
10. Sathiyakumar V, Thakore RV, Stinner DJ, Obremsky WT, Ficke JR, Sethi MK. Gunshot-induced fractures of the extremities: a review of antibiotic and debridement practices. *Curr Rev Musculoskelet Med.* 2015;8(3):276–289. doi:10.1007/s12178-015-9284-9
11. Smith RN, Tracy BM, Smith S, Martin ND, Seamon MJ. Retained bullets after firearm injury: a survey on surgeon practice patterns. *J Interpers Violence.* 2022;37(1–2):NP306–NP326. doi:10.1177/0886260520914557

12. Tosti R, Rehman S. Surgical management principles of gunshot-related fractures. *Orthop Clin North Am.* 2013;44(4):529–540. doi:10.1016/j.ocl.2013.06.006
13. Omid R, Stone MA, Zalavras CG, Marecek GS. Gunshot Wounds to the Upper Extremity. *J Am Acad Orthop Surg.* 2019;27(7):e301–e310. doi:10.5435/jaaos-d-17-00676
14. Bartlett CS. Clinical update: gunshot wound ballistics. *Clin Orthop Relat Res.* 2003;408:28–57. doi:10.1097/00003086-200303000-00005
15. Rhee PM, Moore EE, Joseph B, Tang A, Pandit V, Vercruyse G. Gunshot wounds: a review of ballistics, bullets, weapons, and myths. *J Trauma Acute Care Surg.* 2016;80(6):853–867. doi:10.1097/ta.0000000000001037
16. Yoganandan N, Pintar FA, Kumaresan S, Maiman DJ, Hargarten SW. Dynamic analysis of penetrating trauma. *J Trauma.* 1997;42(2):266–272. doi:10.1097/00005373-199702000-00014
17. Bartlett CS, Helfet DL, Hausman MR, Strauss E. Ballistics and gunshot wounds: effects on musculoskeletal tissues. *J Am Acad Orthop Surg.* 2000;8(1):21–36. doi:10.5435/00124635-200001000-00003
18. Stefanopoulos PK, Pinielis DE, Hadjigeorgiou GF, Filippakis KN. Wound ballistics 101: the mechanisms of soft tissue wounding by bullets. *Eur J Trauma Emerg Surg.* 2017;43(5):579–586. doi:10.1007/s00068-015-0581-1
19. Fackler ML. Wound ballistics: a review of common misconceptions. *JAMA.* 1988;259(18):2730–2736. doi:10.1001/jama.1988.03720180056033
20. Bruner D, Gustafson CG, Visintainer C. Ballistic injuries in the emergency department. *Emerg Med Pract Dec.* 2011;13(12):1–30.
21. Dougherty PJ, Eidt HC. Wound ballistics: minié ball vs. full metal jacketed bullets—a comparison of Civil War and Spanish-American War firearms. *Mil Med.* 2009;174(4):403–407. doi:10.7205/milmed-d-02-2307
22. Ordog GJ, Wasserberger J, Balasubramaniam S. Shotgun wound ballistics. *J Trauma.* 1988;28(5):624–631. doi:10.1097/00005373-198805000-00011
23. Volgas DA, Stannard JP, Alonso JE. Ballistics: a primer for the surgeon. *Injury.* 2005;36(3):373–379. doi:10.1016/j.injury.2004.08.037
24. Maiden N. Historical overview of wound ballistics research. *Forensic Sci Med Pathol.* 2009;5(2):85–89. doi:10.1007/s12024-009-9090-z
25. von See C, Bormann K-H, Schumann P, Goetz F, Gellrich N-C, Rucker M. Forensic imaging of projectiles using cone-beam computed tomography. *Forensic Sci Int.* 2009;190(1):38–41. doi:10.1016/j.forsciint.2009.05.009
26. Ragsdale BD. Gunshot wounds: a historical perspective. *Mil Med.* 1984;149(6):301–315. doi:10.1093/milmed/149.6.301
27. Gestring ML, Geller ER, Akkad N, Bongiovanni PJ. Shotgun slug injuries: case report and literature review. *J Trauma.* 1996;40(4):650–653. doi:10.1097/00005373-199604000-00025
28. Komenda J, Hejna P, Rydlo M, et al. Forensic and clinical issues in the use of frangible projectile. *J Forensic Leg Med.* 2013;20(6):697–702. doi:10.1016/j.jflm.2013.04.006
29. Miller CR, Haag M, Gerrard C, et al. Comparative evaluation of potentially radiolucent projectile components by radiographs and computed tomography. *J Forensic Sci.* 2016;61(6):1563–1570. doi:10.1111/1556-4029.13225
30. Kieser DC, Carr DJ, Leclair SC, et al. Remote ballistic fractures in a gelatine model - aetiology and surgical implications. *J Orthop Surg Res.* 2013;8(1):15. doi:10.1186/1749-799x-8-15
31. Bresson F, Ducouret J, Peyré J, et al. Experimental study of the expansion dynamic of 9 mm Parabellum hollow point projectiles in ballistic gelatin. *Forensic Sci Int.* 2012;219(1–3):113–118. doi:10.1016/j.forsciint.2011.12.007
32. Nag NK, Sinha P. An investigation into pellet dispersion ballistics. *Forensic Sci Int.* 1992;55(2):105–130. doi:10.1016/0379-0738(92)90118-G
33. Dixon DS. Exit keyhole lesion and direction of fire in a gunshot wound of the skull. *J Forensic Sci.* 1984;29(1):336–339. doi:10.1520/JFS11670J
34. Dixon DS. Determination of direction of fire from graze gunshot wounds of internal organs. *J Forensic Sci.* 1984;29(1):331–335. doi:10.1520/JFS11669J
35. Yong YE. A systematic review on ricochet gunshot injuries. *Leg Med.* 2017;26:45–51. doi:10.1016/j.legalmed.2017.03.003
36. Hollerman JJ, Fackler ML, Coldwell DM, Ben-Menachem Y. Gunshot wounds: I. Bullets, ballistics, and mechanisms of injury. *AJR Am J Roentgenol.* 1990;155(4):685–690. doi:10.2214/ajr.155.4.2119095
37. Jandial R, Reichwage B, Levy M, Duenas V, Sturdivan L. Ballistics for the Neurosurgeon. *Neurosurgery.* 2008;62(2):472–480. doi:10.1227/01.neu.0000316015.05550.7a
38. Rhee JM, Martin R. The management of retained bullets in the limbs. *Injury.* 1997;28:C23–C28. doi:10.1016/s0020-1383(97)90090-5
39. Cooper GJ, Ryan JM. Interaction of penetrating missiles with tissues: some common misapprehensions and implications for wound management. *Br J Surg.* 1990;77(6):606–610. doi:10.1002/bjs.1800770604
40. Moriscot A, Miyabara EH, Langeani B, Belli A, Egginton S, Bowen TS. Firearms-related skeletal muscle trauma: pathophysiology and novel approaches for regeneration. *NPJ Regen Med.* 2021;6(1):17. doi:10.1038/s41536-021-00127-1
41. Wang ZG, Feng JX, Liu YQ. Pathomorphological observations of gunshot wounds. *Acta Chir Scand Suppl.* 1982;508:185–195.
42. Pircher R, Preiß D, Pollak S, Thierauf-Emberger A, Perdekamp MG, Geisenberger D. The influence of the bullet shape on the width of abrasion collars and the size of gunshot entrance holes. *Int J Legal Med.* 2017;131(2):441–445. doi:10.1007/s00414-016-1501-6
43. Cail K, Klatt E. The effect of intermediate clothing targets on shotgun ballistics. *Am J Forensic Med Pathol.* 2013;34(4):348–351. doi:10.1097/paf.0000000000000051
44. Stahl C, Johnson F, Luke J. *The Effect of Glass as an Intermediate Target on Bullets: Experimental Studies and Report of a Case.* ASTM International; 1979.
45. Santucci RA, Chang Y-J. Ballistics for physicians: myths about wound ballistics and gunshot injuries. *J Urol.* 2004;171(4):1408–1414. doi:10.1097/01.ju.0000103691.68995.04
46. Jabara JT, Gannon NP, Vallier HA, Nguyen MP. Management of civilian low-velocity gunshot injuries to an extremity. *J Bone Joint Surg Am.* 2021;103(11):1026–1037. doi:10.2106/jbjs.20.01544
47. Berryman HE. A systematic approach to the interpretation of gunshot wound trauma to the cranium. *Forensic Sci Int.* 2019;301:306–317. doi:10.1016/j.forsciint.2019.05.019
48. Breeze J, Sedman AJ, James GR, Newbery TW, Hepper AE. Determining the wounding effects of ballistic projectiles to inform future injury models: a systematic review. *J R Army Med Corps.* 2014;160(4):273–278. doi:10.1136/jramc-2013-000099
49. Amato JJ, Syracuse D, Seaver PR Jr., Rich N. Bone as a secondary missile: an experimental study in the fragmenting of bone by high-velocity missiles. *J Trauma.* 1989;29(5):609–612. doi:10.1097/00005373-198905000-00013

50. Amato JJ, Billy LJ, Lawson NS, Rich NM. High velocity missile injury: an experimental study of the retentive forces of tissue. *Am J Surg.* 1974;127(4):454–459. doi:10.1016/0002-9610(74)90296-7
51. Rose SC, Fujisaki CK, Moore EE. Incomplete fractures associated with penetrating trauma: etiology, appearance, and natural history. *J Trauma.* 1988;28(1):106–109. doi:10.1097/00005373-198801000-00016
52. Meade A, Hembd A, Cho MJ, Zhang AY. Surgical treatment of upper extremity gunshot injuries: an updated review. *Ann Plast Surg.* 2021;86(3S Suppl 2):S312–s318. doi:10.1097/sap.0000000000002634
53. Fackler M. Wound ballistics and soft-tissue wound treatment. *Tech Orthop.* 1995;10(3):163–170. doi:10.1097/00013611-199501030-00005
54. Fackler ML. Civilian gunshot wounds and ballistics: dispelling the myths. *Emerg Med Clin North Am.* 1998;16(1):17–28. doi:10.1016/S0733-8627(05)70346-1
55. Folio L, McHugh C, Hoffman MJ. The even-number guide and imaging ballistic injuries. *Radiol Technol.* 2007;78(3):197–203.
56. Veselko M, Trobec R. Intraoperative localization of retained metallic fragments in missile wounds. *J Trauma Acute Care Surg.* 2000;49(6):1052–1058. doi:10.1097/00005373-200012000-00013
57. Jeffery AJ, Ruddy GN, Robinson C, Morgan B. Computed tomography of projectile injuries. *Clin Radiol.* 2008;63(10):1160–1166. doi:10.1016/j.crad.2008.03.003
58. Hanna TN, Shuaib W, Han T, Mehta A, Khosa F. Firearms, bullets, and wound ballistics: an imaging primer. *Injury.* 2015;46(7):1186–1196. doi:10.1016/j.injury.2015.01.034
59. Long WT, Brien EW, Boucree JB Jr., Filler B, Stark HH, Dorr LD. Management of civilian gunshot injuries to the Hip. *Orthop Clin North Am.* 1995;26(1):123–131. doi:10.1016/S0030-5898(20)31974-X
60. Tornetta P 3rd, Hui RC. Intraarticular findings after gunshot wounds through the knee. *J Orthop Trauma.* 1997;11(6):422–424. doi:10.1097/00005131-199708000-00009
61. Moisi MD, Page J, Gahramanov S, Oskouian RJ. Bullet fragment of the lumbar spine: the decision is more important than the incision. *Global Spine J.* 2015;5(6):523–526. doi:10.1055/s-0035-1566231
62. Meena S, Singla A, Saini P, Mittal S, Chowdhary B. Spontaneous migration of bullet from arm to forearm and its ultrasound guided removal. *J Ultrasound.* 2013;16(4):223–225. doi:10.1007/s40477-013-0041-x
63. Baldawa S, Shivpuje V. Migratory low velocity intradural lumbosacral spinal bullet causing cauda equina syndrome: report of a case and review of literature. *Eur Spine J.* 2017;26(Suppl 1):128–135. doi:10.1007/s00586-016-4913-6
64. De Los Cobos D, Powers A, Behrens JP, Mattei TA, Salari P. Surgical removal of a migrating intraspinal bullet: illustrative case. *J Neurosurg.* 2021;1(22). doi:10.3171/case21132
65. Nguyen MP, Savakus JC, O'Donnell JA, et al. Infection rates and treatment of low-velocity extremity gunshot injuries. *J Orthop Trauma.* 2017;31(6):326–329. doi:10.1097/bot.0000000000000827
66. Ordog GJ, Sheppard GF, Wasserberger JS, Balasubramaniam S, Shoemaker WC. Infection in minor gunshot wounds. *J Trauma.* 1993;34(3):358–365. doi:10.1097/00005373-199303000-00009
67. Tian HM, Deng GG, Huang MJ, Tian FG, Süang GY, Liu YG. Quantitative bacteriological study of the wound track. *J Trauma.* 1988;28(1 Suppl):S215–6. doi:10.1097/00005373-198801001-00045
68. Dickey RL, Barnes BC, Kearns RJ, Tullos HS. Efficacy of antibiotics in low-velocity gunshot fractures. *J Orthop Trauma.* 1989;3(1):6–10. doi:10.1097/00005131-198903010-00002
69. Dougherty PJ, Vaidya R, Silverton CD, Bartlett C, Najibi S. Joint and long-bone gunshot injuries. *JBJS.* 2009;91(4):980–997.
70. Geissler WB, Teasedall RD, Tomasin JD, Hughes JL. Management of low velocity gunshot-induced fractures. *J Orthop Trauma.* 1990;4(1):39–41. doi:10.1097/00005131-199003000-00007
71. Knapp TP, Patzakis MJ, Lee J, Seipel PR, Abdollahi K, Reisch RB. Comparison of intravenous and oral antibiotic therapy in the treatment of fractures caused by low-velocity gunshots. A prospective, randomized study of infection rates. *J Bone Joint Surg Am.* 1996;78(8):1167–1171. doi:10.2106/00004623-199608000-00006
72. Simpson BM, Wilson RH, Grant RE. Antibiotic therapy in gunshot wound injuries. *Clin Orthop Relat Res.* 2003;408:82–85. doi:10.1097/00003086-200303000-00008
73. Nguyen MP, Reich MS, O'Donnell JA, et al. Infection and complications after low-velocity intra-articular gunshot injuries. *J Orthop Trauma.* 2017;31(6):330–333. doi:10.1097/bot.0000000000000823
74. Watters J, Anglen JO, Mullis BH. The role of débridement in low-velocity civilian gunshot injuries resulting in pelvis fractures: a retrospective review of acute infection and inpatient mortality. *J Orthop Trauma.* 2011;25(3):150–155. doi:10.1097/BOT.0b013e3181ea5cb9
75. Velmahos G, Demetriades D. Gunshot wounds of the spine: should retained bullets be removed to prevent infection? *Ann R Coll Surg Engl.* 1994;76(2):85–87.
76. Atesalp AS, Yildiz C, Başbozkurt M, Gür E. Treatment of type IIIa open fractures with Ilizarov fixation and delayed primary closure in high-velocity gunshot wounds. *Mil Med.* 2002;167(1):56–62. doi:10.1093/milmed/167.1.56
77. Marecek GS, Earhart JS, Gardner MJ, Davis J, Merk BR. Surgeon preferences regarding antibiotic prophylaxis for ballistic fractures. *Arch Orthop Trauma Surg.* 2016;136(6):751–754. doi:10.1007/s00402-016-2450-8
78. Ganocy K 2nd, Lindsey RW. The management of civilian intra-articular gunshot wounds: treatment considerations and proposal of a classification system. *Injury.* 1998;29(Suppl 1):Sa1–6. doi:10.1016/S0020-1383(98)00097-7
79. Nguyen MP, Como JJ, Golob JF Jr., Reich MS, Vallier HA. Variation in treatment of low energy gunshot injuries – a survey of OTA members. *Injury.* 2018;49(3):570–574. doi:10.1016/j.injury.2018.01.027
80. Bowyer GW, Rossiter ND. Management of gunshot wounds of the limbs. *J Bone Joint Surg Br.* 1997;79-B(6):1031–1036. doi:10.1302/0301-620x.79b6.0791031
81. Brien WW, Kuschner SH, Brien EW, Wiss DA. The management of gunshot wounds to the femur. *Orthop Clin North Am.* 1995;26(1):133–138. doi:10.1016/S0030-5898(20)31975-1
82. Riddez L. Wounds of war in the civilian sector: principles of treatment and pitfalls to avoid. *Eur J Trauma Emerg Surg.* 2014;40(4):461–468. doi:10.1007/s00068-014-0395-6
83. Ordog GJ, Wasserberger J, Balasubramaniam S, Shoemaker W. Civilian gunshot wounds—outpatient management. *J Trauma.* 1994;36(1):106–111. doi:10.1097/00005373-199401000-00017

84. Maqungo S, Swan A, Naude P, et al. The management of low velocity transarticular gunshot injuries: a pilot study. *SA Orthop J*. 2018;17(3):25–27. doi:10.17159/2309-8309/2018/v17n2a4
85. Marcus NA, Blair WF, Shuck JM, Omer GEJ. Low-velocity Gunshot Wounds to Extremities. *J Trauma Acute Care Surg*. 1980;20(12):1061–1064. doi:10.1097/00005373-198012000-00010
86. Hollmann MW, Horowitz M. Femoral fractures secondary to low velocity missiles: treatment with delayed intramedullary fixation. *J Orthop Trauma*. 1990;4(1):64–69. doi:10.1097/00005131-199003000-00011
87. Hansraj KK, Weaver LD, Todd AO, et al. Efficacy of ceftriaxone versus cefazolin in the prophylactic management of extra-articular cortical violation of bone due to low-velocity gunshot wounds. *Orthop Clin North Am*. 1995;26(1):9–17. doi:10.1016/S0030-5898(20)31963-5
88. Hull JB. Management of gunshot fractures of the extremities. *J Trauma Acute Care Surg*. 1996;40(3S):193S–197S. doi:10.1097/00005373-199603001-00043
89. Barr RJ, Mollan RA. The orthopaedic consequences of civil disturbance in Northern Ireland. *J Bone Joint Surg Br*. 1989;71(5):739–744. doi:10.1302/0301-620x.71b5.2584241
90. Volgas DA, Stannard JP, Alonso JE. Current orthopaedic treatment of ballistic injuries. *Injury*. 2005;36(3):380–386. doi:10.1016/j.injury.2004.08.038
91. Shultz CL, Schrader SN, Garbrecht EL, DeCoster TA, Veitch AJ. Operative versus nonoperative management of traumatic arthrotomies from civilian gunshot wounds. *Iowa Orthop J*. 2019;39(1):173–177.
92. Brunner RG, Fallon WF Jr. A prospective, randomized clinical trial of wound debridement versus conservative wound care in soft-tissue injury from civilian gunshot wounds. *Am Surg*. 1990;56(2):104–107.
93. Patzakis MJ, Harvey JP Jr, Ivler D. The role of antibiotics in the management of open fractures. *J Bone Joint Surg Am*. 1974;56(3):532–541. doi:10.2106/00004623-197456030-00010
94. Woloszyn JT, Uitvlugt GM, Castle ME. Management of civilian gunshot fractures of the extremities. *Clin Orthop Relat Res*. 1988;226:247–251. doi:10.1097/00003086-198801000-00033
95. Turker T, Capdarest-Arest N. Management of gunshot wounds to the hand: a literature review. *J Hand Surg Am*. 2013;38(8):1641–1650. doi:10.1016/j.jhssa.2013.02.011
96. Dienstknecht T, Horst K, Sellei RM, Berner A, Nerlich M, Hardcastle TC. Indications for bullet removal: overview of the literature, and clinical practice guidelines for European trauma surgeons. *Eur J Trauma Emerg Surg*. 2012;38(2):89–93. doi:10.1007/s00068-011-0170-x
97. Burg A, Nachum G, Salai M, et al. Treating civilian gunshot wounds to the extremities in a level 1 trauma center: our experience and recommendations. *Isr Med Assoc J*. 2009;11(9):546–551.
98. Manna B, Nahiriak P, Morrison CA. Wound Debridement. *StatPearls Publishing*. 2021. Available from: <https://www.ncbi.nlm.nih.gov/books/NBK507882/>. Accessed March 20, 2022.
99. Escamilla JAC, Ross JÁG, Atanasio JMP, Martínez GC, Cisneros AG, Avila JJ. Spinal gunshot wounds: pattern and associated lesions in civilians. *Asian Spine J*. 2018;12(4):648–655. doi:10.31616/asj.2018.12.4.648
100. Fackler M. Gunshot wound review. *Ann Emerg Med*. 1996;28(2):194–203. doi:10.1016/s0196-0644(96)70062-8
101. Hikes DC, Manoli A 2nd. Wound botulism. *J Trauma*. 1981;21(1):68–71. doi:10.1097/00005373-198101000-00016
102. Janson B, Seeman T. Muscle devitalization in high-energy missile wounds, and its dependence on energy transfer. *J Trauma*. 1985;25(2):138–144. doi:10.1097/00005373-198502000-00009
103. Deitch EA, Grimes WR. Experience with 112 shotgun wounds of the extremities. *J Trauma*. 1984;24(7):600–603. doi:10.1097/00005373-198407000-00009
104. Leininger BE, Rasmussen TE, Smith DL, Jenkins DH, Coppola C. Experience with wound VAC and delayed primary closure of contaminated soft tissue injuries in Iraq. *J Trauma*. 2006;61(5):1207–1211. doi:10.1097/01.ta.0000241150.15342.da
105. Murray CK, Hsu JR, Solomkin JS, et al. Prevention and management of infections associated with combat-related extremity injuries. *J Trauma Acute Care Surg*. 2008;64(3):S239–S251. doi:10.1097/TA.0b013e318163cd14
106. Buescher TM, Cioffi WG Jr, Johnson AJ, et al. *Textbook of Military Medicine: Series on Combat Casualty Care*. Washington: Office of the Surgeon General at TMM Publications; Vol. 5, 1998
107. Penn-Barwell JG, Brown KV, Fries CA. High velocity gunshot injuries to the extremities: management on and off the battlefield. *Curr Rev Musculoskelet Med*. 2015;8(3):312–317. doi:10.1007/s12178-015-9289-4
108. Hoekstra SM, Bender JS, Levison MA. The management of large soft-tissue defects following close-range shotgun injury. *J Trauma*. 1990;30(12):1489–1493. doi:10.1097/00005373-199012000-00008
109. Nichols JS, Lillehei KO. Nerve injury associated with acute vascular trauma. *Surg Clinics North Am*. 1988;68(4):837–852. doi:10.1016/S0039-6109(16)44589-5
110. Kobbe P, Frink M, Oberbeck R, et al. [Treatment strategies for gunshot wounds of the extremities] Versorgungsstrategien bei Schussverletzungen der Extremität. *Unfallchirurg*. 2008;111(4):247–54; quiz 255. doi:10.1007/s00113-008-1436-6
111. Molinari RW, Yang EC, Strauss E, Einhorn TA. Timing of internal fixation in low-velocity extremity gunshot fractures. *Contemp Orthop*. 1994;29(5):335–339.
112. Nowotarski P, Brumback RJ. Immediate interlocking nailing of fractures of the femur caused by low- to mid-velocity gunshots. *J Orthop Trauma*. 1994;8(2):134–141. doi:10.1097/00005131-199404000-00010
113. Wright DG, Levin JS, Esterhai JL, Heppenstall RB. Immediate internal fixation of low-velocity gunshot-related femoral fractures. *J Trauma*. 1993;35(5):678–81; discussion 681–2. doi:10.1097/00005373-199311000-00004
114. Gustilo RB, Anderson JT. Prevention of infection in the treatment of one thousand and twenty-five open fractures of long bones: retrospective and prospective analyses. *J Bone Joint Surg Am*. 1976;58(4):453–458. doi:10.2106/00004623-197658040-00004
115. Long WT, Chang W, Brien EW. Grading system for gunshot injuries to the femoral diaphysis in civilians. *Clin Orthop Relat Res*. 2003;408:92–100. doi:10.1097/00003086-200303000-00010
116. Kline DG. Timing for exploration of nerve lesions and evaluation of the neuroma-in-continuity. *Clin Orthop Relat Res*. 1982;163:42–49. doi:10.1097/00003086-198203000-00007
117. Kline DG, Hackett ER, Happel LH. Surgery for lesions of the brachial plexus. *Arch Neurol*. 1986;43(2):170–181. doi:10.1001/archneur.1986.00520020058023

118. Magalon G, Bordeaux J, Legre R, Aubert JP. Emergency versus delayed repair of severe brachial plexus injuries. *Clin Orthop Relat Res*. 1988;237:32–35. doi:10.1097/00003086-198812000-00006
119. MacKay BJ, Cox CT, Valerio IL, et al. Evidence-based approach to timing of nerve surgery: a review. *Ann Plast Surg*. 2021;87(3):e1–e21. doi:10.1097/sap.0000000000002767
120. Gonzalez RP, Scott W, Wright A, Phelan HA, Rodning CB. Anatomic location of penetrating lower-extremity trauma predicts compartment syndrome development. *Am J Surg*. 2009;197(3):371–375. doi:10.1016/j.amjsurg.2008.11.013
121. Nee N, Inaba K, Schellenberg M, et al. Retained bullet fragments after nonfatal gunshot wounds: epidemiology and outcomes. *J Trauma Acute Care Surg*. 2021;90(6):973–979. doi:10.1097/ta.0000000000003089
122. Andrade EG, Uberoi M, Hayes JM, Thornton M, Kramer J, Punch LJ. The impact of retained bullet fragments on outcomes in patients with gunshot wounds. *Am J Surg*. 2021. doi:10.1016/j.amjsurg.2021.05.022
123. Chapman AJ, McClain J. Wandering missiles: autopsy study. *J Trauma*. 1984;24(7):634–637. doi:10.1097/00005373-198407000-00017
124. Shannon JJ Jr., Vo NM, Stanton PE Jr., Dimler M. Peripheral arterial missile embolization: a case report and 22-year literature review. *J Vasc Surg*. 1987;5(5):773–778. doi:10.1016/0741-5214(87)90169-8
125. Linden MA, Manton WI, Stewart RM, Thal ER, Feit H. Lead poisoning from retained bullets. Pathogenesis, diagnosis, and management. *Ann Surg*. 1982;195(3):305–313. doi:10.1097/0000658-198203000-00010
126. Howse EA, Rogers JP, Stone AV, Mannava S, Stubbs AJ. Arthroscopic bullet removal from the central and peripheral compartments of the hip joint. *Arthrosc Tech*. 2016;5(2):e217–21. doi:10.1016/j.eats.2015.11.001
127. Gurpinar T, Ozturkmen Y. Arthroscopic removal of an intraarticular bullet from the Hip joint: a case report. *J Pak Med Assoc*. 2018;68(9):1394–1396.
128. Cantrell C, Gerlach E, Butler B, Sheth U, Tjong V. The role of arthroscopy in bullet removal: a systematic review of the literature. *J Orthop*. 2020;22:442–448. doi:10.1016/j.jor.2020.09.019
129. Berg EE, Ciullo JV. Arthroscopic debridement after intraarticular low-velocity gunshot wounds. *Arthroscopy*. 1993;9(5):576–579. doi:10.1016/s0749-8063(05)80408-6
130. Hartford JM, Gorczyca JT. Late arthroscopic debridement of metal fragments and synovectomy after penetrating knee joint injury by low-velocity missile: a report of two cases. *J Orthop Trauma*. 2001;15(3):222–224. doi:10.1097/00005131-200103000-00013
131. Mahirogullari M, Cilli F, Akmaz I, Pehlivan O, Kiral A. Acute arthroscopic removal of a bullet from the shoulder. *Arthroscopy*. 2007;23(6):676.e1–3. doi:10.1016/j.arthro.2006.01.022
132. Mineo RC, Gittins ME. Arthroscopic removal of a bullet embedded in the acetabulum. *Arthroscopy*. 2003;19(9):E121–24. doi:10.1016/j.arthro.2003.09.014
133. Oladipo JO, Creevy W, Remis R. Arthroscopic management of intra-articular low-velocity gunshot wounds of the knee. *Am J Knee Surg*. 1999;12(4):229–232.
134. Otero F, Cuartas E. Arthroscopic removal of bullet fragments from the subacromial space of the shoulder. *Arthroscopy*. 2004;20(7):754–756. doi:10.1016/j.arthro.2004.04.055
135. Parisien JS, Esformes I. The role of arthroscopy in the management of low-velocity gunshot wounds of the knee joint. *Clin Orthop Relat Res*. 1984;185:207–213.
136. Tarkin IS, Hatzidakis A, Hoxie SC, Giangara CE, Knight RQ. Arthroscopic treatment of gunshot wounds to the shoulder. *Arthroscopy*. 2003;19(1):85–89. doi:10.1053/jars.2003.50024
137. Teloken MA, Schmiedt I, Tomlinson DP. Hip arthroscopy: a unique inferomedial approach to bullet removal. *Arthroscopy*. 2002;18(4):E21. doi:10.1053/jars.2002.32232
138. Galland A, Lunebourg A, Airaudi S, Gravier R. A bullet in the supraspinatus compartment successfully removed by arthroscopy: case report and review of the literature. *Case Rep Orthop*. 2015;2015:806735. doi:10.1155/2015/806735
139. Guevara J, Chinnakkannu K, Raju S. Acute arthroscopic removal of a bullet embedded in the glenoid: a case report. *J Orthop Case Rep*. 2021;11(3):59–62. doi:10.13107/jocr.2021.v11.i03.2088
140. Ejnisman B, Andreoli CV, Carvalho CD, Pochini Ade C. Image-guided scapulothoracic arthroscopy for removing firearm projectiles. *BMJ Case Rep*. 2014;2014:bcr2013203146–bcr2013203146. doi:10.1136/bcr-2013-203146
141. Jamdar S, Helm AT, Redfern DR. Arthroscopic removal of a shotgun pellet from the elbow joint. *Arthroscopy*. 2001;17(7):E30. doi:10.1053/jars.2001.24692
142. Wilson RH. Gunshots to the hand and upper extremity. *Clin Orthop Relat Res*. 2003;408:133–144. doi:10.1097/00003086-200303000-00016
143. Anantavorasakul N, Westenberg RF, Serebrakian AT, Zamri M, Chen NC, Eberlin KR. Gunshot injuries of the hand: incidence, treatment characteristics, and factors associated with healthcare utilization. *Hand*. 2021;1558944721998016. doi:10.1177/1558944721998016
144. Bartkiw MJ, Sethi A, Coniglione F, et al. Civilian gunshot wounds of the hip and pelvis. *J Orthop Trauma*. 2010;24(10):645–652. doi:10.1097/BOT.0b013e3181cf03ea
145. Cory JW, Ruch DS. Arthroscopic removal of a .44 caliber bullet from the Hip. *Arthroscopy*. 1998;14(6):624–626. doi:10.1016/s0749-8063(98)70061-1
146. Zura RD, Bosse MJ. Current treatment of gunshot wounds to the Hip and pelvis. *Clin Orthop Relat Res*. 2003;408:110–114. doi:10.1097/00003086-200303000-00012
147. Rehman MA, Umer M, Sepah YJ, Wajid MA. Bullet-induced synovitis as a cause of secondary osteoarthritis of the Hip joint: a case report and review of literature. *J Med Case Rep*. 2007;1(1):171. doi:10.1186/1752-1947-1-171
148. McAninch SA, Adkison J, Meyers R, Benham M. Bullet fragment-induced lead arthropathy with subsequent fracture and elevated blood lead levels. *Proc (Bayl Univ Med Cent)*. 2017;30(1):88–91. doi:10.1080/08998280.2017.11929543
149. Basnayake O, Nihaj A, Pitagampalage R, Jayarajah U, Mathangasinghe Y, Mendis H. Retained shrapnel from a blast injury as a rare cause of secondary osteoarthritis of the hip joint: a case report and review of literature. *Case Rep Surg*. 2019;2019:7190781. doi:10.1155/2019/7190781
150. Riehl JT, Sassoon A, Connolly K, Haidukewych GJ, Koval KJ. Retained bullet removal in civilian pelvis and extremity gunshot injuries: a systematic review. *Clin Orthop Relat Res*. 2013;471(12):3956–3960. doi:10.1007/s11999-013-3260-8
151. Miller AN, Carroll EA, Pilson HT. Transabdominal gunshot wounds of the Hip and pelvis. *J Am Acad Orthop Surg*. 2013;21(5):286–292. doi:10.5435/jaas-21-05-286

152. Delaney R, Albright M, Rebello G. Utilization of the safe surgical dislocation approach of the hip to retrieve a bullet from the femoral head. *Case Rep Orthop*. 2011;2011:1–3. doi:10.1155/2011/160591
153. Meyer NJ, Thiel B, Ninomiya JT. Retrieval of an intact, intraarticular bullet by hip arthroscopy using the lateral approach. *J Orthop Trauma*. 2002;16(1):51–53. doi:10.1097/00005131-200201000-00012
154. Ferro FP, Bessa FS, Ejnisman L, Gurgel HM, Croci AT, Vicente JR. Arthroscopic bullet removal from the Hip joint and concurrent treatment of associated full-thickness chondral defects: a case report. *SAGE Open Med Case Rep*. 2019;7:2050313X1982967. doi:10.1177/2050313X19829670
155. Maqungo S, Hoppe S, Kauta JN, et al. Surgical Hip dislocation for removal of retained intra-articular bullets. *Injury*. 2016;47(10):2218–2222. doi:10.1016/j.injury.2016.06.020
156. Sozen YV, Polat G, Kadioglu B, Dikici F, Ozkan K, Unay K. Arthroscopic bullet extraction from the Hip in the lateral decubitus position. *Hip Int*. 2010;20(2):265–268. doi:10.1177/112070001002000221
157. Williams MS, Hutcheson RL, Miller AR. A new technique for removal of intraarticular bullet fragments from the femoral head. *Bull Hosp Jt Dis*. 1997;56(2):107–110.
158. Tishovsky I, Katz SD, Pincay JJ, et al. Management of gunshot wound-related Hip injuries: a systematic review of the current literature. *J Orthop*. 2021;23:100–106. doi:10.1016/j.jor.2020.12.029
159. Borra V, Serra MJ, Rubel IF. Trans-iliac removal of bullet fragments from the sacroiliac joint. *J Orthop Trauma*. 2006;20(1):52–55. doi:10.1097/01.bot.0000177103.99488.fe
160. Özden R, Davut S, Dođramacı Y, Kalacı A, Duman İG, Uruç V. Treatment of secondary Hip arthritis from shell fragment and gunshot injury in the Syrian civil war. *J Orthop Surg Res*. 2020;15(1). doi:10.1186/s13018-020-01993-z
161. Gupta RK, Aggarwal V. Late arthroscopic retrieval of a bullet from Hip joint. *Indian J Orthop*. 2009;43(4):416–419. doi:10.4103/0019-5413.54764
162. Fournier MN, Rider CM, Olinger CR, Dabov GD, Mihalko WM, Mihalko MJ. Arthroscopic treatment of a low-velocity gunshot injury to a primary total hip arthroplasty: a case report. *JBJS Case Connect*. 2019;9(1):e18. doi:10.2106/jbjs.Cc.18.00204
163. Al-Asiri J, Wong I. Arthroscopic bullet removal from the acetabulum (Hip joint). *J Surg Tech Case Rep*. 2012;4(2):121–125. doi:10.4103/2006-8808.110260
164. Singleton SB, Joshi A, Schwartz MA, Collinge CA. Arthroscopic bullet removal from the acetabulum. *Arthroscopy*. 2005;21(3):360–364. doi:10.1016/j.arthro.2004.10.005
165. Goldman A, Minkoff J, Price A, Krinick R. A posterior arthroscopic approach to bullet extraction from the Hip. *J Trauma*. 1987;27(11):1294–1300. doi:10.1097/00005373-198711000-00016
166. Kaya I, Ugras A, Saglam N, Sungur I, Cetinus E. Bullet in Hip joint. *Eurasian J Med*. 2013;45(2):141–142. doi:10.5152/eajm.2013.29
167. Çatma MF, Ünü S, Ersan Ö, Öztürk A. Treatment of the bullet, traversing femoral neck, lodged in hip joint: initial arthroscopic removal and subsequent cartilage repair. *J Orthop Case Rep*. 2016;6(4):13–16. doi:10.13107/jocr.2250-0685.548
168. Najibi S, Dougherty PJ, Morandi MM. Management of gunshot wounds to the joints. *Tech Orthop*. 2006;21(3):200–204. doi:10.1097/01.bto.0000240270.38353.85
169. Petersen W, Beske C, Stein V, Laprell H. Arthroscopical removal of a projectile from the intra-articular cavity of the knee joint. *Arch Orthop Trauma Surg*. 2002;122(4):235–236. doi:10.1007/s00402-001-0373-4
170. Tornetta PI, Hui RC. Intraarticular findings after gunshot wounds through the knee. *J Orthop Trauma*. 1997;11(6):422–424. doi:10.1097/00005131-199708000-00009
171. Lacy K, Cooke C, Cooke P, Tonnos F. Arthroscopic removal of shotgun pellet from within the medial meniscus. *Arthrosc Tech*. 2016;5(1):e27–32. doi:10.1016/j.eats.2015.09.004
172. Lee GH, Virkus WW, Kapotas JS. Arthroscopically assisted minimally invasive intraarticular bullet extraction: technique, indications, and results. *J Trauma*. 2008;64(2):512–516. doi:10.1097/TA.0b013e31814699ee
173. Latosiewicz R, Murawski J, Skowroński J. Bilateral knee gunshot wounds successfully treated with arthroscopic bullet retrieval: a case report. *Arthroscopy*. 1995;11(1):104–105. doi:10.1016/0749-8063(95)90096-9
174. Cho MS, Warne WJ. Arthroscopic treatment of a transarticular low-velocity gunshot wound using tractsoscopy. *Arthroscopy*. 2002;18(5):532–537. doi:10.1053/jars.2002.31963
175. Keskinbora M, Yağın S, Oltulu İ, Erdil ME, Örmeci T. Compartment syndrome following arthroscopic removal of a bullet in the knee joint after a low-velocity gunshot injury. *Clin Orthop Surg*. 2016;8(1):115–118. doi:10.4055/cios.2016.8.1.115
176. Jazrawi L, Egol KA, Astion DJ, Rose DJ. Arthroscopic removal of bullet fragments from the subtalar joint. *Arthroscopy*. 1999;15(7):762–765. doi:10.1016/s0749-8063(99)70009-5
177. Jelen BA, Scheid DK, Fleuriau-Chateau P. Extraction of an intra-articular bullet fragment from the subtalar joint: the “drill, tap, and extract” method. *Am J Orthop (Belle Mead NJ)*. 2002;31(1):48–51.
178. Ramji Z, Laflamme M. Ankle lead arthropathy and systemic lead toxicity secondary to a gunshot wound after 49 years: a case report. *J Foot Ankle Surg*. 2017;56(3):648–652. doi:10.1053/j.jfas.2016.12.005
179. Chen Y, Tang Y, Vogel L, Devivo M. Causes of spinal cord injury. *Top Spinal Cord Inj Rehabil*. 2013;19(1):1–8. doi:10.1310/sci1901-1
180. Jakoi A, Iorio J, Howell R, Zampini JM. Gunshot injuries of the spine. *Spine J*. 2015;15(9):2077–2085. doi:10.1016/j.spinee.2015.06.007
181. Scuderi GJ, Vaccaro AR, Fitzhenry LN, Greenberg S, Eismont F. Long-term clinical manifestations of retained bullet fragments within the intervertebral disk space. *Clin Spine Surg*. 2004;17(2):108–111.
182. Towner JE, Pieters TA, Maurer PK. Lead toxicity from intradiscal retained bullet fragment: management considerations and recommendations. *World Neurosurg*. 2020;141:377–382. doi:10.1016/j.wneu.2020.05.112
183. Moon E, Kondrashov D, Hannibal M, Hsu K, Zucherman J. Gunshot wounds to the spine: literature review and report on a migratory intrathecal bullet. *Am J Orthop (Belle Mead NJ)*. 2008;37(3):E47–51.
184. Beaty N, Slavin J, Diaz C, Zeleznick K, Ibrahim D, Sansur CA. Cervical spine injury from gunshot wounds. *J Neurosurg Spine*. 2014;21(3):442–449. doi:10.3171/2014.5.spine13522
185. Bono CM, Heary RF. Gunshot wounds to the spine. *Spine J*. 2004;4(2):230–240. doi:10.1016/S1529-9430(03)00178-5
186. Waters RL, Sie IH. Spinal cord injuries from gunshot wounds to the spine. *Clin Orthop Relat Res*. 2003;408:120–125. doi:10.1097/00003086-200303000-00014

187. Kitchel SH. Current treatment of gunshot wounds to the spine. *Clin Orthop Relat Res.* 2003;408:115–119. doi:10.1097/00003086-200303000-00013
188. Louwes TM, Ward WH, Lee KH, Freedman BA. Combat-related intradural gunshot wound to the thoracic spine: significant improvement and neurologic recovery following bullet removal. *Asian Spine J.* 2015;9(1):127. doi:10.4184/asj.2015.9.1.127
189. Benton JA, Rahme R, Krystal J, Holland R, Houten JK, Kinon MD. Retained bullet in the cervical spinal canal and the associated surgical management conundrum: case report and review of the literature. *Spinal Cord Series Cases.* 2020;6(1). doi:10.1038/s41394-020-00326-w
190. Kupcha PC, An HS, Cotler JM. Gunshot wounds to the cervical spine. *Spine.* 1990;15(10):1058–1063. doi:10.1097/00007632-199015100-00014
191. le Roux JC, Dunn RN. Gunshot injuries of the spine—a review of 49 cases managed at the groote schuur acute spinal cord injury unit. *S Afr J Surg.* 2005;43(4):165–168.
192. Waters RL, Adkins RH. The effects of removal of bullet fragments retained in the spinal canal. A collaborative study by the National Spinal Cord Injury Model Systems. *Spine.* 1991;16(8):934–939. doi:10.1097/00007632-199108000-00012
193. Dillman RO, Crumb CK, Lidsky MJ. Lead poisoning from a gunshot wound. Report of a case and review of the literature. *Am J Med.* 1979;66(3):509–514. doi:10.1016/0002-9343(79)91083-0
194. Mazotas IG, Hamilton NA, McCubbins MA, Keller MS. The long-term outcome of retained foreign bodies in pediatric gunshot wounds. *J Trauma Nursing.* 2012;19(4):240–245. doi:10.1097/JTN.0b013e31827757a7
195. Araújo GCSD, Mourão NT, Pinheiro IN, Xavier AR, Gameiro VS, Carpenter DO. Lead toxicity risks in gunshot victims. *PLoS One.* 2015;10(10):e0140220. doi:10.1371/journal.pone.0140220
196. Weiss D, Lee D, Feldman R, Smith KE. Severe lead toxicity attributed to bullet fragments retained in soft tissue. *BMJ Case Rep.* 2017; bcr2016217351. doi:10.1136/bcr-2016-217351
197. Bustamante ND, Macias-Konstantopoulos WL. Retained lumbar bullet: a case report of chronic lead toxicity and review of the literature. *J Emerg Med.* 2016;51(1):45–49. doi:10.1016/j.jemermed.2016.02.025
198. Yen J-S, Yen T-H. Lead poisoning induced by gunshot injury with retained bullet fragments. *QJM.* 2021. doi:10.1093/qjmed/hcab144
199. Nickel WN, Steelman TJ, Sabath ZR, Potter BK. Extra-articular retained missiles; is surveillance of lead levels needed? *Mil Med.* 2018;183(3–4):e107–e113. doi:10.1093/milmed/usx076
200. McQuirter JL. Change in blood lead concentration up to 1 year after a gunshot wound with a retained bullet. *Am J Epidemiol.* 2004;159(7):683–692. doi:10.1093/aje/kwh074
201. Marquez JL, Schindlbeck MA. Lead Toxicity from a Retained Bullet. *N Engl J Med.* 2018;379(25):2451. doi:10.1056/nejmicm1804726
202. Beazley WC, Rosenthal RE. Lead intoxication 18 months after a gunshot wound. *Clin Orthop Relat Res.* 1984;190:199–203. doi:10.1097/00003086-198411000-00032
203. Apte A, Bradford K, Dente C, Smith RN. Lead toxicity from retained bullet fragments: a systematic review and meta-analysis. *J Trauma Acute Care Surg.* 2019;87(3):707–716. doi:10.1097/ta.0000000000002287
204. Long B, April MD. Are patients with retained bullet fragments at greater risk for elevated blood lead levels? *Ann Emerg Med.* 2020;75(3):365–367. doi:10.1016/j.annemergmed.2019.10.010
205. Eward WC, Darcey D, Dodd LG, Zura RD. Case report: lead toxicity associated with an extra-articular retained missile 14 years after injury. *J Surg Orthop Adv.* 2011;20(4):241–246.
206. McQuirter JL, Rothenberg SJ, Dinkins GA, Manalo M, Kondrashov V, Todd AC. The effects of retained lead bullets on body lead burden. *J Trauma.* 2001;50(5):892–899. doi:10.1097/00005373-200105000-00020
207. Nguyen A, Schaidter JJ, Manzanares M, Hanaki R, Rydman RJ, Bokhari F. Elevation of blood lead levels in emergency department patients with extra-articular retained missiles. *J Trauma.* 2005;58(2):289–299. doi:10.1097/01.ta.0000119205.24520.1d
208. Miracle VA. Lead poisoning in children and adults. *Dimens Crit Care Nurs.* 2017;36(1):71–73. doi:10.1097/dcc.0000000000000227
209. Wigle RL. The reaction of copper and other projectile metals in body tissues. *J Trauma.* 1992;33(1):14–18. doi:10.1097/00005373-199207000-00004
210. Avci SB, Açıköz B, Gündoğdu S. Delayed neurological symptoms from the spontaneous migration of a bullet in the lumbosacral spinal canal. Case report. *Paraplegia.* 1995;33(9):541–542. doi:10.1038/sc.1995.117
211. Çağavi F, Kalaycı M, Seçkiner İ, et al. Migration of a bullet in the spinal canal. *J Clin Neurosci.* 2007;14(1):74–76. doi:10.1016/j.jocn.2005.12.042
212. Gutiérrez V, Radice F. Late bullet migration into the knee joint. *Arthroscopy.* 2003;19(3):1–3. doi:10.1053/jars.2003.50065

Orthopedic Research and Reviews

Dovepress

Publish your work in this journal

Orthopedic Research and Reviews is an international, peer-reviewed, open access journal that focusing on the patho-physiology of the musculoskeletal system, trauma, surgery and other corrective interventions to restore mobility and function. Advances in new technologies, materials, techniques and pharmacological agents are particularly welcome. The manuscript management system is completely online and includes a very quick and fair peer-review system, which is all easy to use. Visit <http://www.dovepress.com/testimonials.php> to read real quotes from published authors.

Submit your manuscript here: <https://www.dovepress.com/orthopedic-research-and-reviews-journal>