

CLINICAL REPORT

Case report of bilateral ovarian fibromas associated with de novo germline variants in *PTCH1* and *SMARCA4*

Tomoyasu Higashimoto^{1,2}  | Christy Haakonsen Smith¹ | Mark R. Hopkins³ | John Gross³ | Deyin Xing³ | Jae W. Lee³ | Traevia Morris¹ | Joann Bodurtha^{1,2}

¹Department of Genetic Medicine, Johns Hopkins University, Baltimore, Maryland, USA

²Department of Pediatrics, Johns Hopkins University, Baltimore, Maryland, USA

³Department of Pathology, Johns Hopkins University, Baltimore, Maryland, USA

Correspondence

Tomoyasu Higashimoto, Department of Genetic Medicine Johns Hopkins University, Baltimore, MD, USA.
Email: thigash2@jh.edu

Funding information

National Institute of General Medical Sciences, Grant/Award Number: T32GM007471

Abstract

Background: Ovarian sex cord-stromal tumors (OSCTs) are rare ovarian tumors that can develop from sex cord, stromal cells, or both. OSCTs can be benign or malignant. Bilateral and/or unilateral ovarian fibromas, a type of OSCT of the stromal cells, have been reported in individuals diagnosed with nevoid basal cell carcinoma syndrome (NBCCS). Calcified ovarian fibromas have been reported in 15–25% of individuals diagnosed with NBCCS while 75% of those cases occur bilaterally. The average age at diagnosis of OSCT/ovarian fibromas in patients with NBCCS is in the second to third decade compared with age 50 in the general population. Ovarian tumors are rare in pediatric populations.

Methods: The patient is a 5-year-old female diagnosed with bilateral ovarian fibromas at age 4. Multigene panel for the patient and subsequent targeted molecular evaluation of parents were completed. Histological evaluations on the surgically resected ovaries were performed for microscopic characterization of fibromas.

Results: Germline testing identified de novo heterozygous novel likely pathogenic variants in *PTCH1* gene, exon 12 deletion, and an *SMARCA4* splicing variant c.2002-1G>A. Microscopic examination of bilateral tumors was consistent with an ovarian fibroma.

Conclusions: To our knowledge, this is the first report of bilateral benign ovarian fibroma in a child with a diagnosis of nevoid basal cell carcinoma syndrome (NBCCS) with a potential predisposition to Rhabdoid Tumor Predisposition Syndrome (RTPS).

KEYWORDS

basal cell nevus syndrome, Gorlin syndrome, Gorlin–Goltz syndrome, nevoid basal cell carcinoma syndrome, ovarian stromal tumors, rhabdoid tumor predisposition syndrome

This is an open access article under the terms of the [Creative Commons Attribution-NonCommercial](https://creativecommons.org/licenses/by-nc/4.0/) License, which permits use, distribution and reproduction in any medium, provided the original work is properly cited and is not used for commercial purposes.

© 2022 The Authors. *Molecular Genetics & Genomic Medicine* published by Wiley Periodicals LLC. This article has been contributed to by U.S. Government employees and their work is in the public domain in the USA.

1 | INTRODUCTION

Ovarian sex cord-stromal tumors (OSCT) are a group of rare tumors that can develop from the sex cord, stromal cells, or both. They represent 5–7% of all ovarian tumors in women ages 15–24.(Haroon et al., 2013; Morowitz et al., 2003) These tumors typically present as benign tumors in the 50s with 12% of patients younger than age 30, and 57% between ages 30 and 59.(Quirk & Natarajan, 2005) Some types of OSCT, such as adult granulosa cell tumors are malignant.

Ovarian fibromas in nevoid basal cell carcinoma syndrome (NBCCS, also known as Gorlin Syndrome, OMIM 109400) were first reported in 1963 (Clendenning et al., 1963). Ovarian fibromas have been reported in 15–25% of patients diagnosed with Gorlin syndrome, 75% of those being bilateral (Bagga et al., 2019). Most of these tumors occur after puberty (mean 30.6years, range 16–45years). In the general population, ovarian tumors are rarely present in the pediatric population, and approximately 1.5% of these tumors are fibromas (Ball et al., 2011). There have been few reports of ovarian fibromas in pediatric patients since the first publication (Ball et al., 2011). Herein, we report a 5-year-old female with bilateral ovarian fibromas identified at age 4 in which molecular genetic testing identified de novo likely pathogenic variants in the *PTCH1* and *SMARCA4* genes.

2 | CASE PRESENTATION

A 4-year-old girl was transferred to our hospital after concern about possible ileocolonic intussusception. Repeat ultrasound showed ovarian torsion, a 4.5 cm right ovarian tumor, and a smaller tumor on the left ovary. She underwent urgent detorsion of the right ovary and bilateral ovarian-sparing tumor resection. On gross evaluation, the right ovary showed a lobulated 4.5 × 3.6 × 2.6 cm mass with a homogenous tan/white cut surface, whereas the left showed two discrete masses measuring 1.2 and 0.5 cm in maximum dimension. Microscopically, the bilateral tumors demonstrated bland spindled cells within a dense collagenous background, consistent with an ovarian fibroma (Figure 1a). The tumors were further notable for frequent calcifications. Both ovaries also showed extensive hemorrhage and degenerative changes, consistent with ovarian torsion. An immunostain for steroidogenic factor-1 (SF-1) was positive, confirming sex cord stromal differentiation (Figure 1b).

The patient was referred to our genetics clinic given concern for NBCCS. She appeared nondysmorphic and had a reported height of 111 cm (57th percentile) and weight of 22.5 kg (87th percentile) at this telegenetics visit with unremarkable birth, growth, vision/hearing,

dentition, and development. The patient's head circumference was not available during this visit, and while we attempted to obtain the measurement, we were unable to obtain her head circumference.

The family consented to a germline genetic testing panel of 53 genes associated with pediatric solid tumors (Supplemental Data S1). Results showed a variant in the *PTCH1* gene, exon 12 deletion (Figure 1d), and a *SMARCA4* splicing variant c.2002-1G > A (Figure 1e). Neither of these variants has been previously reported in the literature in association with disease, but the laboratory interpreted both findings as likely pathogenic (Supplemental Table S1). Follow-up immunostain for Brahm-Related-Gene 1 (BRG1), the protein product of the *SMARCA4* gene, was also obtained in the patient's fibroma which showed a normal expression pattern (Figure 1c), demonstrating no loss of this gene within the tumor. Somatic NGS on her tumors was not completed. The patient's parents underwent targeted testing for *PTCH1* and *SMARCA4* which was reported as negative suggesting that these variants are de novo in the patient, though germline mosaicism in her parents could not be excluded. Therefore, it was recommended that her older brother still be tested. However, we did not confirm the paternity molecularly which limits our ability to fully demonstrate that the findings are de novo. Their family history was unremarkable (Figure 2).

The dermatology exam was notable for many presumptive basal cell carcinomas of the upper torso, neck, and face as well as palmoplantar pits, all generally felt to be consistent with NBCCS. She is currently under long-term surveillance through pediatric oncology by recently published management recommendations (Foulkes et al., 2017). Recent echocardiogram and whole-body MRI were unremarkable. Her chest X-ray did not show bifid or splayed ribs, and while limited did not indicate any vertebral anomalies. Her brain MRI did not show falx calcification.

3 | DISCUSSION

We reported a 5-year-old girl with bilateral ovarian fibromas with extensive calcifications diagnosed at age 4. Given the young age of onset, bilateral nature, and uncommon pathology findings such as extensive calcifications, we facilitated germline genetic testing via a gene panel which identified de novo variants in the *PTCH1* and *SMARCA4* genes that had not been previously reported but classified by the laboratory as likely pathogenic, described in more detail below.

Nevoid basal cell carcinoma syndrome (NBCCS), also known as Gorlin Syndrome, Gorlin–Goltz syndrome, and basal cell nevus syndrome (BCNS) (OMIM 109400), is an autosomal dominant condition. In 1960, Gorlin and Goltz described a syndrome that included multiple basal cell

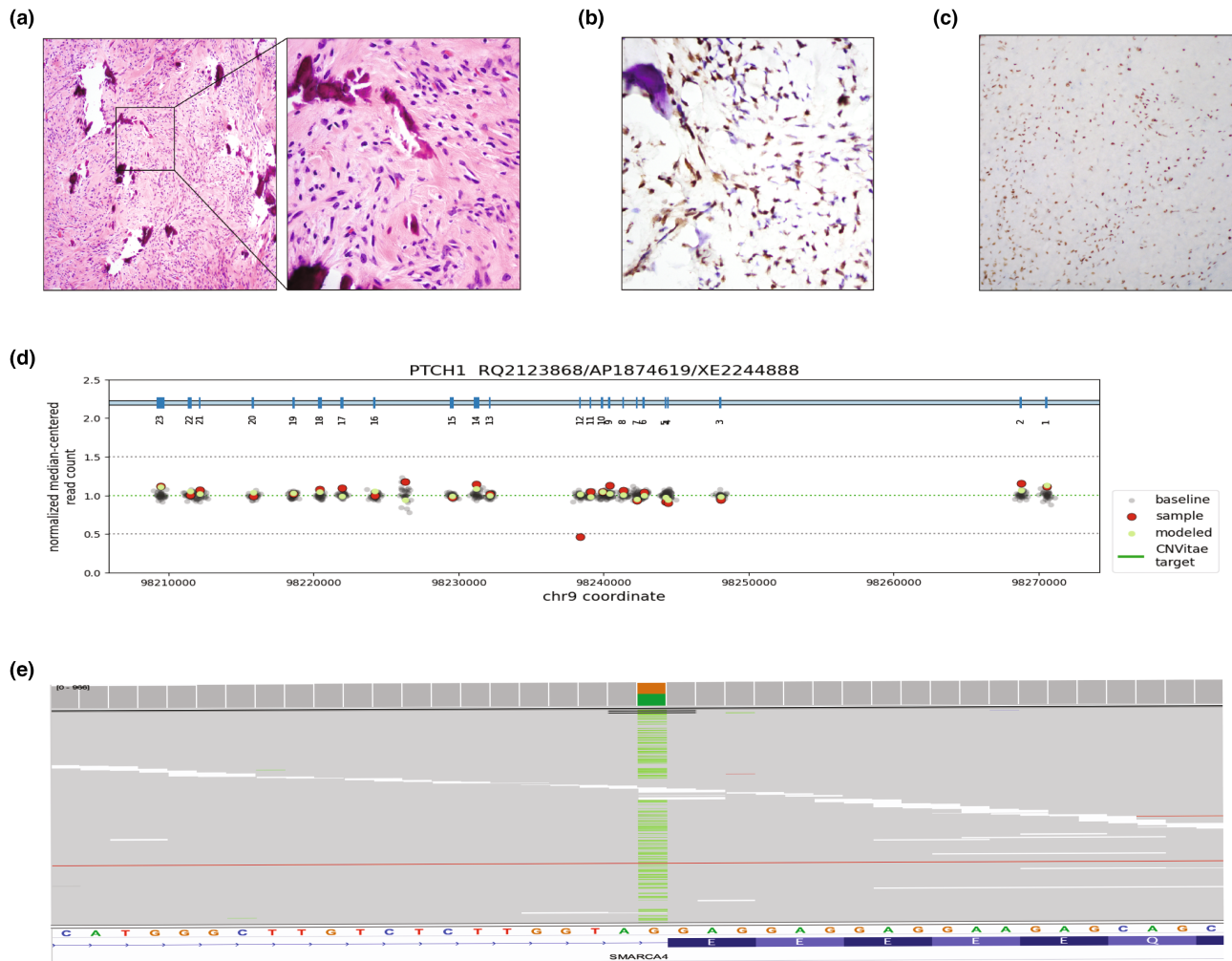


FIGURE 1 (a) Representative H&E staining image of the bilateral fibromas with calcification (magnification 100 \times). Second panel shows increased magnification at 400 \times . (b) Representative image of SF-1 immunostaining from the fibromas (magnification 400 \times). (c) Representative image of immunostaining for BRG1 from the fibromas (magnification 20 \times). (d) *PTCH1* variant identified in the proband (deletion of exon 12). (e) *SMARCA4* variant identified in the proband (c.2002-1G > a).

carcinomas, odontogenic keratocysts of the jaw, and bifid ribs (Gorlin & Goltz, 1960). Individuals with this condition were later described to have many other phenotypic features including a coarse facial appearance, hypertelorism, macrocephaly, palmar/plantar pits, spine and rib anomalies, and lamellar calcification of the falx cerebri. Cardiac and ovarian fibromas have been reported in 2% and 20% of affected individuals, respectively. About 1–2% with *PTCH1* variant and 20% with *SUFU* variant-related NBCCS in children develop medulloblastoma, typically the desmoplastic subtype (Kimonis et al., 1997; Kimonis et al., 2013; Omrani et al., 2010; Veenstra-Knol et al., 2005). NBCCS is characterized by near-complete penetrance with variable expressivity within and across families (Gorlin, 2004). This condition is typically caused by heterozygous pathogenic variants in the *PTCH1* gene, with a smaller percentage of cases due to heterozygous variants in *SUFU*. About 75% of individuals with NBCCS have an affected parent, with the

remainder presumably due to de novo germline variants (Evans & Farndon, 1993).

Features of NBCCS typically become apparent in adolescence, although children may first present with a wide range of congenital anomalies and/or atypical features (Evans et al., 1993; Kimonis et al., 1997; Shanley et al., 1994). Multiple diagnostic criteria have been developed to diagnose NBCCS (Evans et al., 1993; Kimonis et al., 1997; Shanley et al., 1994). While the current clinical criteria are effective in diagnosing older individuals, they are not as effective in identifying pediatric patients as some features do not appear until later in life (Kimonis et al., 2013). A suspected diagnosis of NBCCS can be confirmed by molecular analysis of the *PTCH1* and *SUFU* genes (Hahn et al., 1996; Veenstra-Knol et al., 2005).

The deletion of exon 12 in *PTCH1* identified in our patient is expected to be in-frame, preserving the integrity of the reading frame. While this variant has not

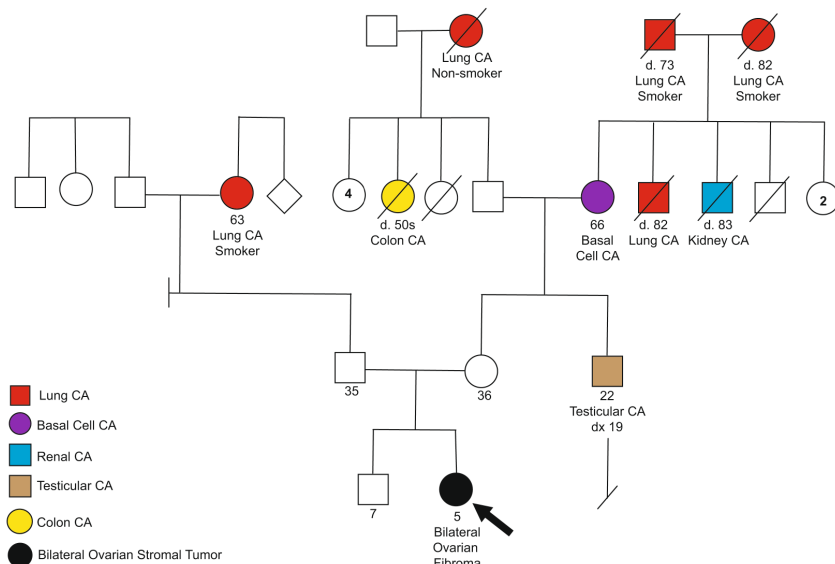


FIGURE 2 Four-generation family history pedigree.

been previously reported in individuals with NBCCS, it disrupts the p.Ser554 amino acid residue in *PTCH1*. Other variants that disrupt this residue have been determined to be pathogenic (Evans et al., 2017; Tanioka et al., 2005). This suggests that this residue is clinically significant, and that variants disrupt this residue are likely to be disease-causing.

Ovarian fibromas have been reported in 15–25% of patients diagnosed with NBCCS with 75% of those being bilateral (Bagga et al., 2019). The ovarian fibromas associated with NBCCS are often extensively calcified, which is in contrast to conventional, nonsyndromic ovarian fibromas which typically have at most focal calcifications. Most of these tumors seen in NBCCS occur after puberty (mean 30.6 years, range 16–45 years) (Kimonis et al., 1997). Ovarian fibromas prior to puberty in those with NBCCS are very unusual. The youngest case of an individual with NBCCS and ovarian fibromas that we were able to identify was age 6 (Jimbo et al., 2014). Our patient's bilateral ovarian fibromas are likely due to the variant identified in *PTCH1*. However, it is unknown whether she developed these tumors abnormally young for this disease and/or if there was some additional effect of having a likely pathogenic variant in *SMARCA4*.

Pathogenic variants in the *SMARCA4* gene are associated with rhabdoid tumor predisposition syndrome (RTPS)-2 (OMIM 613325), an autosomal dominant condition characterized by the development of malignant rhabdoid tumors, and aggressive soft tissue malignancies in infancy, childhood, or young adulthood (Sredni & Tomita, 2015; Witkowski et al., 2013). There is also a risk for small cell carcinoma of the ovary, hypercalcemic type (SCCOHT) in females, also known as malignant rhabdoid tumor of the ovary (Jelinic et al., 2014; Witkowski et al., 2014). Although the penetrance of germline *SMARCA4* variants is unknown, they appear to be less penetrant than *SMARCB1*,

which causes most cases of RTPS (Foulkes et al., 2017). Typically loss of function variants cause RTPS; whereas missense variants (that are typically gain of function) are most often associated with Coffin-Siris syndrome (OMIM 614609), a congenital malformation syndrome characterized by developmental delay, intellectual disability, coarse facial features, feeding difficulties, and hypoplastic or absent fifth fingernails and fifth distal phalanges (Kosho et al., 2014; Tsurusaki et al., 2012). Our patient did not demonstrate features of Coffin-Siris syndrome.

The *SMARCA4* variant identified in our patient affects the splice acceptor site in intron 13 which is suspected to disrupt RNA splicing. Disruption of splice donor and/or acceptor sites often leads to loss of protein function, and loss of function variants in *SMARCA4* is known to be pathogenic (Baralle & Baralle, 2005). This specific variant has not been reported in the literature in individuals with RTPS-2 or Coffin-Siris syndrome. While we do not have enough evidence to know whether this *SMARCA4* variant contributed to the development of the fibromas in our patient, she certainly is at risk to develop SCCOHT in the future as well as other malignant rhabdoid tumors.

In summary, it is unclear whether the presence of these two variants contributed to an additive and/or synergistic effect in the development of her fibromas at a younger age; but this case is unique given that both of these variants are de novo and the associated conditions are both associated with the development of ovarian tumors/malignancies.

4 | CONCLUSION

In conclusion, we report a case of a 5-year-old female diagnosed with bilateral benign ovarian stromal tumors at age 4,

initially raising concern for NBCCS. She was referred to our genetics clinic and identified to have presumably *de novo* pathogenic variants in the *PTCH1* and *SMARCA4* genes. On further exam, she exhibited features of NBCCS including presumptive basal cell carcinomas of the upper torso, neck, and face as well as palmoplantar pits. Our patient's ovarian fibromas had phenotypic features that seem to be most consistent with NBCCS, particularly the multifocal calcifications and bilateral nature. When ovarian fibromas occur in females without NBCCS, they are often unilateral with focal lesions, with bilateral fibromas reported in only 8% of sporadic cases (Roth & Czernobilsky, 2011). The young age of development of her ovarian tumors could be secondary to contributions from her variant in *SMARCA4* as SSCOHT are often diagnosed at younger ages with reported ages ranging from 10 to 47 years (median 24 years) (Witkowski et al., 2014). In NBCCS, ovarian fibromas are typically diagnosed between the ages of 16–45 years (average 30 years) (Kimonis et al., 1997).

This case highlights the importance of molecular genetic testing in young patients with early onset tumors who may lack or have subtle physical features of a hereditary cancer predisposition syndrome. Furthermore, this case supports the previous recommendation to evaluate for NBCCS when ovarian fibromas are present bilaterally, calcified, and/or nodular (Seracchioli et al., 2001). The case also highlights the importance of analyzing additional genes via a larger panel in which important additional findings may be identified. Early identification of these conditions is important as improved surveillance/management can be implemented at a younger age to help prevent further complications and potentially improve survival.

AUTHOR CONTRIBUTION

T. Higashimoto, C. Haakonsen Smith, and J. Bodurtha evaluated and diagnosed the patient. T. Higashimoto, C. Haakonsen Smith, T. Morris, and J. Bodurtha contributed to the conceptualization, data curation, and drafted the manuscript. M. Hopkins, J. Gross, D. Xing, and J. Lee performed pathological evaluation, histological preparation, and diagnosis from the surgical specimen. All the authors read and approved the final manuscript.

ACKNOWLEDGMENTS

We would like to thank the family for their eagerness to participate in writing this manuscript. We would like to thank Dr. Christine Pratilas for critically reviewing this manuscript.

FUNDING INFORMATION

T. Higashimoto was supported by the National Institute of General Medical Sciences of the National Institutes of Health under Award Number T32GM007471.

CONFLICT OF INTEREST

The authors declared that they have no subject-specific conflict of interest.


ETHICS STATEMENT

All procedures performed in studies involving human participants were in accordance with the ethical standards of the institutional and/or national research committee and with the 1964 Helsinki Declaration and with its later amendments or comparable ethical standards. Written informed consent from parents were obtained and are available.

DATA AVAILABILITY STATEMENT

The authors confirm that the data supporting the findings of this study are available within the article and/or its supplementary materials.

ORCID

Tomoyasu Higashimoto  <https://orcid.org/0000-0003-0435-065X>

REFERENCES

- Bagga, R., Garg, S., Muthyala, T., Kalra, J., Kumar Saha, P., Arora, A., Singla, R., Singh, T., & Gupta, N. (2019). Gorlin syndrome presenting with primary infertility and bilateral calcified ovarian fibromas. *Journal of Obstetrics and Gynaecology*, 39, 874–876. <https://doi.org/10.1080/01443615.2019.1581752>
- Ball, A., Wenning, J., & Van Eyk, N. (2011). Ovarian fibromas in pediatric patients with basal cell nevus (Gorlin) syndrome. *Journal of Pediatric and Adolescent Gynecology*, 24, e5–e7. <https://doi.org/10.1016/j.jpog.2010.07.005>
- Baralle, D., & Baralle, M. (2005). Splicing in action: Assessing disease causing sequence changes. *Journal of Medical Genetics*, 42, 737–748. <https://doi.org/10.1136/jmg.2004.029538>
- Clendenning, W. E., Herd, T., Jr., & Block, J. B. (1963). Ovarian fibromas and mesenteric cysts: Their association with hereditary basal cell cancer of the skin. *American Journal of Obstetrics and Gynecology*, 87, 1008–1012. [https://doi.org/10.1016/0002-9378\(63\)90094-2](https://doi.org/10.1016/0002-9378(63)90094-2)
- Evans, D. G., & Farndon, P. A. (1993–2022). *GeneReviews*([R]) (M. P. Adam, H. H. Ardinger, R. A. Pagon, S. E. Wallace, L. J. H. Bean, K. W. Gripp, G. M. Mirzaa, A. Amemiya, Eds). University of Washington, Seattle.
- Evans, D. G., Ladusans, E. J., Rimmer, S., Burnell, L. D., Thakker, N., & Farndon, P. A. (1993). Complications of the naevoid basal cell carcinoma syndrome: Results of a population based study. *Journal of Medical Genetics*, 30, 460–464. <https://doi.org/10.1136/jmg.30.6.460>
- Evans, D. G., Oudit, D., Smith, M. J., Rutkowski, D., Allan, E., Newman, W. G., & Lear, J. T. (2017). First evidence of genotype-phenotype correlations in Gorlin syndrome. *Journal of Medical Genetics*, 54, 530–536. <https://doi.org/10.1136/jmedgenet-2017-104669>
- Foulkes, W. D., Kamihara, J., Evans, D. G. R., Brugières, L., Bourdeaut, F., Molenaar, J. J., Walsh, M. F., Brodeur, G. M., & Diller, L. (2017). Cancer surveillance in Gorlin syndrome and rhabdoid tumor predisposition syndrome. *Clinical Cancer*

- Research, 23, e62–e67. <https://doi.org/10.1158/1078-0432.CCR-17-0595>
- Gorlin, R. J. (2004). Nevoid basal cell carcinoma (Gorlin) syndrome. *Genetics in Medicine*, 6, 530–539. <https://doi.org/10.1097/01.gim.0000144188.15902.c4>
- Gorlin, R. J., & Goltz, R. W. (1960). Multiple nevoid basal-cell epithelioma, jaw cysts and bifid rib. A syndrome. *The New England Journal of Medicine*, 262, 908–912. <https://doi.org/10.1056/NEJM196005052621803>
- Hahn, H., Wicking, C., Zaphiropoulos, P. G., Gailani, M. R., Shanley, S., Chidambaram, A., Vorechovsky, I., Holmberg, E., Unden, A. B., Gillies, S., Negus, K., Smyth, I., Pressman, C., Leffell, D. J., Gerrard, B., Goldstein, A. M., Dean, M., Toftgard, R., Chenevix-Trench, G., ... Bale, A. E. (1996). Mutations of the human homolog of drosophila patched in the nevoid basal cell carcinoma syndrome. *Cell*, 85, 841–851. [https://doi.org/10.1016/s0092-8674\(00\)81268-4](https://doi.org/10.1016/s0092-8674(00)81268-4)
- Haroon, S., Zia, A., Idrees, R., Memon, A., Fatima, S., & Kayani, N. (2013). Clinicopathological spectrum of ovarian sex cord-stromal tumors; 20years' retrospective study in a developing country. *Journal of Ovarian Research*, 6, 87. <https://doi.org/10.1186/1757-2215-6-87>
- Jelinic, P., Mueller, J. J., Olvera, N., Dao, F., Scott, S. N., Shah, R., Gao, J. J., Schultz, N., Gonen, M., Soslow, R. A., Berger, M. F., & Levine, D. A. (2014). Recurrent SMARCA4 mutations in small cell carcinoma of the ovary. *Nature Genetics*, 46, 424–426. <https://doi.org/10.1038/ng.2922>
- Jimbo, T., Masumoto, K., Urita, Y., Takayasu, H., Shinkai, T., Uesugi, T., Gotoh, C., Sakamoto, N., Sasaki, T., Oto, T., Fukushima, T., Noguchi, E., & Nakano, Y. (2014). Nevoid basal cell carcinoma syndrome with a unilateral giant ovarian fibroma in a Japanese 6-year-old girl. *European Journal of Pediatrics*, 173, 667–670. <https://doi.org/10.1007/s00431-013-2200-7>
- Kimonis, V. E., Goldstein, A. M., Pastakia, B., Yang, M. L., Kase, R., DiGiovanna, J. J., Bale, A. E., & Bale, S. J. (1997). Clinical manifestations in 105 persons with nevoid basal cell carcinoma syndrome. *American Journal of Medical Genetics*, 69, 299–308.
- Kimonis, V. E., Singh, K. E., Zhong, R., Pastakia, B., DiGiovanna, J. J., & Bale, S. J. (2013). Clinical and radiological features in young individuals with nevoid basal cell carcinoma syndrome. *Genetics in Medicine*, 15, 79–83. <https://doi.org/10.1038/gim.2012.96>
- Kosho, T., Okamoto, N., & Coffin-Siris Syndrome International, C. (2014). Genotype-phenotype correlation of coffin-Siris syndrome caused by mutations in SMARCB1, SMARCA4, SMARCE1, and ARID1A. *American Journal of Medical Genetics. Part C, Seminars in Medical Genetics*, 166C, 262–275. <https://doi.org/10.1002/ajmg.c.31407>
- Morowitz, M., Huff, D., & von Allmen, D. (2003). Epithelial ovarian tumors in children: A retrospective analysis. *Journal of Pediatric Surgery*, 38, 331–335; discussion 331–335. <https://doi.org/10.1053/jpsu.2003.50103>
- Omrani, H., Hoa, H. B., Bennis, H., Lehmann, M., & Zerr, V. (2010). Recurrent ovarian fibromas in condition of Gorlin syndrome. *Journal de Gynecologie, Obstetrique et Biologie de la Reproduction*, 39, 584–587. <https://doi.org/10.1016/j.jgyn.2010.05.010>
- Quirk, J. T., & Natarajan, N. (2005). Ovarian cancer incidence in the United States, 1992–1999. *Gynecologic Oncology*, 97, 519–523. <https://doi.org/10.1016/j.ygyno.2005.02.007>
- Roth, L. M., & Czernobilsky, B. (2011). Perspectives on pure ovarian stromal neoplasms and tumor-like proliferations of the ovarian stroma. *The American Journal of Surgical Pathology*, 35, e15–e33. <https://doi.org/10.1097/PAS.0b013e31820acb89>
- Seracchioli, R., Bagnoli, A., Colombo, F. M., Missiroli, S., & Venturoli, S. (2001). Conservative treatment of recurrent ovarian fibromas in a young patient affected by Gorlin syndrome. *Human Reproduction*, 16, 1261–1263. <https://doi.org/10.1093/humrep/16.6.1261>
- Shanley, S., Ratcliffe, J., Hockey, A., Haan, E., Oley, C., Ravine, D., Martin, N., Wicking, C., & Chenevix-Trench, G. (1994). Nevoid basal cell carcinoma syndrome: Review of 118 affected individuals. *American Journal of Medical Genetics*, 50, 282–290. <https://doi.org/10.1002/ajmg.1320500312>
- Sredni, S. T., & Tomita, T. (2015). Rhabdoid tumor predisposition syndrome. *Pediatric and Developmental Pathology*, 18, 49–58. <https://doi.org/10.2350/14-07-1531-MISC.1>
- Tanioka, M., Takahashi, K., Kawabata, T., Kosugi, S., Murakami, K. I., Miyachi, Y., Nishigori, C., & Iizuka, T. (2005). Germline mutations of the PTCH gene in Japanese patients with nevoid basal cell carcinoma syndrome. *Archives of Dermatological Research*, 296, 303–308. <https://doi.org/10.1007/s00403-004-0520-1>
- Tsurusaki, Y., Okamoto, N., Ohashi, H., Kosho, T., Imai, Y., Hibi-Ko, Y., Kaname, T., Naritomi, K., Kawame, H., Wakui, K., Fukushima, Y., Homma, T., Kato, M., Hiraki, Y., Yamagata, T., Yano, S., Mizuno, S., Sakazume, S., Ishii, T., ... Matsumoto, N. (2012). Mutations affecting components of the SWI/SNF complex cause coffin-Siris syndrome. *Nature Genetics*, 44, 376–378. <https://doi.org/10.1038/ng.2219>
- Veenstra-Knol, H. E., Scheewe, J. H., van der Vlist, G. J., van Doorn, M. E., & Ausems, M. G. (2005). Early recognition of basal cell naevus syndrome. *European Journal of Pediatrics*, 164, 126–130. <https://doi.org/10.1007/s00431-004-1597-4>
- Witkowski, L., Carrot-Zhang, J., Albrecht, S., Fahiminiya, S., Hamel, N., Tomiak, E., Grynspan, D., Saloustros, E., Nadaf, J., Rivera, B., Gilpin, C., Castellsagué, E., Silva-Smith, R., Plourde, F., Wu, M., Saskin, A., Arseneault, M., Karabakhtsian, R. G., Reilly, E. A., ... Foulkes, W. D. (2014). Germline and somatic SMARCA4 mutations characterize small cell carcinoma of the ovary, hypercalcemic type. *Nature Genetics*, 46, 438–443. <https://doi.org/10.1038/ng.2931>
- Witkowski, L., Lalonde, E., Zhang, J., Albrecht, S., Hamel, N., Cavallone, L., May, S. T., Nicholson, J. C., Coleman, N., Murray, M. J., Tauber, P. F., Huntsman, D. G., Schönberger, S., Yandell, D., Hasselblatt, M., Tischkowitz, M. D., Majewski, J., & Foulkes, W. D. (2013). Familial rhabdoid tumour “avant la lettre” – from pathology review to exome sequencing and back again. *The Journal of Pathology*, 231, 35–43. <https://doi.org/10.1002/path.4225>

SUPPORTING INFORMATION

Additional supporting information can be found online in the Supporting Information section at the end of this article.

How to cite this article: Higashimoto, T., Smith, C. H., Hopkins, M. R., Gross, J., Xing, D., Lee, J. W., Morris, T., & Bodurtha, J. (2022). Case report of bilateral ovarian fibromas associated with de novo germline variants in *PTCH1* and *SMARCA4*. *Molecular Genetics & Genomic Medicine*, 10, e2005. <https://doi.org/10.1002/mgg3.2005>