



Interictal Discharges: All Roads Lead to Rome?

Epilepsy Currents
2022, Vol. 22(4) 252-254
© The Author(s) 2022
Article reuse guidelines:
sagepub.com/journals-permissions
DOI: 10.1177/1535759221098809
journals.sagepub.com/home/epi



Siddharth Gupta, MBBS¹ and Shilpa D. Kadam, PhD²

Human Interictal Epileptiform Discharges Are Bidirectional Traveling Waves Echoing Ictal Discharges

Smith EH, Liou J-Y, Merricks EM, et al. *Elife*. 2022;11:e73541. Published 2022 Jan 20. doi:10.7554/eLife.73541.

Interictal epileptiform discharges (IEDs), also known as interictal spikes, are large intermittent electrophysiological events observed between seizures in patients with epilepsy. Although they occur far more often than seizures, IEDs are less studied, and their relationship to seizures remains unclear. To better understand this relationship, we examined multi-day recordings of microelectrode arrays implanted in human epilepsy patients, allowing us to precisely observe the spatiotemporal propagation of IEDs, spontaneous seizures, and how they relate. These recordings showed that the majority of IEDs are traveling waves, traversing the same path as ictal discharges during seizures, and with a fixed direction relative to seizure propagation. Moreover, the majority of IEDs, like ictal discharges, were bidirectional, with 1 predominant and a second, less frequent antipodal direction. These results reveal a fundamental spatiotemporal similarity between IEDs and ictal discharges. These results also imply that most IEDs arise in brain tissue outside the site of seizure onset and propagate toward it, indicating that the propagation of IEDs provides useful information for localizing the seizure focus.

Commentary

During EEG workups preceding the planning of surgical interventions for refractory epilepsy, patients are regularly implanted with intracranial grids, stereotactic depth electrodes and micro-electrode arrays to help determine seizure focus zones amenable for surgical resections, however, short recording durations preclude capturing an actual seizure event in many patients. Interictal epileptiform discharges (IEDs), on the other hand, are relatively common and thus more readily recorded during clinical and pre-surgical EEGs. Pre-clinical and clinical research has logically focused on investigating the value of using IED location and temporal frequencies to predict seizure occurrence, seizure onset zones (SOZ) and seizure propagation.¹ Additionally, since several groups have documented the clustering of seizures in both animal models and patients^{2,3} using multi-day recording protocols to show both circadian and multidien rhythms, the evaluation of the temporal relationship of IEDs to the seizure clustering is now enabled. Similarly, the availability of long-term intracranial and depth-electrode data from patient pre-surgical workups has made it possible to study the spatiotemporal propagation of IEDs in relationship to the identified seizure focus. IEDs from standard and HD scalp EEG help provide complementary information to define the epileptogenic zones non-invasively⁴ but invasive intracranial recordings can provide a much higher spatiotemporal resolution. Invasive grids and depth electrode intracranial EEG leads are

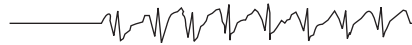usually placed around pre-identified seizure foci. Therefore, the approach of characterizing IED properties using LFPs recorded with multi-unit arrays, though logical, limits the location where the spatiotemporal propagation properties of IEDs can be recorded (ie; only around Rome).^{1,5}

In this manuscript, Smith et al⁶ studied the spatiotemporal features of IEDs using Utah-style microelectrode array (UEA) recordings from 10 patients undergoing invasive monitoring for epilepsy surgery. Prior investigations of seizures suggest a dual spatial structure consisting of an ictal core bounded by an ictal wave-front surrounded by a passively reactive penumbra. The ictal wave-front is a narrow band of intense desynchronized tonic action potential firing that delineates the core and penumbra. The slow propagation of the ictal wave-front (<1 mm/sec) corresponds to the slow evolution of the electrographic seizure and the successive clinical changes during a seizure. As the ictal wave front advances, it generates fast moving seizure discharges (SDs) backwards towards the seizure core. SDs are the basis of high amplitude field potential deflections seen during electrographic seizures. Hence, the 2 types of moving waves that characterize focal seizures are the fast, inward-moving seizure discharges and the slow outward-moving wave-front of ictal recruitment during seizure propagation. Here, the investigators queried whether IEDs show similar behavior.

¹ Johns Hopkins Medicine, USA

² Kennedy Krieger Institute, USA






The UEAs were placed in the area of the subdural grid that was most likely to be in the SOZ. Studying the LFP and multiunit action potential recordings from the UEA, the authors first established that, like SDs, the majority of the IEDs were also travelling waves (66.4%), and in 8/10 patients the IEDs had a bimodal distribution of travel, with 1 predominant and another auxiliary direction. To study whether the spatial features of IEDs correlated with that of SDs, 10 seizures from 6 participants were selected whose UEA locations were “recruited” into the ictal core. It is only in the “recruited” seizure event that an ictal wave-front is formed which would enable the study of direction of seizure propagation, unlike “penumbral” seizures, where such studies could not be reliably performed. To find such “recruited” seizures, time periods in the UEA recordings that corresponded to the seizure times reported in clinical reports were examined and the presence of seizures was confirmed based on the UEA LFP characteristic high amplitude, rhythmic discharges. The investigators then looked for tonic multiunit firing spreading across the array that would suggest the presence of an ictal wave front. The spatial propagation features of the IEDs were found to be similar to those of the SD, and were largely antipodal to the direction of expansion of the ictal wave front representing the seizure propagation. To further study the geometric features of bimodal IED and their relationship to SDs, “recruited” participants with bimodal IEDs were selected (7 seizures in 5 participants). It was found that 5 out of 7 seizures exhibited bimodal SD distribution similar to the IED distribution. The speed of the IEDs and SD discharges in the 2 sub-distribution cohorts were significantly different. Furthermore, the proportion of the IED directions in each sub-distribution predicted the direction of each SD sub-distribution in 4 out of 5 participants. The study concluded that IEDs are travelling waves that have a similar propagation pattern as the SDs in some but not all seizures, especially the ones that fit the model of bimodal distribution. Hence, the IEDs could potentially be used to predict the seizure core in absence of a seizure event.

The IEDs define the so called “irritative zone” (IZ), which shares a complex relationship with the SOZ.⁷ There is often dissociation between the topography of IEDs and the SOZ, and it is generally recognized that the IZ is larger than the SOZ.^{8,9} IZs could extend to brain regions much larger than the SOZ as well as to spatially distant sites where seizures may jump to non-adjacent leads during propagation. The clinical significance of the analysis presented in this manuscript is that IEDs can be used to identify the SOZ. Although the results of the study are important and a step forward, there are certain important limitations that the authors point out, such as an extremely small spatial scale of the recordings using the UEA (4 mm x 4 mm) and that not all IEDs or seizures within their cohort fit the set model and could be used for analysis. In a real-world scenario, this can only be expected to become more convoluted, especially in the absence of prior knowledge of the SOZ. To bring the results of this study to a clinical level, as a next step, it would be

interesting to study the relationship of the propagation patterns of UEA LFPs to the IED propagation on the subdural grid or Stereo EEG, which although more complicated, could possibly be used in clinical practice to define the SOZ. Furthermore, it would also be interesting to study how the removal of the seizure focus predicted by the UEA correlates with post-surgical outcomes.

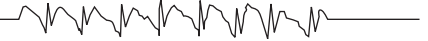IEDs have been studied as a canary in the coal mine tool to help signal and predict seizure onset, as well as for post-intervention workups to evaluate the post-surgical efficacy or success rates. Dense array EEGs are able to capture more location specific IEDs compared to the standard 10-20 EEG for non-invasive monitoring¹⁰ to help define the SOZ. The ability to use IED propagation analyses to help identify seizure focus is a lofty goal when the seizure focus is not already known. Post-hoc analyses as proposed here when UEAs were placed around a known seizure focus have the “all roads in the vicinity of Rome will lead to Rome” bias built in. How would these predictions work when the focus is not known? What if there are multiple foci? Or if the IED propagation is not bimodal as in a subset of their own dataset? Even though more frequent, IEDs just like seizures are episodic with a tendency to cluster with individualistic and variable multidien and circadian cycles.¹¹ Additionally, the analyses conducted using UEA data cannot translate to standard or high-density scalp electrodes therefore the value in non-invasive pre-interventional workups for determining the SOZ seems limited. Nevertheless, the work by Smith et al expands our understanding of IEDs and their potential as a predictive tool.

ORCID iD

Shilpa D. Kadam  <https://orcid.org/0000-0001-5136-9594>

References

1. Khoo HM, von Ellenrieder N, Zazubovits N, He D, Dubeau F, Gotman J. The spike onset zone. *Neurology*. 2018;91:e666-e674.
2. Kadam SD, White AM, Staley KJ, Dudek FE. Continuous electroencephalographic monitoring with radio-telemetry in a rat model of perinatal hypoxia-ischemia reveals progressive post-stroke epilepsy. *J Neurosci*. 2010;30:404-415.
3. Haut SR, Shinnar S, Moshe SL. Seizure Clustering: Risks and Outcomes. *Epilepsia*. 2005;46:146-149.
4. Jabran Y, Mahmoudzadeh M, Martinez N, Heberlé C, Wallois F, Bourel-Ponchel E. Temporal and Spatial Dynamics of Different Interictal Epileptic Discharges: A Time-Frequency EEG Approach in Pediatric Focal Refractory Epilepsy. *Front Neurol*. 2020;11:941.
5. Meisel C, Loddenkemper T. Seizure prediction and intervention. *Neuropharmacology*. 2020;172:107898.
6. Smith EH, Liou J, Merricks EM, et al. Human interictal epileptiform discharges are bidirectional traveling waves echoing ictal discharges. *Elife*. 2022;11:e73541.
7. Jehi L. The Epileptogenic Zone: Concept and Definition. *Epilepsy Current*. 2018;18:12-16.



8. Chowdhury FA, Silva R, Whatley B, Walker MC. Localisation in focal epilepsy: a practical guide. *Practical Neurol*. 2021;21:481-491.
9. Parasuram H, Gopinath S, Pillai A, Diwakar S, Kumar A. Quantification of Epileptogenic Network From Stereo EEG Recordings Using Epileptogenicity Ranking Method. *Front Neurol*. 2021;12:738111.
10. Yamazaki M, Terrill M, Fujimoto A, Yamamoto T, Tucker DM. Integrating dense array EEG in the presurgical evaluation of temporal lobe epilepsy. *ISRN neurology*. 2012;2012:924081-924089.
11. Baud MO, Kleen JK, Mirro EA, et al. Multi-day rhythms modulate seizure risk in epilepsy. *Nat Commun*. 2018;9:88.