



Molecular Layer Heterotopia: Harmless Brain Warts or Ictal Main Force?

Epilepsy Currents
2022, Vol. 22(4) 258-260
© The Author(s) 2022
Article reuse guidelines:
sagepub.com/journals-permissions
DOI: 10.1177/15357597221101263
journals.sagepub.com/home/epi



Kyle P. Lillis, PhD¹

Original Article Citation

Li, A. M., Hill, R. A. & Grutzendler, J. Intravital Imaging of Neocortical Heterotopia Reveals Aberrant Axonal Pathfinding and Myelination around Ectopic Neurons. *Cereb Cortex* 31, 4340-4356 (2021). doi:10.1093/cercor/bhab090.

Neocortical heterotopia consist of ectopic neuronal clusters that are frequently found in individuals with cognitive disability and epilepsy. However, their pathogenesis remains poorly understood due in part to a lack of tractable animal models. We have developed an inducible model of focal cortical heterotopia that enables their precise spatiotemporal control and high-resolution optical imaging in live mice. Here, we report that heterotopia are associated with striking patterns of circumferentially projecting axons and increased myelination around neuronal clusters. Despite their aberrant axonal patterns, *in vivo* calcium imaging revealed that heterotopic neurons remain functionally connected to other brain regions, highlighting their potential to influence global neural networks. These aberrant patterns only form when heterotopia are induced during a critical embryonic temporal window, but not in early postnatal development. Our model provides a new way to investigate heterotopia formation *in vivo* and reveals features suggesting the existence of developmentally modulated, neuron-derived axon guidance and myelination factors.

Commentary


The abnormal presence of neuronal cell bodies in Layer I of the neocortex is associated with wide-ranging neurological disorders including epilepsy, developmental dyslexia, and a rare form of muscular dystrophy.¹⁻³ However, the degree to which these anatomical abnormalities *cause* the clinical symptoms associated with these disorders remains unclear. Perhaps some confusion about the prevalence of Layer I heterotopias in normal and diseased brains comes from subtle differences in classification and quantification of microscopic abnormalities of cortical gray matter. The (sometimes overlapping) terminology includes, among others, neuronal ectopias, microdysgenesis, focal dysplasia, heterotopia, and “brain warts”. The work highlighted here describes an abnormality in which a cluster of neurons forms ectopically in Layer I (the molecular layer) of the neocortex. Going forward this will be referred to as Molecular Layer Heterotopia (MLH). In epilepsy, there is some evidence to suggest a correlation between the prevalence of MLH and drug-resistant epilepsy.¹ And, in tissue resected for the treatment of mesial temporal lobe epilepsy (MTLE), the success rate of the surgery was correlated with the density of MLHs⁴ in the removed tissue. The relationship between MLHs and MTLE has yet to be well-characterized, but this finding

implies that neuronal clusters in Layer I are co-located with (presumably deeper) ictogenic tissue. There was not, however, a significant difference overall in the Layer I neuronal density between tissue resected from patients with intractable epilepsy and autopsy controls.⁴ Furthermore, cerebro-cortical microdysgenesis is seen to some degree in “normal brains”,⁵ suggesting that low-level migrational disturbances are not sufficient to cause epilepsy. In other words, Layer I heterotopia are present overall at “normal” levels in epileptic brains, but their density covaries with tissue ictogenicity in MTLE. It is not clear whether they are causally or incidentally related to the ictogenic zone.

MLH are associated with reduced seizure threshold in genetic mouse models⁶ and in rats in which widespread neuronal heterotopia were induced with low-dose gamma irradiation *in utero*.⁷ *In vivo* recording of anatomical and functional properties of neurons in and around MLHs will be an important step in understanding whether MLHs are ictogenic (ie focal origin of seizures), indirectly related to epilepsy (eg their presence disturbs normal activity in surrounding brain), or simply a red herring (a harmless side effect of some

¹ Massachusetts General Hospital





other epileptogenic process). Unfortunately, with genetic and systemic induction of heterotopia in rodents, it is difficult to control the prevalence and location of heterotopia, which complicates their study *in vivo*.

In the highlighted work,⁸ demonstrate a novel method for targeted induction of molecular layer heterotopia in mouse neocortex. As with many great inventions, the technique was developed accidentally. When attempting to perform *in utero* electroporation (IUE) to label and image cortical axons *in vivo*, the authors discovered that neuronal cell bodies at the site of DNA injection clustered in cortical layer I, closely resembling a molecular layer heterotopia. Unlike global genetic predisposition or radiative manipulations, *in utero* electroporation creates a single nodular heterotopia at a controlled location, with the added advantage that a subset of the MLH cells could be transfected with a plasmid (eg encoding for a fluorescent protein). Anatomical characterization of these IUE-induced heterotopia using both immunohistochemical analysis of fixed tissue and a novel microscopy technique capable of imaging unlabeled axons *in vivo*⁹ revealed an increased density of oligodendrocytes and ectopic bundles of myelinated and unmyelinated axons surrounding and underneath the MLH, similar to the anatomy of spontaneously occurring MLH in specific strains of mice.^{10,11}

The cellular composition of the induced MLH included a diverse population of glutamatergic projection neurons and GABAergic interneurons, with interneuron density comparable to that of adjacent control Layer I cortex. Neuronal birth-dating techniques revealed that cells within the heterotopia were born at various stages of development. Interestingly, although postnatal day zero (P0) injections of adeno-associated virus (AAV) also led to ectopic neuronal clusters in Layer I, only embryonic injections (between days 14 and 17) associated with *in utero* electroporation exhibited abnormalities in axon guidance, myelination, and oligodendrocyte cell body density. Thus, the developmental timing of MLH induction has a dramatic impact on its anatomical phenotype. Importantly, there is not an increased density of glia or microglia within or surrounding the MLH. Thus, although the mechanism of heterotopia induction remains unclear, the “trauma” associated with the MLH-inducing injection does not produce a glial scar, which would have complicated interpretation of experiments using this model, as it would be difficult to disentangle the effects of gliosis from those of the heterotopia.

To directly address the question of whether MLHs are not only anatomically anomalous, but also functionally abnormal, heterotopic and surrounding normotopic cortex were transduced with the genetically encoded calcium indicator GCaMP6f. In two-minute movies acquired from awake, head-fixed mice, there was no significant difference in calcium activity between neurons within the MLH and adjacent normotopic layer II/III neurons, as measured by spike event frequency, spike variance, or synchronous activity. Furthermore, neurons within the MLH responded robustly to whisker stimulation, suggesting that they are functionally connected to other brain areas.

Unfortunately, no data was shown during whisker stimulation from adjacent normotopic cortex to indicate whether the apparently ubiquitous response to whisker stimulation in the MLH was unexpectedly high (which would suggest pathological functional connectivity).

Notably, there was no epileptiform activity observed in any of calcium imaging epochs presented, nor was an epileptic phenotype in mice with the induced MLH reported. This is not entirely unexpected, as IUE-injections produce a single MLH with a mean diameter of 474 μm and there seems to be a relationship between the density of heterotopias and detectable behavioral phenotypes.^{1,4} Small numbers of MLH may be considered within the “normal” range in humans.⁵ While no micro-seizures were observed during calcium imaging of the MLH, the authors note that the recordings were short and longer imaging sessions may have revealed epileptiform activity. Furthermore, the controlled nature of the induced MLH in this model make it potentially feasible in future work to vary the size and number of MLHs to test the hypothesis that the epileptic phenotype is related to the density of MLHs. If an epileptic phenotype can be induced using this approach, it would also be strong evidence that MLHs themselves are epileptogenic, as the injection-induced MLH is a highly targeted manipulation, with no obvious systemic effect. While the study from Li et al just begins to crack the surface of characterizing the functional impact of molecular layer heterotopias, it introduces a powerful new tool for isolating their putative role in epilepsy.


Declaration of Conflicting Interests

The author(s) declared no potential conflicts of interest with respect to the research, authorship, and/or publication of this article.

Funding

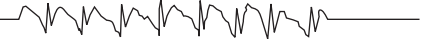The author(s) disclosed receipt of the following financial support for the research, authorship, and/or publication of this article: This work was supported by National Institute of Neurological Disorders and Stroke (R01NS112538).

ORCID iD

Kyle P. Lillis  <https://orcid.org/0000-0003-0219-8113>

References

1. Eriksson S, Rydenhag B, Uvebrant P, Malmgren K, Nordborg C. Widespread microdysgenesis in therapy-resistant epilepsy - a case report on post-mortem findings. *Acta Neuropathol.* 2002;103:74-77. DOI: 10.1007/s004010100426.
2. Galaburda AM, Sherman GF, Rosen GD, Aboitiz F, Geschwind N. Developmental dyslexia: Four consecutive patients with cortical anomalies. *Ann Neurol.* 1985;18:222-233. DOI: 10.1002/ana.410180210.



3. Ramos RL, Siu NY, Brunken WJ, et al. Cellular and Axonal Constituents of Neocortical Molecular Layer Heterotopia. *Dev Neurosci*. 2014;36:477-489. DOI: 10.1159/000365100.
4. Thom M, Sisodiya S, Harkness W, Scaravilli F. Microdysgenesis in temporal lobe epilepsy: A quantitative and immunohistochemical study of white matter neurones. *Brain*. 2001;124:2299-2309. DOI: 10.1093/brain/124.11.2299.
5. Meencke HJ, Veith G. Migration disturbances in epilepsy. *Epilepsy Res Suppl*. 1992;9:31-40.
6. Gabel LA, Manglani M, Ibanez N, Roberts J, Ramos RL, Rosen GD. Differential seizure response in two models of cortical heterotopia. *Brain Res*. 2013;1494:84-90. DOI: 10.1016/j.brainres.2012.11.040.
7. Roper SN, Gilmore RL, Houser CR. Experimentally induced disorders of neuronal migration produce an increased propensity for electrographic seizures in rats. *Epilepsy Res*. 1995;21:205-219. DOI: 10.1016/0920-1211(95)00027-8.
8. Li AM, Hill RA, Grutzendler J. Intravital imaging of neocortical heterotopia reveals aberrant axonal pathfinding and myelination around ectopic neurons. *Cerebr Cortex*. 2021;31:4340-4356. DOI: 10.1093/cercor/bhab090.
9. Schain AJ, Hill RA, Grutzendler J. Label-free in vivo imaging of myelinated axons in health and disease with spectral confocal reflectance microscopy. *Nat Med*. 2014;20:443-449. DOI: 10.1038/nm.3495.
10. Lipoff DM, Bhambri A, Fokas GJ, et al. Neocortical molecular layer heterotopia in substrains of C57BL/6 and C57BL/10 mice. *Brain Res*. 2011;1391:36-43. DOI: 10.1016/j.brainres.2011.03.026.
11. Ramos RL, Smith PT, DeCola C, Tam D, Corzo O, Brumberg JC. Cytoarchitecture and Transcriptional Profiles of Neocortical Malformations in Inbred Mice. *Cerebr Cortex*. 2008;18:2614-2628. DOI: 10.1093/cercor/bhn019.