

Injectional anthrax at a Scottish district general hospital

D. J. INVERARITY^{1*}, V. M. FORRESTER², J. G. R. CUMMING³,
P. J. PATERSON⁴, R. J. CAMPBELL⁵, T. J. G. BROOKS⁶, G. L. CARSON⁶
AND J. P. RUDDY²

¹ Department of Microbiology, Monklands Hospital, Airdrie, Scotland, UK

² Department of Anaesthetics and Intensive Care, Monklands Hospital, Airdrie, Scotland, UK

³ Department of General Surgery, Monklands Hospital, Airdrie, Scotland, UK

⁴ Department of Haematology, Monklands Hospital, Airdrie, Scotland, UK

⁵ Department of Pathology, Monklands Hospital, Airdrie, Scotland, UK

⁶ Special Pathogens Reference Unit, Public Health England, Salisbury, England, UK

Received 15 May 2014; Accepted 2 July 2014; first published online 31 July 2014

SUMMARY

This retrospective, descriptive case-series reviews the clinical presentations and significant laboratory findings of patients diagnosed with and treated for injectional anthrax (IA) since December 2009 at Monklands Hospital in Central Scotland and represents the largest series of IA cases to be described from a single location. Twenty-one patients who fulfilled National Anthrax Control Team standardized case definitions of confirmed, probable or possible IA are reported. All cases survived and none required limb amputation in contrast to an overall mortality of 28% being experienced for this condition in Scotland. We document the spectrum of presentations of soft tissue infection ranging from mild cases which were managed predominantly with oral antibiotics to severe cases with significant oedema, organ failure and coagulopathy. We describe the surgical management, intensive care management and antibiotic management including the first description of daptomycin being used to treat human anthrax. It is noted that some people who had injected heroin infected with *Bacillus anthracis* did not develop evidence of IA. Also highlighted are biochemical and haematological parameters which proved useful in identifying deteriorating patients who required greater levels of support and surgical debridement.

Key words: Anthrax, injecting drug-users (IDUs), soft tissue infections.

INTRODUCTION

Bacillus species often contaminate heroin [1]. *Bacillus anthracis* affecting people who inject drugs (PWID)

was first observed in 2000 [2]. No further heroin-related anthrax occurred until an outbreak in 2009 of injectional anthrax (IA) occurred predominantly in Scotland [3]. PWID with confirmed, probable and possible IA (Table 1) occurred along with many PWID with similar presentations for whom testing for anthrax was negative. Since June 2012 sporadic IA has occurred both in the UK and elsewhere in Europe [4]. IA has several recognized clinical

* Author for correspondence: Dr D. J. Inverarity, Consultant Microbiologist, Monklands Hospital, Monkscourt Avenue, Airdrie ML6 0JS, Scotland, UK.
(Email: Donald.Inverarity@nhs.net)

Table 1. *Health Protection Scotland National Anthrax Outbreak Control Team case classification used in the 2009–2010 outbreak of IA [3]*

Epidemiological category	National Anthrax Outbreak Control Team definition
Confirmed case	Clinical and epidemiological evidence consistent with anthrax infection and unequivocal microbiological evidence
Probable case	Clinical and epidemiological evidence consistent with anthrax infection and positive microbiological evidence short of confirmation
Possible case	Clinical and epidemiological evidence consistent with anthrax infection and microbiological evidence that was equivocal
Non-anthrax case	Clinical and epidemiological evidence of suspected anthrax infection with negative results on microbiological testing and/or evidence of an alternative microbiological agent that could explain their clinical illness

manifestations [3, 5–14]. Confirmed IA has a mortality rate of 28% [3].

METHODS

A database at Monklands Hospital used to store anthrax results issued by the Health Protection Agency Special Pathogens Reference Unit (SPRU) was consulted to identify confirmed, probable and possible cases of IA (as defined in Table 1) and then followed by case-note review and review of laboratory results.

RESULTS

Seven confirmed, five probable and nine possible IA cases were diagnosed; all of which survived. Seventy percent of the cases were men. The median age of females was 28 (range 21–33) years and for males 33 (range 24–54) years. The median duration of admission was 5 days (range 0–62 days).

Table 2 summarizes laboratory results obtained from SPRU and Table 3 summarizes details regarding the clinical features and bacterial co-infections. For only three confirmed and probable cases was the patient's bloodborne virus status known at presentation. During treatment six confirmed cases were identified as antibody positive for hepatitis C virus (HCV) although not all of these had polymerase chain reaction (PCR) evidence of active HCV infection.

Table 4 summarizes haematological and biochemical results of significance including parameters which proved helpful in identifying cases with more severe infection requiring greater levels of intensive care support and surgical intervention and which may help to elucidate the pathogenesis of IA and its spectrum of presentations.

DISCUSSION

Clinical observations

Spectrum of presentations and clinical features

All confirmed IA cases presented with soft tissue infection and features distinct from classical cutaneous anthrax and necrotizing fasciitis (NF) [15]. No cases of intracranial haemorrhage occurred. Some descriptions of IA note necrosis [5–7] while others do not [14]. Pleural effusions have been described as present [5, 13] or absent [6, 8, 14]. The presence [6, 7, 13] or absence of fever [8, 13, 14] may be seen.

In case C, despite thigh fasciotomies there remained gross limb oedema and skin petechiae. Wounds were affected by blistering golden vesicles and desquamation. Thigh oedema worsened with new suprapubic and genital oedema and new vesicles over 24 h associated with worsening coagulopathy and thrombocytopenia. After further debridement and prolonged intravenous antibiotics, the fasciotomies healed with limb salvage although this took over 40 days.

Vesicles are characteristic features of cutaneous anthrax [16] and have been described in IA [13, 14] despite a review suggesting they do not occur [16]. In case C, vesicles manifested with substantial oedema and resembled impetigo [14] although culture was sterile. Microscopy of vesicular fluid demonstrated no bacilli and vesicle PCR was negative for herpes zoster and herpes simplex.

Cases B and K did not have oedema. Case K did not have soft tissue infection but had pneumonia although serology suggested recent exposure to anthrax. Oedema is a common feature of IA [3] but is not always present.

Case E had a swollen, tender, dusky injection site with central oedematous tissue but no drainable collection and no crepitus. Other injection sites on the

Table 2. Summary of diagnostic microbiological test parameters used to identify cases of injectional anthrax

Case	HPS classification	PCR	Anti-PA IgG antibodies	Anti-LF IgG antibodies	Immunoreactive PA	Immunoreactive LF
A	Confirmed	Negative	Positive	Negative	Negative	Negative
B	Confirmed	Negative	Positive	Positive	Negative	Negative
C	Confirmed	Pus PCR positive	Negative	Negative	Not tested	Not tested
D	Confirmed	Blood and pus PCR positive	Positive	Positive	Negative	Negative
E	Confirmed	Tissue PCR positive	Positive	Positive	Negative	Negative
F	Confirmed	Pus PCR positive	Positive	Positive	Negative	Negative
G	Confirmed	Swab PCR positive for <i>cap</i> and <i>lef</i> genes	Positive	Positive	Negative	Negative
H	Probable	Negative	Positive	Negative	Negative	Negative
I	Probable	Negative	Positive	Negative	Negative	Negative
J	Probable	Negative	Equivocal	Negative	Positive	Equivocal
K	Probable	Negative	Positive	Equivocal	Negative	Negative
L	Probable	Negative	Positive	Negative	Not tested	Not tested
M	Possible	Negative	Equivocal	Negative	Negative	Negative
N	Possible	Negative	Negative	Positive	Negative	Negative
O	Possible	Negative	Positive	Negative	Negative	Negative
P	Possible	Negative	Equivocal	Equivocal	Negative	Negative
Q	Possible	Negative	Positive	Positive	Negative	Negative
R	Possible	Negative	Equivocal	Equivocal	Negative	Negative
S	Possible	Negative	Negative	Positive	Not tested	Not tested
T	Possible	Not tested	Positive	Positive	Not tested	Not tested
U	Possible	Negative	Positive	Negative	Not tested	Not tested

HPS, Health Protection Scotland; PA, Protective antigen; LF, lethal factor.

In case G, although the full three genes required for PCR diagnosis were not present on the swab obtained, anthrax was confirmed from debrided tissue when the patient had surgery in another health board. In case C serology was tested on blood taken on day 8 after admission which might account for the negative serology despite the case being confirmed by PCR if seroconversion had not yet taken place. Cases A and B were classed as confirmed on the basis of rising titres of anti-PA IgG several days apart. For case A, the negative PCR result relates to peripheral blood PCR as no tissue or pus was received for PCR. For case B a single wound swab was received and was negative by PCR but as the patient had multiple sites of soft tissue infection at the time it is possible that a lesion was swabbed that did not have *B. anthracis* detectable whereas if sampling had been performed for all the lesions a different one may have tested positive by PCR.

limb were necrotic but not oedematous. Case F had significant limb oedema with few surface changes except cellulitis.

The site of infection is not always the site of injection [14]. The oedema and abscess in case D was where concealed heroin was in contact with skin under clothing and not at a site of injection. IA was confirmed by PCR performed on a swab taken at a General Practice surgery. Of note, case D avoided admission for 6 days and was managed cautiously in the community with oral clindamycin. When admitted, incision and drainage of a small abscess was performed. There was minimal oedema, no necrosis but an impetigo-like appearance.

Neither case A nor case B required debridement and were managed almost entirely with oral antibiotics when continued admission was declined.

Most deaths in confirmed IA are before day 10 after presentation [3, 8]. Confirmed and probable cases usually have an incubation period of <1 day [3]. Protective immunity may develop 14 days after vaccination [17]. The most severe patients we managed improved by day 15 so protective immunity in IA patients may also develop around this time.

Co-infections

Staphylococci may inhibit growth of *B. anthracis* in cutaneous lesions [18]. Co-infection may stimulate the host immune system and oppose immunosuppressive effects of anthrax toxins [3]. Cases G, L, N, P and T were co-infected with *Staphylococcus aureus* and had mild IA. Case C had severe IA co-infected with *Streptococcus pyogenes* yet survived. Cases D, G

Table 3. Summary of clinical features of cases of injectional anthrax

Case	HPS classification	Site of infection	Oedema present	Abscess present	Cellulitis present	Necrosis present	Other organisms identified
A	Confirmed	Arm	Yes	No	Yes	No	Nil
B	Confirmed	Leg and arm	No	Yes	Yes	No	Nil
C	Confirmed	Leg	Yes	No	Yes	Yes	<i>Streptococcus pyogenes</i>
D	Confirmed	Leg	Yes	Yes	No	No	<i>Fingoldia magna</i> , <i>Prevotella oralis</i>
E	Confirmed	Leg	Yes	No	Yes	Yes	Nil
F	Confirmed	Arm	Yes	No	Yes	No	Nil
G	Confirmed	Leg	Yes	Yes	Yes	Yes	MSSA, <i>Prevotella disiens</i> , <i>Prevotella melaninogenicus</i>
H	Probable	Arm	Yes	No	Yes	No	Nil
I	Probable	Arm	Yes	No	Yes	No	Nil
J	Probable	Leg	Yes	No	Yes	No	Nil
K	Probable	Pneumonia	No	No	No	No	Nil
L	Probable	Leg	Yes	Yes	Yes	Unknown	MSSA
M	Possible	Leg	Unknown	No	Yes	Unknown	Nil
N	Possible	Leg	Yes	Yes	Yes	No	MSSA
O	Possible	Leg	Yes	No	Yes	No	Nil
P	Possible	Leg	Yes	Yes	Yes	No	MSSA
Q	Possible	Arm	Yes	No	Yes	No	Nil
R	Possible	Leg	No	No	Yes	No	Nil
S	Possible	Leg	Yes	No	Yes (with crepitus)	Yes	Group G β -haemolytic streptococci, <i>Prevotella timonensis</i> , <i>Porphyromonas</i> species*
T	Possible	Leg	Yes	Yes	No	No	MSSA
U	Possible	Leg	Yes	No	Yes	No	Nil

HPS, Health Protection Scotland; MSSA, methicillin-sensitive *Staphylococcus aureus*.

* Identified by Public Health Wales Anaerobe Reference Laboratory using 16 s rRNA sequence analysis but sequence analysis was unable to determine between *Porphyromonas asaccharolytica* and *Porphyromonas uenonis*.

and S had co-infection with anaerobes which could account for the clinical features more like NF of case S. It is possible that bacterial co-infection may improve survival from IA.

Co-infection with HCV generally did not cause hepatic decompensation although fatal liver failure during IA and HCV co-infection has been described elsewhere [13, 19].

Injecting partners

We investigated individuals who knew they injected the same infected heroin (some from the same syringe) as two severe, confirmed IA cases. One contact had soft tissue abscesses but tested negative for anthrax, highlighting the difficulty in differentiating anthrax and non-anthrax infection even after exposure to infected heroin. Contacts who tested negative had not taken antibiotics, suggesting there may be a

protective host factor, but antibodies to anthrax were not detected. These individuals did not receive post-exposure prophylaxis with ciprofloxacin as indicated in inhaled anthrax [20], yet they did not develop any anthrax even after 60 days. The risk of infection from injected anthrax may be less than from inhaled anthrax.

Cases B and I both injected the same batch of heroin and both developed signs of IA. Had it been possible to obtain follow-up serology from case I they might have been classifiable as confirmed.

Laboratory diagnosis

Culture

No specimens cultured *B. anthracis* despite procedures identical to laboratories that grew anthrax. For several patients antibiotics were necessary prior to

Table 4. Summary of haematological and biochemical parameters for injectional anthrax cases

Case	HPS classification	Admission CRP (normal range <6 mg/l)	Admission white cell count (normal range 4–11 ×10 ⁹ /l)	Admission neutrophil count (normal range 2–8 ×10 ⁹ /l)	Lowest haematocrit (normal range 0.42–0.54 l/l)	Highest haematocrit (normal range 0.42–0.54 l/l)	Lowest fibrinogen (normal range 1.5–4.5 g/l)	Albumin (normal range 36–52 g/l)	Highest alanine aminotransferase (normal range 0–50 IU/l)	Lowest sodium (normal range 135–145 mmol/l)	Lowest adjusted calcium (normal range 2.1–2.6 mmol/l)
A	Confirmed	26	9.4	4.3	0.397	0.397	3.8	39	10	139	2.28
B	Confirmed	20	7.8	4.4	0.405	0.416	n.t.	42	24	141	2.24
C	Confirmed	86	9.8	5.3	0.136	0.609	0.6	41	465	122	1.59
D	Confirmed	14	10.2	6	0.385	0.429	3.2	41	26	138	2.24
E	Confirmed	150	18.6	13.8	0.14	0.389	1.4	17	37	132	2.17
F	Confirmed	18	18.4	15.5	0.322	0.427	3.0	47	49	130	2.17
G	Confirmed	16	7	5.2	0.286	0.286	2.2	41	17	137	n.t.
H	Probable	10	10.9	7.2	0.375	0.385	3.4	45	10	136	n.t.
I	Probable	<6	9.8	5.3	0.386	0.386	n.t.	n.t.	8	141	n.t.
J	Probable	13	5.7	3.3	0.319	0.342	2.9	42	33	136	n.t.
K	Probable	29	15.2	13.6	0.328	0.388	3.0	42	44	137	2.15
L	Probable	230	9.8	9.0	0.314	0.398	5.2	38	21	135	2.08
M	Possible	n.t.	n.t.	n.t.	n.t.	n.t.	n.t.	n.t.	n.t.	n.t.	n.t.
N	Possible	13	6.2	2.4	0.342	0.342	3.1	43	23	138	n.t.
O	Possible	17	4.7	2.3	0.321	0.355	5.0	22	99	133	2.3
P	Possible	112	7	4.7	0.35	0.377	5.0	38	19	136	n.t.
Q	Possible	44	16.4	10.4	0.376	0.405	3.4	41	42	137	2.33
R	Possible	73	8.3	4.8	0.394	0.490	n.t.	37	42	133	2.23
S	Possible	312	15.4	14.1	0.203	0.431	4.0	29	73	133	2.17
T	Possible	217	9.3	6.3	0.339	0.424	5.0	27	27	140	n.t.
U	Possible	9	7.1	3.8	0.378	0.416	3.7	44	35	140	n.t.

HPS, Health Protection Scotland; CRP, C-reactive protein; n.t. not tested.

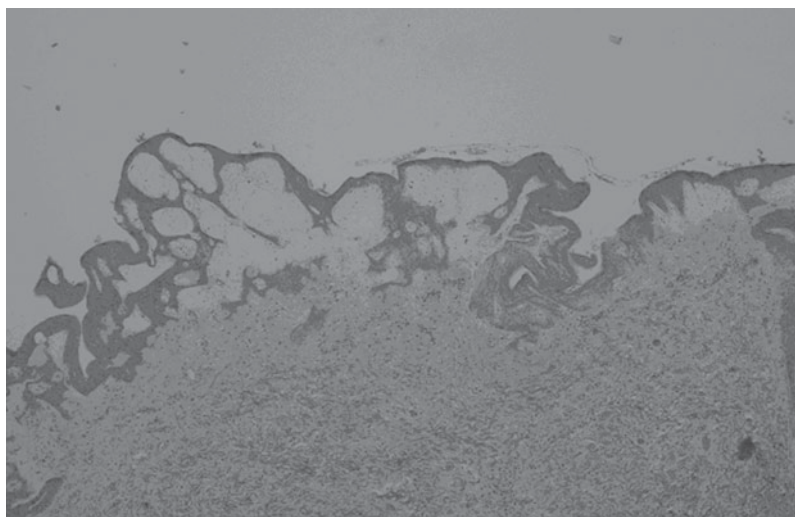


Fig. 1. Haematoxylin and eosin stained section of debrided skin from a patient with confirmed injectional anthrax, illustrating significant subepidermal oedema. No Gram-positive bacilli were visible in the tissue.

debridement. Sometimes antibiotics were administered prior to blood culturing. The lack of sampling prior to antibiotics may explain negative blood cultures. One patient had been self-medicating with amoxicillin prior to presentation. It is unclear if antibiotic self-medication was widespread locally in PWID but this could explain the less severe clinical presentations and the absence of *B. anthracis* bacteraemia.

PLET (polymixin, lysozyme, EDTA, thallos acetate) agar selects *B. anthracis* and inhibits growth of contaminating organisms. It proved difficult to obtain and was not used. However, overgrowth with contaminating organisms did not occur and cultures using Columbia blood agar were often sterile.

PCR

PCR was considered positive if three *B. anthracis* genes were detectable – *lef* (lethal factor on plasmid pXO1), *capA* (capsular gene on plasmid pXO2) and *bagC* (a genomic gene). Blood, body fluids, swabs or tissue were tested. This became the mainstay of confirming IA when cultures were negative.

Serology

In cases A and B paired sera showing rising anti-PA IgG titres suggesting recent anthrax exposure enabled classification as confirmed rather than probable cases. Both cases had soft tissue infection but had minimal contact with medical services. It proved easier in these circumstances to obtain blood for follow-up

serology than blood cultures, tissue, pus or swabs for culture and PCR.

Histopathology

Debrided tissue was available from three confirmed IA cases. For two, abundant necrosis was identified within the deep subcutaneous tissue. Although non-specific, these features were similar to conventional NF. In the remaining case, superficial tissue was preferentially debrided. Small amounts of necrosis were seen but the prominent feature was oedema in the superficial dermis (Fig. 1) similar to that reported in cutaneous anthrax [21]. Gram-positive bacilli or spores were not identified in any cases suggesting toxin-mediated tissue damage although Gram-positive bacilli have been visible in tissue from other IA cases [6]. The different manifestations may relate to the relative proportions of oedema and lethal toxin that are produced.

Antibiotic management

A five antibiotic empirical regimen was advocated [22] based on previous experience of polymicrobial soft tissue infections in PWID [23–25]. The identification of polymicrobial infections (Table 3) supported this strategy.

Optimal treatment [26] was not always achieved due to patient non-compliance. In such cases, 14 days of oral clindamycin and ciprofloxacin was offered. In mice, clindamycin and ciprofloxacin combined may increase mortality in anthrax [27] but we experienced no adverse events using this combination in humans.

Avoiding debridement risks relapse if spores are retained. None of the patients who did not have debridement relapsed despite only 14 days treatment. One confirmed case had continued wound oozing after 14 days treatment and wound fluid remained PCR positive for *B. anthracis* on day 15. As a precaution, the duration of treatment was extended.

Case C reported a penicillin allergy and had severe disease that progressed despite intravenous (IV) ciprofloxacin and clindamycin. They received 6 mg/kg IV daptomycin rather than IV vancomycin. Daptomycin is advocated for septic PWID [28] and evidence in mice supports its use treating anthrax [29]. It is licensed for use in complicated skin and soft tissue infection due to Gram-positive organisms. This patient was co-infected with *B. anthracis* and *S. pyogenes* and risked amputation which they were unlikely to survive. A combination of daptomycin, ciprofloxacin, clindamycin, meropenem and metronidazole in addition to cautious surgery resulted in full recovery both of the patient and the infected limb. Daptomycin is bacteriocidal through calcium-dependent insertion of pores into Gram-positive cell membranes resulting in potassium efflux and membrane depolarization without lysis of the bacteria resulting in minimal exotoxin release [30]. Penicillins cause cell lysis. The minimizing of exotoxin release may be relevant in anthrax infection which is predominantly driven by two exotoxins. Daptomycin also crosses the blood–brain barrier and could therefore treat IA with meningeal involvement [26], albeit it is inactive in pulmonary infections.

Non-antibiotic adjunctive treatment

Some non-antimicrobial therapies have activity against anthrax toxins [31]. None of these drugs were used. Indomethacin and other anti-platelet drugs were considered inappropriate as patients were often thrombocytopenic and haemorrhagic.

Possible exacerbation of haemodynamic instability was felt to be too great a risk for calcium channel antagonists to be used. Additionally, case C was hypocalcaemic throughout the first week of treatment [lowest calcium measured was 1.64 mmol/l on day 6 (normal range 2.1–2.6 mmol/l)] and was receiving infusions of 10% calcium gluconate almost daily (11 bolus infusions of 10 ml of 10% calcium gluconate administered in the first 7 days). It was counterintuitive to replace calcium and administer calcium antagonists concurrently. Calcium replacement was considered

important while daptomycin was being administered. No cases received anthrax immunoglobulin.

Surgical management

Initial expert advice was to excise affected skin with a >2 cm margin, remove any areas of subdermal fat that appeared altered and to widely excise any needle track identified in muscle [26].

Cases C and F exhibited compartment syndrome and had fasciotomies to improve tissue perfusion and antibiotic delivery. Review was performed at 12 h and 24 h post-operatively and then on a daily basis for worsening oedema or new skin changes. In case E despite an initial 10 cm excision margin, further debridement was required and wound oozing was substantial in cases C, E and F.

Because IA does not always present as NF, radical debridement may not always be necessary. Latterly a more cautious surgical approach was promoted when necrosis was absent [5]. Where there was obvious tissue necrosis, we opted for debridement and frequent wound inspection. Repeat debridement in case C was purposefully superficial as deeper tissue appeared healthy. Wounds in case C were dressed with non-adherent materials [oxidized cellulose polymer to promote haemostasis (Surgicel[®], Ethicon Inc., USA), paraffin gauze (Jelonet[®], Smith & Nephew Healthcare, UK), viscose and rayon absorbent pad with adhesive border (Primapore[®], Smith & Nephew Healthcare)] and wool and crepe bandage pressure dressings were used to reduce limb oedema. In case D, where there was no significant oedema, Kaltostat[®] (ConvaTec, UK) dressings were used. Alginate and antiseptic dressings have been used in other places with good results [13]. Similarly to other cases [7, 13], two of our patients had negative pressure wound therapy using a Venturi[™] (Talley Group, UK) wound sealing kit. It was used after 14 days treatment had elapsed to minimize the risk of aerosolizing viable *B. anthracis* if the system was dislodged in the first 14 days.

Both patients managed in an intensive care unit (ICU) with confirmed anthrax had pleural effusions and one had significant ascites. These can be reservoirs of anthrax toxins [15, 32]. However drainage was not performed. In one patient because the infection was managed prior to guidance advising drainage being issued and in the other, chest drain insertion was considered too great a risk given the degree of coagulopathy and haemodynamic instability.

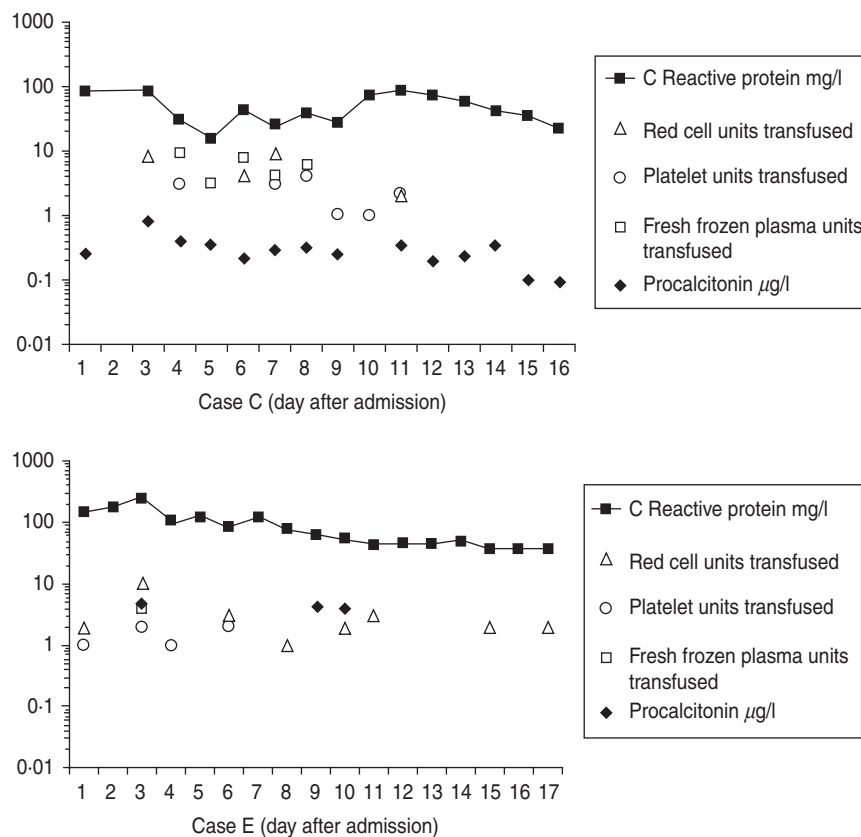


Fig. 2. Timelines showing serial C-reactive protein measurements and serial procalcitonin measurements for two different cases of confirmed injectional anthrax, requiring intensive care management, during the first 17 days of treatment. Daily requirements of blood products (units of packed red cells, platelets and fresh frozen plasma) are also included to illustrate disease severity and response to treatment with regard to progression and resolution of coagulopathy.

Intensive care management

Management of shock

Two of the confirmed cases had shock requiring fluid resuscitation and transfusion of blood products. Case C responded to fluids alone (with 6 l of colloid and crystalloid) whereas case E required noradrenaline infusions for 4 days. Both had increased cardiac output despite lethal toxin reducing cardiac output in monkeys and dogs [32–34]. This was unusual as many cases of IA requiring ICU support described elsewhere had vasopressor-resistant shock [15] postulated to be a consequence of oedema toxin [17]. Our patients had significant limb oedema and pleural effusions (likely due to oedema toxin), but did not experience vasopressor-resistant shock. This was fortunate as its development appears to be fatal [13, 15].

Management of coagulopathy and haemorrhage

Cases C and E required substantial blood products replacement. Within the first 14 days, case C required

23 U packed red cells, 22 U platelets, 30 U fresh frozen plasma (FFP) and eight pools of cryoprecipitate. Within the first 17 days, case E required 25 U packed red cells, 6 U platelets and 4 U FFP (Fig. 2). These requirements are similar to other cases where up to 37 U blood were transfused [6]. A drop in fibrinogen was noted in cases C and E (Table 4) possibly from dilution secondary to fluid resuscitation and consumption from disseminated intravascular coagulopathy.

Haemoconcentration has been observed in anthrax-associated sepsis when the route of infection has been cutaneous, gastrointestinal or inhalational [32], but was seen only initially in case C during the first 48 h. It then fell, possibly due to dilution from the volume of fluid required to manage shock or as a consequence of anthrax toxins. Paradoxically, lower than normal haematocrit levels were observed in all cases during treatment even although IV fluids were not administered to all cases (Table 4).

Case C received other measures to improve their coagulopathy, including three doses of 10 mg IV

vitamin K within the first 4 days and six doses of 1 g IV tranexamic acid within the first 6 days. In view of significant peri- and post-operative bleeding, 10 µg IV desmopressin was also given on days 2 and 6.

Hyponatraemia

Case C was hyponatraemic [sodium 134 mmol/l (normal range 135–145 mmol/l)] on admission and this fell to 124 mmol/l prior to the commencement of fluids. Hyponatraemia in inhalational anthrax has been described but it was not known how often this occurred prior to fluid resuscitation [32]. Hyponatraemia may help differentiate inhalational anthrax from community-acquired pneumonia [35]. Moreover, hyponatraemia has been associated more with NF than non-necrotizing soft tissue infection [36]. All our confirmed cases that required high dependency or intensive care support had hyponatraemia prior to fluid resuscitation or had hyponatraemia without receiving fluid resuscitation. Of the less severe IA cases, hyponatraemia was less common.

This absence of hyponatraemia is in keeping with cases elsewhere that did not require ICU support [14] while cases requiring ICU support presented with hyponatraemia [8, 37]. It has been observed that infusion of oedema toxin in dogs reduces sodium levels [34] so it is possible that the hyponatraemia we observed in our patients is an effect of oedema toxin independent of the dilutional effects of fluid resuscitation. Potentially, hyponatraemia in a septic PWID individual could be used as a marker to indicate possible IA requiring greater support.

Procalcitonin

Procalcitonin was tested in confirmed cases C and E (Fig. 2) and possible cases R and U. In case C procalcitonin remained low suggesting ongoing infection was unlikely despite uncontrolled coagulopathy, further debridements, rising C-reactive protein (CRP) and deterioration on day 9 from secondary bacterial infection. In case E procalcitonin was raised suggesting infection and did not change over the first 10 days of treatment despite a falling CRP, reducing requirements of blood products and improvement. Case R had an initial procalcitonin level of 4.4 µg/l and in case U it was < 0.05 µg/l. A German who died from IA with septic shock, coagulopathy and multi-organ failure had a single procalcitonin measurement reported of 1.05 ng/ml [13, 19].

Procalcitonin testing was not useful either in identifying infection or monitoring response to treatment.

Release of procalcitonin is triggered by pro-inflammatory cytokines interleukin (IL)-1β, tumour necrosis factor (TNF)-α and IL-6 during bacterial infections [38]. *B. anthracis* lethal toxin suppresses TNF-α in macrophages, T cells and dendritic cells, suppresses IL-1β in macrophages and dendritic cells and suppresses IL-6 in dendritic cells [39]. Procalcitonin may be low in IA as the cytokine pathways which require stimulation to release procalcitonin may be being suppressed by anthrax lethal toxin.

CONCLUSIONS

We describe a series of patients with IA who presented to Monklands Hospital for diagnosis and management with 100% survival. Clinical presentations varied from mild soft tissue infection to multi-organ failure, shock and coagulopathy. These cases highlight the difficulty in differentiating IA from non-anthrax-related soft tissue infection. Our clinical management of IA at times, out of clinical necessity, deviated from expert opinion, or scenarios were encountered where there was no agreed expert opinion. For instance, whether to use a less aggressive approach to surgical debridement, optimal post-operative wound management, management of severe coagulopathy, management of mild cases with oral antibiotics and what we believe to be the first description of using daptomycin to treat human anthrax. Some cases had IA plus co-infection with other bacteria or HCV. Additionally we report observations regarding some routine laboratory tests, such the sodium level, which may be useful biomarkers of severe IA.

ACKNOWLEDGEMENTS

The authors thank all staff of Monklands Hospital who have been involved in the diagnosis and management of these patients. In particular from the Department of Infectious Diseases (Drs A. Todd, N. Kennedy, S. Dundas, C. McGoldrick), from the Intensive Care Unit (Drs S. Marshall, D. Clough, S. Chohan, M. MacKinnon, R. McKenzie), from the Department of Orthopaedics (Drs A. Campbell, K. Cheng, B. Singh, S. Sinha, D. Bramley), from the Department of General Surgery (Drs A. MacDonald, T. Salem), from the Department of Microbiology (Dr P. Hunter, Dr P. Robertson, H. Robertson, I. Winning, R. Yates, E. Kilgour, K. Gordon), from

the Department of Pathology (Dr M. Agarwal) and the Infection Control Team (L. Thomas, R. Fox). The Anaerobe Reference Unit, National Public Health Service for Wales, Cardiff for identification of anaerobes and the Health Protection Team, Department of Public Health, NHS Lanarkshire.

This research received no specific grant from any funding agency, commercial or not-for-profit sectors.

DECLARATION OF INTEREST

None.

REFERENCES

1. **McLauchlin J, et al.** An investigation into the microflora of heroin. *Journal of Medical Microbiology* 2002; **51**: 1001–1008.
2. **Ringertz SH, et al.** Injectional anthrax in a heroin skin-popper. *Lancet* 2000; **356**: 1574–1575.
3. **National Anthrax Outbreak Control Team.** An outbreak of anthrax among drug users in Scotland, December 2009 to December 2010. Health Protection Scotland, 2011.
4. **Health Protection Scotland.** NHS Lanarkshire alert on anthrax and heroin use. *HPS Weekly Report* 2012; **46**: 261.
5. **Jallali N, et al.** The surgical management of injectional anthrax. *Journal of Plastic Reconstructive and Aesthetic Surgery* 2010; **64**: 276–277.
6. **Parcell BJ, et al.** Injection anthrax causing compartment syndrome and necrotising fasciitis. *Journal of Clinical Pathology* 2011; **64**: 95–96.
7. **Powell AGMT, et al.** A case of septicæmic anthrax in an intravenous drug user. *BMC Infectious Diseases* 2011; **11**: 21.
8. **Johns N, et al.** An unusual case of peritonitis in an intravenous drug user. *Gastroenterology* 2011; **141**: 435–436.
9. **Beaumont G.** Anthrax in a Scottish intravenous drug user. *Journal of Forensic and Legal Medicine* 2010; **17**: 443–445.
10. **Bannard-Smith J, et al.** Anthrax infection in an intravenous drug user. *Intensive Care Medicine* 2013; **39**: 530.
11. **Radun D, et al.** Preliminary case report of fatal anthrax in an injecting drug user in North-Rhine-Westphalia, Germany, December 2009. *Eurosurveillance* 2010; **15**: 14.
12. **Meghji S, Judd O, Carr E.** Fatal cutaneous anthrax in a heroin user. *Journal of Laryngology and Otology* 2013; **127**: 423–425.
13. **Grunow R, et al.** Injection anthrax – a new outbreak in heroin users. *Deutsches Ärzteblatt International* 2012; **109**: 843–848.
14. **Knox D, et al.** Subcutaneous anthrax in three intravenous drug users: a new clinical diagnosis. *Bone & Joint Journal* 2011; **93**: 414–417.
15. **Booth MG, et al.** Anthrax infection in drug users. *Lancet* 2010; **375**: 1345–1346.
16. **Sweeney DA, et al.** Anthrax infection. *American Journal of Respiratory and Critical Care Medicine* 2011; **184**: 1333–1341.
17. **Hicks CW, et al.** An overview of anthrax infection including the recently identified form of disease in injection drug users. *Intensive Care Medicine* 2012; **38**: 1092–1104.
18. **Brentall CG.** The medical treatment of anthrax. *Lancet* 1930; **216**: 1174–1177.
19. **Holzmann T, et al.** Fatal anthrax infection in a heroin user from southern Germany, June 2012. *Eurosurveillance* 2012; **17**: 2012.
20. **Hart CA, Beeching NJ.** Prophylactic treatment of anthrax with antibiotics. *British Medical Journal* 2001; **323**: 1017–1018.
21. **Mallon E, McKee PH.** Extraordinary case report: cutaneous anthrax. *American Journal of Dermatopathology* 1997; **19**: 79–82.
22. **Health Protection Scotland.** Clinical algorithm, clinical evaluation and management of drug users with possible anthrax, 2010 (<http://www.documents.hps.scot.nhs.uk/giz/anthrax-outbreak/clinical-algorithm-part-of-clinical-guidance-v12-17032010-asv.pdf>). Accessed 21 April 2014.
23. **Brett MM, et al.** Soft tissue infections caused by spore-forming bacteria in injecting drug users in the United Kingdom. *Epidemiology & Infection* 2005; **133**: 575–582.
24. **McGuigan CC, et al.** Lethal outbreak of infection with *Clostridium novyi* type A and other spore-forming organisms in Scottish injecting drug users. *Journal of Medical Microbiology* 2002; **51**: 971–977.
25. **McLauchlin J, et al.** Amplified fragment length polymorphism (AFLP) analysis of *Clostridium novyi*, *C. perfringens* and *Bacillus cereus* isolated from injecting drug users during 2000. *Journal of Medical Microbiology* 2002; **51**: 990–1000.
26. **Health Protection Scotland.** Interim clinical guidance for the management of suspected anthrax in drug users, 2010 (<http://www.documents.hps.scot.nhs.uk/giz/anthrax-outbreak/clinical-guidance-for-use-of-anthrax-immune-globulin-v12-1-2010-03-19.pdf>). Accessed 4 April 2014.
27. **Brook I, et al.** Clindamycin and quinolone therapy for *Bacillus anthracis* Sterne infection in ⁶⁰Co-gamma-photon-irradiated and sham-irradiated mice. *Journal of Antimicrobial Chemotherapy* 2005; **56**: 1074–1080.
28. **Seaton RA.** Daptomycin: rationale and role in the management of skin and soft tissue infections. *Journal of Antimicrobial Chemotherapy* 2008; **62** (Suppl. 3): iii15–iii23.
29. **Heine HS, et al.** Efficacy of daptomycin against *Bacillus anthracis* in murine model of anthrax spore inhalation. *Antimicrobial Agents & Chemotherapy* 2010; **54**: 4471–4473.
30. **Wiedemann B.** Test results: characterising the antimicrobial activity of daptomycin. *Clinical Microbiology & Infection* 2006; **12** (Suppl. 8): 9–14.

31. **Artenstein AW, et al.** Novel approaches to the treatment of systemic anthrax. *Clinical Infectious Diseases* 2012; **54**: 1148–1161.
32. **Hicks CW, et al.** The potential contributions of lethal and edema toxins to the pathogenesis of anthrax associated shock. *Toxins* 2011; **3**: 1185–1202.
33. **Moayeri M, Leppla SH.** Cellular and systemic effects of anthrax toxin and edema toxin. *Molecular Aspects of Medicine* 2009; **30**: 439–455.
34. **Sweeney DA, et al.** Anthrax lethal and edema toxin produce different patterns of cardiovascular and renal dysfunction and synergistically decrease survival in canines. *Journal of Infectious Diseases* 2010; **202**: 1885–1896.
35. **Kuehnert MJ, et al.** Clinical features that discriminate inhalational anthrax from other acute respiratory illnesses. *Clinical Infectious Diseases* 2003; **36**: 328–336.
36. **Wall DB, et al.** Objective criteria may assist in distinguishing necrotizing fasciitis from nonnecrotizing soft tissue infection. *American Journal of Surgery* 2000; **179**:17–21.
37. **Booth M, et al.** Comparison of survivors and nonsurvivors in 27 confirmed injectional anthrax cases from the 2009 outbreak in Scotland. *Critical Care* 2013; **17** (Suppl. 2): S26.
38. **Shuetz P, Albrich W, Mueller B.** Procalcitonin for diagnosis of infection and guide to antibiotic decisions: past, present and future. *BMC Medicine* 2011; **9**: 107.
39. **Baldari CT, et al.** Anthrax toxins: a paradigm of bacterial immune suppression. *Trends in Immunology* 2006; **27**: 434–440.