



Contents lists available at [ScienceDirect](https://www.sciencedirect.com)

# AAACE Clinical Case Reports

journal homepage: [www.aaaceclinicalcasereports.com](http://www.aaaceclinicalcasereports.com)



## Case Report

# Hyperphosphatemic Tumoral Calcinosis With Pemigatinib Use

Akshan Puar, MBBS<sup>1,\*</sup>, Diane Donegan, MD<sup>1</sup>, Paul Helft, MD<sup>2</sup>, Matthew Kuhar, MD<sup>3</sup>, Jonathan Webster, MD<sup>4</sup>, Megana Rao, BS<sup>4</sup>, Michael Econs, MD<sup>1</sup>



<sup>1</sup> Division of Endocrinology Diabetes and Metabolism, Indiana University School of Medicine, Indianapolis, Indiana

<sup>2</sup> Division of Hematology/Oncology, Indiana University School of Medicine, Indianapolis, Indiana

<sup>3</sup> Department of Pathology, Indiana University School of Medicine, Indianapolis, Indiana

<sup>4</sup> Department of Dermatology, Indiana University School of Medicine, Indianapolis, Indiana

## ARTICLE INFO

### Article history:

Received 27 April 2022

Received in revised form

30 June 2022

Accepted 7 July 2022

Available online 16 July 2022

### Key words:

hyperphosphatemia  
fibroblast growth factor receptor  
fibroblast growth factor 23  
calcification

## ABSTRACT

**Background/Objective:** Pemigatinib, a fibroblast growth factor receptor (FGFR) 1-3 inhibitor, is a novel therapeutic approach for treating cholangiocarcinoma when an FGFR fusion or gene rearrangement is identified. Although the most reported side effect of pemigatinib is hyperphosphatemia, tumoral calcinosis with soft tissue calcifications is not widely recognized as a complication. We report a case of patient with hyperphosphatemic tumoral calcinosis on pemigatinib.

**Case Report:** A 59-year-old woman with progressive metastatic cholangiocarcinoma, despite receiving treatment with cisplatin and gemcitabine for 7 months, was found to have an *FGFR2-BICC1* fusion in the tumor on next-generation sequencing. Pemigatinib was, therefore, initiated. Four months into the therapy, multiple subcutaneous nodules developed over the lower portion of her back, hips, and legs. Punch biopsies revealed deep dermal and subcutaneous calcifications. Investigations revealed elevated serum phosphorus (7.5 mg/dL), normal serum calcium (8.7 mg/dL), and elevated intact fibroblast growth factor-23 (FGF23, 1216 pg/mL; normal value <59 pg/mL) levels. Serum phosphorus levels improved with a low-phosphorus diet and sevelamer. Calcifications regressed with pemigatinib discontinuation.

**Discussion:** Inhibition or deficiency of FGF-23 results in hyperphosphatemia and can lead to ectopic calcification. Pemigatinib, a potent inhibitor of FGFR-1-3, blocks the effect of FGF-23 leading to hyperphosphatemia and tumoral calcinosis as observed in our case. Treatment is aimed primarily at lowering serum phosphate levels through dietary restriction or phosphate binders; however, the regression of tumoral calcinosis can occur with pemigatinib cessation, as seen in this case.

**Conclusion:** As the use of FGFR 1-3 inhibitors becomes more prevalent, we aim to raise attention to the potential side effects of tumoral calcinosis.

© 2022 Published by Elsevier Inc. on behalf of the AAACE. This is an open access article under the CC BY-NC-ND license (<http://creativecommons.org/licenses/by-nc-nd/4.0/>).

## Introduction

Fibroblast growth factor receptor (FGFR) gene fusions or alterations have been implicated in the pathogenesis of cholangiocarcinoma. Pemigatinib, a novel inhibitor of FGFR 1-3, recently received expedited approval for the patients with previously treated, unresectable locally advanced, or metastatic

cholangiocarcinoma with a fibroblast growth factor receptor 2 (FGFR2) fusion or other rearrangements as detected by the US Food and Drug Administration-approved test.<sup>1</sup> Although the most commonly reported side effect of pemigatinib is hyperphosphatemia,<sup>2,3</sup> tumoral calcinosis with soft tissue calcifications is not widely recognized as a complication. Here, we report a case of hyperphosphatemic tumoral calcinosis in a patient treated with pemigatinib.

## Case Report

A 59-year-old woman with metastatic intrahepatic cholangiocarcinoma presented with progression of her malignancy, despite receiving treatment with cisplatin and gemcitabine for 7

**Abbreviations:** FGFR, fibroblast growth factor; FGF-23, fibroblast growth factor-23.

\* Address correspondence to Dr Akshan Puar, Division of Endocrinology Diabetes and Metabolism, Indiana University School of Medicine, 43545, 1120 W, Michigan St, CL 459, Indianapolis, IN 46202.

E-mail address: [puarakshan@gmail.com](mailto:puarakshan@gmail.com) (A. Puar).

months of cisplatin and gemcitabine. Next-generation sequencing identified an *FGFR2-BICC1* fusion in the tumor and pemigatinib was initiated. After 4 months of treatment, the patient noted a progressively worsening rash and multiple flesh-colored nodules over her lower back, hips, and legs. She denied any previous or current trauma to this area. Her skin examination revealed deep indurated subcutaneous nodules with overlying peau d'orange change extending to her posterior thighs in addition to a plaque with a similar appearance on her left lower back. After the initiation of pemigatinib, surveillance computed tomography scans of the chest/abdomen/pelvis demonstrated interval development of subcutaneous calcifications corresponding to the sites of induration (Fig. 1 B and C). She was referred to the dermatology department for further evaluation. Punch biopsies of the nodules and pathologic examination confirmed deep dermal and subcutaneous calcifications (Fig. 2). Hyperphosphatemia (7.5 mg/dL; normal range: 2.5–4.9 mg/dL) was observed shortly after pemigatinib administration, whereas serum calcium level was normal at 8.7 mg/dL, (normal range: 8.5–10.5 mg/dL), albumin level was 3.8 mg/dL (normal range: 3.5–5.5 mg/dL), and creatinine level was 1.01 mg/dL (normal range: 0.6–1.2), respectively. She was referred to the endocrinology department and underwent further investigations, which were performed just before an anticipated seventh cycle of pemigatinib. These investigations demonstrated an elevated intact fibroblast growth factor-23 (FGF-23) level (1216 pg/mL; normal value <59 pg/mL), a low 25 hydroxy-Vitamin D (20 ng/mL; normal range: 30–100 ng/mL), and 1,25-dihydroxy-Vitamin D3 (16.5 pg/mL; normal

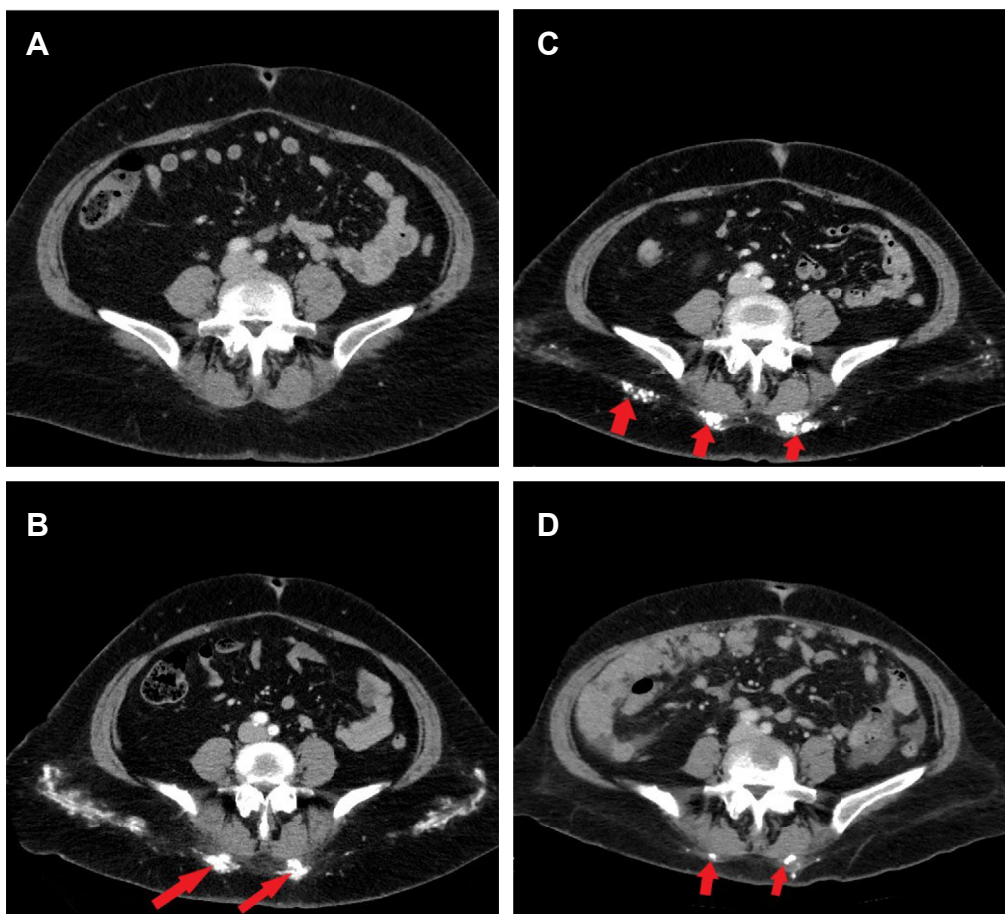
**Highlights**

- A rare case of tumoral calcinosis associated with pemigatinib (FGFR Inhibitor)
- Knowledge of FGFR-23 provides insight into the pathophysiology of cholangiocarcinoma
- Tumoral calcinosis is reversible upon discontinuation of pemigatinib

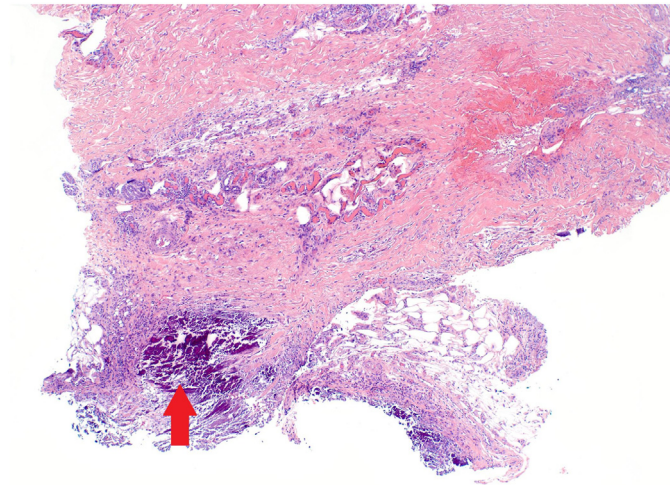
**Clinical Relevance**

FGFR inhibitors have revolutionized the management of certain malignancies; however, this case highlights the development of tumoral calcinosis following the use of pemigatinib. As the use of these medications increases, we want to raise awareness of this uncommon complication but may be prevalent with an increase in usage.

range: 19.9–79.3 pg/mL), although a normal comprehensive metabolic panel revealed an elevated serum calcium level (10.5 mg/dL when albumin was 3.69 mg/dL) and normal serum phosphorus level (3.5 mg/dL).



**Fig. 1.** A–D, Computed tomography scan of abdomen and pelvis with contrast (axial view). A, Before initiating pemigatinib therapy, no visible subcutaneous calcifications are seen in the sacral region, (B) initial demonstration of subcutaneous calcifications after 4 cycles of pemigatinib therapy (arrow), (C) progression of subcutaneous calcifications after 6 cycles of pemigatinib therapy (arrow), and (D) resolution of subcutaneous calcifications 5 months after discontinuation of pemigatinib therapy.



**Fig. 2.** Hematoxylin and eosin section (4-mm skin punch biopsy) from an indurated plaque of the right inner thigh at low magnification (40x) showing significant zones of calcification within the deep dermis (arrow). This was after 5 cycles of pemigatinib therapy.

Given the development of pathologically confirmed subcutaneous calcifications in the presence of an FGFR1-3 inhibitor that causes hyperphosphatemia, the patient was diagnosed with tumoral calcinosis and was started on a low-phosphate diet followed by the addition of sevelamer carbonate leading to a gradual normalization of serum phosphorus levels. Unfortunately, despite pemigatinib therapy, her cancer progressed after 6 months of treatment and was therefore discontinued. Computed tomography scans following the cessation of pemigatinib demonstrated significant regression of tissue calcium deposits on follow-up (Fig. 1 D).

## Discussion

FGF-23, a hormone secreted by osteoblasts and osteocytes, is a key regulator of phosphate and vitamin D homeostasis. The binding of FGF-23 to FGFR-1c and its coreceptor  $\alpha$ Klotho leads to decreased proximal renal tubular phosphate reabsorption resulting in phosphaturia. Additionally, FGF-23 suppresses  $1\alpha$ -hydroxylase transcription necessary for 1,25-dihydroxy-Vitamin D<sub>3</sub> activation.<sup>4</sup> Therefore, the inhibition of FGFR phosphorylation by pemigatinib not only significantly decreases cellular proliferation in target cancer cells with altered FGFR mediated pathways, but also inadvertently blocks the effect of FGF-23 with consequential hyperphosphatemia.<sup>5</sup> The calcium deposition observed in hyperphosphatemic tumoral calcinosis can also be seen in patients with a deficiency of FGF-23 (because of increased cleavage of FGF-23 in *GALNT3* and *FGF23* sequence variations)<sup>6-8</sup> or resistance to FGF-23 (variants in the *KL* gene which encodes the coreceptor  $\alpha$ Klotho)<sup>9</sup> and is related to an increase in the calcium/phosphate product leading to ectopic calcifications.

Clinical trials conducted on patients having pemigatinib showed that, out of 466 patients, 92% developed hyperphosphatemia.<sup>2</sup> Although the prevalence of hyperphosphatemia is common, only 30% of patients required further treatment.<sup>10</sup> Although adverse dermatologic manifestations such as alopecia, dry skin, nail toxicity, and palmar-plantar erythrodysesthesia have been reported with FGFR inhibitors, only 3 cases of ectopic calcifications have been reported in the literature to date.<sup>3,11,12</sup> However, the increasing use of FGFR inhibitors will lead to more cases and, therefore, the recognition of tumoral calcinosis as a potential complication of these medications is important.

Ectopic calcification as observed in hyperphosphatemic tumoral calcinosis or metastatic calcinosis cutis commonly occurs over periarticular (extracapsular) areas and areas of repeated trauma. There can be associated pain and overlying ulceration. If chronic and severe, they can even impair mobility and be debilitating.<sup>8</sup> Phosphate-lowering therapies, including a low-phosphate diet and phosphate binders, are the mainstay of treatment for hyperphosphatemia and have been successful in lowering serum phosphate levels in patients treated with FGFR inhibitors who develop hyperphosphatemia.<sup>11,12</sup> In the setting of familial tumoral calcinosis and other causes of ectopic calcification, additional therapies that have been used include acetazolamide<sup>4</sup> and probenecid.<sup>13</sup> Sodium thiosulfate has shown some success in patients with chronic kidney disease.<sup>4</sup> Patients with associated inflammatory diseases (associated erythema and elevated inflammatory markers) displayed symptomatic improvement with nonsteroidal antiinflammatory drugs, glucocorticoids, and interleukin-1 antagonists (anakinra).<sup>8</sup> However, the efficacy of these alternative therapies has not been reported in the setting of FGFR inhibitor-induced complications. Additionally, 1 case report demonstrated the reversibility of calcium deposits on treatment withdrawal, as also witnessed in our patient. However, this may not always be feasible, if the patient's tumor is responding to pemigatinib therapy.

## Conclusion

Although hyperphosphatemia is a recognized adverse effect of FGFR inhibitors, subsequent tumoral calcinosis is only just gaining recognition. As the use of pemigatinib and other similar FGFR inhibitors increases, tumoral calcinosis may become more prevalent unless close monitoring and aggressive treatment of hyperphosphatemia occur while patients receive these medications.

## Acknowledgment

Informed signed consent was provided by the patient to publish this case.

## Author Contributions

All authors had access to the data and had a role in writing the manuscript. Each author approved the final manuscript as submitted and agree to be accountable for all aspects of the work.

## Disclosure

The authors have no multiplicity of interest to disclose.

## References

1. Abou-Alfa GK, Sahai V, Hollebecque A, et al. Pemigatinib for previously treated, locally advanced or metastatic cholangiocarcinoma: a multicentre, open-label, phase 2 study. *Lancet Oncol.* 2020;21(5):671–684.
2. Bekaii-Saab TS, Valle JW, Van Cutsem E, et al. FIGHT-302: first-line pemigatinib vs gemcitabine plus cisplatin for advanced cholangiocarcinoma with FGFR2 rearrangements. *Future Oncol.* 2020;16(30):2385–2399.
3. Loriot Y, Necchi A, Park SH, et al. Erdafitinib in locally advanced or metastatic urothelial carcinoma. *N Engl J Med.* 2019;381(4):338–348.
4. Boyce AM, Lee AE, Roszko KL, Gafni RI. Hyperphosphatemic tumoral calcinosis: pathogenesis, clinical presentation, and challenges in management. *Front Endocrinol (Lausanne).* 2020;11(293):1–9.
5. Yanochko GM, Vitsky A, Heyen JR, et al. Pan-FGFR inhibition leads to blockade of FGF23 signaling, soft tissue mineralization, and cardiovascular dysfunction. *Toxicol Sci.* 2013;135(2):451–464.
6. Ichikawa S, Baujat G, Seyahi A, et al. Clinical variability of familial tumoral calcinosis caused by novel *GALNT3* mutations. *Am J Med Genet A.* 2010;152A(4):896–903.

7. Larsson T, Yu X, Davis SI, et al. A novel recessive mutation in fibroblast growth factor-23 causes familial tumoral calcinosis. *J Clin Endocrinol Metab.* 2005;90(4):2424–2427.
8. Ramnitz MS, Gourh P, Goldbach-Mansky R, et al. Phenotypic and genotypic characterization and treatment of a cohort with familial tumoral calcinosis/hyperostosis-hyperphosphatemia syndrome. *J Bone Miner Res.* 2016;31(10):1845–1854.
9. Ichikawa S, Imel EA, Kreiter ML, et al. A homozygous missense mutation in human KLOTHO causes severe tumoral calcinosis. *J Clin Invest.* 2007;117(9):2684–2691.
10. Hoy SM. Pemigatinib: First approval. *Drugs.* 2020;80(9):923–929.
11. Arudra K, Patel R, Tetzlaff MT, et al. Calcinosis cutis dermatologic toxicity associated with fibroblast growth factor receptor inhibitor for the treatment of Wilms tumor. *J Cutan Pathol.* 2018;45(10):786–790.
12. Lopez-Castillo D, March-Rodriguez A, Rodriguez-Vida A, Pujol RM, Segura S. Metastatic calcinosis cutis secondary to selective fibroblast growth factor receptor inhibitor: rapid and complete regression after blood phosphate normalization and drug withdrawal. *Acta Derm Venereol.* 2020;100(6), adv00079.
13. Eddy MC, Leelawattana R, McAlister WH, Whyte MP. Calcinosis universalis complicating juvenile dermatomyositis: resolution during probenecid therapy. *J Clin Endocrinol Metab.* 1997;82(11):3536–3542.