

Available online at www.sciencedirect.com

ScienceDirect

journal homepage: www.elsevier.com/locate/radcr

Case Report

Ossicular osteoma of the malleus—A rare diagnosis of middle ear mass ☆

Matti Sievert, MD^a, Konstantinos Mantsopoulos, MD^a, Joachim Hornung, MD^a, Vivian Thimsen, MD^a, Rafael Heiss, MD^b, Markus Kopp, MD^b, Matthias Wetzl, MD^b, Heinrich Iro, MD^a, Michael Uder, MD^b, Marco Wiesmueller, MD^{b,*}

^aDepartment of Otorhinolaryngology, Head and Neck Surgery, University Hospital Erlangen, Friedrich-Alexander-University Erlangen-Nürnberg, Waldstraße 1, 91054 Erlangen, Germany

^bInstitute of Radiology, University Hospital Erlangen, Friedrich-Alexander-University Erlangen-Nürnberg, Maximiliansplatz 3, 91054, Erlangen, Germany

ARTICLE INFO

Article history:

Received 10 August 2022

Revised 17 August 2022

Accepted 21 August 2022

Available online 16 September 2022

Keywords:

Middle ear osteoma
Temporal bone osteoma
Computed tomography
Conductive hearing loss
Middle ear lesion

ABSTRACT

Osteoma of the middle ear (MEO) is a rarity. Due to the benign nature and slow growth rate, MEO are often occasionally found by chance. Possible unspecific clinical symptoms may be conductive hearing loss, tinnitus, effusion, and a sense of fullness. If the osteoma is small and not visible in the otoscopic inspection, it may be confused with other conductive hearing loss etiologies, such as otosclerosis. Nevertheless, one should be aware of this rare but important differential diagnosis of middle ear lesions. This article presents an MEO case causing conductive hearing loss and outlines the diagnostic approach with computed tomography.

© 2022 The Authors. Published by Elsevier Inc. on behalf of University of Washington.

This is an open access article under the CC BY-NC-ND license

(<http://creativecommons.org/licenses/by-nc-nd/4.0/>)

Introduction

Osteomas are slow-growing, benign tumors comprised of mature bone. An otolaryngologist primarily finds osteomas in the paranasal sinus region. In the temporal bone, osteomas occur mainly in the external auditory canal or the mastoid as unilateral, solitary lesions arising from the tympanic bone [1,2]. So far, manifestation in the middle ear is rare and has

been described only in a few cases [3]. The promontory, middle ear ossicles, and epitympanum are typically affected. The symptoms of a middle ear osteoma (MEO) vary depending on its location. The most frequent symptom of conductive hearing loss is caused by inhibition of the eardrum and ossicular chain's vibratory capacity or Eustachian tube obliteration with subsequent effusion [4]. A combined hearing loss due to contact and overgrowth of the incus and stapes or facial nerve palsy has been reported [5,6]. Due to the complaints, and rare asymptomatic courses, the majority of MEO patients underwent tympanoplasty. However, watchful waiting was also de-

Abbreviations: MEO, middle ear osteoma; CT, computed tomography; HU, Hounsfield units.

☆ Competing Interests: The authors declare no conflicts.

* Corresponding author.

E-mail address: marco.wiesmueller@uk-erlangen.de (M. Wiesmueller).

<https://doi.org/10.1016/j.radcr.2022.08.083>

1930-0433/© 2022 The Authors. Published by Elsevier Inc. on behalf of University of Washington. This is an open access article under the CC BY-NC-ND license (<http://creativecommons.org/licenses/by-nc-nd/4.0/>)

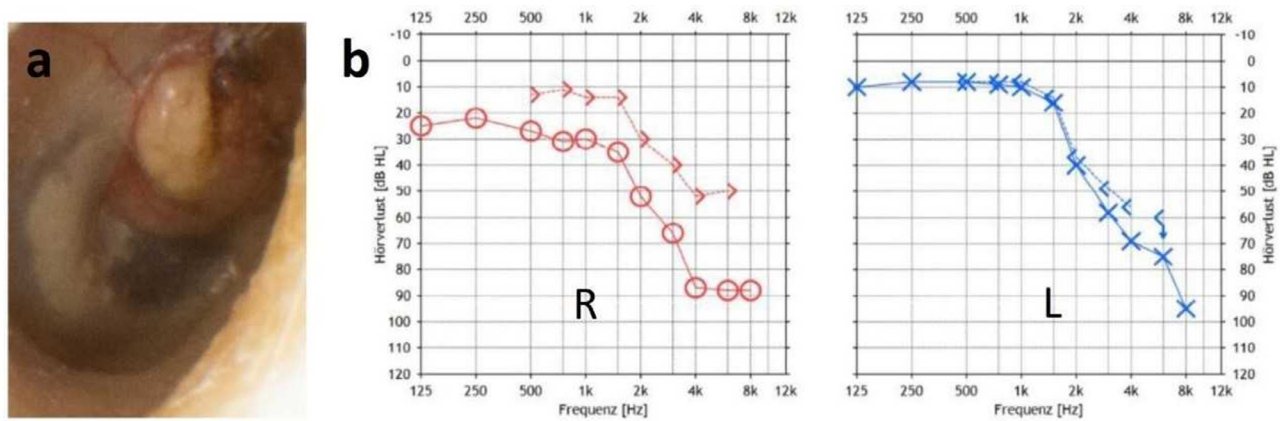


Fig 1 – (A) Otoscopic findings of an osteoma of the right handle of the malleus. A white mass behind the intact tympanic membrane with a smooth surface is visible. (B) Pure tone audiometry indicates a combined hearing loss on the right with a conductive component of 20 dB, in known presbycusis.

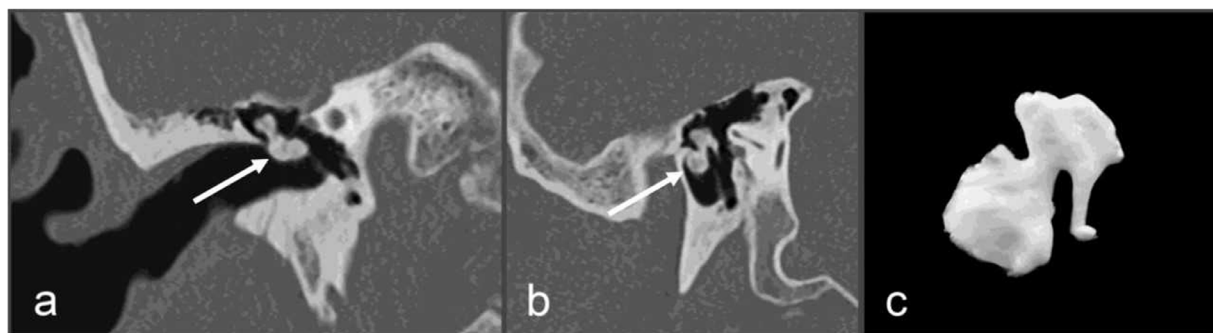


Fig 2 – (A, B) Multiplanar reconstruction of the right middle ear illustrating the auditory ossicle chain and an adjacent high-density mass (white arrows) with a small link to the malleus and with bulging of the tympanic membrane. (C) Snapshot of the high-resolution 3-dimensional reconstruction of the auditory ossicle chain and the suspected malleus osteoma.

scribed in some cases [3]. Alternatively to primary invasive tympanoplasty or watchful waiting, computed tomography (CT) is a reliable diagnostic tool to narrow the different diagnostic possibilities, mainly due to its wide availability and its superior spatial resolution [4,7,8].

Case report

We present the case of a 73-year-old man with bilateral presbycusis and hearing aid supply who was initially diagnosed with cholesteatoma by the resident otolaryngologist after clinical inspection. The occasion for the consultation was a hearing impairment on the right side. The patient had no recurring episodes of otorrhea, vertigo, or facial nerve palsy. Tone audiometry shows a combined hearing loss on the right side with a conductive component of 20 dB. On the left side, there is sensorineural hearing loss (Fig. 1B). The Weber test lateralizes to the right. Rinne's test was positive on both sides. Otoscopy revealed a white mass behind the intact tympanic membrane, resulting in a lateral

bulge (Fig. 1A). Vestibular examinations were without a pathological finding. Since the history and absence of a tympanic membrane defect was inconsistent with the initial diagnosis of cholesteatoma, we performed a CT scan of the temporal bone for further diagnosis. The CT scan revealed a lesion in the right middle ear space (handle of malleus) with high-density values, suggesting calcified or bony components (mean value 930 ± 115 Hounsfield Units (HU)). Erosion of the adjacent bone was absent. By comparison, the right temporal squama's density values were 1100 ± 95 HU, confirming the middle ear lesion's bony composition. A closer review of 3D CT data illustrated a small link to the adjacent malleus (Fig. 2).

In summary, both clinical inspection and CT examinations led to an MEO diagnosis of the malleus. We discussed the possibility of an explorative tympanoscopy or tympanoplasty to confirm the diagnosis and improve the conductive hearing impairment. Due to additional existing presbycusis (Fig. 1B), the patient already had a bilateral hearing aid fitting supply at presentation. As the patient was satisfied with his hearing aid supply and was unwilling to undergo surgery, we agreed to provide follow-up examinations.

Discussion

Temporal bone osteomas are rare, benign neoplasms consisting of lamellar bone masses [9]. The most frequent manifestation in the temporal bone area is the external auditory canal [10]. Typically, these tumors appear solitary and unilateral. Manifestation at the middle ear's ossicles is rare and described in only a few cases. The diagnosis was easily confirmed by a routine CT of the temporal bone due to its high spatial resolution and the possibility to determine if a mass is made of bone. The most common otoscopic differential diagnosis is a cholesteatoma, but this entity would appear typically different in CT without high-density values and would probably erode the adjacent ossicles [11]. Finally, malignant lesions should always be precluded in cases of unclear middle ear masses. CT proves to be a valid method for differential diagnosis in this context, as other lesions exhibit different image features with much lower density values and chronic inflammation or malignancy suspicious osseous destruction. Alternatively, tympanoscopy, resection, and subsequent histopathological confirmation can also prove the diagnosis [12].

In summary, osteoma of the ossicles is an infrequent differential diagnosis of a space-occupying middle ear process with conductive hearing loss. The diagnosis can be verified by a high-resolution CT scan of the temporal bone.

Patient consent

Informed consent was obtained from the patient for use of anonymized clinical and radiological information.

REFERENCES

- [1] Cho YS, Joon HK, Sung HH, Chung WH. A huge osteoma of the middle ear. *Int J Pediatr Otorhinolaryngol* 2005;69:1569–74.
- [2] Yamasoba T, Harada T, Okuno T, Nomura Y. Osteoma of the middle ear: report of a case. *Arch Otolaryngol Neck Surg* 1990;116:1214–16.
- [3] Temirbekov D, Celikyurt C. Middle ear osteoma causing Eustachian tube obstruction: a case report and literature review. *J Otol* 2020;15:161–5.
- [4] Vérillaud B, Guilleré L, Williams MT, El Bakkouri W, Ayache D. Middle ear osteoma: a rare cause of conductive hearing loss with normal tympanic membrane. *Rev Laryngol Otol Rhinol* 2011;132:159–61.
- [5] Molher J, De Mones Del Pujol E, Do Santos Zounon A, Darrouzet V, Bonnard D. Middle ear osteoma causing mixed hearing loss: a case report. *J Int Adv Otol* 2018;14:493–6.
- [6] Curtis K, Bance M, Carter M, Hong P. Middle ear osteoma causing progressive facial nerve weakness: a case report. *J Med Case Rep* 2014;8:310.
- [7] Nguyen T, Pulickal G, Singh A, Lingam R. Conductive hearing loss with a “dry middle ear cleft”—a comprehensive pictorial review with CT. *Eur J Radiol* 2019;110:74–80.
- [8] Hiraumi H, Obara M, Yoshioka K, Ehara S, Sato H. Detectability of minute temporal bone structures with ultra-high resolution CT. *Auris Nasus Larynx* 2019;46:830–5.
- [9] Yuan W, Chen L, Jiang X, Zhang X. Osteoma of stapes in the middle ear: a case report. *Otol Neurotol* 2013;34:119–20.
- [10] Carbone PN, Nelson BL. External auditory osteoma. *Head Neck Pathol* 2012;6:244–6.
- [11] Gaurano JL, Joharjy IA. Middle ear cholesteatoma: characteristic CT findings in 64 patients. *Ann Saudi Med* 2004;24:442–7.
- [12] Kim CW, Oh SJ, Kang JM, Ahn HY. Multiple osteomas in the middle ear. *Eur Arch Otorhinolaryngol* 2006;263:1151–4.