




Elsevier has created a [Monkeypox Information Center](#) in response to the declared public health emergency of international concern, with free information in English on the monkeypox virus. The Monkeypox Information Center is hosted on Elsevier Connect, the company's public news and information website.

Elsevier hereby grants permission to make all its monkeypox related research that is available on the Monkeypox Information Center - including this research content - immediately available in publicly funded repositories, with rights for unrestricted research re-use and analyses in any form or by any means with acknowledgement of the original source. These permissions are granted for free by Elsevier for as long as the Monkeypox Information Center remains active.



## New challenges in human monkeypox outside Africa: A review and case report from Italy

Davide Mileto<sup>a</sup>, Agostino Riva<sup>b,c</sup>, Miriam Cutrera<sup>a</sup>, Davide Moschese<sup>d</sup>, Alessandro Mancon<sup>a</sup>, Luca Meroni<sup>c</sup>, Andrea Giacomelli<sup>c</sup>, Giovanna Bestetti<sup>c</sup>, Giuliano Rizzardini<sup>d</sup>, Maria Rita Gismondo<sup>a,b</sup>, Spinello Antinori<sup>b,c,\*</sup>

<sup>a</sup> Clinical Microbiology, Virology and Bioemergency Diagnostics, ASST Fatebenefratelli Sacco, Luigi Sacco Hospital, Milan, Italy

<sup>b</sup> Department of Biomedical and Clinical Sciences, Università Degli Studi di Milano, Italy

<sup>c</sup> III Division of Infectious Diseases, ASST Fatebenefratelli Sacco, Luigi Sacco Hospital, Milan, Italy

<sup>d</sup> I Division of Infectious Diseases, ASST Fatebenefratelli Sacco, Luigi Sacco Hospital, Milan, Italy

### ARTICLE INFO

**Keywords:**  
Monkeypox  
Outbreak  
HIV  
Italy  
Diagnosis

### ABSTRACT

**Background:** Human monkeypox (MPX) is a neglected zoonotic disease caused by the MPX virus a double-stranded DNA virus which belongs to the Poxviridae family genus *Orthopoxvirus*. It is endemic in the rural rainforests of Central and Western Africa where it is responsible of human sporadic cases and outbreaks since 1970. Outside Africa MPXV caused an outbreak in 2003 in the United States linked to importation of infected rodents from Ghana and a few travel-related cases in the USA, United Kingdom, Israel and Singapore. Actually, a worldwide outbreak with more than 1200 confirmed cases mainly concentrated among men who have sex with men is ongoing.

**Case report:** We present the case of an Italian man living in Portugal that was diagnosed with MPX at our clinic in Milan, Italy. *Monkeypox virus* infection was confirmed by a specific homemade Real-Time PCR. Samples obtained from different sites (pharynx, skin lesions, anal ulcer, seminal fluid) turned all positive with different viral load.

**Conclusions:** Our report illustrates the challenge of a disease that seems to present in a different way from classic description with possible human-to-human transmission through sexual contact.

### 1. Introduction

Monkeypox (MPX) is a neglected zoonosis endemic in the tropical rain forests of Central and West Africa [1]. Monkeypox virus (MPXV) was first identified in 1958 in *Cynomolgus* monkeys in Denmark but nonhuman primates are considered “incidental” hosts in the same way of human beings with rodents and other small mammals actually considered (although unproven) the natural hosts [2]. The first human case was reported in 1970 in a 9-month child admitted for suspected smallpox to the Basankusu hospital in the Democratic Republic of Congo (DRC) [3]. Soon after six cases of human infection with MPXV were identified in one adult and five unvaccinated children in Liberia, Sierra Leone and Nigeria with isolation of an identical virus [4,5]. Since then several outbreaks of human monkeypox have been regularly reported in Equatorial Africa especially in DRC and Nigeria [6–9]. However, in recent years an increasing number of suspected and confirmed cases has

been reported with over 19,000 cases in the period 2000–2019 according to a systematic review of the literature [10] and 15,600 cases in 2021–2022 according to the WHO Bulletin [11,12]. Outside Africa a large multistate outbreak with 71 confirmed and suspected cases was described in 2003 in the USA linked to importation of infected animals from Ghana [13]. Sporadic cases associated with travels to Africa have been observed in the United Kingdom (UK), USA, Singapore and Israel [14–18]. However, starting from 7, May 2022, nearly contemporary cases of human MPX apparently not linked with travel to Africa were reported from 13 countries in Europe (UK, Portugal, Spain, Italy, France, Germany, Belgium, Austria, Denmark, Slovenia, Sweden and Czech Republic), Canada, USA, Australia, Israel [19].

We present the case of a patient diagnosed with human MPX infection in Milan, Italy on May 24. We also made a review of monkeypox diagnosed in Africa and outside Africa with a discussion of many of the challenges faced by clinicians in non-endemic countries who provide

\* Corresponding author. Department of Biomedical and Clinical Sciences, Università degli Studi di Milano, Via GB Grassi 74, 20157, Milano, Italy.

E-mail address: [spinello.antinori@unimi.it](mailto:spinello.antinori@unimi.it) (S. Antinori).

<https://doi.org/10.1016/j.tmaid.2022.102386>

Received 9 June 2022; Received in revised form 13 June 2022; Accepted 16 June 2022

Available online 20 June 2022

1477-8939/© 2022 Elsevier Ltd. All rights reserved.

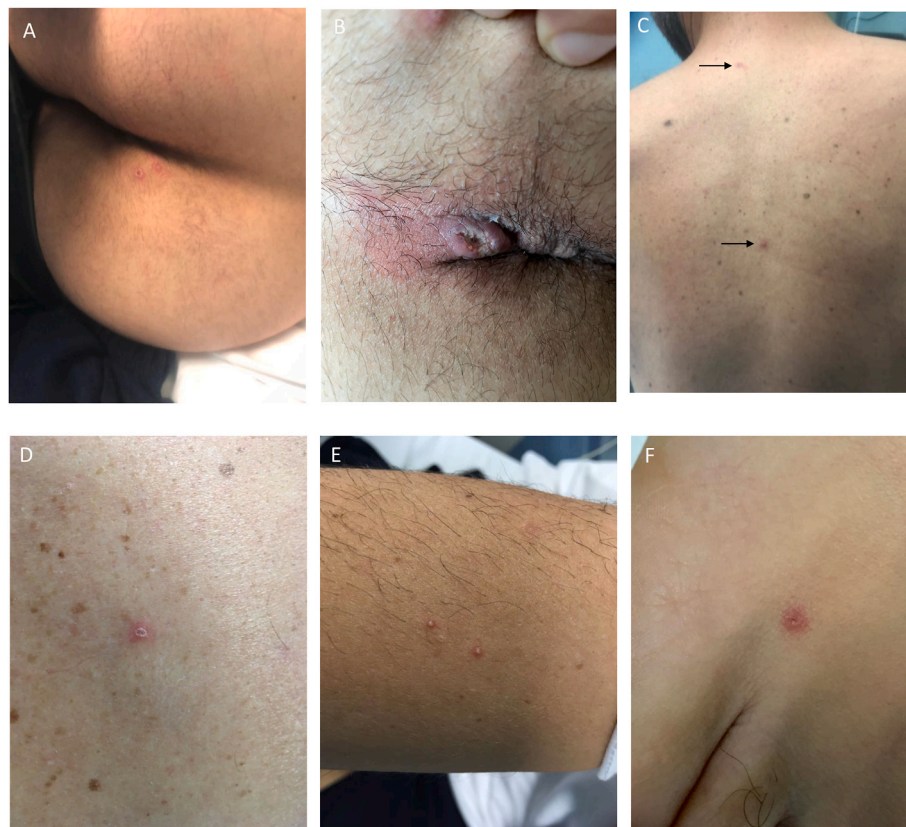care for patients with MPX.

## 2. Patient case presentation

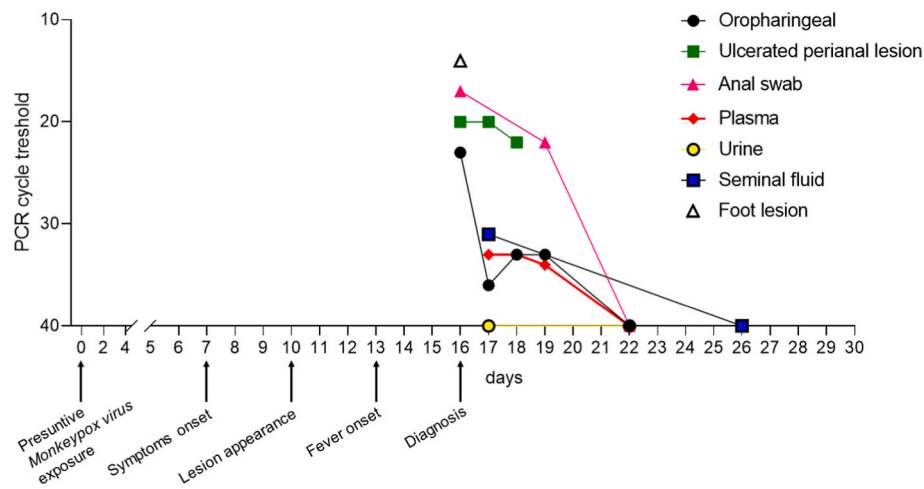
A 33-year old Italian man attended our clinic on May 24th at Luigi Sacco Hospital in Milan, Italy to investigate a perianal lesion that appeared a few days before. He was living in Lisbon (Portugal) since January 2022 and returned to Italy on May 18th. His past medical history was notable for HIV infection diagnosed in 2016 that was under treatment with dolutegravir/rilpivirine 50/25 mg with good viro-immunological response (CD4<sup>+</sup> lymphocyte 771 cell/ $\mu$ L, HIV-RNA < 20 cp/mL). He was fully vaccinated against COVID-19 (two doses of Comirnaty and one dose of Moderna mRNA vaccines). In the previous six months he had travelled only once for a week in January 2022 to Madrid. On May 15th he complained of asthenia, malaise, anorexia with the appearance of two small papular lesions on both elbows and an ulcerated perianal lesion; 3 days later (May 18th) a new lesion appeared on the right cheek associated with symptoms involving the upper respiratory tract (faryngodynia and sneezing). Before flying to Italy he underwent a nasopharyngeal swab for SARS-CoV-2 that resulted negative. On May 21 he complained of the appearance of fever (38.5 °C) with spontaneous resolution in one day. On May 24th he presented to our ward complaining of pain in the perianal region. He reported a receptive anal intercourse on May 8th with a casual partner in Lisbon. On physical examination he appeared in good clinical condition with the following parameters: blood pressure 100/55 mm Hg; pulse rate 105/min; oxygen saturation 95% on ambient air. Mild oropharyngeal hyperemia and several scattered skin lesions with different stage of evolution were observed on the face, both elbows, the trunk, the buttock and the right foot (total number of lesions <10) (Fig. 1A–F). Bilateral inguinal lymphadenopathy was confirmed by means of ultrasound. Blood test were all within normal limits with the exception of moderate

thrombocytopenia (146,000/ $\mu$ L) and mild increase of C-reactive protein (30 mg/L). He underwent a rectal swab for research of sexually transmitted agents (herpes simplex virus, *Chlamydia trachomatis* and *Neisseria gonorrhoeae*) using a real-time PCR that gave negative results. Swabs taken from the oropharynx, anus, the perianal ulcerated lesion, a foot vesicle and plasma at the time of hospital admission turned positive for non-human *Orthopoxvirus* (as depicted in Fig. 2 and Table 1) with subsequent confirmation of MPXV infection. The specimens from skin lesion and oropharyngeal swab were collected by mean of Universal Transport Medium swabs (UTM-RT®; COPAN Diagnostics, Italy). Sterile screw cap containers were used to collect urine and seminal fluid while blood samples were collected in the BD Vacutainer® K2EDTA tube and Thrombin tube to obtain plasma and serum respectively. The DNA was extracted from 200  $\mu$ L of sample and eluted in 100  $\mu$ L using the automated ELITE InGenius® system.

Real-time Polymerase Chain Reaction (PCR) [RealStar Orthopoxvirus PCR Kit 1.0 – altona DIAGNOSTICS) targeting *variola virus* and non-variola Orthopoxvirus species (*Cowpox virus*, *Monkeypox virus*, *Raccoonpox virus*, *Camelpox virus*, *Vaccinia virus*] was used as *Orthopoxvirus* screening PCR. *Monkeypox virus* infection was confirmed by a specific homemade Real-Time PCR performed on *Orthopoxvirus* screening PCR positive samples as previously described [20]. Sampling was repeated on a daily basis to evaluate viral load variation in terms of Cycle threshold (Ct) values over time, viral shedding and virus clearance collecting also plasma, urine and seminal fluid (Fig. 2). All the positive samples were used to attempt viral isolation. In brief, a 200  $\mu$ L aliquot of each sample was plated in duplicate in 24-wells plates containing 80%–90% confluent Vero E6 cells with 800  $\mu$ L of Dulbecco's Modified Eagle Medium with L-glutamine (Gibco™ ThermoFisher Scientific) supplemented with 2% of heat-inactivated fetal bovine serum (Gibco™ ThermoFisher Scientific) and 1% Penicillin-Streptomycin [5000 U mL<sup>-1</sup>] (Pen-Strep, Gibco™ ThermoFisher Scientific). Plates was incubated at



**Fig. 1.** A–E. Skin lesions with different appearance obtained at time of diagnosis of MPX. A, buttock. B, perianal ulcerated lesion. C, trunk. D, one of the trunk lesions at major magnification. E, two vesicula/pustular lesion of the arm. F, one foot lesion. Arrows indicate two lesions of the trunk.



**Fig. 2.** Clinical and virological timeline of the patient affected by monkeypox. Real-Time PCR cycle threshold value indicates the number of PCR cycle required to a positive result. The value is inversely proportional to the viral DNA. Ct value of 40 cycle is the PCR negative cut-off.

37 °C and 5% CO<sub>2</sub> atmospheric pressure and checked every 24 h. Cytopathic effect was observed in Vero E6 cells showing typical monolayer separation and cell rounding (Fig. 3).

The patient was isolated in a negative-pressure room and remained well throughout admission until discharge. He was examined daily for new skin lesions and was discharged to home on day 7 of hospitalization. The patient was instructed to remain isolated in his residence until all skin lesions recovered. During follow-up the RT-PCR turned negative on all examined specimens except the last oropharyngeal swab which showed a Ct of 35.

### 2.1. Search strategy and selection criteria

We undertook a search of PubMed from Jan 1, 1970 to June 3, 2022, with no language restriction using the following search terms: “Monkeypox”, “Monkeypox virus”, “Imported monkeypox”, “Monkeypox and Africa”, “Monkeypox and travel”, “Monkeypox and Europe”, “Monkeypox outbreak”, “Monkeypox reservoir”, “Monkeypox and treatment”. We selected key references and seminal papers, review articles, patient reports. We also reviewed publications from international organizations such as the WHO, ECDC and CDC. We completed manual search with references from selected reports.

## 3. Review and discussion

### 3.1. Monkeypox virus

MPXV was first identified in 1959 in Copenhagen (Denmark) in captive cynomolgus monkeys (*Macaca fascicularis*) shipped from Singapore and showing a pox-like disease [2]. Subsequently the causal agent named MPXV has been recovered in outbreaks of illness involving monkeys or apes in the USA, The Netherland and France [4,21]. However, MPX is considered a misnomer because monkeys are not the natural reservoir of the virus with small rodents considered although not proved the probable animal reservoir. Till now the virus has been isolated in wild animals only twice: in 1985 in DRC in a rope squirrel (*Funisciurus anerythrus*) and in 2012 in a sooty mangabey (*Cercocebus atys*) in Ivory Coast [22,23]. The virus belongs to the Poxviridae family genus *Orthopoxvirus* with a double-stranded DNA genome with approximately 200,000 base pairs. On electron microscopy observation the virus shows a brick-like shape measuring 200–400 nm. Genomic sequencing of MPXV isolates from cases diagnosed in Western and Central Africa and during the 2003 USA outbreak showed the existence of two clades: the West Africa clade and the Central Africa (Congo basin) clade [24–26]. Difference in pathogenicity has been observed with a

milder disease and a better outcome associated with the West Africa clade in comparison with the Congo basin clade [10,25]. D14L encoding VCP-MPXV an ortholog VACV complement binding protein has been proposed as a candidate virulence gene [25]. Interestingly the first published genome sequence of MPXV associated with the actual multi-country outbreak indicates that the virus belongs to the West African clade [27,28]. MPXV is considered endemic in ten countries of the tropical rain forests of Africa (DRC, Republic of Congo, Nigeria, Central African Republic, Cameroon, Liberia, Sierra Leone, Ivory Coast, South Sudan) [1,9,10]. Humans can be infected from either a direct contact or a bite/scratch with an infected animal (i.e. primary zoonotic transmission) or by human-to-human transmission [29–31]. Activities such as hunting or butchering of bushmeat are considered as risk factors for primary zoonotic acquisition of MPXV [7,10,32]. Transmission of MPXV occurs through salivary or respiratory droplets, direct contact with skin lesions and with fomites. Among previous imported cases in UK both household and nosocomial infections were observed [14]. Secondary attack rate reported in the literature is extremely variable and seems to be influenced by several variables such as the geographic area involved by the outbreak, the period of study, a history of previous vaccination against smallpox and the degree of contact [7,33–36]. In the first survey of human MPX cases diagnosed in West and Central Africa (mainly in DRC) during the first decade of ‘70s, Breman et al. reported an overall secondary attack rate of 3.3% but it increased to 7.7% among very close family members [33]. A subsequent study conducted in DRC assessing more than two thousand people with close contacts with monkeypox patients showed an overall 3% probability to become infected from a human source [34]. However, the attack rate increased to 7.5% among unvaccinated persons, to 9.3% among unvaccinated household contact and to 11.7% among household contact in the 0–4 year age group [34]. Independently from history of smallpox vaccination, household contacts had a significantly higher attack rate than for other contacts being four times higher for unvaccinated and seven times higher for vaccinated [35]. Another study conducted in DRC during a 1996–1997 outbreak reported a household secondary attack rate of 8.3% [7]. More recently the median attack rate in an outbreak in DRC was reported to be 50% [36]. Sexual transmission of MPXV has never been demonstrated but it is hypothesized based on previous reports of vaccinia transmission through sexual intercourses and the high rate of genital lesions (68%) observed among monkeypox cases in Nigeria [37–40]. The incubation period of human monkeypox is not well characterized although it is generally reported to be in the range of 10–14 days [41]. Experts joining at a WHO meeting in 1984 indicated in cases of human-to-human transmission an interval between contacts and onset of rash ranging between 7 and 23 days [42]. More recently during an outbreak of

**Table 1**  
Timeline of Polymerase Chain Reaction (PCR) for monkeypox virus and virus isolation.

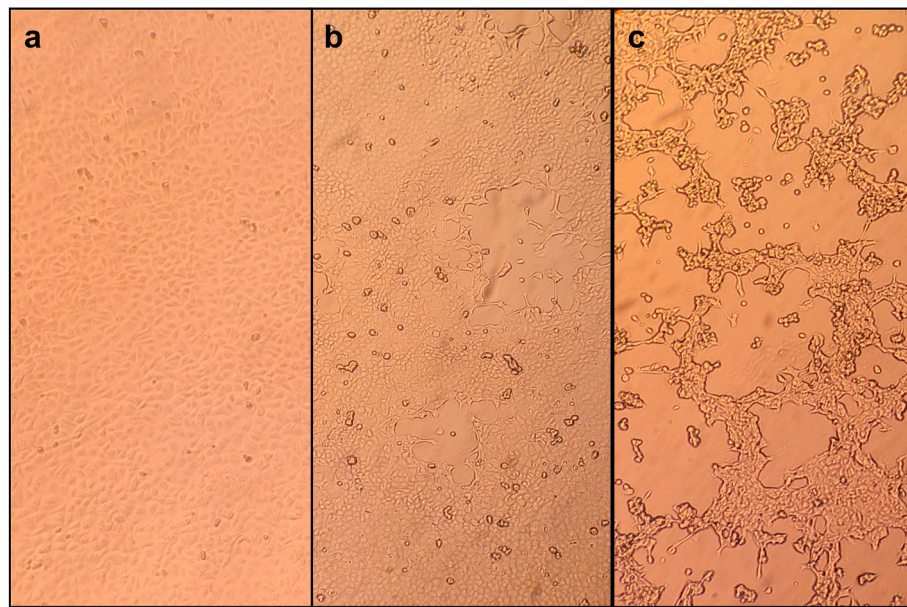
Days from symptoms onset	Oropharyngeal swab		Ulcerated perianal lesion		Anal swab		Foot lesion		Plasma		Seminal fluid		Urine	
	PCR cycle threshold	Viral Isolation	PCR cycle threshold	Viral Isolation	PCR cycle threshold	Viral Isolation	PCR cycle threshold	Viral Isolation	PCR cycle threshold	Viral Isolation	PCR cycle threshold	Viral Isolation	PCR cycle threshold	Cell culture
9	23	Positive	20	Positive	17	Positive	14	Positive			n.a.	/	n.a.	/
10	36	Negative	20	Positive	n.a.	/	n.a.	/	33	Negative	31	Negative	Negative	/
11	33	Negative	22	Positive	n.a.	/	n.a.	/	33	Negative	n.a.	/	n.a.	/
12	33	Negative	n.a.	/	22	Positive	n.a.	/	34	Negative	n.a.	/	n.a.	/
15	Negative	/	n.a.	/	Negative	/	n.a.	/	Negative	/	n.a.	/	Negative	/
19	35	a.o.	n.a.	/	Negative	/	n.a.	/	Negative	/	n.a.	/	Negative	/

List of abbreviations: n.a., not available; a.o., analysis ongoing; Polymerase Chain Reaction, PCR.

monkeypox in Nigeria the reported exposure to another patient before the onset of the disease was 7–21 days in 73% of subjects for whom this information was available [7]. Finally, in a study using either cases described in the literature with well defined incubation period and their own well characterized cases Nolen and coworkers provided indication of a median incubation period of 9 days with 75% of patients having an incubation period of 5–12 days [36]. A significant increase of the number of individual outbreak reports in Africa has been observed since 1970 [9,10,43]. Particularly in the DRC a 20-fold increase was observed between 1981–1986 and 2006–2007 with an average annual cumulative incidence of 5.53 per 10,000 [43]. Interestingly, the median age of presentation increased from 4 years (in the 70s) to the actual 21 years (2010–2019) [10]. Several possible explanations for the increasing number of monkeypox outbreaks have been proposed: enhanced surveillance system with improved reporting of cases [10,44]; deforestation with increasing exposure to animal reservoir harboring monkeypox virus thus providing more opportunities for zoonotic transmission [45–47]; declining vaccine coverage against smallpox with decreased herd immunity against poxviruses [30,43,46,48]; genetic evolution of MPXV with increased capacity of human-to-human transmission [49]. Old calculation of the basic reproduction number using data collected in the DRC in 1980–1984 resulted in a  $R_0$  of 0.81 with a net reproduction number ( $R_{net}$ ) of 0.3 and an upper limit of 1.0 thus not excluding the possibility of MPXV persistence in the human population [30]. Another study again performed in DRC with data collected in 2006–2007 calculated an  $R_{net}$  of 0.6 [49]. However, researchers from Pasteur using the data of 85% vaccine protection (induced by smallpox vaccine) calculated an  $R_0$  for monkeypox in DRC of 2.13 (uncertainty bounds 1.46–2.67) [50]. A new proposed model consisting of eight mutually exclusive compartments five of which regarding the human population (exposed and isolated humans, exposed population, infected humans and recovered humans) and three the rodent population (exposed, susceptible and infected rodents) provided evidence that isolation of infected humans helps to reduce disease transmission [51].

### 3.2. Monkeypox in West and Central Africa

Since the first recognized case of human monkeypox in the DRC on the wake of smallpox eradication MPXV has been responsible of regular outbreaks especially in rural communities of central and western Africa with possible expanding frequency and geographic extension in the last decade [1,3,6–10]. However, the disease is mostly neglected and our knowledge about transmission, clinical manifestations and outcome are largely derived from a few old studies [30,33,52,53] and even in recent studies important information are lacking [7,8,40,54,55] (Table 2). The appearance of rash is considered a distinctive feature of human MPXV present in all the patients [7,8,33,40,53–55] although in some studies its presence was inferred only retrospectively from the residual skin scars [7,54]. The rash is reported to be similar to that of smallpox with monomorphic lesions and centrifugal distribution thus fairly different from that observed in chickenpox [56]. However, such description is based on the classic studies conducted by Jezek and coworkers during the 80s [52,53] and a more recent study reported a pleomorphic characteristic of the rash in nearly 38% of patients being even more frequent among people living with HIV infection [40]. Moreover, it should be highlighted that cases identified as probable MPXV might be indeed cases of chickenpox [54,57]. In the outbreak of Kasai Oriental in 1996–1997 testing of skin lesion vesicles in nineteen patients identified MPXV in nine cases and varicella zoster virus (VZV) in four cases [54]. The investigation of seven outbreaks observed in DRC in 2001 showed that two were caused only by VZV and in another two both MPXV and VZV were involved [57]. However, also the opposite can be true with cases diagnosed as chickenpox that are instead MPXV [58]. In a recent study conducted in DRC 12.1% of suspected MPX cases were confirmed MPX/chickenpox coinfections and such patients presented significant higher lesion counts than patients with chickenpox [59]. The rash of



**Fig. 3.** Isolation of Monkeypox virus in Vero E6 cells from skin lesions and oropharyngeal swab. a: mock-infected Vero E6 cells; b: Vero E6 cells at 3 days post-infection; c: Vero E6 cells at 6 days post-infection.

**Table 2**  
Clinical characteristics of human monkeypox infection in West and Central Africa.

Author [reference]	Breman [33]	Jezek [53]	Hutin [7]	CDC [54]	Formenty [55]	Yinka-Ogunleye [8]	Ogoina [40]
Country (ies)	DRC, Liberia, Sierra Leone, Nigeria, Ivory Coast	DRC (ex Zaire)	DRC (ex Zaire)	DRC (ex Zaire)	Sudan	Nigeria	Nigeria
Year	1970–1979	1981–1986	1996–1997	1996–1997	2005–2006	2017–2018	2017–2018
N° of cases/Confirmed/ Probable cases	47/37/10	338/NR/NR	88/7/81	344/NR/NR	19/10/9	122/118/4	40/NR/NR
Male gender (%)	24 (51.1)	182 (53.8)	50 (56.8)	NR	9 (47.4)	84 (69)	31 (77.5)
Age, median (range)	4y (7 mo–40y)	4.4y (3mo–69y)	10y (1mo–62y)	NR	NR (8mo–32y)	29 (2d–50y)	32y (28d–54y)
Previous smallpox vaccination	4 (8.5%)	43 (13%)	13/84 (15.5)	39 (11.3)	NR	NR	NR
Rash (%)	47 (100%)	338 (100)	82/82 (100)	344 (100)	19 (100)	122 (100)	40 (100)
Rash involvement	NR			NR			
*Face		256 (75.7%)			3/11 (27.3)	68/71 (96)	34/35 (97.5)
* Trunk		NR			8/11 (72.7)	56/70 (80)	32/35 (92.5)
*Palms		206 (60.9%)	5/7 (71.4)		3/11 (27.3)	48/70 (69)	19/35 (55)
* Soles of feet		196 (58%)	5/7 (71.4)		3/11 (27.3)	42/66 (64)	17/35 (50)
*Genitalia		88 (26%)			NR	44/65 (68)	24/35 (67.5)
Rash characteristic <sup>^</sup>	NR		NR	NR	NR		NR
* Monomorphic		233/295 (79)				25 (62.5)	
* Pleomorphic		62/295 (21)				15 (37.5)	
Diffusion, N° (%)	NR		NR	NR	NR	NR	NR
*Centrifugal		246/295 (83.4)					
*Centripetal		13/295 (4.4)					
*Indefinite		36/295 (12.2)					
N° skin lesions (%)			NR	NR		NR	
* < 25	6 (12.7)	22 (6.5)			-		
*26–99	18 (38.3)	55 (16.3)			3 (50)		16 (40)
* > 100	23 (48.9)	218 (66.5)			3 (50)		24 (60)§
Fever	NR	NR	NR	NR	16 (84.2)	81/92 (88)	36 (90)
Lymphadenopathy, N° (%)	18 (38.3)	164 (48.5)	47/85 (55.3)	237 (69)	15 (79)	45/65 (69)	35 (87.5)
Case fatality rate (%)	8 (17%)	33 (9.7)	3/81 (3.7)	5 (1.5)	0 (0)	7 (5.7)*	5 (12.5)

List of abbreviations: DRC, Democratic Republic of Congo; NR, not reported; mo, months; y, year; d, days; \* four patients had AIDS; § 17 patients had 101–1000 lesions, 7 patients >1000 lesions; ^ monomorphic indicates similar size and appearance, pleomorphic indicates different sizes and appearance.

MPX is frequently localized to the face (75–97%) and the trunk (72–92%) with palms and soles generally not spared [8,40,53]. Involvement of genital area was reported in an old study in less than 30% of affected patients [53] but in more recent studies nearly 68% of subjects had such localization [8,40]. The skin lesions usually progress

through macules, papules, vesicles and pustules before umbilicating and crusting [52]. The number of skin lesions exceeds one hundred (an indirect sign of severity) in 49–66% of patients [30,40,53,55] with more than one thousand lesions in 17.5% of cases [40]. Secondary bacterial infection of skin has been recorded in 18.4–54% of cases [40,52].

Hypo-hyperpigmented scars were reported to be still present 1–4 years following the acute disease [33,52] but in a recent study skin scars were no longer visible after 8 weeks of follow-up [40]. Jezek et al. reported that illness started with fever in most patients with 5% of patients developing fever and rash on the same day [52]. Two recent studies reported fever preceding the rash only in 34.3% and 57% of patients, respectively [8,40]. Lymphadenopathy has been considered a distinctive clinical feature of MPX in the differential diagnosis with either smallpox and chickenpox [52,56] with possible generalized, cervical, submandibular, axillary and inguinal involvement [33,40,52]. However, it has been reported in 38–87% in different case series [7,8,33,40,54,55]. A case fatality rate (CFR) ranging from 0 to 17% has been reported with a calculated pooled estimate in a recent meta-analysis of 8.7% [10]. However, a significant difference emerged according to the different MPXV clades involved with a CFR of 10.6% for Central African clade and 4.6% for West African clade [10].

### 3.3. Monkeypox cases in non-endemic areas (2003–2021)

Up to 2021, 48 confirmed MPX cases have been reported outside the endemic African regions [13–18,31,60,61] and epidemiology, clinical characteristics and outcome are summarized in Table 3. Most of the patients belong to a large multistate monkeypox outbreak occurred in 2003 in the USA following the importation from Ghana of infected African rodents causing direct human infections or indirect infections by means of an intermediate animal host (i.e. prairie dogs) [31,62]. All the cases involved in the 2003 US outbreak had direct contact with infected exotic or wild mammalian pets, whereas human-to-human transmission had never been confirmed. Females were slightly prevalent (53.2%) and 23.4% of patients were <18 years of age [31]. Vaccination against smallpox was reported in approximately one out of three patients of the initial outbreak and none of this received the vaccine shot after 1972 [13]. The median incubation period was 12 days which was shorter for patients with a complex exposure (bite or scratch sufficient to provoke a break in the skin) when compared to those with a noninvasive exposure (9 vs 13 days, respectively) [31]. The clinical course was usually characterized, in patients with a noninvasive exposure, by a short prodromic phase (2–3 days) with fever, chills, lymphadenopathy, headache, sore throat, myalgias, and gastrointestinal symptoms, followed by the onset of the rash [31,62,63]. On the contrary, for patients with a complex exposure the rash usually preceded the acme of febrile illness [31]. Lymphadenopathy was frequently reported (71% of 34 confirmed cases) [63]. The rash presented with the centrifugal distribution in only 48% of cases and the involvement of palms in 28% and soles was observed only 9%, respectively [63]. Only 5 patients (12.5%) experienced >100 skin lesions [31]. In addition, healing with prominent hemorrhagic crusts was distinctive of the US cases and the resolution of lesions occurred after sloughing of these crusts usually without significant scars. Fourteen patients were hospitalized (only 9 for longer than 48 h) and five met the criteria for severe disease. All patients fully recovered without any specific antiviral treatment although it is worth mentioning that one 6-year-old child developed encephalitis with seizures and required mechanical ventilation for 48 h [31,63].

Since 2018, eleven additional cases of human MPX have been reported in non-endemic countries: seven in UK [14,60,61], two in the USA [16,18], one each in Israel [15] and in Singapore [17]. All but one patient aged <2 years were middle-aged adults (9 males and 2 females). All the cases had an epidemiological link with Nigeria (a travel to the country or the exposure to MPX cases imported from Nigeria). Notably, in three cases diagnosed in the UK human to human transmission was proven for the first time outside endemic areas [14,61]. In the first two cases it was in a family cluster [61] and in the third case the exposure was related to the health care assistance of a patient with MPX [14]. Reported exposures among travel-related cases were attending social gathering with bushmeat consumption [17,60] and contact with two rodent carcasses [15]. Lymphadenopathy was a common finding and the

clinical presentation, and the distribution of the vesiculo-pustular rash (present in all cases) appeared to be similar to that described in the noninvasive exposed patients of the 2003 US outbreak [31]. Notably three patients experienced low mood (with also emotional lability in one case) [14] and ulcerated inguinal lesions with a protracted healing were reported in two cases [14]. All patients were hospitalized experiencing a mild illness and fully recovered. Three patients were treated with brincidofovir (all experiencing a significant increase in liver enzyme) [14,60], two with tecovirimat [14,16] and one patient received post-exposure modified vaccinia Ankara [14].

### 3.4. Monkeypox laboratory diagnosis

The swab of a lesion exudate or crust specimens is considered the best sample to obtain a rapid and definite diagnosis of MPX. In particular, the direct recognition of the viral DNA by means of real-time PCR allow the rapid discrimination between smallpox and other poxvirus [20,64–69]. The nucleic acid of the virus could be also retrieved in blood, urine, upper respiratory tract and seminal fluid [14,69]. In addition, the GeneXpert assay has been demonstrated to perform well with both crust and vesicle samples providing an additional diagnostic platform that may expand and expedite MPX detection capabilities [70]. As an additional molecular tool useful for epidemiological purpose high-throughput shotgun metagenomics should be used to reconstruct the genome sequences and to inform about the evolutionary trajectory of MPX outbreak by means of phylogenomic data [71]. Viral isolation from a clinical specimen, electron microscopy, and immunohistochemistry are techniques that require advanced technical skills and training, and should be reserved to reference laboratories with appropriate expertise and skills [56]. Serological examination is useful for epidemiological purpose although limited by cross-reactivity to a variety of *Orthopoxviruses*. Consequently, the presence of anti-*Orthopoxvirus* IgG does not allow to reach a definitive diagnosis since a previous exposure to *Orthopoxviruses* or smallpox vaccine could cause a false positive result. The presence of anti-*Orthopoxvirus* IgM could be helpful, also in individuals with prior vaccination, in case of a recent exposure to MPX although again limited by the absence of intra *Orthopoxvirus* specificity [72].

### 3.5. Monkeypox treatment

Currently there are no treatments proven to be effective in clinical trial against human MPX; nevertheless, two orally bioavailable drugs, brincidofovir and tecovirimat, approved in the USA for the treatment of smallpox in preparation for a potential bioterrorism event [73,74], have been demonstrated to be effective against orthopoxviruses (including MPX) in animal models [75–78].

Tecovirimat is a small synthetic molecule that inhibits the production of extracellular viruses by interacting with the F13L gene product, which encodes a phospholipase involved in the formation of a protein complex that catalyzes the envelopment of intracellular mature virus particles [79]. The drug has been proven to be tolerated following oral administration at a single oral dose of 400 mg or 600 mg per day during 14 days in healthy volunteers in a phase I clinical trial [80,81]. On May 18, 2022 the FDA also approved an intravenous formulation of tecovirimat to treat smallpox as an option for those who are unable to swallow the oral capsule [82].

Brincidofovir (hexadecyloxypropyl-cidofovir), is a lipid conjugate of cidofovir with a broad antiviral activity against several DNA viruses [83]. Cidofovir after conversion to cidofovir diphosphate by intracellular kinases when incorporated in a growing DNA strand results in slower incorporation of the next nucleotide before a complete block of DNA synthesis with a subsequent impairment of genome encapsidation and virion assembly [84,85]. The advantage of brincidofovir when compared to cidofovir is an increased cellular uptake and better conversion to the active form by intracellular enzymes [86]. This if on the

**Table 3**  
Epidemiology, characteristics, clinical presentation and outcome of patients with monkeypox infection in non-endemic countries.

Country/ Year/Ref	N°	Sex	Age	Exposure risk	Type of exposure*	Incubation	Respiratory symptoms	GI symptoms	Systemic illness	Number of lesions	Fever	Specific Treatment	Duration	Adverse events	Post exposure vaccination	Hospitalized	Outcome
<b>USA/ 2003/ 13,31</b>	47 (37 confirmed and 10 probable)	25 (53.2%) F (46.8%) M	11 (23.4%) <18 years	Prairie dogs exposed to imported animals from Ghana	Noninvasive 30 (63.8%) Complex 17 (36.2%)	9–13 days	39 (83%) pronounced 8 (17%) mild	14 (29.8%)	Pronounced 30 (72.3%) Mild 17 (26.7%)	</ = 25 22 (46.8%) 26–100 13 (27.7%) 101–249 2 (4%) >/ = 250 3 (6.4%)	31 (66%)	None	NA	NA	None	14 (29.8%)	Recovered
<b>UK/2018/ 60</b>	2	2 M	Age range 30–40 years	Travel from Nigeria, bush meat possible for one case	Noninvasive	Unknown	NR	NR	Mild in both patients	Unknown, vesiculopustular rash present in both cases, lymphadenopathy	Yes	BCV 200 mg orally	One dose in one case and 2 dose in another	Increase in liver enzyme in both patients (ALT peak 331 IU/L and 550 IU/ L)	None	Yes	Recovered
<b>Israel/ 2018/15</b>	1	M	38 years	Rodent carcasses in Nigeria	Noninvasive	12 days	NR	NR	Mild	Unknown, vesiculopustular rash present, lymphadenopathy	Yes	NR	NR	NR	NR	Yes	Recovered
<b>Singapore 2019/17</b>	1	M	38 years	Travel to Nigeria and attended a wedding and eat bushmeat	Noninvasive	9 days	NR	NR	Mild	Unknown, vesiculopustular rash present, lymphadenopathy	Yes	None	NA	NA	None	Yes	Recovered
<b>UK/2021/ 61</b>	3	2 M 1 F	18 months and age range 30–40 years	Travel to Nigeria (index case), family cluster	Noninvasive	Index case unknow Secondary cases 19 and 14 days	NR	NR	Mild 3	Unknown, vesiculopustular rash, lymphadenopathy in one adult case and in the baby	None	TCV 600 mg twice orally in one case	2 weeks	None	None	Yes	Recovered
<b>USA/ 2021/16</b>	1	M	Middle aged	Travel to Nigeria, large social gathering	Noninvasive	Unknown	Yes	Yes	Mild	Unknown, vesiculopustular rash	Yes	TCV	Not specified	NR	None	Yes	Recovered
<b>USA/ 2021/18</b>	1	M	28 years	Travel to Nigeria	Noninvasive	Unknown	NR	NR	Mild	Unknown, vesiculopustular rash present, lymphadenopathy	Yes	None	NA	NA	None	Yes	Recovered
<b>UK/2018/ 14</b>	1	F	Age range 30–40	Secondary exposure during healthcare in UK	Noninvasive	18 days	NR	NR	Mild	32 lesions	No	BCV 200 mg orally	2 dose	Increase in liver enzyme (ALT peak 127 IU/L), nausea and abdominal discomfort	Modified vaccina Ankara 6 days post- exposure	Yes	Recovered

List of abbreviations: BCV, brincidofovir; NR, not reported; NA, not available; TCV, tecovirimat; GI, gastrointestinal.



one hand results in at least 25-fold higher efficacy than that of cidofovir against vaccinia strains on the other it exerts a higher cellular toxicity [87]. Brincidofovir takes the advantage of oral administration and the absence of nephrotoxicity, although in a phase I study mild gastrointestinal adverse effects and transient elevation of transaminases were reported and confirmed in phase II and III trials performed in immunocompromised adults and children [88,89].

The clinical experience with both these compounds in the treatment of *Orthopoxvirus* infections is extremely limited. A press release in 2021 announced an expanded access programme for tecovirimat is in progress in the Central African Republic, although no data is published to date [90]. There are three reports of compassionate use of tecovirimat for complicated vaccinia [91–94], without significant safety signals identified. Few anecdotal cases reported the use of these compounds in patients with MPXV in non-endemic countries. Three patients with a diagnosis of human MPXV were treated in the UK with brincidofovir (all experiencing a significant increase in liver enzyme [14,60] and two with tecovirimat one in the UK [14] and the other in the USA [16]. However, no definitive conclusions can be drawn about the efficacy of both drugs in the treatment of MPXV.

#### 4. Ongoing Monkeypox virus outbreak (April–June 2022) and discussion

As of June 8, 1200 confirmed cases of human MPXV have been reported worldwide (29 countries) with cases observed in seventeen European countries (including UK and Switzerland), the Americas (USA, Canada, Mexico, Argentina), Middle East (Israel, United Arab Emirates), Asia (Thailand) and Australia [95]. This is the largest ever reported multi-country outbreak of human MPXV outside Africa [96]. As far as UK, three distinct incidents have been identified: 1) one isolated imported case from Nigeria; 2) a separate household cluster (3 subjects with two confirmed cases) without a link with travel to endemic countries; 3) 82 confirmed cases not linked to the first two incidents [97]. For the latter, available information indicates that all subjects were males (79), 66 (83%) reported sex with men (MSM), the median age was 38 years and 18 reported foreign travel to multiple countries outside Africa [97]. Portugal reported 96 confirmed MPXV cases up to May, 27 with detailed information for 27 cases [98]. All were males with a median age of 33 years and resided mainly (92.6%) in the Lisbon and Tangus Valley but four reported travelling abroad [98]. Eighteen subjects identified themselves as MSM, fourteen were people living with HIV. An exanthema with inguinal lymphadenopathy was reported in fourteen patients but such information was missing for the remaining patients. Six presented genital ulcers and four anal ulcers [98]. Genital and anal lesions were also reported at the beginning of the illness in four MSM diagnosed in Rome (Italy) [69], two MSM who had sexual intercourse with each other in UK [99], one MSM diagnosed in Australia who had insertive anal intercourse with four casual male partners in Europe [100], one MSM diagnosed in Czech Republic who had unprotected sexual intercourses in Gran Canaria (Spain) [101] and our patient who reported a single anal receptive intercourse in Portugal seven days before the appearance of lesions. Also in the CDC report from USA, 94% of confirmed cases (16/17) identified themselves as MSM with 35% complaining of perianal lesions and 24% on genitals [102]. All such cases raised the possibility that MPXV can be transmitted by close contact during sexual intercourse as previously reported for vaccinia virus [36–38]. Interestingly in our case we were able to demonstrate MPXV DNA in the seminal fluid with a Ct value of 31 which is similar to the results obtained by our colleagues in Rome who found positivity in the seminal fluid of 3 patients with a Ct ranging from 27 to 30 [69]. However, we were not able to culture MPXV from this specimen and actually it is not demonstrated a direct sexual transmission although the lesions localized on genitals suggests close physical contact during sexual intercourse as the route of acquisition. Different from the study by Adler and coworkers (reporting the UK experience on eight patients

diagnosed between 2018 and 2021) [14] who were not able to confirm positive PCR results with viral culture assays, we showed positive culture from four sites with Ct ranging from 14 to 23 demonstrating shedding of viable virus.

In conclusion, we observed in our patient a mild disease with a low number of skin lesions localized also to the genital area and with an asynchronous pattern evolution which is consistent with the clinical presentation reported so far in few reports [69,97] regarding the actual worldwide outbreak of MPXV.

#### 5. Conclusion

This case report highlights the difficulties encountered by clinicians facing with patients with MPXV infection during the ongoing outbreak outside Africa. Diagnostic methods to confirm the diagnosis are sensitive but generally available only in few national reference laboratories. Differential diagnosis should consider several diseases including secondary syphilis, disseminated gonorrhoea, herpes simplex, lymphogranuloma venereum, molluscum contagiosum, disseminated cryptococcosis. Our case as well as other well described cases in the literature seems to present with few skin lesions sometimes localized to genital and anal area with an asynchronous pattern and with inguinal lymphadenopathy that is different from classical description of the illness. Contact tracing is not an easy task since many patients engaged sex with multiple anonymous partners. Awareness among health-care providers in non-endemic countries need to be strengthened.

#### Contributors

DM drafted the manuscript and tables, made the laboratory diagnosis and participated in the isolation of the virus. AR cared for the patient. MC participated in the laboratory diagnosis and isolation of the virus. DM cared for the patient and sampled all the specimens. MC participated in the laboratory diagnosis and isolation of the virus. LM cared for the patient. AG drafted the manuscript and did the scientific literature search. GB cared for the patient. MRG participated in the laboratory diagnosis and isolation of the virus. GR drafted the manuscript. SA drafted the manuscript and tables, did the scientific literature search and cared for the patient. All the authors revised the drafted manuscript and approved the final version.

#### Declaration of interests

We declare no competing interests.

#### Ethical statement

The patient provided written informed consent to publish this manuscript and for material sampling.

#### Acknowledgments

We would like to thank Dr Fabrizio Carletti of the National Institute for Infectious Diseases “Lazzaro Spallanzani” (IRCCS), Rome, Italy for providing reagents for specific RT-PCR for Monkeypox virus.

#### References

- [1] Durski KN, McCollum AM, Nakazawa Y, Petersen BW, Reynolds MG, Briand S, Djingarey MH, Olson V, Damon IK, Khalakdina A. Emergence of monkeypox in West Africa and central Africa, 1970–2017. *Wkly Epidemiol Rec* 2018;11:125–32.
- [2] Von Magnus P, Andersen EA, Petersen KB, Birch-Andersen A. A pox-like disease in cynomolgus monkeys. *Acta Pathol Microbiol Scand* 1959;46:156–76.
- [3] Ladnyj ID, Ziegler P, Kima E. A human infection caused by monkeypox virus in Basakunsu Territory, Democratic Republic of Congo. *Bull World Health Organ* 1972;46:593–7.

- [4] Lourie B, Bingham PG, Evans HH, Foster SO, Nakano JH, Hermann KL. Human infection with monkeypox virus: laboratory investigation of six cases in West Africa. *Bull World Health Organ* 1972;46:633–9.
- [5] Marennikova SS, Seluhina EM, Mal'ceva NN, Cimiskian KL, Macevic GR. Isolation and properties of the causal agent of a new variola-like disease (monkeypox) in man. *Bull World Health Organ* 1972;46:599–611.
- [6] Heymann DL, Szczeniowski M, Esteves K. Re-emergence of monkeypox in Africa: a review of the past six years. *Br Med Bull* 1998;54:693–702.
- [7] Hutin YJF, Williams J, Malfait P, Pebody R, Loparev VN, Ropp SL, et al. Outbreak of human monkeypox, Democratic Republic of Congo, 1996–1997. *Emerg Infect Dis* 2001;7:434–8.
- [8] Yinka-Ogunleye A, Aruna O, Dalhat M, Ogoina D, McCallum A, Disu Y, et al. Outbreak of human monkeypox in Nigeria in 2017–18: a clinical and epidemiological report. *Lancet Infect Dis* 2019;19:872–9.
- [9] Beer EM, Rao VB. A systematic review of the epidemiology of human monkeypox outbreaks and implications for outbreak strategy. *PLoS Negl Trop Dis* 2019;13:e0007791.
- [10] Bunge EM, Hoet B, Chen L, Lienert F, Weidenthaler H, baer LR, et al. The changing epidemiology of human monkeypox- A potential threat? A systematic review. *PLoS Negl Trop Dis* 2022;16:e0010141.
- [11] World Health Organization. Regional office for Africa. Weekly Bulletin on Outbreak and other Emergencies : Met Week January 2021;4:18–24.
- [12] World Health Organization. Regional office for Africa. Weekly Bulletin on Outbreak and other Emergencies : Met Week January 2022;4:17–23.
- [13] Centers for Disease Control and Prevention. Update: multistate outbreak of monkeypox- Illinois, Indiana, Kansas, Missouri, Ohio, and Wisconsin, 2003. *MMWR Morb Mortal Wkly Rep* 2003;52(27):642–6.
- [14] Adler H, Gould S, Hine P, Snell LB, Wong W, Houlihan CF, et al. Clinical features and management of human monkeypox: a retrospective observational study in the UK. *Lancet Infect Dis* 2022. [https://doi.org/10.1016/S1473-3099\(22\)00228-6](https://doi.org/10.1016/S1473-3099(22)00228-6). published online May 24, 2022.
- [15] Erez N, Achoudot H, Milrot E, Schwartz Y, Wiener-Well Y, Paran N, et al. Diagnosis of imported monkeypox. *Israel*, 2018. *Emerg Infect Dis* 2019;25:980–3.
- [16] Rao AK, Schulte J, Chen T-H, Hughes CM, Davidson W, Neff JM, et al. Monkeypox in a traveller returning from Nigeria- Dallas, Texas, July 2021. *MMWR (Morb Mortal Wkly Rep)* 2022;71(14):509–16.
- [17] Yong SEF, Ng OT, Ho ZJM, Mak TM, Marimuthu K, Vasoo S, et al. Imported monkeypox. Singapore. *Emerg Infect Dis* 2020;26:1826–30.
- [18] Costello V, Sowash M, Gaur A, Cardis M, Pasieka H, Wortmann G, Ramdeen S. Imported monkeypox from international traveller, Maryland, USA. 2021 *Emerg Infect Dis* 2022;28(5):1002–5.
- [19] European Centre for Disease Prevention and Control. Monkeypox multi-country outbreak- 23. Stockholm: ECDC; May 2022.
- [20] Li Y, Zhao H, Wilkins K, Hughes C, Damon IK. Real-time PCR assays for the specific detection of monkeypox virus West African and Congo Basin strain DNA. *J Virol Methods* 2010;169(1):223–7.
- [21] Arita I, Henderson DA. Smallpox and monkeypox in non-human primates. *Bull World Health Organ* 1968;39:277–83.
- [22] Khodakevich L, Jezek Z, Kinzanzka K. Isolation of monkeypox virus from wild squirrel infected in nature. *Lancet* 1986;1:98–9.
- [23] Radonic A, Metzger S, Dabrowski PW, Couacy-Hymann E, Schuenadel L, Kurth A, et al. Fatal monkeypox in wild-living sooty mangabey. *Cote d'Ivoire*, 2021. *Emerg Infect Dis* 2014;20:1009–11.
- [24] Likos AM, Sammons SA, Olson VA, Frace AM, Li Y, Olsen-Rasmussen M, et al. A tale of two clades: monkeypox viruses. *J Gen Virol* 2005;86:2661–72.
- [25] Chen N, Li G, Liszewski MK, Atkinson JP, Jahrling PB, Feng Z, et al. Virulence differences between monkeypox virus isolates from West Africa and the Congo basin. *Virology* 2005;340:46–63.
- [26] Berthet N, Descorps-Declere S, Besombes C, Curaudeau M, Meyong AAK, Selekon B, et al. Genomic history of human monkey pox infections in the Central African Republic between 2001 and 2018. *Sci Rep* 2021;11:13085.
- [27] Isidro J, Borges V, Pinto M, Ferreira R, Sobral D, Nunes A, et al. First draft genome sequence of Monkeypox virus associated with the suspected multi-country outbreak. confirmed case in Portugal, <https://virological.org>; May 2022.
- [28] Martinez-Puchol S, Coello A, Bordoy AE, Soler L, Panisello D, Gonzalez-Gomez S, et al. Spanish draft genome sequence of Monkeypox virus related to multi-country outbreak. <https://virological.org>; May 2022.
- [29] Mutombo M, Arita I, Jezek Z. Human monkeypox transmitted by a chimpanzee in a tropical rain-forest area of Zaire. *Lancet* 1983;1(8327):735–7.
- [30] Fine PE, Jezek Z, Grab B, Dixon H. The transmission potential of monkeypox virus in human population. *Int J Epidemiol* 1988;17:643–50.
- [31] Reynolds MG, Yorita KL, Kuehnert MJ, Davidson WB, Huhn GD, Holman RC, Damon IK. Clinical manifestations of human monkeypox influenced by route of infection. *J Infect Dis* 2006;194:773–80.
- [32] Quiner CA, Moses C, Monroe BP, Nakazawa Y, Doty JB, Hughes CM, et al. Presumptive risk factors for monkeypox in rural communities in the Democratic Republic of the Congo. *PLoS One* 2017;12(2):e0168664.
- [33] Breman JG, Ruti K, Steniowski MV, Zanutto E, Gromyko AI, Arita I. Human monkeypox, 1970–79. *Bull World Health Organ* 1980;58:165–82.
- [34] Jezek Z, Grab B, Szczeniowski MV, Paluku KM, Mutombo M. Human monkeypox: secondary attack rates. *Bull World Health Organ* 1988;66:465–70.
- [35] Jezek Z, Marennikova SS, Mutumbo M, Nakano JH, Paluku KM, Szczeniowski M. Human monkeypox: a study of 2,510 contacts of 214 patients. *J Infect Dis* 1986;154:551–5.
- [36] Nolen LD, Osadebe L, Katomba J, Likofata J, Mukadi D, Monroe B, et al. Extended human-to-human transmission during a monkeypox outbreak in the Democratic Republic of Congo. *Emerg Infect Dis* 2016;22:1014–21.
- [37] CDC. Secondary and tertiary transmission of vaccinia virus after sexual contact with a smallpox vaccine-San Diego, California. *MMWR Morb Mortal Wkly Rep* 2013;62:145–7.
- [38] CDC. Vulvar vaccinia infection after sexual contact with a military smallpox vaccine-Alaska, 2006. *MMWR (Morb Mortal Wkly Rep)* 2007;56:417–9.
- [39] CDC. Vaccinia virus infection after sexual contact with a military smallpox vaccine-Washington, 2010. *MMWR (Morb Mortal Wkly Rep)* 2010;59:773–5.
- [40] Ogoina D, Iroezindu M, James HI, Oladokun R, Yinka-Ogunleye A, Wakama P, et al. Clinical course and outcome of human Monkeypox in Nigeria. *Clin Infect Dis* 2020;71:e210–4.
- [41] Di Giulio DB, Eckburg PB. Human monkeypox: an emerging zoonosis. *Lancet Infect Dis* 2004;4:15–25.
- [42] Anonymous. The current status of human monkeypox: memorandum from a WHO meeting. *Bull World Health Organ* 1984;62:702–13.
- [43] Rimoin AW, Mulembakani PM, Johnston SC, Lloyd Smith JO, Kisalu NK, et al. Major increase in human monkeypox incidence 30 years after smallpox vaccination campaigns cease in the Democratic Republic of Congo. *Proc Natl Acad Sci USA* 2010;107:16262–7.
- [44] Hoff NA, Doshi RH, Colwell B, Kebela-Llungu B, Mukadi P, Mossoko M, et al. Evolution of a disease surveillance system: an increase in reporting of human monkeypox disease in Democratic Republic of the Congo. 2001–2013. *Int J Trop Dis Health* 2017;25(2).
- [45] Khodakevich L, Jezek Z, Messenger D. Monkeypox virus: ecology and public health significance. *Bull World Health Organ* 1988;66:747–52.
- [46] Nguyen PY, Ajiseigiri WS, Costantino V, Chughtai AA, MacIntyre CR. Reemergence of human monkey-pox and declining population immunity in the context of urbanization. *Nigeria*, 2017–2020. *Emerg Infect Dis* 2021;27.
- [47] Simpson K, Heymann D, Brown CS, Edmunds WJ, Elsgaard J, Fine P, et al. Human monkeypox- after 40 years, an unintended consequence of smallpox eradication. *Vaccine* 2020;38:5077–81.
- [48] McMullen CL, Mulembakani P, Hoff NA, Doshi RH, Mukadi P, Shongo R, et al. Human monkeypox transmission dynamics thirty years after smallpox eradication in the Sankuru district, Democratic Republic of Congo. *Am J Trop Med Hyg* 2015;93(Suppl.4):341.
- [49] Kugelman JR, Johnston SC, Mulembakani PM, Kisalu N, Lee MS, Koroleva G, et al. Genomic variability of monkeypox virus among humans, Democratic Republic of Congo. *Emerg Infect Dis* 2017;20:232–9.
- [50] Grant R, Nguyen LBL, Breban R. Modelling human-to-human transmission of monkeypox. *Bull World Health Organ* 2020;98:638–40.
- [51] Peter OJ, Kumar S, Kumari N, Oguntolu FA, Oshinubi K, Musa R. Transmission dynamics of Monkeypox virus: a mathematical modelling approach. *Model Earth Syst Environ* 2021;1–12. Oct 15.
- [52] Jezek Z, Szczeniowski M, Paluku KM, Mutombo M. Human monkeypox: clinical features of 282 patients. *J Infect Dis* 1987;156:293–8.
- [53] Jezek Z, Grab B, Szczeniowski M, Paluku KM, Mutombo M. Clinico-epidemiological features of monkeypox patients with an animal or human source of infection. *Bull World Health Organ* 1988;66:459–64.
- [54] CDC. Human monkeypox- Kasai oriental, democratic republic of Congo, february 1996–october 1997. *MMWR (Morb Mortal Wkly Rep)* 1997;46:1168–71.
- [55] Formenty P, Muntasir MO, Damon I, Chowdhary V, Opoka ML, Monimart C, et al. Human monkeypox outbreak caused by novel virus belonging to Congo Basin Clade, Sudan, 2005. *Emerg Infect Dis* 2010;16:1539–45.
- [56] McCollum AM, Damon IK. Human monkeypox. *Clin Infect Dis* 2014;58:260–7.
- [57] Meyer H, Perrichot M, Stemmler M, Emmerich P, Schmitz H, Varaine F, et al. Outbreaks of disease suspected of being due to human monkeypox virus infection in the Democratic Republic of Congo in 2001. *J Clin Microbiol* 2002;40:2919–21.
- [58] Jezek Z, Szczeniowski M, Paluku KM, Mutombo M, Grab B. Human monkeypox : confusion with chickenpox. *Acta Trop* 1988;45:297–307.
- [59] Hughes CM, Liu L, Davidson WB, Radford K, Wilkins K, Monroe B, et al. A tale of two viruses: coinfections of Monkeypox and Varicella Zoster virus in the Democratic Republic of Congo. *Am J Trop Med Hyg* 2020;104:604–11.
- [60] Vaughan A, Aarons E, Astbury J, Balasegaram S, Beadsworth M, Beck CR, et al. Two cases of monkeypox imported to the United Kingdom, September 2018. *Euro Surveill* 2018;23:1800509.
- [61] Hobson G, Adamson J, Adler H, et al. Family cluster of three cases of monkeypox imported from Nigeria to the UK, May 2021. *Euro Surveill* 2021;26:2100745.
- [62] Reed KD, Melski JW, Graham MB, Regnery RL, Sotir MJ, Wegner MV, et al. The detection of monkeypox in humans in the western hemisphere. *N Engl J Med* 2004;350:342–50.
- [63] Huhn GD, Bauer AM, Yorita K, Graham MB, Sejvar J, Likos A, et al. Clinical characteristics of human monkeypox, and risk factors for severe disease. *Clin Infect Dis* 2005;41:1742–51.
- [64] Kulesh DA, Loveless BM, Norwood D, Garrison J, Whitehouse CA, Hartmann C, et al. Monkeypox virus detection in rodents using real-time 3'-minor groove binder TaqMan assays on the Roche LightCycler. *Lab Invest* 2004;84:1200–8.
- [65] Olson VA, Laue T, Laker MT, Baskin IV, Drosten C, Shchelkunov SN, et al. Real-time PCR system for detection of orthopoxviruses and simultaneous identification of smallpox virus. *J Clin Microbiol* 2004;42:1940–6.
- [66] Li Y, Olson VA, Laue T, Laker MT, Damon IK. Detection of monkeypox virus with real-time PCR assays. *J Clin Virol* 2006;36:194–203.
- [67] Shchelkunov SN, Shcherbakov DN, Maksyutov RA, Gavrilova EV. Species-specific identification of variola, monkeypox, cowpox, and vaccinia viruses by multiplex real-time PCR assay. *J Virol Methods* 2011;175:163–9.

- [68] Shchelkunov SN, Gavrilova EV, Babkin IV. Multiplex PCR detection and species differentiation of orthopoxviruses pathogenic to humans. *Mol Cell Probes* 2005; 19:1–8. <https://doi.org/10.1016/j.mcp.2004.07.004>.
- [69] Antinori A, Mazzotta V, Vita S, Carletti Tacconi D, Lapini LE, et al. Epidemiological, clinical and virological characteristics of four cases on monkeypox support transmission through sexual contact. Italy, may 2022. *Euro Surveill* 2022;27(22). pii=2200421.
- [70] Li D, Wilkins K, McCollum AM, Osadebe L, Kabamba J, Nguete B, et al. Evaluation of the GeneXpert for human monkeypox diagnosis. *Am J Trop Med Hyg* 2017;96(2):405–10.
- [71] Gomes JP, Isidro J, Borges V, et al. Multi-country outbreak of monkeypox virus: phylogenomic characterization and signs of microevolution. PREPRINT (Version 1) available at: Research Square, <https://doi.org/10.21203/rs.3.rs-1700947/v1>; May 2022. 31.
- [72] Karem KL, Reynolds M, Braden Z, et al. Characterization of acute phase humoral immunity to monkeypox: use of immunoglobulin M enzyme-linked immunosorbent assay for detection of monkeypox infection during the 2003 North American outbreak. *Clin Diagn Lab Immunol* 2005;12:867–72.
- [73] Grosenbach DW, Honeychurch K, Rose EA, Chinsangaram J, Frimm A, Maiti B, Lovejoy C, Meara I, Long P, Hruby DE. Oral tecovirimat for the treatment of smallpox. *N Engl J Med* 2018;379(1):44–53.
- [74] Chittick G, Morrison M, Brundage T, Nichols WG. Short-term clinical safety profile of brincidofovir: a favorable benefit-risk proposition in the treatment of smallpox. *Antivir Res* 2017 Jul;143:269–77. <https://www.fda.gov/emergency-prparedness-and-response/mcm-issues/smallpox-preparedness-and-response-updates-fda>. [Accessed 30 May 2022].
- [75] Yang G, Pevear DC, Davies MH, Collett MC, Bailey T, Rippen S, et al. An orally bioavailable antipoxvirus compound (ST-246) inhibits extracellular virus formation and protects mice from lethal orthopoxvirus Challenge. *J Virol* 2005;79(20):13139–49.
- [76] Russo AT, Grosenbach DW, Brasel TL, Baker RO, Cawthon AG, Reynolds C, et al. Effects of treatment delay on efficacy of tecovirimat following lethal aerosol monkeypox virus challenge in cynomolgus macaques. *J Infect Dis* 2018;218(9):1490–9.
- [77] Delaune D, Iseni F. Drug development against smallpox: present and future. *Antimicrob Agents Chemother* 2020;64(4). e01683–19.
- [78] Hutson CL, Kondas AV, Mauldin MR, Doty JB, Grossi IM, Morgan CN, et al. Pharmacokinetics and efficacy of a potential smallpox therapeutic, brincidofovir, in a lethal monkeypox virus animal model [published correction appears in mSphere. 2021 Feb 17;6(1):] *mSphere* 2021;6(1). e00927–20.
- [79] Jordan R, Leeds JM, Tyavanagimatt S, Hruby DE. Development of ST-246 for treatment of poxvirus infections. *Viruses* 2010;2:2409–35.
- [80] Jordan R, Tien D, Bolken TC, Jones KF, Tyavanagimatt SR, Strasser J, Frimm A, Corrado ML, Strome PG, Hruby DE. Single-dose safety and pharmacokinetics of ST-246, a novel orthopoxvirus egress inhibitor. *Antimicrob Agents Chemother* 2008;52:1721–7.
- [81] Chinsangaram J, Honeychurch KM, Tyavanagimatt SR, Leeds JM, Bolken TC, Jones KF, Jordan R, Marbury T, Ruckle J, Mee-Lee D, Ross E, Lichtenstein I, Pickens M, Corrado M, Clarke JM, Frimm AM, Hruby DE. Safety and pharmacokinetics of the anti-orthopoxvirus compound ST-246 following a single daily oral dose for 14 days in human volunteers. *Antimicrob Agents Chemother* 2012;56:4900–5.
- [82] <https://www.fda.gov/emergency-preparedness-and-response/mcm-issues/smallpox-preparedness-and-response-updates-fda>. [Accessed 30 May 2022].
- [83] De Clercq E, Holy A, Rosenberg I, Sakuma T, Balzarini J, Maudgal PC. A novel selective broad-spectrum anti-DNA virus agent. *Nature* 1986;323:464–7.
- [84] Magee WC, Hostetler KY, Evans DH. Mechanism of inhibition of vaccinia virus DNA polymerase by cidofovir diphosphate. *Antimicrob Agents Chemother* 2005; 49:3153–62.
- [85] Jesus DM, Costa LT, Goncalves DL, Achete CA, Attias M, Moussatche N, Damaso CR. Cidofovir inhibits genome encapsidation and affects morphogenesis during the replication of vaccinia virus. *J Virol* 2009;83:11477–90.
- [86] Hostetler KY. Synthesis and early development of hexadecyloxypropylcidofovir: an oral antipoxvirus nucleoside phosphonate. *Viruses* 2010;2:2213–25.
- [87] Kern ER, Hartline C, Harden E, Keith K, Rodriguez N, Beadle JR, Hostetler KY. Enhanced inhibition of orthopoxvirus replication in vitro by alkoxyalkyl esters of cidofovir and cyclic cidofovir. *Antimicrob Agents Chemother* 2002;46:991–5.
- [88] Marty FM, Winston DJ, Chemaly RF, Mullane KM, Shore TB, Papanicolaou GA, et al. A randomized, double-blind, placebo-controlled phase 3 trial of oral brincidofovir for cytomegalovirus prophylaxis in allogeneic hematopoietic cell transplantation. *Biol Blood Marrow Transplant* 2019;25(2):369–81.
- [89] Grimley MS, Chemaly RF, Englund JA, Kustzberg J, Chittick G, Brundage TM, et al. Brincidofovir for asymptomatic adenovirus viremia in pediatric and adult allogeneic hematopoietic cell transplant recipients: a randomized placebo-controlled phase II trial. *Biol Blood Marrow Transplant* 2017;23(3):512–21.
- [90] SIGA announces collaboration with oxford university to support expanded access protocol for use of tpoxx (tecovirimat) to treat monkeypox in Central African Republic. <https://www.globenewswire.com/news-release/2021/07/29/2270930/9738/en/SIGA-Announces-Collaboration-with-Oxford-University-to-Support-Expanded-Access-Protocol-for-Use-of-TPOXX-Tecovirimat-To-Treat-Monkeypox-in-Central-African-Republic.html>. [Accessed 30 May 2022].
- [91] Vora S, Damon I, Fulginiti V, Weber SG, Kahama M, Stein SL, et al. Severe eczema vaccinatum in a household contact of a smallpox vaccinee. *Clin Infect Dis* 2008; 46(10):1555–61.
- [92] Lindholm DA, Fisher RD, Montgomery JR, Davidson W, Yu PA, Yu YC, et al. Preemptive tecovirimat use in an active duty service member who presented with acute myeloid leukemia after an smallpox vaccination. *Clin Infect Dis* 2019;69(12): 2205–7.
- [93] Kiernan M, Koutroumanos N. Orbital cowpox. *N Engl J Med* 2021;384(23):2241.
- [94] Wendt R, Tittelbach J, Schrick L, Kellner N, Kalbitz S, Ruehe B, et al. Generalized cowpox virus infection in an immunosuppressed patient. *Int J Infect Dis* 2021; 106:276–8.
- [95] Cdc. 2022 Monkeypox and Orthopoxvirus outbreak global map. [CDC.gov accessed on June 9, 2022](https://www.cdc.gov/media/releases/2022/s050922-monkeypox-map.html).
- [96] Leon-Figueroa DA, Bonilla-Aldana K, Pachar M, Romani L, Saldana-Cumpa HM, Anchay-Zuloeta C, et al. The never-ending global emergence of viral zoonoses after COVID-19? The rising concern of monkeypox in Europe, North America and beyond. *Travel Med Infect Dis* 2022;49:102362.
- [97] Vivancos R, Anderson C, Blomquist P, Balasegaram Bell A, Bishop L, et al. Community transmission of monkeypox in the United Kingdom. April to May 2022. *Euro Surveill* 2022;27(22). pii=2200422.
- [98] Perez Duque M, Ribeiro S, Martins JV, Casaca P, Leite PP, Tavares M, et al. Ongoing monkeypox virus outbreak, Portugal. 29 April to 23 May 2022. *Euro Surveill* 2022;(22):27. pii=2200424.
- [99] Heskin J, Belfield A, Milne C, Brown N, Walters Y, Scott C, et al. Transmission of monkeypox virus through sexual contact- A novel route of infection. *J Infect* 2022. pii:S0163-4453(22) 00335–00338.
- [100] Hammerschlag Y, MacLeod G, Papadakis G, Sanchez AA, Druce J, Taiaroa G, et al. Monkeypox infection presenting as genital rash, Australia, May 2022. *Euro Surveill* 2022;27(22). pii=2200411.
- [101] Bizova B, Vesely D, Trojanek M, Rob F. Coinfection with syphilis and monkeypox in HIV positive man in Prague, Czech Republic. *Travel Med Infect Dis* 2022;49: 102368.
- [102] Minhaj FS, Ogale YP, Whitehill F, Schultz J, Foote M, Davidson W, et al. Monkeypox outbreak- nine States, May 2022. *MMWR (Morb Mortal Wkly Rep)* 2022;71:764–9.