

# Facial Nerve Paralysis and COVID-19: A Systematic Review

Amirpouyan Namavarian, MD ; Anas Eid, BMSc ; Hedyeh Ziai, MD ; Emily YiQin Cheng, BSc ;  
Danny Enepekides, MD, MSc, FRCSC

**Objective:** Several cases of facial nerve paralysis (FNP) post-COVID-19 infection have been reported with varying presentations and management. This study aims to identify FNP clinical characteristics and recovery outcomes among patients acutely infected with COVID-19. We hypothesize that FNP is a potentially unique sequelae associated with COVID-19 infections.

**Methods:** A systematic review of PubMed-Medline, OVID Embase, and Web of Science databases from inception to November 2021 was conducted following the Preferred Reporting Items for Systematic Reviews and Meta-Analyses guidelines.

**Results:** This search identified 630 studies with 53 meeting inclusion criteria. This resulted in 72 patients, of which 30 (42%) were diagnosed with Guillain-Barré Syndrome (GBS). Non-GBS patients were on average younger (36 vs. 53 years) and more likely to present with unilateral FNP (88%) compared to GBS patients who presented predominantly with bilateral FNP (74%). Among non-GBS patients, majority (70%) of FNP presented a median of 8 [IQR 10] days after the onset of initial COVID-19 symptom(s). Treatment for non-GBS patients consisted of steroids (60%), antivirals (29%), antibiotics (21%), and no treatment (21%). Complete FNP recovery in non-GBS patients was achieved in 67% patients within a median of 11 [IQR 24] days.

**Conclusion:** FNP is a possible presentation post COVID-19 infections, associated with both GBS and non-GBS patients. Although no causation can be assumed, the clinical course of isolated FNP associated with COVID-19 raises the possibility of a unique presentation differing from Bell's palsy, seen with higher proportion of patients developing bilateral FNP and a shorter duration to complete recovery.

**Key Words:** Bell's palsy, COVID-19, facial nerve, paralysis.

*Laryngoscope*, 00:1–7, 2022

## INTRODUCTION

Facial nerve paralysis/palsy (FNP) is a debilitating condition with significant morbidity associated with functional and psychological implications.<sup>1</sup> Although the etiology of FNP is broad, viral-associated Bell's palsy is thought to be the most prevalent contributor.<sup>2</sup> Herpes simplex virus (HSV) and Varicella zoster virus (VZV) are known contributors in the development of Bell's Palsy in the pediatric and adult population.<sup>3,4</sup> Since the onset of the COVID-19 pandemic, FNP incidence has increased and there has been a suggested association with COVID-19 infections.<sup>5–8</sup>

Many neurological symptoms have been reported in patients infected with COVID-19 including anosmia,

ageusia, myalgia, paraplegias, and facial palsy among others.<sup>9,10</sup> FNP has been described by numerous studies as an outcome of COVID-19, either as an isolated symptom in patients who have otherwise been asymptomatic or in combination with other COVID-19 symptoms.<sup>6,11</sup> Guillain-Barré Syndrome (GBS), an autoimmune polyneuropathy, is linked to viral infections including Epstein-Barr virus (EBV), VZV, human immunodeficiency virus, and influenza among others.<sup>12</sup> GBS has also been described by numerous case reports as a sequelae of COVID-19 infections, with many reported cases of FNP.<sup>13</sup> The mechanism of GBS is believed to involve an aberrant immune response resulting in nerve trauma secondary to inappropriate complement activation and inflammatory mediators.<sup>14</sup>

The current literature highlights facial paralysis in COVID-19 infected patients including both adult and pediatric cohorts. Although many case reports have described the presence of acute facial paralysis in COVID-19 patients, to date, there is no comprehensive systematic review on these patients. The objective of this study is to identify FNP clinical characteristics and recovery outcomes among patients acutely infected with COVID-19 (confirmed by a positive reverse transcription polymerase chain reaction [RT-PCR]). We hypothesize that FNP is a potentially unique sequelae associated with COVID-19 infections. In this systematic review, we summarize the current literature on the presentations of facial nerve paralysis in COVID-19 patients and describe the management of

From the Department of Otolaryngology Head and Neck Surgery (A.N., H.Z., D.E.), University of Toronto, Toronto, Ontario, Canada; Schulich School of Medicine and Dentistry (A.E.), Western University, London, Ontario, Canada; Temerty Faculty of Medicine (E.Y.C.), University of Toronto, Toronto, Ontario, Canada; and the Department of Otolaryngology – Head and Neck Surgery (D.E.), Sunnybrook Health Sciences Centre, Toronto, Ontario, Canada.

Additional supporting information may be found in the online version of this article.

Editor's Note: This Manuscript was accepted for publication on July 22, 2022.

A.N. and A.E. contributed equally to this manuscript and are considered co-first authors.

The authors have no funding, financial relationships, or conflicts of interest to disclose.

Send correspondence to Hedyeh Ziai, 6 Queen's Park Crescent West, Suite 120, Toronto, ON M5S 3H2, Canada. E-mail: [Hedyeh.ziai@mail.uToronto.ca](mailto:Hedyeh.ziai@mail.uToronto.ca)

DOI: 10.1002/lary.30333

these patients with the aim of providing guidance for future practitioners on these patients' clinical diagnosis and management.

## METHODS

### Search Strategy

This systematic review was completed using the Preferred Reporting Items for Systematic Reviews and Meta-Analyses (PRISMA) guidelines (Fig. 1). The search strategy was conducted using Ovid Embase, PubMed-Medline, CINAHL and Web of Science databases from inception to November 2021. The database search was done by two reviewers (A.E./A.N.). Keywords and medical subject headings (MeSH) included facial, facial nerve, peripheral facial nerve, paralysis, paresis, droop, impair\*, Bell's palsy, weakness, disease, movement, COVID-19, coronavirus, covid, and SARS-CoV-2. The exact search details used for all databases are found in Table S1.

### Inclusion and Exclusion Criteria

Inclusion criteria consisted of studies reporting FNP in adult and/or pediatric patients actively infected with COVID-19. This was defined as a positive COVID-19 RT-PCR result. There was no comparator and the outcomes recorded included study design, patient demographic, and FNP clinical characteristics and recovery outcome. Published original studies including case reports, randomized controlled trials, prospective, or retrospective observational studies, cross-sectional and case-control trials since journal inception were included. Patients with non-active COVID-19 infections (i.e., negative RT-PCR results) despite positive serology (positive immunoglobulin G) were excluded. Furthermore, papers published in a non-English language or non-peer reviewed publications (abstracts, conference posters, reviews, letters to editors, and editorials) were also excluded.

### Data Extraction and Analysis

The search titles and abstracts were independently screened by two reviewers (A.E./A.N.) based on the inclusion and exclusion criteria. Complete manuscripts were retrieved and

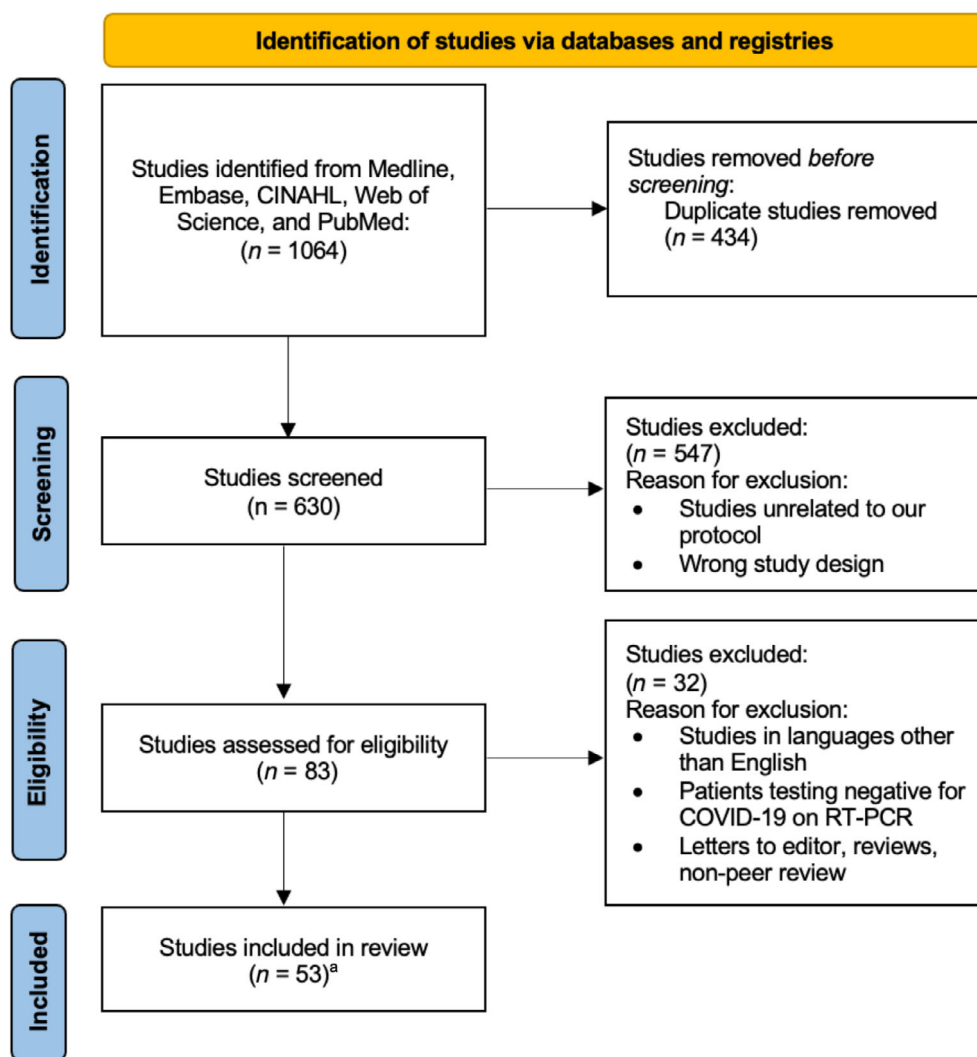


Fig. 1. PRISMA flow diagram. <sup>a</sup>Two studies were included after a screen of the citations from the papers during the eligibility phase. RT-PCR = reverse transcription polymerase chain reaction. [Color figure can be viewed in the online issue, which is available at [www.laryngoscope.com](http://www.laryngoscope.com).]

independently reviewed by the same two reviewers. If there were any disagreements in article selection between the two reviewers, these were resolved by consensus. If a disagreement persisted, a third reviewer was consulted (H.Z.). All titles, abstracts, and full texts screening were completed using Covidence (version 1501). Cross-checking of the included articles and relevant reviews, as well as a manual web search was conducted for unidentified articles. Extracted data included study design, study population demographics, and clinical characteristics. Information regarding FNP onset, laterality, House-Brackmann (HB) score, associated symptoms, investigations, treatments, and outcomes was extracted. Patients in studies that did not report HB score were assigned a score by the reviewers based on the described clinical presentation and HB scale by the reviewers when possible.<sup>15</sup> Similarly, if there was any disagreement between the two reviewers, a third reviewer was consulted.

### Risk of Bias Assessment

The Joanna Briggs Institute critical appraisal checklist for case reports and case series assessment tools were used to appraise the quality of the studies. This was independently assessed by two authors (A.E. and E.C.). Discrepancies were resolved by consensus or by involving a third author (A.N.). The quality of the studies was quantified according to the assessment tools and a final quality rating of “Good,” “Fair,” or “Poor” was given (Table S2A and B). For case reports, “Good” was defined as at least 6 out of 8 criteria met, “Fair” as 4 or 5 criteria met, and “Poor” as 3 or less criteria met. For case series, “Good” was defined as at least 7 out of 10 criteria met, “Fair” as 5 or 6 criteria met, and “Poor” as 4 or less criteria met.

### Statistical Analysis

Descriptive statistics were computed for all variables. Categorical variables were reported as unweighted frequencies and percentages. Continuous variables were reported as medians and interquartile range (IQR). Subgroup analysis was performed based on GBS status. IBM SPSS Statistics for Windows, Version 27.0 was used for all statistical analyses.

## RESULTS

### Study Selection

Our search identified 1064 studies. After duplicates were removed, a total of 630 studies were reviewed for initial screening. Fifty-two studies met our inclusion, and two studies were found during our screen of citations listed in our included papers. A total of 54 studies were included (Fig. 1), resulting in 73 patients.<sup>5-7,9-11,16-63</sup> The characteristics of each study can be found in Table S3.

### Clinical Features: Non-GBS Versus GBS Patients

The clinical presentations are summarized in Table I. Forty-two percent of patients presented with FNP in the context of GBS. Patients without GBS were younger than those with GBS (36 vs. 54 years, respectively). Additionally, more non-GBS patients presented with unilateral FNP compared to those with GBS (88% vs. 26%, respectively). Furthermore, non-GBS patients had a shorter delay to FNP onset (median [IQR];

TABLE I.  
Overall Study Demographics and FNP Clinical Presentations.

	Non-GBS (n = 42)	GBS (n = 30)
Patients (%)	58	42
Age (years), median [IQR]	36 [22]	54 [23]
Male, n (%)	19 (49)	21 (70)
Onset of FNP relative to COVID-19 symptoms, n (%)		
Only FNP	4 (11)	0
Before or concurrent	7 (19)	2 (6.8)
After	26 (70)	27 (93.1)
Days from initial symptoms to onset of FNP, median [IQR]	8 [10]	16 [11]
Unilateral FNP, n (%)	37 (88)	7 (25.9)
Degree of FNP, median [IQR]	3 [2]	4.5 [3]
Complete recovery of FNP achieved, n (%)	20 (67)	4 (13.3)
Days to complete recovery of FNP, median	11 [24]	30

FNP = facial nerve paralysis; GBS = Guillain-Barré Syndrome; IQR = interquartile range.

8 [10] days) from the onset of initial COVID-19 symptoms compared to GBS patients (16 [11] days).

Thirty-two studies reported the severity of the FNP using the House-Brackmann scale, the median grade was 3 [IQR 2] and 4.5 [3] for non-GBS and GBS patients, respectively.

Of the COVID-19 symptoms, the most reported were fever (36% and 60% in non-GBS and GBS patients, respectively) and cough (32% and 63% in non-GBS and GBS patients, respectively). When considering neurological symptoms in patients with COVID-19 other than FNP, impairments in taste function (e.g., ageusia, hypogeusia or dysgeusia) were most reported (10% in

TABLE II.  
Patient Symptoms.

Symptom	Non-GBS (n = 42), n (%)	GBS (n = 30), n (%)
Non-neurologic		
Fever	10 (36)	18 (60)
Cough	9 (32)	19 (63.3)
Myalgia	8 (29)	5 (16.7)
Dyspnea	5 (18)	7 (23.3)
Fatigue	3 (11)	5 (16.7)
Neurologic		
Anosmia or hyposmia	3 (8)	7 (23.3)
Ageusia, hypogeusia, dysgeusia	4 (10)	11 (36.7)
Dysarthria	0	4 (13.3)
Dysphagia	0	4 (13.3)
Odynophagia	1 (3)	1 (3.3)
Diplopia	1 (3)	3 (10)

GBS = Guillain-Barré Syndrome.

non-GBS vs. 37% in GBS) followed by impairments in olfaction (8% and 23% in non-GBS and GBS patients, respectively). The detailed distribution of symptoms associated with COVID-19 is found in Table II.

When considering the distribution of non-neurological COVID-19 symptoms based on patient GBS status, more GBS patients presented with a cough compared to non-GBS patients (63% vs. 32%, respectively) (Table II). More GBS presented with taste dysfunction (37% vs. 10%), dysarthria (13% vs. 0%), and dysphagia (13% vs. 0%) compared with non-GBS patients.

### Imaging

The distribution of utilized imaging investigations is shown in Table S3. Magnetic resonance imaging was performed in 36 patients, all of which reported no structural pathology contributing to their FNP (i.e., retro cochlear or middle ear pathology).

### Treatment

A summary of the management is shown in Table III. The non-GBS patients were most frequently treated with steroids ( $n = 25$ , 60%), followed by antivirals ( $n = 12$ , 29%), antibiotics ( $n = 9$ , 21%), symptom management/no treatment ( $n = 9$ , 21%), intravenous immunoglobulins (IVIG) ( $n = 4$ , 10%), hydroxychloroquine ( $n = 4$ , 10%), and physiotherapy ( $n = 2$ , 5%). On the other hand, patients with GBS were most treated with IVIG ( $n = 24$ , 80%), followed by hydroxychloroquine ( $n = 12$ , 43%), plasmapheresis ( $n = 8$ , 27%), steroids ( $n = 7$ , 23%), antivirals ( $n = 6$ , 21%), antibiotics ( $n = 6$ , 21%), and physiotherapy ( $n = 1$ , 3%).

### Recovery Outcomes: Non-GBS Versus GBS

More patients presenting without GBS had complete recovery of their FNP symptoms compared to those with GBS (67% vs. 13% respectively; Table I). Among those with complete recovery in the non-GBS group, the majority (80%) did not have any additional neurological symptoms, whereas a minority (20%) had further cranial nerve involvement. Fifty-three percent ( $n = 8$ ) of those

15 patients treated with steroids in the non-GBS group completely recovered within 60 days. In contrast, only 15% ( $n = 2/13$ ) of the GBS patients treated with IVIG achieved complete FNP recovery within 44 days. There was insufficient data on steroid therapy among GBS patients to compare outcomes to non-GBS patients.

### DISCUSSION

This systematic review summarizes FNP in the context of COVID-19 infections highlighting patients with systemic autoimmune pathology of GBS and isolated FNP (non-GBS). Most patients had moderate FNP as graded on the HB scale. Of the reported non-neurological COVID-19 symptoms, the most common were fever and cough. Patients with and without GBS during COVID-19 infections presented and progressed with FNP differently, with GBS patients typically presenting with a delayed onset, more severe FNP, and worse facial nerve outcomes. Additionally, the clinical course of isolated FNP associated with COVID-19 appears to differ from typical Bell's palsy. Non-GBS FNP patients had a shorter duration to complete recovery and a higher proportion of bilateral FNP compared to Bell's palsy patients. This suggests that we may be observing an etiology different than Bell's palsy patients with differing presentation and prognosis.

Patients diagnosed with GBS were on average older than non-GBS patients and the duration from the onset of COVID-19 symptoms to the manifestation of FNP differed considerably between the GBS and non-GBS diagnosed subgroups. The most common treatments for non-GBS patients consisted of steroids, antivirals, and antibiotics. Complete recovery of FNP in non-GBS patients was achieved in over two thirds of patients within an average of under 3 weeks. In contrast, only 17% of GBS patients achieved complete recovery of FNP within an average of over a month.

### Clinical Presentation

The initial COVID-19 symptoms including cough, fever, and dyspnea can be challenging to interpret as they are similar to common upper respiratory tract infections. With the advent of COVID-19, clinical suspicion of these symptoms has become increasingly recognized and should also be considered when taking a history from a patient presenting with acute FNP. In the context of known viral etiologies related to FNP, COVID-19 infected patients presented differently. For example, when evaluating the non-GBS patient category, most patients with FNP after COVID-19 infection (70%) presented on average 9 days (1–20 days) after the onset of initial COVID-19 symptom(s). In comparison, FNP secondary to Ramsay Hunt syndrome typically presents either before or concurrently with the typical manifestations including VZV blisters.<sup>64,65</sup>

In terms of laterality, bilateral FNP is an extremely rare clinical manifestation of Bell's palsy, accounting for only up to 2% of these patients.<sup>66–69</sup> In comparison, a larger proportion (12%) of the isolated FNP patients in

TABLE III.  
Patient Management.

Treatment	Non-GBS (%)	GBS (%)
Steroids	25 (60)	7 (23.3)
Antivirals	12 (29)	6 (21.4)
Antibiotics	9 (21)	6 (21.4)
Hydroxychloroquine	4 (10)	12 (42.9)
IVIG	4 (10)	24 (80)
Plasmapheresis	0	8 (26.7)
Physiotherapy	2 (5)	1 (3.3)
No treatment	9 (21)	0

GBS = Guillain-Barré Syndrome; IVIG = intravenous immunoglobulins.

this review presented with bilateral FNP. This may be explained by the potentially greater inflammatory impact of the COVID-19 virus on the facial nerve that has been previously hypothesized.<sup>6</sup> In our study, approximately 75% of the GBS patients presented with bilateral FNP which was higher than non-GBS patients. Unlike Bell's palsy, GBS has systemic involvement, more severe symptoms, and highly variable clinical course and outcome.<sup>70</sup>

Lastly, a small minority (11%) of the non-GBS patients presented with FNP as either their presenting or sole symptom of COVID-19 during an active infection. These findings highlight the importance of considering COVID-19 infection in the differential diagnosis when evaluating patients with isolated FNP symptoms who may otherwise be asymptomatic. An RT-PCR for COVID-19 may be considered in an infectious work-up of patients presenting with isolated FNP.

### **Treatments and Outcomes**

The most common treatment for non-GBS patients consisted of steroids, antivirals, and/or antibiotics. Twenty percent of patients had no treatment. According to the American Academy of Neurology (AAN) and the American Academy of Otolaryngology-Head and Neck Surgery Foundation (AAO-HNSF), the treatment of Bell's palsy primarily focuses on the use of corticosteroids and advises against the routine use of antiviral therapy.<sup>71-73</sup> However, previous studies have shown that treatment of FNP from Bell's palsy and RHS with acyclovir and prednisone leads to better outcomes.<sup>74,75</sup> Half of those treated with steroids and half of patients treated with antiviral therapy had complete recovery within 60 days. Among our non-GBS patients, there were no differences in outcomes between prednisone monotherapy and the combination therapy with antivirals.

Our findings suggest that patients with GBS who develop FNP were more likely to develop severe presentations and were more prone to worse clinical outcomes. Patients presenting with FNP in the context of GBS were most treated with IVIG, followed by hydroxychloroquine, plasmapheresis, and/or steroids. The first line treatments for GBS are plasma exchange or IVIG therapy which should be initiated within 7 and 14 days of symptom onset, respectively, to hasten recovery.<sup>76</sup> In contrast, corticosteroids are not recommended for the treatment of GBS, as several clinical trials have shown no benefit in recovery outcomes compared to placebo.<sup>77</sup> This could explain why steroids were much less commonly used in our GBS patients compared to plasmapheresis and IVIG. Importantly, patients presenting with GBS and FNP were over three times less likely to have complete recovery of FNP compared to non-GBS patients. This can be explained by the systemic involvement of GBS with more severe symptoms, and highly variable clinical course and outcome.<sup>70</sup>

When comparing patients with Bell's palsy, FNP associated with COVID-19 infection appeared to have a shorter time to complete recovery. Complete recovery of FNP in non-GBS patients was achieved in over two thirds of patients within almost 20 days with and without

treatments. Previous studies on the natural history of Bell's palsy have suggested that approximately 85% of patients begin to experience some recovery of their FNP within the first 3 weeks.<sup>71</sup> However, complete recovery of Bell's palsy with steroid treatment is typically seen in 3–9 months and our study was limited in terms of follow up duration.<sup>78</sup> In our non-GBS cohort, complete recovery was achieved in the majority (62%) within the first 2 months.

Although our study did not identify any significant predictors of FNP outcomes related to treatment for COVID-19 patients, this is likely due to the limited sample size, and is an area for future research.

### **Etiology**

Infectious etiology of FNP has a broad differential. Presumed culprits include HSV, VZV, EBV, and *Borrelia burgdorferi*. With the advent of COVID-19, our results suggest that the etiology of FNP in non-GBS COVID-19 patients is potentially novel.

COVID-19 has been hypothesized to cause neurologic damage by two distinct mechanisms: (1) dissemination to the central nervous system by hematogenous spread or trans-neuronally via cranial nerves causing direct neuronal damage due to viral neurotropism and (2) neuronal damage secondary to an abnormal immune-mediated response.<sup>6,79</sup> The first is thought to be responsible for cranial nerve manifestations (e.g., hypogeusia, hyposmia, headache, and vertigo), whereas the latter mechanism is believed to result in severe complications and contribute to the development of dysimmune neuropathies like GBS.<sup>13,80</sup>

Our findings indicate that among the non-GBS patients, a suggestion can be made of an association between COVID-19 and a clinical manifestation of FNP, although no causation can be assumed. Although the acute onset and age distribution of the non-GBS patients present similarly to Bell's palsy, the differences in clinical presentations and outcomes should be considered. The non-GBS subgroup had a relatively shorter duration to complete recovery and a higher proportion of bilateral FNP compared to Bell's palsy patients.<sup>69,78</sup>

This study is not without limitations. Firstly, a full infectious work-up to rule out other potential infectious causes of FNP was done in only 41% patients, although it was non-contributory except for one patient who also had an active concurrent EBV infection. Secondly, there was variability in the length of follow-up with the majority being 60 days or less and thus long-term outcomes data are limited. Since the full recovery of Bell's palsy typically occurs within a year, this limitation may be underestimating the recovery in our patients. Furthermore, we did not discuss treatment specific outcomes as we were unable to control for multiple patient specific variables and concurrent treatments. Another important limitation is that case reports and case series are more likely to report severe manifestations of COVID-19. Therefore, the patients included in our study may not represent the complete spectrum of FNP associated COVID-19, and instead could underestimate the true prevalence of mild, undifferentiated, or undiagnosed cases. Additionally, the

onset of FNP was determined relative to patient awareness of related COVID-19 symptom(s) which may have been non-specific and may not have been accurately reported. Finally, since the completion of our literature search in November 2021, subsequent omicron and delta variants may not have been adequately represented in our results. Despite these limitations, this study is the first systematic review on patients with COVID-19 and FNP and may help advance knowledge and guide management of these patients.

## CONCLUSION

Although COVID-19 symptoms are predominantly respiratory, emerging evidence has highlighted various neurologic manifestations associated with COVID-19 infections. Our study highlights and delineates the presentations of FNP in the context of COVID-19 for systemic conditions such as GBS as well as an isolated FNP. Systemic and isolated cases of FNP during COVID-19 infections present and progress differently. Additionally, the clinical course of isolated FNP associated with COVID-19 appears to differ from typical Bell's palsy presentation and prognosis. This suggests that patients with COVID-19 may have an atypical presentation of Bell's palsy with a more severe initial presentation and a relatively better prognosis with higher propensity for complete recovery. This review suggests COVID-19 infection may be associated with the development of a unique clinical manifestation of FNP. There is some literature associating FNP with COVID-19, although a causal association cannot be definitively assumed. Our study may help future practitioners in identifying FNP as a possible sequela of COVID-19 infection that may aid in the management of these patients.

## REFERENCES

- Movérare T, Lohmander A, Hultcrantz M, Sjögreen L. Peripheral facial palsy: speech, communication and oral motor function. *Eur Ann Otorhinolaryngol Head Neck Dis.* 2017;134(1):27-31.
- Lorch M, Teach SJ. Facial nerve palsy: etiology and approach to diagnosis and treatment. *Pediatr Emerg Care.* 2010;26(10):763-769.
- Karalok ZS, Taskin BD, Ozturk Z, Gurkas E, Koc TB, Guven A. Childhood peripheral facial palsy. *Childs Nerv Syst.* 2018;34(5):911-917. <https://doi.org/10.1007/s00381-018-3742-9>.
- Jeon Y, Lee H. Ramsay Hunt syndrome. *J Dent Anesth Pain Med.* 2018;18(6):333-337.
- Goh Y, Beh DLL, Makmur A, Somani J, Chan ACY. Pearls & Oysters: facial nerve palsy in COVID-19 infection. *Neurology.* 2020;95(8):364-367.
- Lima MA, Silva MTT, Soares CN, et al. Peripheral facial nerve palsy associated with COVID-19. *J Neurovirol.* 2020;26(6):941-944.
- Figueiredo R, Falcão V, Pinto MJ, Ramalho C. Peripheral facial paralysis as presenting symptom of COVID-19 in a pregnant woman. *BMJ Case Rep.* 2020;13(8):e237146.
- Brisca G, Garbarino F, Carta S, et al. Increased childhood peripheral facial palsy in the emergency department during COVID-19 pandemic. *Pediatr Emerg Care.* 2020;36(10):E595-E596.
- Mackenzie N, Lopez-Coronel E, Dau A, et al. Concomitant Guillain-Barre syndrome with COVID-19: a case report. *BMC Neurol.* 2021;21(1):135.
- Ottaviani D, Boso F, Tranquillini E, et al. Early Guillain-Barré syndrome in coronavirus disease 2019 (COVID-19): a case report from an Italian COVID-hospital. *Neurol Sci.* 2020;41(6):1351-1354.
- Bsates S, Olson B, Gaur S, et al. Bell's palsy associated with SARS-CoV-2 infection in a 2-year-old child. *J Pediatr Neurol.* 2021;19(6):440-442.
- Jasti AK, Selmi C, Sarmiento-Monroy JC, Vega DA, Anaya JM, Gershwin ME. Guillain-Barré syndrome: causes, immunopathogenic mechanisms and treatment. *Expert Rev Clin Immunol.* 2016;12(11):1175-1189.

- Abu-Rumeileh S, Abdelhak A, Foschi M, Tumani H, Otto M. Guillain-Barré syndrome spectrum associated with COVID-19: an up-to-date systematic review of 73 cases. *J Neurol.* 2021;268(4):1133-1170.
- Walling AD, Dickson G. Guillain-Barre syndrome. *Am Fam Physician.* 2013;87(3):191-197.
- House JW, Brackmann DE. Facial nerve grading system. *Otolaryngol Head Neck Surg.* 1985;93(2):146-147.
- Cabrera Muras A, Carmona-Abellán MM, Collía Fernández A, Uterga Valiente JM, Antón Méndez L, García-Moncó JC. Bilateral facial nerve palsy associated with COVID-19 and Epstein-Barr virus co-infection. *Eur J Neurol.* 2021;28(1):358-360.
- Chan JL, Ebadi H, Sarna JR. Guillain-Barré syndrome with facial diplegia related to SARS-CoV-2 infection. *Can J Neurol Sci.* 2020;47(6):1-854.
- Chan M, Han SC, Kelly S, Tamimi M, Giglio B, Lewis A. A case series of Guillain-Barré syndrome after COVID-19 infection in New York. *Neurol Clin Pract.* 2021;11(4):e576-e578.
- Chaumont H, San-Galli A, Martino F, et al. Mixed central and peripheral nervous system disorders in severe SARS-CoV-2 infection. *J Neurol.* 2020;267(11):1-3127.
- Corrêa DG, Hygino da Cruz LC, Lopes FCR, et al. Magnetic resonance imaging features of COVID-19-related cranial nerve lesions. *J Neurovirol.* 2021;27(1):1.
- Dahl EH, Mosevoll KA, Cramariuc D, Vedeler CA, Blomberg B. COVID-19 myocarditis and postinfection Bell's palsy. *BMJ Case Rep.* 2021;14(1):e240095.
- de Freitas Ribeiro BN, Marchiori E. Facial palsy as a neurological complication of SARS-CoV-2. *Arq Neuropsiquiatr.* 2020;78(10):667.
- Derollez C, Alberto T, Leroi I, Mackowiak MA, Chen Y. Facial nerve palsy: an atypical clinical manifestation of COVID-19 infection in a family cluster. *Eur J Neurol.* 2020;27(12):2670-2672.
- Doo FX, Kassim G, Lefton DR, Patterson S, Pham H, Belani P. Rare presentations of COVID-19: PRES-like leukoencephalopathy and carotid thrombosis. *Clin Imaging.* 2021;69:94-101.
- Gogia B, Gil Guevara A, Rai PK, Fang X. A case of COVID-19 with multiple cranial neuropathies. *Int J Neurosci.* 2020;1-3. <https://doi.org/10.1080/00207454.2020.1869001>.
- González-Castro A, Rodríguez ER, Arnaiz F, Pargada DF. Parálisis facial periférica en pacientes con SARS-CoV-2 en decúbito prono. *Rev Neurol.* 2021;72(8):296-297.
- Guilmot A, Maldonado Sloopjes S, Sellimi A, et al. Immune-mediated neurological syndromes in SARS-CoV-2-infected patients. *J Neurol.* 2021;268(3):751-757.
- Homma Y, Watanabe M, Inoue K, Moritaka T. Coronavirus disease-19 pneumonia with facial nerve palsy and olfactory disturbance. *Intern Med.* 2020;59(14):1773-1775.
- Hutchins KL, Jansen JH, Comer AD, et al. COVID-19-associated bifacial weakness with paresthesia subtype of Guillain-Barré syndrome. *AJNR Am J Neuroradiol.* 2020;41(9):1707-1711.
- Juliao Caamaño DS, Alonso Beato R. Facial diplegia, a possible atypical variant of Guillain-Barré syndrome as a rare neurological complication of SARS-CoV-2. *J Clin Neurosci.* 2020;77:230-232.
- Kaplan AC. Noteworthy neurological manifestations associated with COVID-19 infection. *Cureus.* 2021;13(4):e14391.
- Khaja M, Roa Gomez GP, Santana Y, et al. A 44-year-old Hispanic man with loss of taste and bilateral facial weakness diagnosed with Guillain-Barré syndrome and Bell's palsy associated with SARS-CoV-2 infection treated with intravenous immunoglobulin. *Am J Case Rep.* 2020;21:e927956-e927951.
- Kilinc D, van de Pasch S, Doets AY, Jacobs BC, van Vliet J, Garssen MPJ. Guillain-Barré syndrome after SARS-CoV-2 infection. *Eur J Neurol.* 2020;27(9):1757-1758.
- Kumar V, Narayanan P, Shetty S, Mohammed AP. Lower motor neuron facial palsy in a postnatal mother with COVID-19. *BMJ Case Rep.* 2021;14(3):e240267.
- Lascano AM, Epiney JB, Coen M, et al. SARS-CoV-2 and Guillain-Barré syndrome: AIDP variant with a favourable outcome. *Eur J Neurol.* 2020;27(9):1751-1753.
- Manganotti P, Bellavita G, D'Acunto L, et al. Clinical neurophysiology and cerebrospinal liquor analysis to detect Guillain-Barré syndrome and polyneuritis cranialis in COVID-19 patients: a case series. *J Med Virol.* 2021;93(2):766-774.
- McDonnell EP, Altomare NJ, Parekh YH, et al. COVID-19 as a trigger of recurrent Guillain-Barré syndrome. *Pathogens.* 2020;9(11):1-9.
- Mehta S, Mackinnon D, Gupta S. Severe acute respiratory syndrome coronavirus 2 as an atypical cause of Bell's palsy in a patient experiencing homelessness. *CJEM.* 2020;22(5):1-610.
- Nanda S, Handa R, Prasad A, et al. Covid-19 associated Guillain-Barre syndrome: contrasting tale of four patients from a tertiary care centre in India. *Am J Emerg Med.* 2021;39:125-128.
- Neo WL, Ng JCF, Iyer NG. The great pretender—Bell's palsy secondary to SARS-CoV-2? *Clin Case Rep.* 2021;9(3):1175-1177.
- Ochoa-Fernández EG, Villora-Morcillo N, Taboas-Pereira A. Parálisis facial periférica en un paciente pediátrico sin factores de riesgo en el contexto de infección por SARS-CoV-2. *Rev Neurol.* 2021;72(5):177-178.
- Oke IO, Oladunjoye OO, Oladunjoye AO, Paudel A, Zimmerman R. Bell's palsy as a late neurologic manifestation of COVID-19 infection. *Cureus.* 2021;13(3):e13881.

43. Paybast S, Gorji R, Mavandadi S. Guillain-Barré syndrome as a neurological complication of novel COVID-19 infection: a case report and review of the literature. *Neurologist*. 2020;25(4):101-103.
44. Pelea T, Reuter U, Schmidt C, Laubinger R, Siegmund R, Walther BW. SARS-CoV-2 associated Guillain-Barré syndrome. *J Neurol*. 2021;268(4):1191-1194.
45. Pfeifferkorn T, Dabitz R, von Wernitz-Keibel T, Aufenanger J, Nowak-Machen M, Janssen H. Acute polyradiculoneuritis with locked-in syndrome in a patient with Covid-19. *J Neurol*. 2020;267(7):1-1884.
46. Pinna P, Grewal P, Hall JP, et al. Neurological manifestations and COVID-19: experiences from a tertiary care center at the frontline. *J Neurol Sci*. 2020;415:116969.
47. Rana S, Lima AA, Chandra R, et al. Novel coronavirus (COVID-19)-associated Guillain-Barré syndrome: case report. *J Clin Neuromuscul Dis*. 2020;21(4):240-242.
48. Reyes-Bueno JA, García-Trujillo L, Urbaneja P, et al. Miller-Fisher syndrome after SARS-CoV-2 infection. *Eur J Neurol*. 2020;27(9):1759-1761.
49. Saberi H, Tanha RR, Derakhshanrad N, Soltaninejad MJ. Acute presentation of third ventricular cavernous malformation following COVID-19 infection in a pregnant woman: a case report. *Neurochirurgie*. 2021;68(2):228-231.
50. Sancho-Saldaña A, Lambea-Gil Á, Capablo Liesa JL, et al. Guillain-Barré syndrome associated with leptomeningeal enhancement following SARS-CoV-2 infection. *Clin Med*. 2020;20(4):e93-e94.
51. Sedaghat Z, Karimi N. Guillain Barre syndrome associated with COVID-19 infection: a case report. *J Clin Neurosci*. 2020;76:233-235.
52. Tard C, Maurage CA, de Paula AM, et al. Anti-pan-neurofascin IgM in COVID-19-related Guillain-Barré syndrome: evidence for a nodo-paranodopathy. *Neurophysiol Clin*. 2020;50(5):397-399.
53. Taşlıdere B, Mehmetaj L, Özcan AB, Gülen B, Taşlıdere N. Melkersson-Rosenthal syndrome induced by COVID-19. *Am J Emerg Med*. 2021;41:262.e5-262.e7.
54. Tekin AB, Zanafalioglu U, Gulmez S, Akarsu I, Yassa M, Tug N. Guillain Barre syndrome following delivery in a pregnant woman infected with SARS-CoV-2. *J Clin Neurosci*. 2021;86:190-192.
55. Theophanous C, Santoro JD, Itani R. Bell's palsy in a pediatric patient with hyper IgM syndrome and severe acute respiratory syndrome coronavirus 2 (SARS-CoV-2). *Brain Dev*. 2021;43(2):357-359.
56. Tiet MY, Alshaiikh N. Guillain-Barré syndrome associated with COVID-19 infection: a case from the UK. *BMJ Case Rep*. 2020;13(7):e236536.
57. Toscano G, Palmerini F, Ravaglia S, et al. Guillain-Barré syndrome associated with SARS-CoV-2. *N Engl J Med*. 2020;382(26):2574-2576.
58. Wong PF, Craik S, Newman P, et al. Lessons of the month 1: a case of rhombencephalitis as a rare complication of acute COVID-19 infection. *Clin Med (Northfield Il)*. 2020;20(3):293-294.
59. Zain S, Petropoulou K, Mirchia K, Hussien A, Mirchia K. COVID-19 as a rare cause of facial nerve neuritis in a pediatric patient. *Radiol Case Rep*. 2021;16(6):1400-1404.
60. Abolmaali M, Heidari M, Zeinali M, et al. Guillain-Barré syndrome as a parainfectious manifestation of SARS-CoV-2 infection: a case series. *J Clin Neurosci*. 2021;83:119-122.
61. Almutairi A, Bin Abdulqader S, Alhameed M, Alit S, Alosaimi B. Guillain-Barré syndrome following COVID-19: a case report. *J Res Med Dent Sci*. 2021;9(3):7-10.
62. Bastola A, Sah R, Nepal G, et al. Bell's palsy as a possible neurological complication of COVID-19: a case report. *Clin Case Rep*. 2021;9(2):747-750.
63. Bigaut K, Mallaret M, Baloglu S, et al. Guillain-Barré syndrome related to SARS-CoV-2 infection. *Neurol Neuroimmunol Neuroinflamm*. 2020;7(5):785.
64. Kanerva M, Jones S, Pitkaranta A. Ramsay Hunt syndrome: characteristics and patient self-assessed long-term facial palsy outcome. *Eur Arch Otorhinolaryngol*. 2020;277(4):1235-1245.
65. Aizawa H, Ohtani F, Futura Y, Sawa H, Fukuda S. Variable patterns of varicella-zoster virus reactivation in Ramsay Hunt syndrome. *J Med Virol*. 2004;74(2):355-360.
66. Adour KK, Byl FM, Hilsinger RL, Kahn ZM, Sheldon MI. The true nature of Bell's palsy: analysis of 1,000 consecutive patients. *Laryngoscope*. 1978;88(5):787-801.
67. Adour KK, Swanson PJ. Facial paralysis in 403 consecutive patients: emphasis on treatment response in patients with Bell's palsy. *Trans Am Acad Ophthalmol Otolaryngol*. 1971;75(6):1284-1301.
68. Leibowitz U. Bell's palsy—two disease entities? *Neurology*. 1966;16(11):1105-1109.
69. McGovern FH. Bilateral Bell's palsy. *Laryngoscope*. 1965;75(7):1070-1080.
70. Van Den Berg B, Walgaard C, Drenthen J, Fokke C, Jacobs BC, Van Doorn PA. Guillain-Barré syndrome: pathogenesis, diagnosis, treatment and prognosis. *Nat Rev Neurol*. 2014;10(8):469-482.
71. Eviston TJ, Croxson GR, Kennedy PGE, Hadlock T, Krishnan AV. Bell's palsy: aetiology, clinical features and multidisciplinary care. *J Neurol Neurosurg Psychiatry*. 2015;86(12):1356-1361.
72. Baugh RF, Basura GJ, Ishii LE, et al. Clinical practice guideline: Bell's palsy. *Otolaryngol Head Neck Surg*. 2013;149:S1-S27.
73. Gronseth GS, Paduga R. Evidence-based guideline update: steroids and antivirals for Bell palsy: report of the guideline development subcommittee of the American academy of neurology. *Neurology*. 2012;79(22):2209-2213.
74. Tang IP, Lee SC, Shashinder S, Raman R. Outcome of patients presenting with idiopathic facial nerve paralysis (Bell's palsy) in a tertiary centre - a five year experience. *Med J Malaysia*. 2009;64(2):155-158.
75. Da Costa Monsanto R, Bittencourt AG, Bobato Neto NJ, Beilke SCA, Lorenzetti FTM, Salomone R. Treatment and prognosis of facial palsy on Ramsay Hunt syndrome: results based on a review of the literature. *Int Arch Otorhinolaryngol*. 2016;20(4):394-400.
76. Raphaël JC, Chevret S, Hughes RA, Annane D. Plasma exchange for Guillain-Barré syndrome. *Cochrane Database Syst Rev*. 2012;7:CD001798.
77. Hughes RA, Swan AV, van Koningsveld R, van Doorn PA. Corticosteroids for Guillain-Barré syndrome. *Cochrane Database Syst Rev*. 2006;2:CD001446.
78. Sullivan FM, Swan IR, Donnan PT, et al. Early treatment with prednisolone or acyclovir in Bell's palsy. *Clin Otolaryngol*. 2007;32(6):460.
79. Costello F, Dalakas MC. Cranial neuropathies and COVID-19: neurotropic and autoimmunity. *Neurology*. 2020;95(5):195-196.
80. Wang L, Shen Y, Li M, et al. Clinical manifestations and evidence of neurological involvement in 2019 novel coronavirus SARS-CoV-2: a systematic review and meta-analysis. *J Neurol*. 2020;267(10):2777-2789.