

Access this article online
Quick Response Code:

Website: www.e-tjo.org
DOI: 10.4103/2211-5056.354280

# Microbial profile of lacrimal system Dacryoliths in American Midwest patient population

Peter M. Kally<sup>1,2</sup>, Amro Omari<sup>1\*</sup>, Dianne M. Schlachter<sup>1,2</sup>, Robert Folberg<sup>1,3</sup>, Francesca Nesi-Eloff<sup>1,2</sup>

## Abstract:

**PURPOSE:** Dacryoliths of the canalicular pathway are classically attributed to *Actinomyces* species as the most common organism. However, global shifts toward *Streptococcus* and *Staphylococcus* species have been reported. The objective of this article is to update the American Midwest epidemiology of lacrimal system dacryoliths for targeted clinical treatment.

**MATERIALS AND METHODS:** A retrospective chart review from January 2015 to 2021 of patients with a history of surgical procedure for lacrimal removal of dacryolith for canaliculitis, canalicular obstruction, dacryocystitis, and nasolacrimal duct obstruction was included. Specimens were sent for histopathological evaluation and microbial culture.

**RESULTS:** A total of 48 specimens were included. The most common organism isolated for canalicular pathology was *Actinomyces* spp (23%), followed by *Staphylococcus* spp (21%) and *Streptococcus* spp (19%). Histopathological staining accounted for 45% of *Actinomyces* isolation when culture data inconclusive. In a subgroup analysis of lacrimal sac dacryoliths, the most common organism was *Staphylococcus* spp (29%). *Actinomyces* species were not isolated from the lacrimal sac or nasolacrimal duct.

**CONCLUSION:** *Actinomyces* maintains a microbial predominance in canalicular dacryoliths and requires careful culture and histopathological analysis for its fastidious nature. Lacrimal sac and nasolacrimal duct dacryolith found no isolates of *Actinomyces*, and the most common organism was *Staphylococcus*.

## Keywords:

Canaliculitis, dacryolith, epidemiology, lacrimal system, nasolacrimal duct obstruction

## Introduction

Lacrimal system dacryoliths are a well-known cause of primary canalicular and nasolacrimal duct obstruction.<sup>[1,2]</sup> Obstructive systems present with recurrent epiphora and discharge and cause lacrimal system stasis with subclinical microbial overgrowth. Prolonged obstruction can lead to clinically significant infections including canaliculitis and dacryocystitis.<sup>[3]</sup>

Clinical treatment is dependent on the surgical removal of the dacryolith obstruction, which

This is an open access journal, and articles are distributed under the terms of the Creative Commons Attribution-NonCommercial-ShareAlike 4.0 License, which allows others to remix, tweak, and build upon the work non-commercially, as long as appropriate credit is given and the new creations are licensed under the identical terms.

For reprints contact: WKHLRPMedknow\_reprints@wolterskluwer.com

is based on location. This is generally achieved with either punctoplasty with canalicular curettage, canaliculotomy, or dacryocystorhinostomy (DCR). Precedent or concurrent antibiotic usage is generally used to control an active infection.<sup>[1,4]</sup> The underlying microbial profile of dacryoliths can aid in empiric treatment for presenting infections of the lacrimal system. In general, the Gram-positive filamentous bacteria *actinomyces* has been considered the most common causative pathogen.<sup>[2,5]</sup>

However, in recent reports from Asia, there is a geographic change to *streptococcus* and

**How to cite this article:** Kally PM, Omari A, Schlachter DM, Folberg R, Nesi-Eloff F. Microbial profile of lacrimal system Dacryoliths in American Midwest patient population. Taiwan J Ophthalmol 2022;12:330-3.

<sup>1</sup>Department of Ophthalmology, Beaumont Eye Institute, Royal Oak, Michigan, USA,

<sup>2</sup>Consultants in Ophthalmic and Facial Plastic Surgery, Southfield, Michigan, USA,

<sup>3</sup>Wayne State University School of Medicine, Detroit, Michigan, USA

## \*Address for correspondence:

Dr. Amro Omari,  
Beaumont Eye Institute,  
3535 West 13 Mile Road  
Suite #555, Royal Oak  
48073, Michigan, USA.  
E-mail: amro.omari@beaumont.org

Submission: 22-04-2022  
Accepted: 22-05-2022  
Published: 22-08-2022

*staphylococcus* as the most common pathogens.<sup>[4,6,7]</sup> Further, when subdividing out lacrimal sac from canalicular dacryoliths, there are fewer reports of *Actinomyces* as a pathogen.<sup>[1,3]</sup> The objective of this article is to update the American Midwest epidemiologic microbial profile of lacrimal system dacryoliths to optimize empiric antimicrobial therapy and improve clinical outcomes.

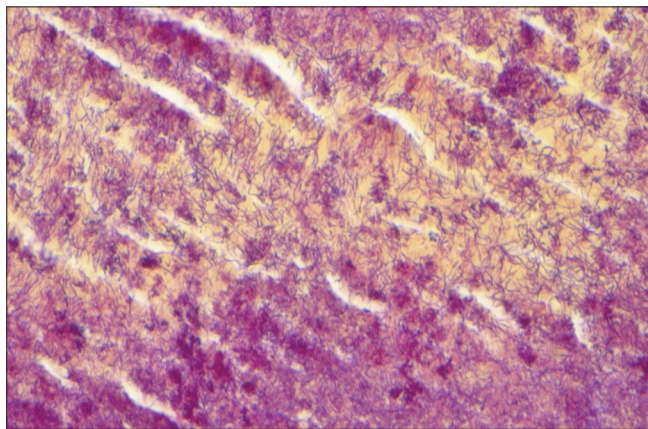
## Materials and Methods

A single-center retrospective chart review from January 2015 to 2021 was conducted with IRB approval from Beaumont Health (#2021-126) and adhered to the tenets of the Declaration of Helsinki. Patients with a history of surgical removal of lacrimal or canalicular dacryolith were identified and included primary canaliculitis, canalicular obstruction, dacryocystitis, and nasolacrimal duct obstruction. Secondary canaliculitis, other foreign body causing nasolacrimal duct obstruction, or lack of culture data were excluded from the study.

Pertinent clinical and demographic data were collected. All specimens were sent for microbial anaerobic and aerobic culture and submitted to ophthalmic pathology for histopathological diagnosis. All specimens were evaluated with Brown and Hopps Gram-stain. Gomori's methenamine-silver stain and periodic acid-Schiff stain were run as necessary. Isolated pathogens were recorded and cross-referenced to microbial culture data. *Actinomyces* was diagnosed presumptively if the ophthalmic pathologist determined gram-positive filamentous organisms on examination [Figure 1]. Statistical analysis was performed with R for mean, standard deviation, and Fischer exact test.

## Results

Eighty-one patients were identified, 19 were removed for secondary canaliculitis or foreign body obstruction



**Figure 1:** Histopathology of canalicular dacryolith showing numerous branching filamentous gram-positive bacteria consistent with *Actinomyces* (Brown and Hopps stain, x60. Insert: hematoxylin-eosin, x2)

and 14 for incomplete culture data. Of the 48 patients included, the average age was 64 years (range 4–92 years) with a female-to-male ratio of 5:1. Forty-one (85%) were located in the canaliculus and 7 (15%) in the lacrimal sac. Pathogen frequency of canalicular dacryolith by culture and histopathology is shown in Table 1. The most common organism isolated was *Actinomyces* spp (23%), followed by *Staphylococcus* spp (21%) and *Streptococcus* spp (19%). Histopathological staining accounted for 45% of *Actinomyces* determination when culture data was not conclusive. Of lacrimal sac and nasolacrimal duct dacryolith subgroup [Table 2], the most common organism was *Staphylococcus* spp (29%) with no *Actinomyces* identified.

## Discussion

Lacrimal system dacryoliths are commonly misdiagnosed and are generally recurrent if not surgically treated. They can be present in up to 1%–2% of patients presenting with epiphora and are reported to be present in 6%–18% of DCR surgeries.<sup>[1-4]</sup> Given the prevalence, understanding

**Table 1: Frequency of pathogens isolated from dacryoliths removed for primary canalicular obstruction or nasolacrimal duct obstruction.**

Pathogen (n=48)	Number of cases (%)
<i>Actinomyces</i> spp	11 (23)*
<i>Staphylococcus</i> spp	10 (21)
<i>Streptococcus</i> spp	9 (19)
<i>Fusobacterium nucleatum</i>	4 (8)
<i>Peptostreptococcus</i> spp	4 (8)
<i>Parvimonas micra</i>	3 (6)
<i>Propionibacterium</i> spp	3 (6)
<i>Serratia marcescens</i>	3 (6)
Fungal spp*	3 (6)
<i>Escherichia Coli</i>	2 (4)
<i>Prevotella</i> spp	2 (4)
<i>Pseudomonas aeruginosa</i>	2 (4)
<i>Gemella morbillorum</i>	2 (4)

\*Histopathologic staining yielded 5/11 (45%) of positive cases. \*Includes one *Candida Albicans*, one *Aspergillus fumigatus*, one non-specific yeast. The following bacteria were positive in only one case (2%): *Proteus mirabilis*, *Klebsiella oxytoca*, *Enterobacter cloacae*, *Capnocytophaga sputigena*, *Aggregatibacter aphrophilus*, *Haemophilus influenzae*, *Stenotrophomonas maltophilia*.

**Table 2: Frequency of pathogens isolated from lacrimal sac dacryolith obtained during dacryocystorhinostomy.**

Pathogen (n=7)	Number of cases (%)
<i>Staphylococcus</i> spp	2 (29)
<i>Peptostreptococcus</i> spp	1 (14)
<i>Serratia marcescens</i>	1 (14)
<i>Escherichia Coli</i>	1 (14)
<i>Klebsiella oxytoca</i>	1 (14)
Fungal yeast forms	1 (14)
<i>Actinomyces</i> spp	0 (0)

the microbial background when encountered can aid in adjunctive treatment. Antibiotic usage may help decrease bacterial load or control an active infection; however, the definitive treatment is surgical removal of the obstruction.

The results of this study support a continued prevalence of *Actinomyces* in American Midwest canaliculac dacryoliths as previously described by Repp *et al.* 12 years prior.<sup>[3]</sup> The more recent studies supporting a shift to *Staphylococcus* and *Streptococcus* species in Asia may have a geographic difference in the microbiome although this reasoning is unlikely as the highest prevalence of *Actinomyces* species follows the equatorial belt specifically in the locations of prior publications.<sup>[8]</sup>

*Actinomyces* can be difficult to isolate on culture media. These bacteria are slow-growing, Gram-positive, anaerobic, Gram-positive branching filamentous rods. They are the most commonly isolated microbe, yet other viruses, bacteria, and fungi such as staphylococcus, streptococcus, and candida may also appear. Culture results can take between 5 and 20 days, and therefore, an incubation period of at least 10 days is required for conclusion of a negative culture.<sup>[9]</sup> As facultative anaerobes, they require a strictly anaerobic culture environment. Given the fastidious nature of such bacteria, culture data can be limited and a histopathological evaluation with bacterial and fungal evaluation can be critical in confirmation of the underlying cause.<sup>[5]</sup> However, with the appropriate staining, actinomyces species may be isolated in all histopathologic specimens. Therefore, H and E stains is necessary as a routine patient's care standard. Further investigations might include special stains for microorganisms, such as gram stain, Grocott, or Periodic acid Schiff. In our study, approximately 45% of the *Actinomyces* identified were on histopathology by an ocular pathologist when culture data was inconclusive. The main pathological characteristics of *Actinomyces* are blue-staining bacteria surrounded by an eosinophilic fibrillary coat, known as the Splendore-Hoeppli phenomenon, which was found by an ocular pathologist on the histopathological specimens in this study. This finding may explain prior study epidemiologic data using bacterial aerobic and anaerobic culture alone, limiting evaluation of *Actinomyces* without histopathological analysis.<sup>[4,6]</sup>

Many other bacteria have been pathologically reported in lacrimal excretory system dacryoliths. *Myroides* spp., *Stenotrophomonas maltophilia* and multi-drug resistant *Escherichia coli* have been reported in case-studies.<sup>[6,10-12]</sup> *Pseudomonas aeruginosa* was also found to be most common in secondary canaliculitis

from punctal plugs.<sup>[7]</sup> Anatomically, there appears to be a microbial difference in lacrimal sac dacryoliths cultured on DCR with less *Actinomyces* isolated from the lacrimal sac.<sup>[1,3]</sup> The subgroup analysis of specimens is in concordance, with no *Actinomyces* found in our lacrimal sac subgroup. However, this small sample size is insufficiently powered for statistical significance. Given the numerous and sometimes rare organisms associated with dacryoliths, clinicians should maintain a broad differential.

## Conclusion

In conclusion, the regional prevalence of *Actinomyces* in canaliculac dacryoliths is maintained. This data can be used to guide empiric therapy in the cases where culture data may be pending or inconclusive. Careful anaerobic culture with histopathological analysis of dacryolith specimens including staining to differentiate other bacteria, fungi, and viruses that may grow alongside *Actinomyces* is recommended. These infections can cause serious morbidity without appropriate treatment including orbital cellulitis and vision loss. Although a broad differential should always be maintained, this epidemiologic data may help the clinician isolate the causative organism, tailor patient counseling, and provide targeted treatment for lacrimal system dacryoliths.

## Financial support and sponsorship

Nil.

## Conflicts of interest

The authors declare that there are no conflicts of interests of this paper.

## References

1. Yazici B, Hammad AM, Meyer DR. Lacrimal sac dacryoliths: Predictive factors and clinical characteristics. *Ophthalmology* 2001;108:1308-12.
2. Balıkoğlu Yılmaz M, Şen E, Evren E, Elgin U, Yılmazbaş P. Canaliculitis awareness. *Turk J Ophthalmol* 2016;46:25-9.
3. Repp DJ, Burkat CN, Lucarelli MJ. Lacrimal excretory system concretions: Canaliculac and lacrimal sac. *Ophthalmology* 2009;116:2230-5.
4. Kim UR, Wadwekar B, Prajna L. Primary canaliculitis: The incidence, clinical features, outcome and long-term epiphora after snip-punctoplasty and curettage. *Saudi J Ophthalmol* 2015;29:274-7.
5. Freedman JR, Markert MS, Cohen AJ. Primary and secondary lacrimal canaliculitis: A review of literature. *Surv Ophthalmol* 2011;56:336-47.
6. Kaliki S, Ali MJ, Honavar SG, Chandrasekhar G, Naik MN. Primary canaliculitis: Clinical features, microbiological profile, and management outcome. *Ophthalmic Plast Reconstr Surg* 2012;28:355-60.
7. Huang YY, Yu WK, Tsai CC, Kao SC, Kau HC, Liu CJ. Clinical features, microbiological profiles and treatment outcome of

- lacrimal plug-related canaliculitis compared with those of primary canaliculitis. *Br J Ophthalmol* 2016;100:1285-9.
8. van de Sande WW. Global burden of human mycetoma: A systematic review and meta-analysis. *PLoS Negl Trop Dis* 2013;7:e2550.
  9. Valour F, Sénéchal A, Dupieux C, Karsenty J, Lustig S, Breton P, *et al.* Actinomycosis: Etiology, clinical features, diagnosis, treatment, and management. *Infect Drug Resist* 2014;7:183-97.
  10. Bansal O, Bothra N, Sharma S, Ali MJ. Multidrug-resistant *Escherichia coli* canaliculitis. *Ophthalmic Plast Reconstr Surg* 2020;36:e122-4.
  11. Habib M, Saunders PJ, Rubinstein TJ. *Stenotrophomonas maltophilia*-associated dacryocystitis in leukemia-infiltrated lacrimal sacs: Case and review of literature. *Ophthalmic Plast Reconstr Surg* 2021;37:e143-5.
  12. Ali MJ, Joseph J, Sharma S, Naik MN. Canaliculitis with isolation of myroides species. *Ophthalmic Plast Reconstr Surg* 2017;33:S24-5.