

Arthroscopic Autologous Bone Grafting for Hallux Sesamoid Fracture Nonunion Results in a High Rate of Complete Resolution



Kenichiro Nakajima, M.D.

Purpose: To review the outcomes of patients with hallux sesamoid fracture nonunion who underwent arthroscopic autologous bone grafting. **Methods:** Medical records of patients who underwent surgery between July 2017 and April 2020 were reviewed. The inclusion criterion was 2 years or more of follow-up. The exclusion criterion was less than 2 years of follow-up. Outcomes were assessed using the visual analog scale (VAS) for pain and the Japanese Society for Surgery of the Foot (JSSF) score. Improvements after surgery were analyzed using the Wilcoxon signed-rank test. **Results:** Eleven patients (3 women and 8 men) were enrolled. The mean age was 18.6 years (standard deviation [SD] \pm 10.3 years), and the mean body mass index was 21.9 kg/m² (SD \pm 2.5 kg/m²). The mean follow-up duration was 3.2 years (SD \pm 0.8 years). One patient had fracture nonunion in the fibular sesamoid and a hypoplastic tibial sesamoid. Another patient had fracture nonunion in the distal part of the congenital bipartite sesamoid. The other patients had fracture nonunion in the normal tibial sesamoids. The mean duration until bone union was 2.9 months (SD \pm 0.8 months). The mean duration until returning to sports was 5.3 months (SD \pm 3.6 months). The VAS score improved from 72.1 (SD \pm 15.2) preoperatively to 12.0 (SD \pm 26.7) postoperatively. The JSSF score improved from 58.7 (SD \pm 15.8) preoperatively to 95.0 (SD \pm 11.0) postoperatively ($P < 0.01$, respectively). All patients except the two previously described achieved a VAS score of 0 and a JSSF score of 100 postoperatively. The remaining 2 patients with congenitally distinct sesamoids and fractures had poor outcomes. No complications were observed. **Conclusions:** Nine of the 11 patients reported complete resolution. The remaining two patients with congenitally distinct sesamoids and fractures had poor outcomes.

Introduction

Although the first metatarsophalangeal (MTP) joint is anatomically small, it has an important role in supporting large propulsion during normal gait.¹ McBryde et al. reported that 80% of the body weight is loaded on the first MTP joint during barefoot walking, and this value increases from 200% to 300% during

exercise activity; furthermore, during running and jumping, this value increases to 800%.²

Sesamoid fractures comprise traumas associated with overload on the first MTP joint. Using a typical protocol, the hallux is slightly plantar-flexed and fixated for 4 to 6 weeks; then, it is gradually returned to normal activity after walking with partial weight-bearing.³ Most sesamoid fractures heal with proper treatment; however, a potential complication of conservative treatment for sesamoid fractures is nonunion.⁴ Although the incidence rate is unknown, this complication causes injured high-level athletes to be unable to return to participating in sports.³

Conservative treatment, including rest, medication, insoles, orthosis use, radial soundwave therapy, and platelet-rich plasma injection, was initially selected to treat hallux sesamoid fracture nonunion.⁵⁻⁸ Surgery is indicated when conservative treatment fails.

Operative treatments reported in the literature include open sesamoidectomy, arthroscopic sesamoidectomy, percutaneous screw fixation, and open autologous bone grafting.⁹⁻¹⁹ Among these, open sesamoidectomy is a major surgery. Good outcomes have

From the Department of Orthopedic Surgery, Yashio Central General Hospital, Saitama, Japan.

The author reports no conflicts of interest in the authorship and publication of this article. Full ICMJE author disclosure forms are available for this article online, as [supplementary material](#).

Received May 5, 2022; accepted July 25, 2022.

Address correspondence to Kenichiro Nakajima, M.D., Department of Orthopedic Surgery, Yashio Central General Hospital, 845 Minamikawasaki, Yashio-shi, Saitama 340-0814 Japan. E-mail: nakajimakenichiro@hotmail.co.jp

© 2022 THE AUTHORS. Published by Elsevier Inc. on behalf of the Arthroscopy Association of North America. This is an open access article under the CC BY-NC-ND license (<http://creativecommons.org/licenses/by-nc-nd/4.0/>). 2666-061X/22602

<https://doi.org/10.1016/j.asmr.2022.07.007>

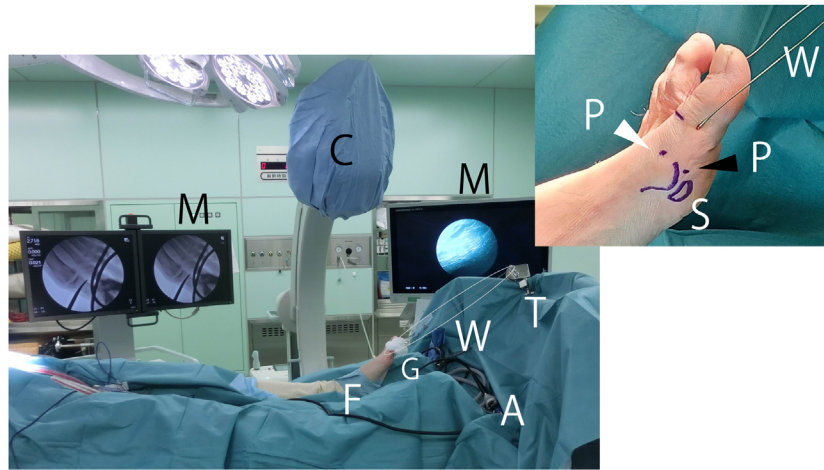


Fig 1. Operative field for arthroscopic autologous bone grafting for hallux sesamoid fracture nonunion. A transverse bar (T) for traction was attached to the distal end of the operating table. The patient was placed in the supine position on the operating table, and their feet were 40 cm away from the transverse bar during the arthroscopy maneuver (A). The arthroscopic monitor (M), C-arm (C), and fluoroscopic monitor (M) were placed caudally to cranially on the operated side. Direct traction was applied to the hallux at the proximal phalanx by the traction device (T) (Takasago Medical Industry Co.) pulling the soft wire (W). The hallux was wrapped with gauze (G) to avoid damage by the wire. The surgeon stood at the unoperated side. A planned dorsomedial portal (P, white arrowhead) was marked at the edge of the first metatarsophalangeal joint using an anteroposterior fluoroscopic view. The planned distal sesamoid portal (P, black arrowhead) was marked at the bottom of the joint using a lateral fluoroscopic view. The shape of the sesamoid (S) was also marked. A, arthroscopy; C, C-arm; F, foot; G, gauze; M, monitor; P, portal; S, sesamoid; T, traction device; W, soft wire.

been reported with open sesamoidectomy⁹⁻¹⁴; however, the complication rate is high.^{15,16} Nayfa et al. reported a case series of 19 patients who underwent sesamoidectomy; of these patients, 8 experienced postoperative hallux valgus.¹⁵ Shimozono et al. performed a systematic review of sesamoidectomy and reported a complication rate of 22.5%.¹⁶ Nakajima reviewed a case series of 14 patients who underwent arthroscopic sesamoidectomy; they reported that 12 of the 14 patients experienced some complications.¹⁷ The high occurrence of complications may be associated with the removal of the sesamoid.

Sesamoid-preserving procedures, including percutaneous screw fixation and open autologous bone grafting, may be more promising than sesamoidectomy.^{18,19} Regarding percutaneous screw fixation, Blundell et al. investigated a case series of 9 patients and reported that the American Orthopaedic Foot and Ankle Score improved from 46 to 80, and that no complications were observed.¹⁸ Regarding autologous bone grafting, Anderson and McBryde reviewed a case series of 21 patients and reported that 19 patients achieved bone union; the remaining 2 patients with persistent nonunion underwent sesamoidectomy later.¹⁹ They also reported that among 18 patients who answered follow-up questionnaires, 17 returned to their pre-injury level of sports and occupational activities.¹⁹ However, reports of these procedures are scarce; therefore, their effectiveness remains unclear.

The purpose of this study was to review the outcomes of patients with hallux sesamoid fracture nonunion who underwent arthroscopic autologous bone grafting. We hypothesized that this procedure would result in good outcomes and few complications.

Methods

This study was approved by the Institutional Review Board of Yashio Central General Hospital (approval number: YIHCE002-02). The medical records of patients with hallux sesamoid fracture nonunion who underwent arthroscopic autologous bone grafting from July 2017 to April 2020 after the failure of more than 6 months of conservative treatment were reviewed. Informed consent to use the medical records was acquired from the patients before surgery.²⁰ The inclusion criterion for this study was 2 years or more of follow-up. The exclusion criterion was less than 2 years of follow-up.

Surgical Technique

Arthroscopy of the first MTP joint was performed using Nakajima's method.²¹ A fluoroscopic monitor, C-arm, and arthroscopic monitor were placed cranially to caudally on the operated side, and a transverse bar for traction was set at the end of the table (Fig 1). The surgeon stood beside the unoperated feet. The proximal phalanx bone was drilled transversely using a 1.8-mm K-wire, and a 0.9-mm soft wire was passed through

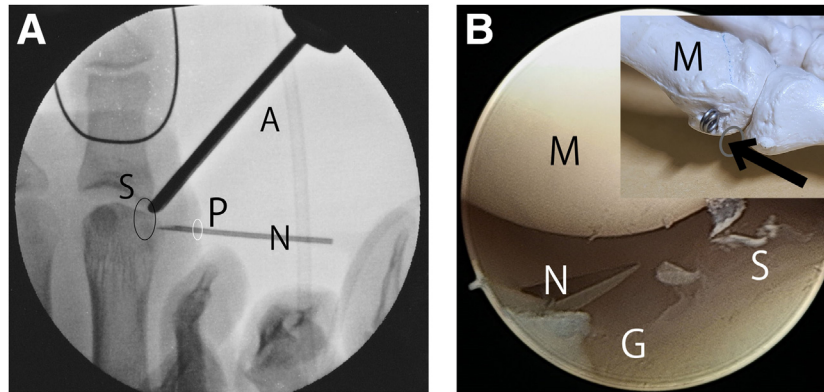


Fig 2. Creating the proximal sesamoid portal on the left foot for arthroscopic autologous bone grafting for hallux sesamoid fracture nonunion. (A) Fluoroscopic image. An 18-G needle was inserted into the joint in line with the diastasis of the sesamoid. A proximal sesamoid portal was created at the skin where the needle penetrated. A, arthroscope; N, needle; P, portal; S, sesamoid. (B) Arthroscopic image of the left foot from the distal sesamoid portal (gray ellipse) using a 2.3-mm, 30° arthroscope (Stryker). The arthroscope was directed toward the medial gutter (G, arrow). An 18-G needle (N) was introduced through the medial skin at the same level of the marked sesamoid and in line with the sesamoid diastasis under fluoroscopic guidance (A). When the needle (N) was identified arthroscopically in the medial gutter, the surgeon pulled the needle out. Subsequently, the no. 11 blade was introduced into the joint in the same direction as the needle to incise the skin and joint capsule to create a proximal sesamoid portal. G, medial gutter; M, metatarsal head; N, needle; S, tibial sesamoid.

the hole. Then, the soft wire was circled for traction. An adjustable traction device (Kent Retractor; Takasago Medical Industry, Tokyo, Japan) was attached to the transverse bar, and the traction hook of the device was connected to a circle. The hallux was wrapped with gauze to avoid damage by the soft wire (Fig 1).

A dorsomedial portal was marked at the medial edge of the first MTP joint using an anterolateral fluoroscopic view, and a distal sesamoid portal was marked at the bottom of the MTP joint using a lateral fluoroscopic view and surgical pen (Fig 1). Traction was applied to the hallux. A 5-mm skin incision was made at the planned dorsomedial portal, and blunt dissection was performed to reach the joint. A 2.3-mm, 30-degree arthroscope (Stryker, Kalamazoo, MI) was introduced into the joint and directed to the plantar site. The infusion pump (FloSteady Stryker) was set to the autocalibration mode.¹⁷ An 18-G needle penetrated the planned distal sesamoid portal in the joint. When the needle was identified, it was extracted; then, a no. 11 blade penetrated the skin and capsule in the same direction as the needle. The blade was extracted, and a 2.5-mm radiofrequency coagulator (SERFAS Energy Probes; Stryker) was introduced into the joint. Synovitis at the plantar site coagulated, and the tibial sesamoid was identified. The arthroscope and coagulator were extracted, and the arthroscope was subsequently introduced through the distal sesamoid portal. The arthroscope was directed to the medial gutter, an 18-G needle was introduced into the medial gutter in line with the diastasis of the sesamoid using an anteroposterior fluoroscopic view, and the needle was

identified arthroscopically (Fig 2). Then, the needle was removed, and a no. 11 blade was subsequently introduced in the same direction as the needle to incise 5 mm of the skin and capsule. This skin incision was called the proximal sesamoid portal. A 2.0-mm K-wire was introduced through the portal and advanced into the diastasis site. The K-wire was rotated manually such that the diastasis site was unstable (Fig 3). During manipulation, care was taken so that the K-wire did not penetrate the articular cartilage of the sesamoid.

The 2.0-mm K-wire was extracted. A 2.0-mm hooded abrasion bur (Formula Compatible; Stryker) was separated into the bur and hood. The bur was introduced and advanced into the diastasis, and the diastasis aspect of the sesamoid fragments was abraded manually (Fig 3). When the diastasis was sufficiently widened, the bur was extracted. Subsequently, the hooded bur was introduced, and power abrasion was performed until bleeding occurred. After abrasion, the arthroscope was introduced through the proximal sesamoid portal to confirm that the corresponding aspects of the two sesamoid fragments were bleeding (Fig 3).

Bone Graft Harvesting

A 2-cm skin incision was created on the iliac crest, and blunt dissection was performed to reach the ilium. After the periosteum was incised and denuded, the bone graft was harvested using an osteochondral autograft transfer system (Arthrex, Naples FL). The bone shape was cylindrical, with a diameter of 6 mm and a length of 15 mm (Fig 4). The defect of the ilium was filled with bone substitute material (Ostinate;

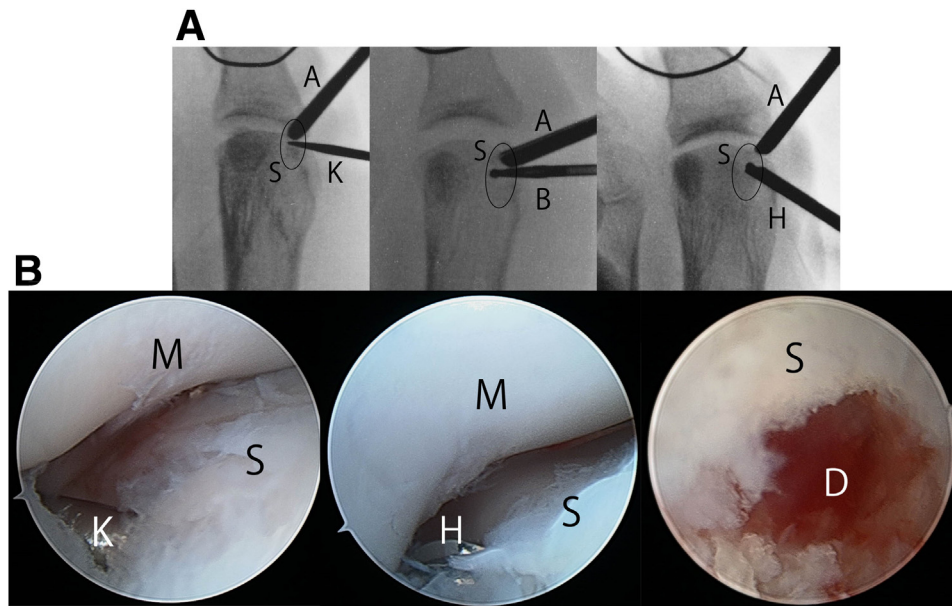


Fig 3. Debridement of the diastasis of the left tibial sesamoid under fluoroscopic and arthroscopic guidance for arthroscopic autologous bone grafting for hallux sesamoid fracture nonunion. (A) Fluoroscopic images showing debridement of the diastasis. The 2.0-mm K-wire (K) was introduced from the proximal sesamoid portal, advanced in the diastasis of the tibial sesamoid (ellipse), and revolved manually to make the fracture site unstable. Next, a 2.0-mm hooded bur (Stryker) was separated into the hood and the bur. The bur was introduced into the diastasis and revolved manually, so that the diastasis was debrided. Finally, the 2.0-mm hooded bur was introduced, and the diastasis aspects of the fragments of the sesamoid was power-abraded to induce bleeding. A, 2.3-mm arthroscope (Stryker); B, bur; K, 2.0-mm K-wire; H, 2.0-mm hooded bur (Stryker); S, tibial sesamoid. (B) Arthroscopic images from the distal sesamoid portal using a 2.3-mm, 30° arthroscope (Stryker), showing debridement of the diastasis of the left tibial sesamoid. Care was taken so that the K-wire and bur did not break the articular cartilage of the sesamoid. After debridement, the arthroscope was introduced through the proximal sesamoid portal to confirm that the corresponding aspects of the two sesamoid fragments were bleeding (D). D, diastasis site; M, metatarsal head; K, 2.0-mm K-wire; S, tibial sesamoid.

Zimmer Biomet, Warsaw, IN), and the cortical site of the bone was cut and returned to the ilium. After washing with saline, the periosteum and subcutaneous tissue were sutured with 3-0 polydioxanone sutures, and the skin was taped with Steri-Strip adhesive (3M; St. Paul, MN).

Bone Grafting Preparation

Cancellous bone harvested from the iliac crest was fragmented as much as possible (Fig 4). The hooded bur was separated into the hood and bur, and fragments of the bone graft were crammed into the hood using a bur. After filling the bone fragments with the hood, the bur was returned to the hood, and the fragments in the hood were confirmed fluoroscopically (Fig 4). The bone fragments were filled in the hood such that the length of the fragments was approximately twice that of the diastasis.

Bone Grafting

After filling the bone fragments with the hood, the arthroscope was introduced from the distal sesamoid

portal, and the hood was introduced from the proximal sesamoid portal and advanced in the diastasis until the tip of the hood reached the lateral edge of the diastasis under fluoroscopic and arthroscopic guidance (Fig 5). Bone grafting was performed by pulling out the hood while pushing the bone graft with a bur. When bone grafting was completed, the tips of the hood and bur were at the medial edge of the tibial sesamoid (Fig 5). The bone graft was confirmed arthroscopically (Fig 5). Finally, traction was released, the foot was rotated externally, and the bone graft placed in the diastasis was confirmed fluoroscopically (Fig 6). Incisions of the portals were sutured using 5-0 nylon.

Postoperative Management

Passive plantar flexion exercise of the hallux was initiated 1 day after surgery to prevent adhesion of the extension hood to the dorsomedial portal. The existence of adhesions was confirmed by active dorsiflexion. Passive dorsiflexion and active plantar flexion were not allowed until 6 weeks after surgery. Unrestricted range-of-motion exercises were initiated 6

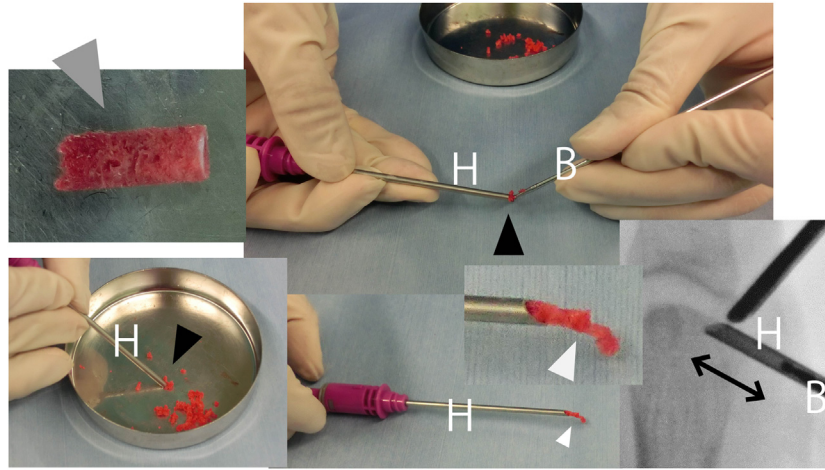


Fig 4. Preparation for arthroscopic autologous bone grafting for hallux sesamoid fracture nonunion. Cancellous bone (gray arrowhead) with a length of 15 mm and diameter of 6 mm was harvested from the ilium using an Osteochondral Autograft Transfer System (Arthrex). The cancellous bone was fragmented as much as possible. A 2.0-mm hooded bur (Stryker) was separated into the hood and the bur, and the bone fragments were crammed into the tip of the hood (black arrowhead). When the bur pushed the bone fragments into the hood, the bone fragments were extruded (white arrow). Using this method, the surgeon grafted the bone fragments in the diastasis of the sesamoid. Bone fragments in the hood were identified using a fluoroscope (arrow). B, bur; H, hood.

weeks after surgery. Walking with a postoperative shoe that reduced the weight-bearing pressure of the forefoot (OrthoWedge shoe; DARCO, Huntington, WV) was started 1 day after surgery. Walking without an orthosis was started at 6 weeks after surgery. Postoperative follow-up roentgenography was performed every 2 weeks. When X-ray imaging showed the appearance of bone union after 10 weeks postoperatively, CT of a 1-mm slice was performed to confirm complete union of the bone (Fig 7). Then, sports activities were initiated as tolerated.

Data Collection and Statistical Analysis

Data regarding age, sex, body mass index, preoperative and postoperative visual analog scale (VAS) scores, preoperative and postoperative Japanese Society for Surgery of the Foot (JSSF) scores,^{22,23} duration until bone union, and return to sports after surgery were obtained from the medical records. Preoperative data were obtained 1 month before surgery, and postoperative data were obtained during the final follow-up. The postoperative improvements were analyzed using the Wilcoxon signed-rank test. All tests were two-tailed, and differences were considered statistically significant at $P < 0.05$. All statistical analyses were performed using EZR version 1.38 (Saitama Medical Center, Jichi Medical University, Saitama, Japan), which is a modified version of R version 3.5.2 (The R Foundation for Statistical Computing, Vienna, Austria) designed to add statistical functions frequently used in biostatistics.^{17,24}

Results

Eleven patients (3 women and 8 men) were enrolled. The mean age was 18.6 years (standard deviation [SD] \pm 10.3; range: 13-49 years). The mean body mass index was 21.9 kg/m² (SD \pm 2.5 kg/m²; range: 19.2-26.3 kg/m²). The mean follow-up duration was 3.2 years (SD \pm 0.8 years; range: 2.1-4.8 years). One patient had fracture nonunion in the fibular sesamoid and a hypoplastic tibial sesamoid. Another patient had fracture nonunion in the distal part of the congenital bipartite sesamoid. The remaining patients had fracture nonunion in the normal tibial sesamoids. None of the patients have had apparent episodes of trauma. The mean duration until bone union was 2.9 months (SD \pm 0.8 months; range: 2-4 months). Ten patients participated in sports activities (baseball, 5; basketball, 1; cheerleading, 1; badminton, 1; street dancing, 1; karate, 1). The mean duration until return to sports was 5.3 months (SD \pm 3.6 months; range: 2-15 months) (Table 1).

The VAS score improved from 72.1 (SD \pm 15.2; range: 50-100) preoperatively to 12.0 (SD \pm 26.7; range: 0-70) postoperatively ($P < 0.01$). The JSSF score improved from 58.7 (SD \pm 15.8; range: 42-87) preoperatively to 95.0 (SD \pm 11.0; range: 69-100) postoperatively ($P < 0.01$). Nine of the 11 patients achieved a VAS score of 0 and JSSF score of 100 postoperatively (Table 1). No complications were observed.

Two patients had poor scores (patients 1 and 10 in Table 1). Patient 1 was the only patient with an affected fibular sesamoid and hypoplastic tibial sesamoid. Bone union was obtained at 5 months

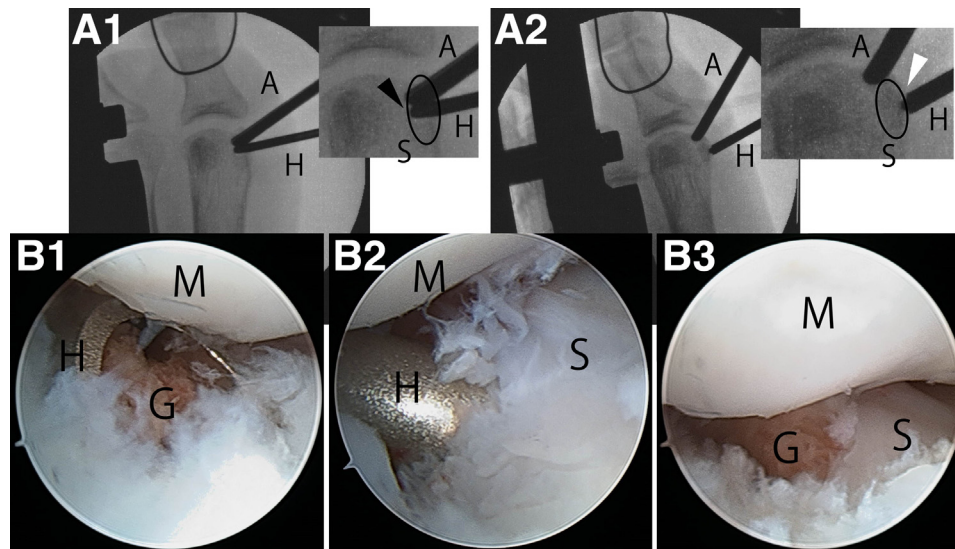


Fig 5. Arthroscopic autologous bone grafting for the left tibial sesamoid fracture nonunion. (A1) Fluoroscopic image at the beginning of bone grafting. The hood that contained the bone graft (H) was advanced in the diastasis of the tibial sesamoid (ellipse) until the tip of the hood reached the lateral edge of the diastasis (black arrowhead). (A2) Fluoroscopic image showing bone-grafting completion. The tips of the hood and bur were at the medial end of the diastasis (white arrowhead), which indicated that the bone fragments in the hood were left in the diastasis. (B1) Arthroscopic image from the distal sesamoid portal using a 2.3-mm, 30° arthroscope (Stryker), showing the beginning of bone grafting to the left tibial sesamoid. The tip of the hood (H) that contained the bone graft (G) was located at the medial entrance of the diastasis through the proximal sesamoid portal. (B2) The hood in the diastasis during the process of bone grafting. The location of the tip of the hood could not be identified arthroscopically; however, it was identified fluoroscopically. (B3) Arthroscopic image showing bone grafting completion. The bone graft (G) was visible in the diastasis. A, arthroscope; G, bone graft; H, hood; M, metatarsal head; S, sesamoid.

postoperatively, but the pain was not alleviated. This patient opted for arthroscopic sesamoidectomy, which was performed 1 year postoperatively, when the VAS score was 62 and JSSF score was 69 (Table 1). At the final follow-up after 4.8 years, the VAS score was 3 and the JSSF score was 85. Patient 10 had an affected tibial sesamoid, which is a congenital bipartite sesamoid, and fracture nonunion of the distal fragment. During surgery, the congenital diastasis and fracture sites were abraded, and bone grafting was performed at both sites. The diastasis site achieved bone union within 3 months, but bone union was not achieved at the distal fracture site until the final follow-up. The next treatment plan was pending at the final follow-up because the patient had not decided.

Discussion

In this study, the subjects' VAS scores improved from 72.1 to 12.0, and the JSSF score improved from 58.7 to 95.0. Nine of the 11 patients reported a VAS score of 0 and a JSSF score of 100. The remaining two patients with congenitally distinct sesamoids and fractures had poor outcomes. No complications were observed.

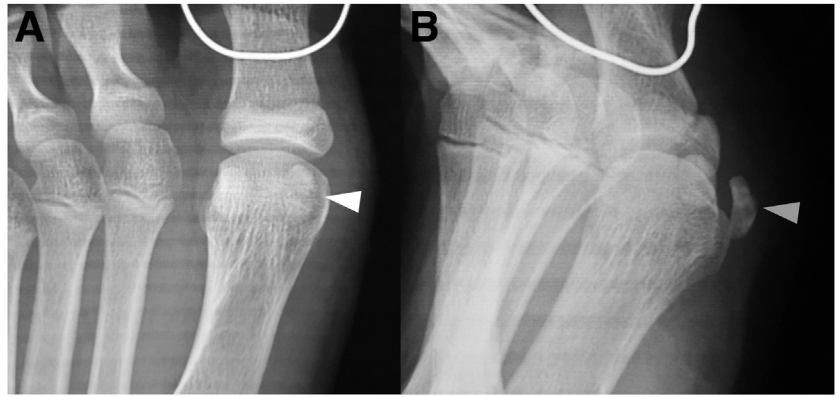
This study reviewed the outcomes of 11 patients with hallux sesamoid fracture nonunion who underwent arthroscopic autologous bone grafting. The VAS score improved from 72.1 to 12.0, and the JSSF score

improved from 58.7 to 95.0. Studies of several sesamoidectomies have been previously reported. Bichara et al. reported a case series of 24 patients with VAS scores that improved from 62 to 7.¹³ Canales et al. reported 5 patients with VAS scores that improved from 68 to 10.¹⁴ Nakajima reported a case series of 14 patients treated with arthroscopic sesamoidectomy who had VAS scores that improved from 75 to 14 and JSSF scores that improved from 55 to 88.¹⁷ These were all small case series; therefore, it is unclear whether our autologous bone grafting outcomes were better than the previously reported sesamoidectomy outcomes.

The mean duration until returning to sports was 5.3 months (SD \pm 3.6 months; range: 2-15 months). This result is consistent with those of previous studies of sesamoidectomy. Bichara et al. reported that 91% (22/24) returned to activities within a mean period of 11.6 weeks.¹³ Biedert and Hintermann reported five patients treated with open sesamoidectomy who returned to sports within 2.5 to 6 months.¹⁰ It is unclear which procedure resulted in an earlier return to sports because the case series study was small.

No complications were observed. Shimozono et al. performed a systematic review and reported that the complication rate of open sesamoidectomy was 22%.¹⁶ Nakajima studied 14 patients treated with arthroscopic sesamoidectomy and reported that 71% (12 of 14) of

Fig 6. Postoperative roentgenographs of arthroscopic autologous bone grafting for the left tibial hallux sesamoid fracture nonunion. (A) Antero-posterior view. The bone graft was less visible (white arrowhead) because it was cancellous bone that overlapped the metatarsal head. (B) External oblique view. The bone graft was visible (gray arrowhead).



patients had complications.¹⁷ The low complication rate of this study may be attributable to the low invasiveness of arthroscopic surgery and preservation of the sesamoid.

The mean duration until bone union during this study was 2.9 months (SD \pm 0.8 months; range: 2-4 months). Anderson and McBryde studied a case series of 18 patients treated with open autologous bone grafting and reported that the mean time until bone union was 12 weeks.¹⁹ The durations until bone union in our study and that of Anderson and McBryde were similar.

Among the 11 patients in our study, two patients (patients 1 and 10 in the Table 1) had poor outcomes. Patient 1 was the only patient with fibular sesamoid fracture nonunion. Moreover, the tibial sesamoid was hypoplastic. Bone union was achieved at 5 months postoperatively, but the pain persisted. This may have occurred because the fibular sesamoid continued to be highly stressed by hypoplasia of the tibial sesamoid.

Patient 10 had fracture nonunion of the distal fragment of the congenital bipartite tibial sesamoid. During surgery, bone grafting was applied to the congenital diastasis and fracture site. The proximal congenital diastasis achieved bone union, but the distal fracture site did not. A study of the blood supply for the sesamoid indicated that, in the normal sesamoid, the blood supply originates from the proximal, plantar, and distal sites; however, in the bipartite sesamoid, the blood supply originates from only the proximal and distal sites.²⁵ Moreover, the vessels in the bipartite sesamoid are narrower than those in the normal sesamoid, and the vessels in the distal site are narrower than those from the proximal site.²⁵ These anatomical characteristics may be associated with the results of patient 10 (the proximal diastasis achieved bone union, but the distal fracture site did not). Patients 1 and 10 had congenitally distinct sesamoids and fractures. In such cases, surgery may not be feasible.

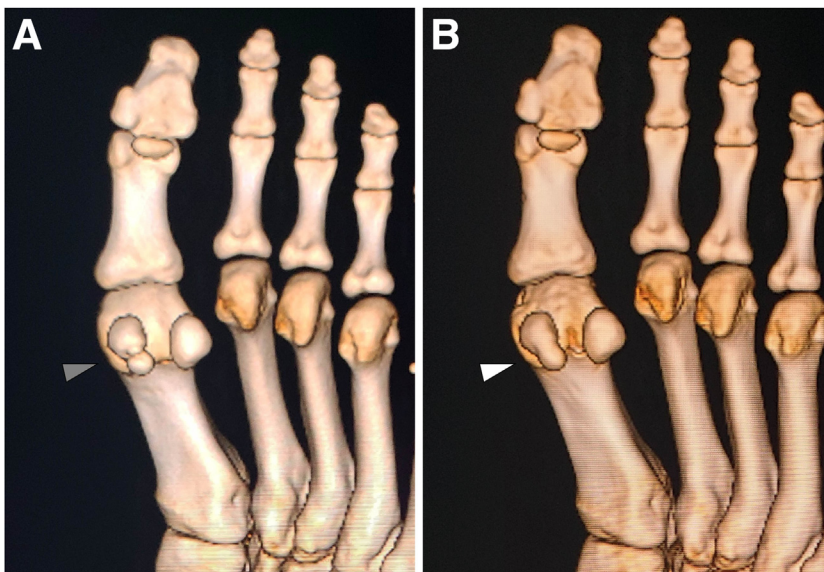


Fig 7. Preoperative and postoperative three-dimensional computed tomography (3D-CT) of the left tibial hallux sesamoid fracture nonunion treated with arthroscopic autologous bone grafting. (A) Preoperative 3D-CT. The diastasis was visible (gray arrowhead). (B) Postoperative 3D-CT after achieving bone union. The diastasis disappeared (white arrowhead).

Table 1. Demographics and Preoperative and Postoperative Results of 11 Patients With Hallux Sesamoid Fracture Nonunion Who Underwent Arthroscopic Autologous Bone Grafting

Number	Sex	Age	BMI	Follow-up (years)	Sesamoid Affected	Split Type	Preoperative VAS score	Postoperative VAS score	Preoperative JSSF Score	Postoperative JSSF Score	Bone Union	Sport	RTS (months)
1	Male	16	21.8	4.8	Fibular	FN	79	62*	67	69*	4	Basketball	4
2	Male	17	26.0	4.3	Tibial	FN	65	0	49	100	4	Karate	15
3	Female	22	20.5	4.2	Tibial	FN	100	0	87	100	2	Street dance	7
4	Female	17	21.0	3.2	Tibial	FN	65	0	86	100	2	Cheerleading	3
5	Male	14	23.4	3.2	Tibial	FN	90	0	47	100	2	Baseball	3
6	Male	13	23.1	3.1	Tibial	FN	87	0	52	100	3	Baseball	4.5
7	Male	14	19.2	3.0	Tibial	FN	66	0	55	100	4	Baseball	5
8	Female	49	26.3	2.8	Tibial	FN	50	0	67	100	3	NA	NA
9	Male	14	19.2	2.8	Tibial	FN	66	0	42	100	4	Baseball	5
10	Male	15	19.9	2.6	Tibial	BP & FN	70	70	47	77	3**	Badminton	5
11	Male	14	20.9	2.1	Tibial	FN	55	0	47	100	2	Baseball	2
Mean		18.6 ± 10.3	21.9 ± 2.5	3.2 ± 0.8	—	—	72.1 ± 15.2	12.0 ± 26.7	58.7 ± 15.8	95.0 ± 11.0	2.9 ± 0.8	—	5.3 ± 3.6

Preoperative data were obtained 1 month before surgery. Postoperative data were obtained at the final follow-up. Patient 1 had fibular sesamoid fracture nonunion, had poor outcomes after arthroscopic autologous bone grafting, and opted for arthroscopic sesamoidectomy. Postoperative VAS scores (*) were obtained at 1 year after the primary surgery, just before the secondary surgery. Patient 10 was the only patient whose congenital bipartite was the affected sesamoid. The distal fragment had fracture nonunion. During surgery, both the congenital diastasis and fracture site were bone grafted. **Diastasis achieved bone union 3 months after surgery. Bone union was not achieved at the fracture site until the final follow-up. BMI, body mass index; BP, bipartite sesamoid; FN, fracture nonunion; JSSF, Japanese Society for Surgery of the Foot; NA, not available; RTS, return to sports; VAS, visual analog scale.

Limitations

Our study had several limitations. First, the sample size was small. Second, only one elderly patient was enrolled in this study. Third, the follow-up period was relatively short. Finally, there was no comparison group because this study was a case series.

Conclusion

Nine of the 11 patients reported complete resolution. The remaining two patients with congenitally distinct sesamoids and fractures had poor outcomes.

Acknowledgments

The author would like to thank Elsevier for the English language review.

References

- Mason LW, Molloy AP. Turf toe and disorders of the sesamoid complex. *Clin Sports Med* 2015;34:725-739.
- McBride ID, Wyss UP, Cooke TD, et al. First metatarsophalangeal joint reaction forces during high-heel gait. *Foot Ankle Int* 1991;11:282-288.
- Kadokia AR, Molloy A. Current concepts review: Traumatic disorders of the first metatarsophalangeal joint and sesamoid complex. *Foot Ankle Int* 2011;32:834-849.
- York PF, Wydra FB, Hunt KJ. Injuries to the great toe. *Curr Rev Musculoskelet Med* 2017;10:104-112.
- Atiya S, Quah C, Pillai A. Sesamoiditis of the metatarsophalangeal joint. *OA Orthop* 2013;1:19.
- Saxena A, Yun A, Patel R, Gerdesmeyer L, Maffulli N. Radial soundwave for sesamoidopathy in athletes: A pilot study. *Foot Ankle Surg* 2016;55:1333-1335.
- Garrett KS, Bramlage LR, Spike-Pierce DL, Cohen ND. Injection of platelet- and leukocyte-rich plasma at the junction of the proximal sesamoid bone and the suspensory ligament branch for treatment of yearling Thoroughbreds with proximal sesamoid bone inflammation and associated suspensory ligament branch desmitis. *J Am Vet Med Assoc* 2013;243:120-125.
- Le HM, Stracciolini A, Stein CJ, Quinn BJ, Jackson SS. Platelet-rich plasma for hallux sesamoid injuries: A case series. *Phys Sportsmed* 2022;50:181-184.
- Leventen EO. Sesamoid disorders and treatment. An update. *Clin Orthop Relat Res* 1991;269:236-240.
- Biedert R, Hintermann B. Stress fractures of the medial great toe sesamoids in athletes. *Foot Ankle Int* 2003;24:137-141.
- Saxena A, Krisdakumtorn T. Return to activity after sesamoidectomy in athletically active individuals. *Foot Ankle Int* 2003;24:415-419.
- Lee S, James WC, Cohen BE, Davis WH, Anderson RB. Evaluation of hallux alignment and functional outcome after isolated tibial sesamoidectomy. *Foot Ankle Int* 2005;26:803-809.
- Bichara DA, Henn RF 3rd, Theodore GH. Sesamoidectomy for hallux sesamoid fractures. *Foot Ankle Int* 2012;33:704-706.
- Canales MB, DeMore M III, Bowen MF, Ehredt DJ Jr, Razzante MC. Fact or fiction? Iatrogenic hallux abductor

- valgus secondary to tibial sesamoidectomy. *J Foot Ankle Surg* 2015;54:82-888.
15. Nayfa TM, Sort LA. The incidence of hallux abductus following tibial sesamoidectomy. *J Am Podiatr Assoc* 1982;72:617-620.
 16. Shimozone Y, Hurley ET, Brown AJ, Kennedy JG. Sesamoidectomy for hallux sesamoid disorders: A systematic review. *Foot Ankle Surg* 2018;57:1186-1190.
 17. Nakajima K. Arthroscopic sesamoidectomy for hallux sesamoid disorders. *J Foot Ankle Surg* 2022;61:175-180.
 18. Blundell CM, Nicholson P, Blackney MW. Percutaneous screw fixation for fractures of the sesamoid bones of the hallux. *J Bone Joint Surg Br* 2002;84:1138-1141.
 19. Anderson RB, McBryde AM Jr. Autogenous bone grafting of hallux sesamoid nonunions. *Foot Ankle Int* 1997;18:293-296.
 20. Nakajima K. Sliding oblique metatarsal osteotomy fixated with a K-wire without cheilectomy for hallux rigidus. *J Foot Ankle Surg* 2022;61:279-285.
 21. Nakajima K. Arthroscopy of the first metatarsophalangeal joint. *J Foot Ankle Surg* 2018;57:357-363.
 22. Niki H, Aoki H, Inokuchi S, et al. Development and reliability of a standard rating system for outcome measurement of foot and ankle disorders. II: Interclinician and intraclinician reliability and validity of the newly established standard rating scales and Japanese Orthopaedic Association rating scale. *J Orthop Sci* 2005;10:466-474.
 23. Niki H, Aoki H, Inokuchi S, et al. Development and reliability of a standard rating system for outcome measurement of foot and ankle disorders. I: Development of standard rating system. *J Orthop Sci* 2005;10:457-465.
 24. Kanda Y. Investigation of the freely available easy-to-use software 'EZ' for medical statistics. *Bone Marrow Transplant* 2013;48:452-458.
 25. Sobel M, Hashimoto J, Arnoczky SP, Bohne WH. The microvasculature of the sesamoid complex: Its clinical significance. *Foot Ankle* 1992;13:359-363.