

Surgical treatment of bipolar segmental clavicle fracture: A case report

Lin Liang, Xin-Lei Chen, Ye Chen, Nian-Nian Zhang

Specialty type: Medicine, research and experimental

Provenance and peer review: Unsolicited article; Externally peer reviewed.

Peer-review model: Single blind

Peer-review report's scientific quality classification

Grade A (Excellent): 0

Grade B (Very good): 0

Grade C (Good): C, C

Grade D (Fair): 0

Grade E (Poor): 0

P-Reviewer: Khalifa AA, Egypt; Velázquez-Saornil J, Spain

Received: May 27, 2022

Peer-review started: May 27, 2022

First decision: July 13, 2022

Revised: July 21, 2022

Accepted: August 24, 2022

Article in press: August 24, 2022

Published online: October 16, 2022



Lin Liang, Nian-Nian Zhang, Department of Orthopedics, Shangyu People's Hospital of Shaoxing City, Shaoxing 312000, Zhejiang Province, China

Xin-Lei Chen, Ye Chen, Department of Orthopedics, Haimen People's Hospital, Nantong 226000, Jiangsu Province, China

Corresponding author: Xin-Lei Chen, Doctor, Doctor, Department of Orthopedics, Haimen People's Hospital, No. 1201 Beijing Middle Road, Haimen District, Nantong 226000, Jiangsu Province, China. chenxinleidoctor@sina.com

Abstract

BACKGROUND

Shoulder injuries caused by trauma are common, including clavicle fractures. Even so, bipolar segmental fracture of the clavicle is extremely rare and seldom reported. Therefore, there is still a controversial issue about how to treat these bipolar segmental clavicle fractures.

CASE SUMMARY

A 56-year-old security guard arrived at our emergency room after falling on his electric bicycle. There was no loss of consciousness or other pain. He had no numbness in his fingers. X-rays and 3D computed tomography revealed that the patient's right shoulder had a bipolar segmental clavicle fracture. The surgical procedure included both open reduction and internal fixation. At the 1-year follow-up, he had a full range of motion and minimal discomfort in the injured shoulder.

CONCLUSION

We provide a rare case of bipolar clavicle fracture in the right clavicle. We hold the opinion that such patients would get better clinical and radiological outcomes by early and correct operation.

Key Words: Bipolar segmental clavicle fracture; Arm sling; Open reduction and internal fixation; Acromioclavicular hook plate; Case report

©The Author(s) 2022. Published by Baishideng Publishing Group Inc. All rights reserved.

Core Tip: A rare case of bipolar clavicle fracture due to trauma is reported. Early operation provides a possibility for such patients to recover well later.

Citation: Liang L, Chen XL, Chen Y, Zhang NN. Surgical treatment of bipolar segmental clavicle fracture: A case report. *World J Clin Cases* 2022; 10(29): 10529-10534

URL: <https://www.wjgnet.com/2307-8960/full/v10/i29/10529.htm>

DOI: <https://dx.doi.org/10.12998/wjcc.v10.i29.10529>

INTRODUCTION

Clavicle fractures are a frequent occurrence in clinical practice. Considering the anatomy of the clavicle, more than 70% of clavicle fractures occur in the midshaft region[1]. However, due to the low occupancy of the clavicle, simultaneous fractures of the proximal and distal ends of the clavicle, also known as the bipolar clavicle fracture, are not frequently mentioned in the medical literature. It is frequently caused by high-energy trauma, such as automobile accidents and falls from great heights[2-4]. Despite multiple managements ranging from non-operative to surgical available, it remains controversial as to which is the optimal treatment. Historically, a figure-8 sling was most frequently used for traditional conservative treatment[5-7]. However, as people's knowledge and beliefs evolve, more and more evidence demonstrates that surgical management results in a more reliable, earlier, and complication-free return to full function. In this article, we report a patient with a right bipolar segmental clavicle fracture treated by bipolar fixation.

CASE PRESENTATION

Chief complaints

A 56-year-old security guard presented to our hospital with right shoulder pain after a 1-d history of fall from an electric bicycle.

History of present illness

The patient fell onto his right shoulder 1 d ago and felt pain and swelling in his right shoulder without coma, dyspnea, or numbness in his upper extremities. He did not immediately go to the hospital. Subsequently, the patient complained of increased edema, pain in the right shoulder, and limited range of motion at the right sternoclavicular joint. He visited our hospital's emergency room and was sent for imaging.

History of past illness

Previously, the patient was in good health. He denied having a history of diabetes, hypertension, coronary heart disease, other significant surgical injuries, and food and drug allergies.

Personal and family history

The patient had no relevant personal or family history.

Physical examination

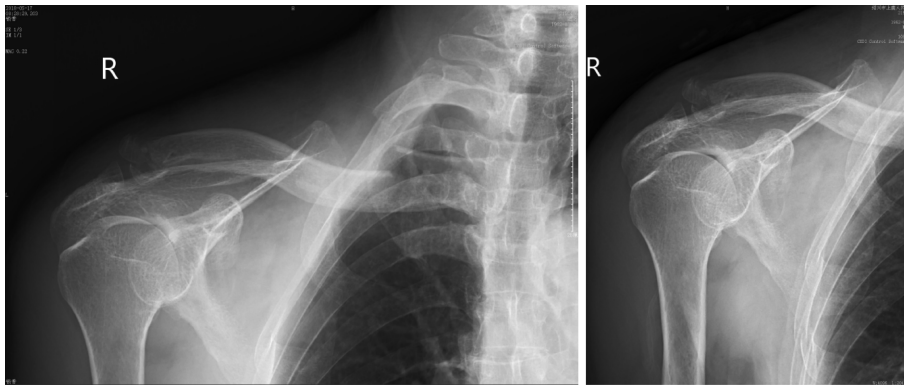
The patient's right shoulder and sternoclavicular joint were swollen and exhibited local congestion. It was impossible for him to raise the right upper limb above the shoulder. There was no limb numbness. The injured limb's muscle strength and radial artery pulse were normal.

Laboratory examinations

Blood analysis revealed the following: White blood cell count, $5.5 \times 10^9/L$; red blood cell count, $3.11 \times 10^{12}/L$; haemoglobin, 113 g/L; and platelet count, $116 \times 10^9/L$. Biochemical analysis revealed the following: Total protein, 56.9 g/L; albumin, 34.8 g/L; creatinine, 100.4 $\mu\text{mol}/L$; urea nitrogen, 3.12 mol/L; prothrombin time, 12.0 s; prothrombin activity percentage, 100%; activated partial prothrombin time, 41.3 s; and D-dimer, 2.41 mg/L. The findings of routine urine and stool examinations were normal, as were the findings of electrocardiography.

Imaging examinations

On standard radiograph of the patient, both the proximal and distal ends of the clavicle fractures were detached (Figure 1). In addition, 3D computed tomography (CT) revealed the degree of the displa-



DOI: 10.12998/wjcc.v10.i29.10529 Copyright ©The Author(s) 2022.

Figure 1 X-ray showed the bipolar segmental clavicle fracture.

cement and classification of the fracture (Figure 2). The distal end of the clavicle was displaced upward and the proximal end anteriorly. It showed the fracture instability and the risk of non-union or malunion.

FINAL DIAGNOSIS

Bipolar segmental clavicle fracture.

TREATMENT

We decided to treat the patient by open reduction and internal fixation after admission. The patient consented to the surgery 4 d after the injury, which was performed with his permission. The patient underwent surgery under general anesthesia with a 30-degree angle of support. After a skin incision was made over the proximal and distal ends of the clavicle, the fractures were observable upon direct examination. At the proximal end of the free bone fragment, one cortical screw and a Kirschner wire were used to fix it, followed by a fragment-contoured T plate. The distal aspect of the clavicle was elevated. The rupture of the acromioclavicular ligament caused the subluxation of the acromioclavicular joint. To stabilize the fracture and dislocation, an acromioclavicular hook plate was placed.

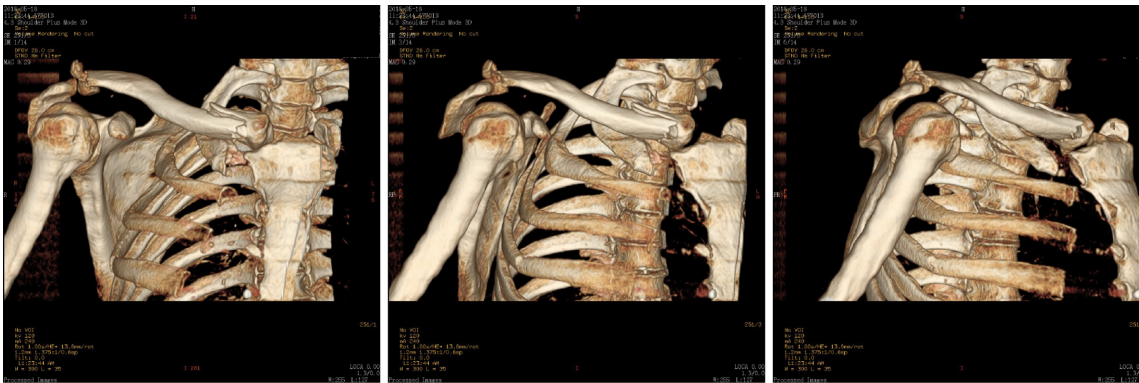
OUTCOME AND FOLLOW-UP

On postoperative radiographic evaluations, excellent fracture line and dislocation reduction were observed (Figure 3). The patient performed horizontal right shoulder range of motion exercises under supervision. Six weeks after surgery, the active motion of the right shoulder joint was gradually permitted as tolerated. After 10 wk of recovery, the patient returned to work. At the 4-mo follow-up, the patient could flex his right shoulder forward up to 150 degrees. X-rays and 3D CT revealed that bipolar segmental clavicle fractures had healed completely (Figure 4). At the 1-year follow-up, the implant was removed due to implant-related discomfort.

DISCUSSION

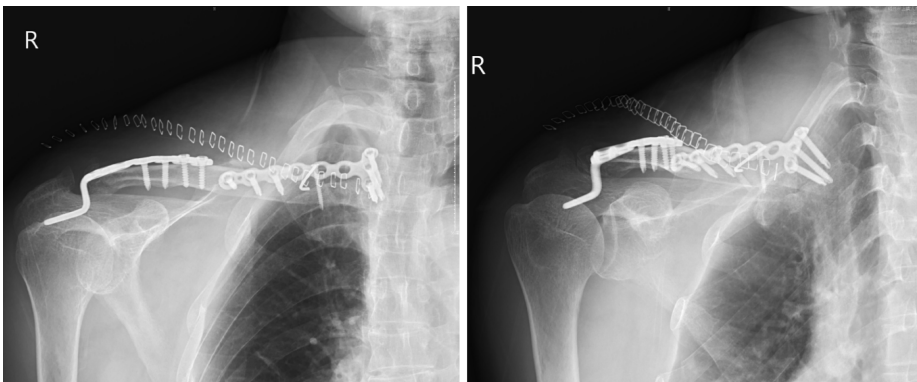
Clavicle fractures represent 2% to 5% of all fractures and 5% to 10% of fractures in young adults[8]. However, bipolar clavicle fractures are uncommonly reported in the medical literature. Due to their rarity, there is no consensus regarding treating bipolar clavicle fractures. It suggests using age and activity demands to determine the treatment approach. Elderly patients should be treated with caution. Young and active individuals are often operated on. However, there is a counterargument. Some articles report that non-surgical treatment results in gross clavicle deformity and poor function. Even if a low-energy trauma causes shoulder instability, the condition may persist in the patients. Therefore, surgical intervention was chosen for our patient.

Additionally, the selection of the internal fixation material is debatable. A locking plate is frequently used to treat fractures of the clavicle. In their report, Takahisa Ogawa *et al* decided to internally fixate



DOI: 10.12998/wjcc.v10.i29.10529 Copyright ©The Author(s) 2022.

Figure 2 3D computed tomography showed the displacement of clavicle fracture from different angles.



DOI: 10.12998/wjcc.v10.i29.10529 Copyright ©The Author(s) 2022.

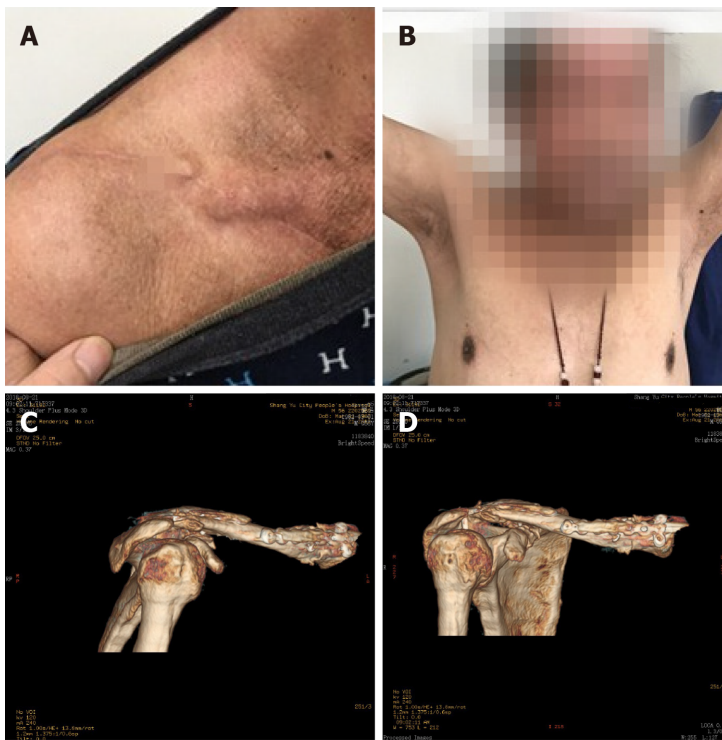
Figure 3 The fracture line and dislocation were dismissed postoperatively.

only the distal end of the bipolar segmental clavicle fracture, while the proximal end was treated conservatively[9]. After surgery, a month-long arm sling was used to prevent displacement of the proximal clavicle fracture. After 3 years, the patient experienced neither pain nor hypofunction. In their case of a left segmental bipolar clavicle fracture, Varelas *et al* opted for conservative treatment due to the patient's advanced age and low functional demand. CT revealed a displaced medial fracture with clavicle bone shortening. Therefore, they chose two anatomical compression plates with a lateral extension[10].

In our case, one 3.5 mm cortical screw and one Kirschner wire were utilized to immobilize the proximal fractured bone. Another 9-hole reconstruction locking plate was used to prevent rotational displacement from securing the proximal clavicle fracture. The fracture of the distal end was treated with a seven-hole locking hook plate. Wu *et al* concluded that hook plate fixation was statistically associated with better shoulder function and stability[11,12]. On the first postoperative day, the patient was instructed to activate the shoulder joint and gradually raise the right upper limb above the shoulder. Three months later, the clavicle fracture line had healed and disappeared.

CONCLUSION

We provide a rare case of bipolar clavicle fracture in the right clavicle. We hold the opinion that such patients would get better clinical and radiological outcomes by early and correct operation.



DOI: 10.12998/wjcc.v10.i29.10529 Copyright ©The Author(s) 2022.

Figure 4 Bipolar segmental clavicle fractures had healed completely. A and B: The skin incision healed and the functional motion of the right shoulder recovered 4 mo later; C and D: 3D computed tomography showed that the bone union of bipolar segmental clavicle fractures was complete at the 4-mo follow-up after the operation.

FOOTNOTES

Author contributions: Liang L, Chen XL, and Chen Y contributed to conceptualization; Liang L and Zhang NN contributed to data curation and investigation; Liang L conducted the project administration; Liang L and Chen XL wrote the original draft, and reviewed and edited the manuscript; all authors issued final approval for the version to be submitted.

Informed consent statement: Informed written consent was obtained from the patient for publication of this report and any accompanying images.

Conflict-of-interest statement: All authors declare that they have no conflict of interest to disclose.

CARE Checklist (2016) statement: All authors have read the CARE Checklist (2016), and the manuscript was prepared and revised according to the CARE Checklist (2016).

Open-Access: This article is an open-access article that was selected by an in-house editor and fully peer-reviewed by external reviewers. It is distributed in accordance with the Creative Commons Attribution NonCommercial (CC BY-NC 4.0) license, which permits others to distribute, remix, adapt, build upon this work non-commercially, and license their derivative works on different terms, provided the original work is properly cited and the use is non-commercial. See: <https://creativecommons.org/licenses/by-nc/4.0/>

Country/Territory of origin: China

ORCID number: Lin Liang 0000-0002-2654-8360; Xin-Lei Chen 0000-0001-9370-6405; Ye Chen 0000-0002-8251-8369; Nian-Nian Zhang 0000-0001-5201-6088.

S-Editor: Wang LL

L-Editor: Wang TQ

P-Editor: Wang LL

REFERENCES

- 1 Nordqvist A, Petersson C. The incidence of fractures of the clavicle. *Clin Orthop Relat Res* 1994; **300**: 127-132 [DOI: 10.1097/00003122-199403000000127]

- 10.1097/00003086-199403000-00016]
- 2 **Eni-Olotu DO**, Hobbs NJ. Floating clavicle--simultaneous dislocation of both ends of the clavicle. *Injury* 1997; **28**: 319-320 [PMID: 9282191 DOI: 10.1016/s0020-1383(97)00009-0]
 - 3 **Heywood R**, Clasper J. An unusual case of segmental clavicle fracture. *J R Army Med Corps* 2005; **151**: 93-94 [PMID: 16097113 DOI: 10.1136/jramc-151-02-06]
 - 4 **Madhuri V**, Gangadharan S, Gibikote S. Bipolar physeal injuries of the clavicle in a child. *Indian J Orthop* 2012; **46**: 593-595 [PMID: 23162157 DOI: 10.4103/0019-5413.101049]
 - 5 **Post M**. Current concepts in the treatment of fractures of the clavicle. *Clin Orthop Relat Res* 1989; **245**: 89-101 [DOI: 10.1097/00003086-198908000-00015]
 - 6 **Robinson CM**, Court-Brown CM, McQueen MM, Wakefield AE. Estimating the risk of nonunion following nonoperative treatment of a clavicular fracture. *J Bone Joint Surg Am* 2004; **86**: 1359-1365 [PMID: 15252081 DOI: 10.2106/00004623-200407000-00002]
 - 7 **Grassi FA**, Tajana MS, D'Angelo F. Management of midclavicular fractures: comparison between nonoperative treatment and open intramedullary fixation in 80 patients. *J Trauma* 2001; **50**: 1096-1100 [PMID: 11426125 DOI: 10.1097/00005373-200106000-00019]
 - 8 **Postacchini F**, Gumina S, De Santis P, Albo F. Epidemiology of clavicle fractures. *J Shoulder Elbow Surg* 2002; **11**: 452-456 [DOI: 10.1067/mse.2002.126613]
 - 9 **Ogawa T**, Sasaki T, Masayuki-Kawashima MK, Okawa A, Mahito-Kawashima MK. Internal Fixation of Only the Distal End in a Bipolar Segmental Clavicle Fracture: A Case Report. *Malays Orthop J* 2017; **11**: 47-49 [PMID: 29326767 DOI: 10.5704/MOJ.1711.003]
 - 10 **Varelas N**, Joosse P, Zermatten P. Operative Treatment of an Atypical Segmental Bipolar Fracture of the Clavicle. *Arch Trauma Res* 2015; **4**: e29923 [PMID: 26848475 DOI: 10.5812/atr.29923]
 - 11 **Wu K**, Chang CH, Yang RS. Comparing hook plates and Kirschner tension band wiring for unstable lateral clavicle fractures. *Orthopedics* 2011; **34**: e718-e723 [PMID: 22049952 DOI: 10.3928/01477447-20110922-17]
 - 12 **Kiefer H**, Claes L, Burri C, Holzwarth J. The stabilizing effect of various implants on the torn acromioclavicular joint. A biomechanical study. *Arch Orthop Trauma Surg (1978)* 1986; **106**: 42-46 [PMID: 3566494 DOI: 10.1007/BF00435651]



Published by **Baishideng Publishing Group Inc**
7041 Koll Center Parkway, Suite 160, Pleasanton, CA 94566, USA
Telephone: +1-925-3991568
E-mail: bpgoffice@wjgnet.com
Help Desk: <https://www.f6publishing.com/helpdesk>
<https://www.wjgnet.com>

