



Single-Stage Continent Reconstruction of Composite Pericommissural Defects Using a Combination of Pacman-Style Free Radial Forearm Flaps and Modified Elastic Musculomucosal Flaps

T.M. Balakrishnan¹  M. Aruna¹ Prethee Martina Christabel¹ J. Jaganmohan¹

¹Department of Plastic and Faciomaxillary Surgery, Madras Medical College, Chennai, Tamil Nadu, India

Indian J Plast Surg 2022;55:234–243.

Address for correspondence T.M. Balakrishnan, MBBS, MS, FRCS, DNB, MCH, DNB, old no 15, new no10, Thiruvalluvar Street, Rangarajapuram, Kodambakkam, Chennai, Tamil Nadu, 600024, India (e-mail: thalaiviri.b@gmail.com).

Abstract

Introduction Based on the cross-innervation of buccal and marginal mandibular branches of the facial nerve, oblique elastic musculomucosal flaps (OEMMFs) can be harvested and used for continent neo-commissure and modiolus reconstructions. The composite pericommissural defects can then be reconstructed with double cutaneous paddles in Pacman-style free radial forearm flap (PFRFF). This novel single-stage continent reconstruction of composite post-excisional commissure and pericommissural (CPECPC) defects is evaluated in this study.

Patients and Methods This retrospective cohort study was conducted from April 2016 to March 2019. Forty-two patients underwent this type of reconstruction using a combination of PFRFF and OEMMF for the CPECPC defects. They were followed for an average period of 11.5 months. At the end of the follow-up period, they were assessed using the objective institutional scoring system by two independent observers and final score was computed for each patient.

Results The average score obtained at the end of the follow-up period was 11.5 ($p = 0.035$) using the institutional assessment scoring system, which evaluated both the overall aesthesis and function of the neo-commissure and modiolus.

Conclusions The combination of OEMMF and PFRFF for the single-stage reconstruction of CPECPC defects is a useful addendum for re-establishing the aesthesis and continence at the reconstructed site.

Keywords

- ▶ Pacman-style free radial forearm flaps
- ▶ oblique elastic musculomucosal flaps
- ▶ oral commissure reconstruction
- ▶ oral continence

Introduction

Reconstruction of the composite post-excisional commissural and pericommissural (CPECPC) defects is the most difficult task from a functional and aesthetic point of view.^{1–4} Concertedly 12 pairs of retractors with various vectors antagonize one dominant oral sphincter, integrating the forces at a pair of

fibrous modiolii, to form the mobile skeleton of lips and commissure.^{5–8} In the continence of the oral cavity, the lips play a pivotal role.^{5–8} Even minimal mismatch and discrepancy will evoke a dissent response from the casual onlooker in this region. Function and aesthesis are integrated more closely in the commissure than any other region of the face.^{6,9} The

published online
October 9, 2022

DOI <https://doi.org/10.1055/s-0042-1744454>.
ISSN 0970-0358.

© 2022. Association of Plastic Surgeons of India. All rights reserved. This is an open access article published by Thieme under the terms of the Creative Commons Attribution-NonDerivative-NonCommercial-License, permitting copying and reproduction so long as the original work is given appropriate credit. Contents may not be used for commercial purposes, or adapted, remixed, transformed or built upon. (<https://creativecommons.org/licenses/by-nc-nd/4.0/>)
Thieme Medical and Scientific Publishers Pvt. Ltd., A-12, 2nd Floor, Sector 2, Noida-201301 UP, India

CPECPC defects for the oral commissure cancer when reconstructed with the locoregional flaps alone either end up in microstomia, rounded commissure, and drooling (which needs secondary revision) or these flaps may be inadequate so that they recruit adjacent “non-like” regional tissues resulting in more scars with poor functional and aesthetic outcomes.^{10–12} Multiple pedicled and microvascular distant flaps were used in a staged manner to reconstruct these defects. But none of them provided early continence and anatomical-looking commissure.^{10–15} So, for the best functional outcomes in the CPECPC reconstruction, the locoregional flaps are imperative, but alone, they are inadequate for moderate to large pericommissural reconstructions.⁶ In this study, as a balanced act, in a single stage, we have used the oblique elastic musculomucosal flap (OEMMF) (a locoregional flap) with a fascial static sling for the continent reconstruction of the commissure and pericommissure and the rest of the composite post-excisional defect was reconstructed with the Pacman-style (name was based on the shape) free radial forearm flap (PFRFF).¹⁶ Goldstein was the first one to develop the axial pattern vermilion musculomucosal flaps based on the elasticity of the lips and contralateral labial vessels for the reconstruction of lip defects.^{17–19} But, Robotti et al²⁰ used these vermilion musculomucosal flaps primarily and secondarily in the commissuroplasty. For the moderate to large CPECPC defects, our anatomically construed, newly designed OEMMF was used for the reconstruction of anatomical, functional commissure with neo-fibro modiolus which was held in position by a static fascial sling. The rest of the primary CPECPC defect was reconstructed with patterned PFRFF. The design of OEMMF was based on the anatomical fact that orbicularis oris muscle receives the innervation from both the ipsilateral and contralateral (cross-over) buccal and marginal mandibular branches.²¹ Therefore, harvesting the OEMMF from the ipsilateral residual lips renders a vascularized, sensate, and motorized musculature with like tissues for a continent commissure and neo-modiolus reconstruction.

The objective of this article was to evaluate the efficacy and the outcomes of our single-stage reconstruction technique of CPECPC defects with a combination of OEMMF and PFRFF.

Patients and Methods

Our institutional ethical committee approved the conduction of this clinical study. Written informed consent was obtained from all patients regarding the use and display of clinical material, photographs, and videos for research and publication purposes.

This retrospective cohort study was conducted from April 2016 to March 2019. Forty-two patients underwent this type of reconstruction using a combination of PFRFF and OEMMF for the CPECPC defects. Of the forty-two patients, 36 were male and 6 were female. Ages of the patients were in the range of 36 to 51 years with an average age of 40.5 years.

Patients with stage III and IVA oral commissure carcinoma who had undergone wide local excision with neck dissection resulting in the moderate to large CPECPC defects and subsequently undergone reconstruction with OEMMF and PFRFF were included in the study. The essential criteria for performing the OEMMFs are that at least 1 cm of the residual ipsilateral lip should be available.

Those with mandibular involvement with carcinoma of the oral commissures were excluded. Those with oral submucosal fibrosis were excluded.

Pre-operative inter-commissural distance was measured. In those cases with blunting or distortion and destruction of the commissure due to carcinoma, the ideal symmetrical commissural point was marked and the inter-commissural distance was measured at repose. The summaries of the patient's details are shown in ►Table 1.

Surgical Technique

After the wide local excision and neck node management were done by the oncologist, reconstruction was performed after the assessment of the defect. The OEMMFs were harvested by placing two incisions—one on the white roll falling short of the ipsilateral philtral column (but in the lower lip it could cross the center) and another on the labial aspect of gingivobuccal sulcus falling short of the apex by 2 mm (►Fig. 1). By an oblique incision through marginalis (marginal artery included in the flap) and proprius orbicularis oris muscle, the OEMMFs were constructed (►Fig. 1). The OEMMFs were nothing but

Table 1 Patient's summary

S. no	Age	Sex	Dimensions (cm ²)			Complications	Difference in inter-commissural distance pre- and post-operation (mm)	Adjuvant therapy	Follow-up (months)	Score
			OEMMF	Cutaneous paddle	Mucosal paddle					
1	45	F	1.5	26.5	23.5	Nil	5	Yes	10.5	12
2	43	M	1.7	27.5	26.5	Nil	2	Yes	9.5	12
3	38	M	1.4	25.5	23.5	Nil	7	No	11.5	11
4	50	M	1.3	26.8	24.2	Nil	6	Yes	9.8	11
5	48	F	1.2	25.5	23.5	Nil	0	Yes	10.2	12

(Continued)

Table 1 (Continued)

S. no	Age	Sex	Dimensions (cm ²)			Complications	Difference in inter-commissural distance pre- and post-operation (mm)	Adjuvant therapy	Follow-up (months)	Score
			OEMMF	Cutaneous paddle	Mucosal paddle					
6	42	M	1.1	26.5	24.5	Nil	3.5	Yes	9.2	12
7	36	M	1.4	29.5	27.5	Nil	6.5	No	10.8	11
8	46	M	1.1	28.5	26.5	Epidermolysis	8	Yes	9	11
9	51	M	1.2	27.8	26.4	Nil	4.5	No	9.4	12
10	44	M	1.5	28.4	26.6	Nil	2	Yes	10.5	12
11	42	M	1.1	26.6	24.2	Nil	2.8	Yes	11.3	12
12	36	F	1.2	27.5	24.4	Nil	8	No	10.2	10
13	46	M	1.3	26.5	23.5	Nil	6	Yes	9.4	11
14	44	M	1.1	24.4	22.5	Nil	7	No	9.2	11
15	36	F	1.4	29.5	27.5	Nil	6.5	No	10.8	12
16	46	M	1.1	28.5	26.5	Arterial thrombosis	8	Yes	9	11
17	51	M	1.2	27.8	26.4	Nil	4.5	No	9.4	12
18	44	M	1.5	28.4	26.6	Nil	2	Yes	10.5	12
19	42	M	1.1	26.6	24.2	Nil	2.8	Yes	11.3	12
20	36	F	1.2	27.5	24.4	Nil	8	No	10.2	10
21	46	M	1.3	26.5	23.5	Nil	6	Yes	9.4	12
22	44	M	1.1	24.4	22.5	Nil	7	No	9.2	11
23	45	F	1.5	26.5	23.5	Nil	5	Yes	10.5	12
24	43	M	1.7	27.5	26.5	Nil	4	Yes	9.5	12
25	38	M	1.4	25.5	23.5	Nil	7	No	11.5	10
26	50	M	1.3	26.8	24.2	Venous thrombosis infection	6	Yes	9.8	11
27	48	F	1.2	25.5	23.5	Nil	0	Yes	10.2	12
28	42	M	1.1	26.5	24.5	Nil	3.5	Yes	9.2	12
29	51	M	1.2	27.8	26.4	Nil	2.8	No	9.4	12
30	44	M	1.5	28.4	26.6	Nil	8	Yes	10.5	11
31	42	M	1.1	26.6	24.2	Arterial thrombosis	6	Yes	11.3	12
32	36	F	1.2	27.5	24.4	Nil	7	No	10.2	11
33	36	M	1.3	26.5	23.5	Nil	5	Yes	9.4	12
34	44	M	1.1	24.4	22.5	Nil	2.8	No	9.2	12
35	45	F	1.5	26.6	24.5	Nil	4	Yes	10.5	12
36	43	M	1.7	27.5	26.5	Nil	7	Yes	9.5	11
37	38	M	1.4	25.5	23.5	Nil	6	No	11.5	12
38	50	M	1.3	26.8	24.2	Venous thrombosis	0	Yes	9.8	12
39	45	F	1.6	26.6	24.5	Nil	3.5	Yes	10.5	12
40	43	M	1.7	27.5	26.5	Nil	4	Yes	9.5	12
41	45	M	1.5	26.5	23.5	Nil	7	Yes	10.5	10
42	43	M	1.7	27.5	26.5	Nil	3	Yes	9.5	12

Abbreviations: M; male, F; female, OEMMF, oblique elastic musculomucosal flap. ^aDimension of unstretched OEMMF.

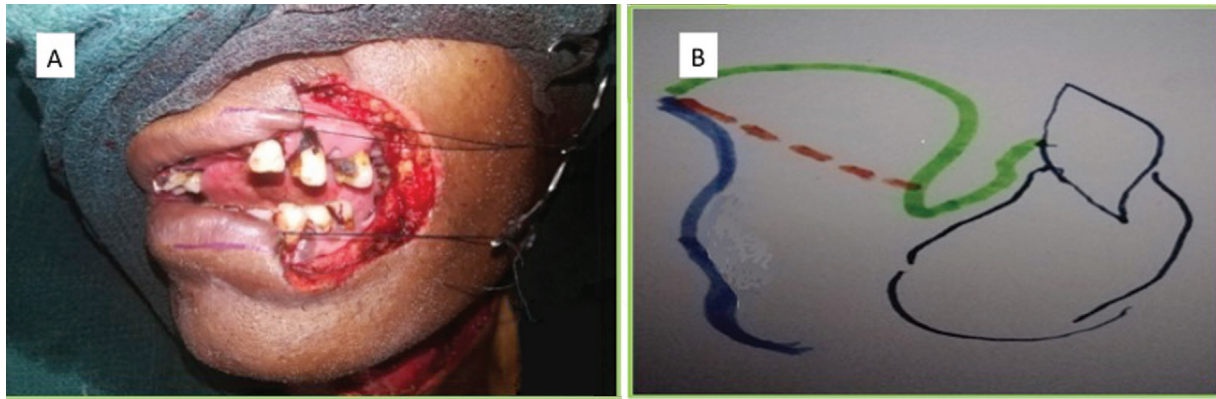


Fig. 1 (A) Marking for the incision on the white roll in the upper and lower lips. (B) Schematic diagram showing oblique incision through the lower lip ending up few millimeters above the lower gingivobuccal sulcus.

white roll orbicularis oris mucomuscular flaps. Utilizing the innate stretchability of the OEMMF, they were pulled toward the marked area of neo-commissure. The anatomically looking neo-commissure was reconstructed using white roll vermilion orbicularis oris components of the OEMMFs (►Fig. 2). The neo-modiolus was constructed by suturing the static iliotibial tract fascial sling with both upper and lower lip marginalis components of the OEMMFs (►Fig. 3). The other end of fascial sling was sutured to the zygomatic arch with exaggerated tension placing the neo-commissure with an average of 5 mm overcorrection (►Fig. 3). The proprius and peripheralis residuum of both OEMMFs were sutured laterally to the neo-modiolus (►Fig. 3). Latter reduced the size of the lining defect (►Figs. 2 and 3). With patterns obtained from the defect, the two PFRFF cutaneous islands were marked on the non-dominant forearm (►Fig. 4). The distal Pacman island, which was meant for the lining, was smaller when compared with the proximal Pacman cutaneous island designed for the cover. The jaws of the Pacman were facing each other, and the fascial sling was enclosed between the two paddles of PFRFF (►Figs. 3 and 4). The Pacman cutaneous paddles were in continuity with the narrowed adipofascial element and in few cases also islanded based on the independent perforator. This design allowed the freedom to orient the two paddles independently without being compressed by the iliotibial tract fascial sling. The proximally based PFRFF was harvested and was used for the inset for the composite peri-commissural defect. Then, microvascular anastomosis was performed with the prepared neck vessels. The neck wound was closed with the Segmuller drain.

Post-Operative Follow-up

The function and the aesthetics of the neo-commissure were assessed at the end of 6, 9, and 12 months by two independent observers using the institutional scoring system (►Table 2). The functional outcome was assessed by the lip competence by looking for the ability to retain food and saliva, ability to chew, and smile. The aesthetic outcome was assessed for the re-establishment of anatomically looking neo-commissure. Finally, the computed score for each patient was obtained (►Table 1).

Illustration of Case 2

Forty-three-year old male, a known tobacco chewer, presented with stage IVA (T4aN2aM0) squamous cell carcinoma of the left commissure (►Fig. 4). After wide local excision and modified radical neck dissection, he was reconstructed with OEMMF and PFRFF. Flaps settled well (►Fig. 5). He had post-operative adjuvant radiotherapy that was well tolerated. At the end of his follow-up period, he had anatomical-looking commissure that was symmetrical at rest. He had the oral continence for solids and fluids right from the sixth post-operative week (►Video 1). The inter-commissural distance at the end of the follow-up was falling short only by 2 mm (►Fig. 5).

Video 1

The continence of the oral cavity at 6 months post-operative for case 2. Online content including video sequences viewable at: <https://www.thieme-connect.com/products/ejournals/html/10.1055/s-0042-1744454>.

Illustration of Case 26

Fifty-year-old male, a known smoker, presented with carcinoma of the right commissure stage IVA (T4aN2bM0). (►Fig. 6A) He had undergone wide local excision with modified radical neck dissection. Similar reconstruction was done for the commissure and pericommissure defects (►Fig. 6B–D). On the second post-operative day, the patient developed venous thrombosis and the flap was salvaged by vein graft. In the early post-operative period, the patient developed a small loculation in relation to the neo-commissure that was let out and treated with antibiogram-directed antibiotic therapy. His wound settled well including the donor area (►Fig. 6E–H). He subsequently had post-operative adjuvant radiotherapy. He had a good continent oral cavity (►Video 2) and anatomical oral commissure despite the inter-commissural distance being reduced by 6 mm (►Fig. 6D–F).

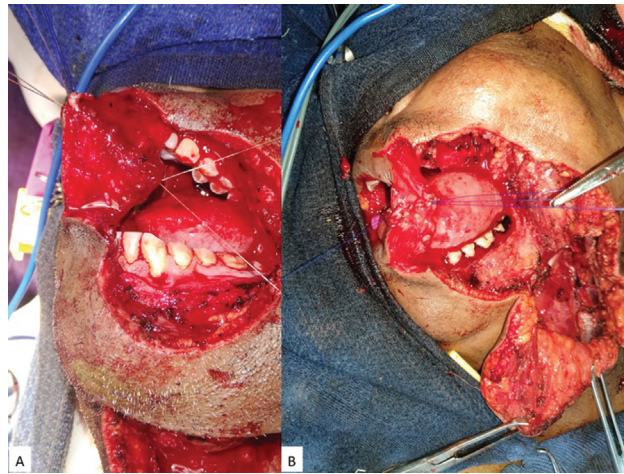


Fig. 2 (A) Neo-commissure reconstruction and anterior part of lining defect using the stretched OEMMFs lateral to neo-commissure. (B) Positioning of neo-commissure.

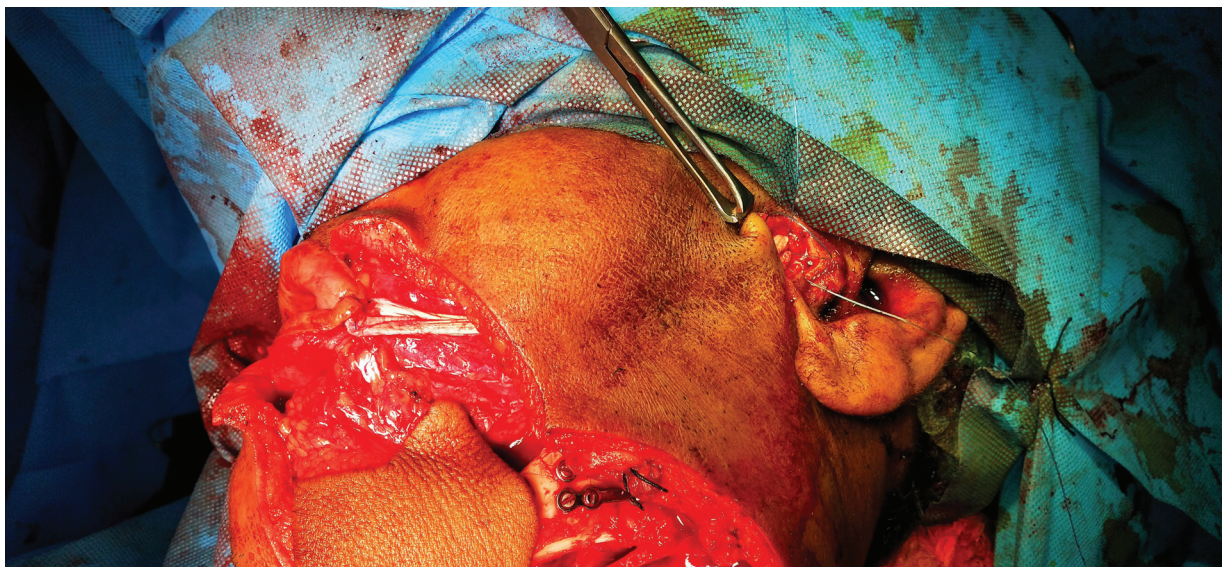


Fig. 3 Neo-modiolus reconstruction using the iliotibial tract fascial sling attached laterally to the neo-commissure tunneled toward zygomatic arch in the vector of zygomaticus and fixed to it at appropriate tension. This is done after inset of lining Pacman cutaneous paddle.

Video 2

The oral continence at 6 months post-operative for case 26. Online content including video sequences viewable at: <https://www.thieme-connect.com/products/ejournals/html/10.1055/s-0042-1744454>.

The technique described is illustrated in ►Fig. 7.

Results

Patients were followed up for an average period of 10.05 months. The average age in this study was 40.5 years. The CPECPC defects in average included 20% of the lateral upper lip and up to 35% of the lateral lower lip defects. Average

dimension of OEMMF used was 1.3 cm. The average external cutaneous paddle was 38.8 cm. Average mucosal paddle was 24.8 cm (►Table 1). The average difference in the pre- and post-operative inter-commissural distance was 4.9 mm. The initial allowance of overcorrection though brought the neo-commissure to the near orthotopic posture and position in the immediate post-operative period, the wound-healing forces bring about some changes at the end of the follow-up as noted in the late post-operative period inter-commissural distance differences (►Table 1). In this series, our overall flap success rate was 100%. Four cases of free flap needed re-exploration and were successfully salvaged (with the re-exploration rate of 9.5%). No flap failure was observed in our series. There was epidermolysis, and superficial infection uneventfully healed (with the overall complication rate of 14.2%) (►Table 1). The average score obtained at the end of the follow-up period was 11.5 ($p=0.035$) using the institutional assessment scoring system (►Table 2), which

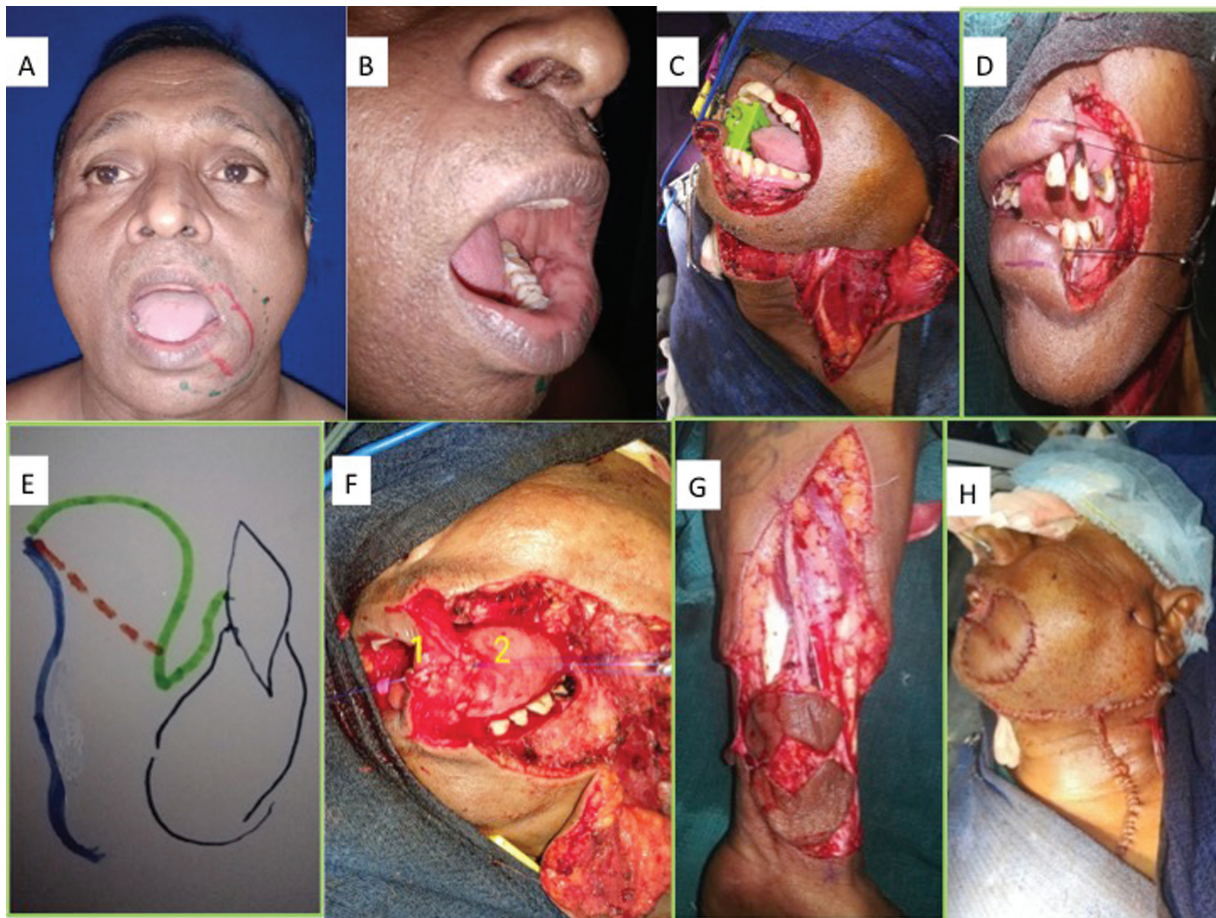


Fig. 4 (A, B) Illustrating case 2, left commissure cancer stage IVA. (C) Wide local excision with modified radical neck dissection. (D, E) Marking and method of harvesting of OEMMFs, (F) mark1. Neo-commissure mark 2. Orbicularis oris mucosal component of OEMMFs used for the reconstruction of anterior peri-commissural lining defects. (G) Two Pacman cutaneous paddles with jaws of Pacman facing each other harvested on left forearm radial vessels. (H) Immediate post-operative pictures.

evaluated both the overall aesthesia and function of the neo-commissure and modiolus. Ninety-five percent of cases (40 out of 42 patients) started regaining continence of the oral cavity as early as third post-operative week. All the cases had regained complete oral continence with re-establishment of all functions of the lip at the 6-month post-operative period (► **Video 1** and ► **Video 2**). None of the cases developed any locoregional recurrences. All the patients were satisfied with the aesthesia and function of the oral cavity.

Discussion

Surgical treatment of oral cancers is a well-established modality noted for its excellent locoregional control of the disease.²¹ Loss of commissure—an important aesthetic and function integrated region of the lower third face when not adequately reconstructed results in significant aesthetic deformity with dysfunctions of speech, swallowing, chewing, and smile. To this date, anatomical commissure with continence and good animation is still elusive in the reconstruction of moderate to large CPECPC defects.^{15,21} The locoregional flaps can easily obtain animated commissure, but they lack aesthesia envisaging secondary corrections. Furthermore, in the moderate to large pericommissure defects reconstruction, they recruit non-like tissues from

the cheek region resulting in more scars and distortion of facial features. The isolated distant flap reconstructions in multiple stages fail to bring good function and aesthesia integration to these sites. So, here in our study, the moderate to large CPECPC defects are reconstructed with a combination of functional local flap—the OEMMF derived from the adjunct portions of the upper and lower lips and the rest of the defect with PFRFF that is a balanced act of reaping the benefits of both local and distant flaps. It has the following advantages. (1) The local OEMMF containing part of three sphincters of the orbicularis oris muscle (the marginalis, intermedius, and a good portion of peripheralis) were sutured in two layers reconstituting effectively the animated neo-commissure, fibrous modiolus, and anterior lining pericommissure region. This reconstituted region is held statically in position by the iliotibial tract fascial sling suspended from the zygomatic arch in the vector of the zygomaticus muscle providing the stability during animation. This technique hinges on the anatomy of the orbicularis oris muscle receiving cross-innervations from the contralateral buccal and marginal mandibular branches of the facial nerve.²¹ The OEMMFs with their retained innervations and vascularity contributes to the continence of the oral cavity as early as 3 weeks in our study. Further, it provides adequate local tissue for function with no distortion. (2) The two Pacman-style cutaneous paddles of radial forearm

Table 2 Objective institutional scoring system

S. no.	Parameter	Score				
1	Ability to retain oral fluids and foods	0	1	2	3	4
2	Ability to chew food on ipsilateral side	0	1	2	3	4
3	Smile and aesthesis of neo-commissure	0	1	2	3	4
<i>Parameter</i>	<i>Score</i>					
Ability to retain oral fluids and foods	0	No continence				
	1	Some retention of only solid food				
	2	Good retention of only solid food				
	3	Good retention of solid food and fluids with occasional spill				
	4	Excellent retention of solids and fluids				
<i>Parameter</i>	<i>Score</i>					
Ability to chew food on ipsilateral side	0	Poor formation of vestibule. Chewing food not possible on ipsilateral side				
	1	Good vestibule with poor sulcus. Poor ability to chew and stasis of food				
	2	Good vestibule and sulcus with chewing moderately possible without retention				
	3	Anatomically normal vestibule and sulcus with chewing moderately possible with mild retention				
	4	Anatomically normal vestibule and sulcus with chewing moderately possible with no retention				
<i>Parameter</i>	<i>Score</i>					
Smile and aesthesis of neo-commissure	0	Asymmetrical smile. Commissure rounded and blunted				
	1	Poor commissure. Poor animation				
	2	Good commissure but with asymmetry and asymmetrical smile				
	3	Good commissure but with mild asymmetry and mild asymmetrical smile				
	4	Anatomically normal-looking commissure with good animation and symmetrical smile				

flap were used to reconstruct the rest of the composite defects in the pericommissure. The latter flap provides a good contour with thickness match and reinforces the high vascularity of this region enduring the post-operative radiotherapy in all our cases. The flaps showed less or no tendency for fibrosis. All the mucositis and pigmentary changes of RT had healed well due to the robust blood supply of the radial forearm flap. This also gives freedom from the distortion caused by the large locoregional flaps. This technique we have used is the first of its kind in CPECPC defects. In contrast to Goldstein and Robotti et al^{17-20,22} our OEMMF has the following features. (1) During harvest, the strut-like motor and sensory branches traversing horizontally in the muscle mass were preserved and dissected retrograde toward the contralateral side to allow the accordion-like expansion movements. In our series, we had seen a considerable number of patients having oral continence as early as 3 weeks post-operation that is explained by our technique of preserva-

tion of both sensory and motor branches by retrograde dissection. (2) In our experience, extending the harvest of OEMMF across the median tubercle of the upper lip had resulted in the distortion of philtral column. In our series, upper lip OEMMF that was obtained by release up to 0.5 cm from the ipsilateral height of Cupid's bow was sufficient enough to reconstruct the neo-commissure. In our series, the full thickness lip defects were 20 to 35%. This may be considered a limiting factor for this type of reconstruction. Hence, the aesthesis of the philtral column and median tubercle is maintained in our series. (3) In quiet contrast to Robotti et al our oblique incision included a considerable portion of orbicularis oris peripheralis muscle mass that was sutured laterally to the neo-commissure to create a mucomuscular sling that also reduced the lining defect. (4) In our technique, the neo-commissure was created by suturing the leading tip of white roll vermilion to mimic an anatomical commissure, and thereby, there was a smooth transition of

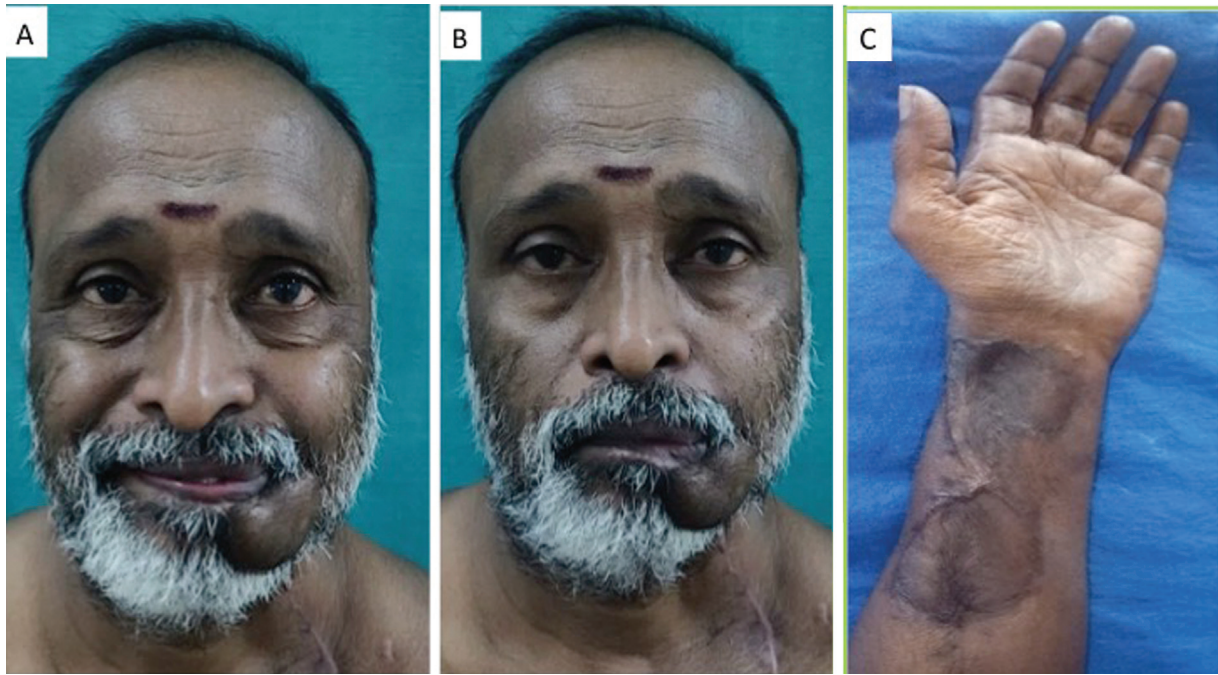

Fig. 5 (A) 6-month post-operative animation of the commissure at repose. (B) 6-month symmetry at repose. (C) Well-settled donor site at 6 months.

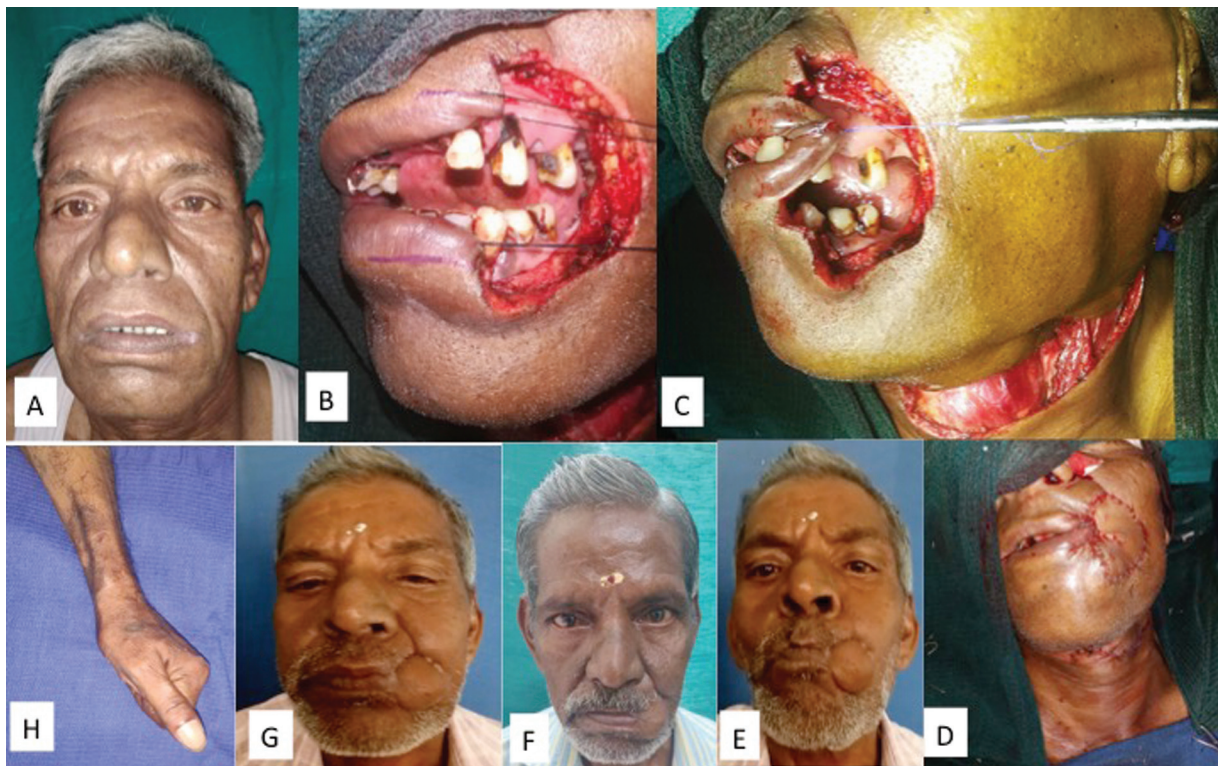

Fig. 6 (A) Left commissure carcinoma stage IVA. (B and C) OEMMF being raised after wide local excision and modified radical neck dissection. (D) Immediate post-operative picture showing anatomical commissure given inset into the concavity of cover Pacman cutaneous paddle. (E) Animation of commissure. (F) Symmetry of commissure at repose. (G) Continence of the oral cavity. (H) Donor site 6 months post-operation.

vermilion thickness toward the commissure mimicking the normal lip. This has increased the requirement of the cover, and later was addressed by our relatively large Pacman cover cutaneous paddle. (5) We used iliotibial tract fascial sling both for positioning and to support the animation of neo-commissure.

The unstretchable fascial sling apart from providing support to the neo-commissure also adds to the animation of residual buccinators in our series. (6) In contrast to Robotti et al²⁰ all our series was only primary reconstruction which explains the better results. The hyper-correction of 0.5 cm had

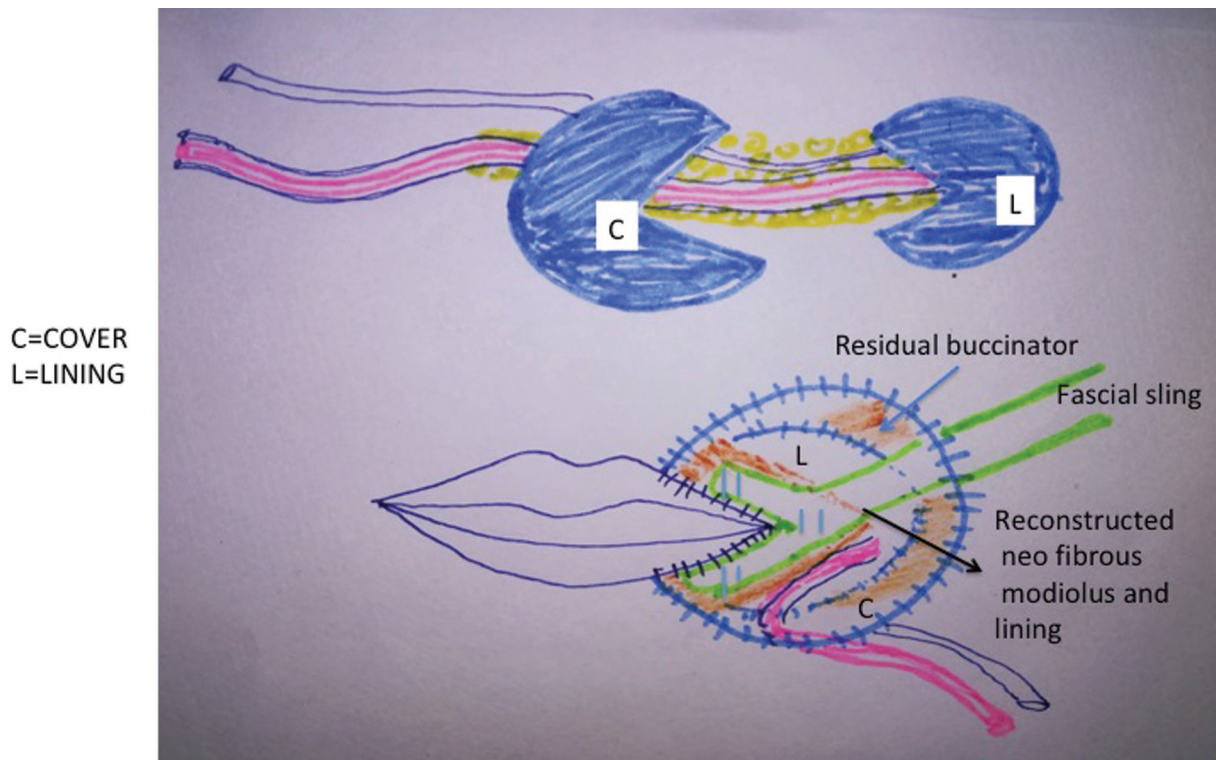


Fig. 7 Illustration of the technique of reconstruction.

invariably resulted in the near-normal position of the commissure after the healing period. This explains our average difference in the pre and post-operative inter-commissural distance which was 4.9 mm.

Yokoo et al²³ in their series of four cases used radial forearm flap or rectus abdominis myocutaneous flaps in conjunction with the vermilion white roll mucomuscular flap for the reconstruction of composite peri-commissural defects. But in all these cases, the vermilion flap was raised up to the contralateral side commissure with no mention of maintenance of sensory and motor branches. In addition, there were no attempts to use the vermilion flap for the lining of the composite peri-commissural defect. Our technique resulted in better aesthetics and functional results.

The strength of the study is establishing the useful combination of locoregional flap and distant flap for the continent reconstruction of the oral cavity with anatomical commissure and function. The relatively small size is the limitation of the study.

Conclusion

The combination of oblique lactic musculomucosal flap and Pacman-style free radial forearm flap for the reconstruction of composite commissure and pericommissure defects may be a useful addendum from the point of re-establishing the aesthetics and continence in the reconstructed lips.

Funding
None

Conflicts of Interest

None declared.

References

- 1 Baker SR. Current management of cancer of the lip. *Oncology (Williston Park)* 1990;4(09):107–120, discussion 122–124
- 2 Vartanian JG, Carvalho AL, de Araújo Filho MJ, Junior MH, Magrin J, Kowalski LP. Predictive factors and distribution of lymph node metastasis in lip cancer patients and their implications on the treatment of the neck. *Oral Oncol* 2004;40(02):223–227
- 3 Zitsch RP III, Lee BW, Smith RB. Cervical lymph node metastases and squamous cell carcinoma of the lip. *Head Neck* 1999;21(05):447–453
- 4 Moore S, Johnson N, Pierce A, Wilson D. The epidemiology of lip cancer: a review of global incidence and aetiology. *Oral Dis* 1999;5(03):185–195
- 5 McMinn RM. *Last's Anatomy Regional and Applied*. 9th ed. Edinburgh: Churchill Livingstone; 1994:446–448
- 6 Neligan PC. *Plastic surgery: craniofacial, head and neck surgery*. In: Rodriguez ED, Neligan PC, Gottlieb L, eds. *Lip Reconstruction*. 4th ed., Vol. 3. London: Elsevier Inc.; 2018:306–307
- 7 Marinetti CJ. The lower muscular balance of the face used to lift labial commissures. *Plast Reconstr Surg* 1999;104(04):1153–1162, discussion 1163–1164
- 8 Pessa JE, Zadoo VP, Adrian EK Jr, Yuan CH, Aydelotte J, Garza JR. Variability of the midfacial muscles: analysis of 50 hemifacial cadaver dissections. *Plast Reconstr Surg* 1998;102(06):1888–1893
- 9 Coppit GL, Lin DT, Burkey BB. Current concepts in lip reconstruction. *Curr Opin Otolaryngol Head Neck Surg* 2004;12(04):281–287
- 10 McCarthy ED. *Plastic surgery*, Vol. 3. Philadelphia: Saunders WB; 1990
- 11 Neligan PC. Strategies in lip reconstruction. *Clin Plast Surg* 2009;36(03):477–485

- 12 Estlander JA. A method of reconstructing loss of substance in one lip from the other lip. *Arch Klin Chir.* 1872;14:622
- 13 Abbe R. A new plastic operation for the relief of deformity due to double harelip. *Plast Reconstr Surg* 1968;42(05):481–483
- 14 Karapandzic M. Reconstruction of lip defects by local arterial flaps. *Br J Plast Surg* 1974;27(01):93–97
- 15 Tutela JP, Davis J, Zeiderman M, Kelishadi SS, Wilhelmi B. Lower lip suspension with gore-tex suture: technique and literature review. *Eplasty* 2014;14:e37
- 16 Purnell CA, Vaca EE, Ellis MF. Conical modification of forearm free flaps for single-stage reconstruction after total orbital exenteration. *J Craniofac Surg* 2017;28(08):e767–e769
- 17 Goldstein MH. “Orbiting the orbicularis”—restoration of muscle-ring continuity with myocutaneous flaps. *Plast Reconstr Surg* 1983;72(03):294–301
- 18 Goldstein MH. A tissue-expanding vermilion myocutaneous flap for lip repair. *Plast Reconstr Surg* 1984;73(05):768–770
- 19 Goldstein MH. The elastic flap for lip repair. *Plast Reconstr Surg* 1990;85(03):446–452
- 20 Robotti E, Righi B, Carminati M, et al. Oral commissure reconstruction with orbicularis oris elastic musculomucosal flaps. *J Plast Reconstr Aesthet Surg* 2010;63(03):431–439
- 21 Neligan PC. Plastic surgery: craniofacial, head and neck surgery. In: Rodriguez ED, Neligan PC, Gottlieb L, eds. *Lip Reconstruction*. 4th ed., Vol. 3 London: Elsevier Inc.; 2018:363
- 22 Goldstein MH. The elastic flap: an expanding vermilion myocutaneous flap for lip repairs. *Facial Plast Surg* 1990;7(02):119–125
- 23 Yokoo S, Tahara S, Tsuji Y, et al. Functional and aesthetic reconstruction of full-thickness cheek, oral commissure and vermilion. *J Craniomaxillofac Surg* 2001;29(06):344–350