



Simulation of Reconstructive Microsurgery in Soft Embalmed Cadavers: A Teaching Module for Plastic Surgery Residents

Baswa Manikumari¹ Sasidhar Reddy Jaggavarapu¹ Kakumanu Subha¹ Tumma Kalpana¹
Roopesh Kumar Nambi Muni¹ Prajakta Kishve² P. Bheemesh²

¹Department of Plastic Surgery, ESIC Medical College, Hyderabad, Telangana, India

²Department of Anatomy, ESIC Medical College, Hyderabad, Telangana, India

Address for correspondence Sasidhar Reddy Jaggavarapu, DNB, Department of Plastic Surgery, ESIC Medical College, Hyderabad, Telangana 500038, India (e-mail: j.sasidharreddy@gmail.com).

Indian J Plast Surg 2022;55:262–267.

Abstract

Background Cadaveric dissection courses—comprising flap harvesting techniques, vessel dissections, flap transfers to the defect, and microvascular anastomosis—would help residents gain confidence and master these difficult major reconstructive microsurgery procedures. Formalin embalmed bodies lack natural softness and many other features of a live body. Many soft embalming techniques have evolved to mimic live tissue and Theil technique is the most popular one among them. We explored alternate soft embalming options and started using Genelyn.

Materials and Methods Over a span of 2 years (2019–2021), we have conducted three flap dissection workshops using soft-embalmed cadavers. Six soft-embalmed and two formalin-embalmed cadavers were used. Total number of participants was 80.

Results Feedback of experience from the third course participants in the form of grades (1–5) for different criteria was obtained and evaluated. Confidence in the dissection of the various flaps and microsurgery is noticeable in all the participants.

Conclusion Based on our experience, we propose that flap dissection and microsurgery training on soft-embalmed cadavers be included as a teaching module in the plastic surgery postgraduate curriculum.

Keywords

- ▶ reconstructive microsurgery
- ▶ soft embalming
- ▶ cadaver training
- ▶ Genelyn
- ▶ resident training in plastic surgery
- ▶ surgical simulation

Introduction

Flap dissection, microsurgery, and free tissue transfer are challenging procedures within plastic and reconstructive surgery, for which the learning curve is long, and students often face difficulties in mastering these techniques during the 3-year plastic surgery residency program. Cadaveric dissection courses—comprising flap-harvesting techniques, vessel dissections, flap transfers to the defect, and microvascular anastomosis—would help residents gain confidence and master these difficult major reconstructive microsurgery procedures, where

the learning curve is longer.^{1–3} Formalin embalmed bodies are traditionally used for training in cadaver dissection courses, but they lack natural softness and many other features of a live body. Many soft embalming techniques have evolved to mimic live tissue and Theil technique is the most popular one among them. Iyer et al have described “Modified Theil technique,” a more suitable technique for tropical countries.⁴ But some components used in preparing it are very difficult to procure and some are explosive in nature. We explored alternate soft embalming options and started using Genelyn (Span Surgical Co, Coimbatore, Tamil Nadu, India). Over a span of 2 years, we

published online
October 9, 2022

DOI <https://doi.org/10.1055/s-0042-1750375>.
ISSN 0970-0358.

© 2022. Association of Plastic Surgeons of India. All rights reserved. This is an open access article published by Thieme under the terms of the Creative Commons Attribution-NonDerivative-NonCommercial-License, permitting copying and reproduction so long as the original work is given appropriate credit. Contents may not be used for commercial purposes, or adapted, remixed, transformed or built upon. (<https://creativecommons.org/licenses/by-nc-nd/4.0/>)

Thieme Medical and Scientific Publishers Pvt. Ltd., A-12, 2nd Floor, Sector 2, Noida-201301 UP, India

have conducted three flap dissection courses using soft-embalmed cadavers at our institute for plastic surgery residents and young plastic surgeons (►Table 1; ►Fig. 1). Based on this experience, we propose that flap dissection training using soft-embalmed cadavers is included as a teaching module in the plastic surgery postgraduate curriculum.

Materials and Methods

We started cadaveric flap dissection courses in the year 2019. Soft embalming of the cadavers was done by our Anatomy Department using Genelyn, which is a proprietary mixture manufactured by an Australian company and marketed in India. In the first course, we used four cadavers, where two were embalmed with Genelyn, and two were regular formalin fixed. There were 40 participants. There was an initial demonstration of each flap by the senior faculty, followed by dissection by the participants. The various flaps that were dissected are those flaps that are commonly used in trauma and onco-reconstructions, both regional and free: radial artery forearm flap, anterolateral thigh flap, lateral arm flap (►Fig. 2A, B), fibula flap, gracilis flap, pectoralis major myocutaneous flap, deltopectoral flap, latissimus dorsi flap, posterior interosseous artery flap, (►Fig. 3A–C; ►Video 1) and various perforator flaps. All the participants and the senior faculty could notice the difference in tissue pliability, tissue planes dissection,

perforator visibility, and vessel pliability in Genelyn-embalmed bodies, which was life-like when compared with the formalin-fixed bodies. The second course was conducted 6 months after the first one, and was an exclusive 2-day course for 20 participants. It was modified to an extent; in place of a live demonstration, we played the videos of the flap dissections (►Video 2) to allot more time for hands-on training, which the participants were keener and more eager for. The participants could do more flaps individually and gave positive feedback regarding their experience with Genelyn-embalmed bodies as in the first course.

Video 1

Demonstration of posterior interosseous artery flap harvest by a senior faculty in a Genelyn embalmed body showing good tissue pliability, nice tissue planes, and perforator visibility. Online content including video sequences viewable at: <https://www.thieme-connect.com/products/ejournals/html/10.1055/s-0042-1750375>.

Video 2

Flap dissection. Online content including video sequences viewable at: <https://www.thieme-connect.com/products/ejournals/html/10.1055/s-0042-1750375>.

Table 1 Flap dissection courses details

Date	Flap dissection course	Number of cadavers	Number of people attended
September 2019	1	Soft embalmed—2 Formalin embalmed—2	40
January 2020	2	Soft embalmed—2	20
July 2021	3	Soft embalmed—2	20

In the third cadaveric flap dissection course, we limited the course content to the dissection of fewer flaps, but added further steps in addition to the flap dissection for simulation of defect recreation, that is, defect creation, vessel dissection at recipient site, and flap transfer along with the vessel anastomosis with the aid of magnifying loupes. Two soft-embalmed

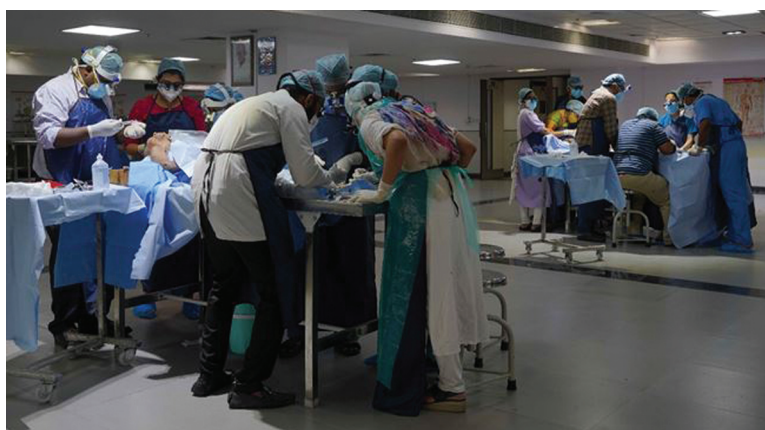

Fig. 1 Participants dissecting flaps on cadavers.

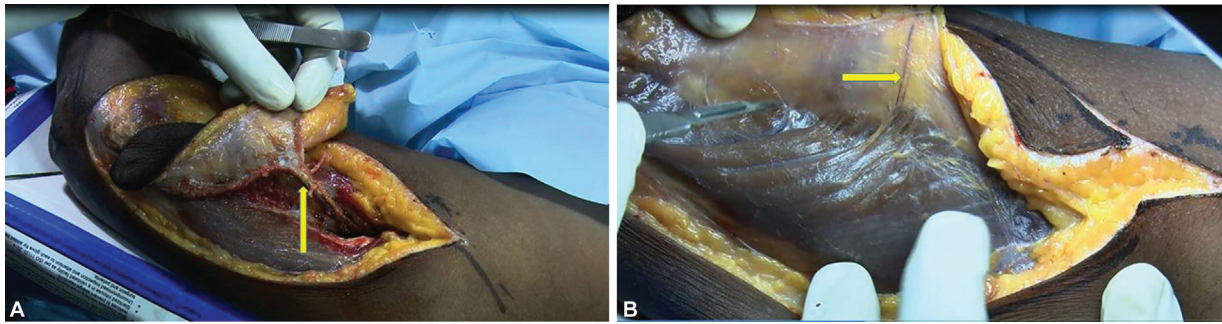


Fig. 2 (A) Lateral arm flap. Pedicle shown by yellow arrow. (B) Lateral arm flap with clearly visible perforator (yellow arrow) entering the flap.

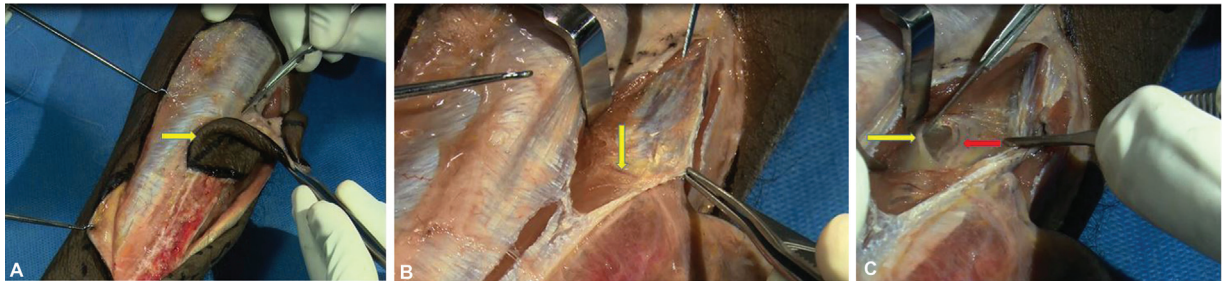


Fig. 3 (A) Posterior interosseous artery flap (yellow arrow) being dissected. (B) Clearly visible perforator (yellow arrow) in posterior interosseous artery flap. (C) Posterior interosseous artery, shown by red arrow, and posterior interosseous nerve, shown by yellow arrow.

cadavers were used, and 16 participants were given hands-on experience while four participated as observers.

The three most commonly used free flaps in head and neck reconstruction and trauma reconstruction (radial artery forearm flap, anterolateral thigh flap, and fibula osteocutaneous flap) (► **Figs. 4A, B** and **5A–C**) were taught in the third course. Additionally, we also taught pectoralis major myocutaneous flap and deltopectoral flap, the two most used regional flaps for head and neck reconstruction. The recipient sites that were chosen were defect in the oral cavity (buccal mucosa/tongue) and heel/sole defect. The recipient vessels were facial artery, external jugular vein, and internal jugular vein tributaries in the neck, and posterior and anterior tibial vessels in the leg. Magnifying loupes were used both for the dissection of the flaps and anastomosis of the vessels. The sutures used for anastomosis was 8.0 nylon. Patency of the anastomosis was tested by injecting diluted methylene blue (► **Video 3**).

Video 3

Testing patency of the anastomosis by injecting diluted methylene blue. Online content including video sequences viewable at: <https://www.thieme-connect.com/products/ejournals/html/10.1055/s-0042-1750375>.

Procedure of Embalming

The fresh cadavers (not frozen before embalming) obtained within 12 hours after death were utilized for soft embalming. The bodies were transferred to the embalming table and disinfected with topical disinfectant solution. A 2 to 3 cm incision was made in the carotid triangle, and the cannula is inserted into common carotid artery. The Genelyn kit contains three liters of fluid to which we have added five liters of distilled water. Thus, total eight liters of fluid was injected into the artery with the help of electric embalming machine. Once the embalming process is completed, the cadavers are placed in a cadaver bag, stored in a freezer at 2 to 4°C temperature. The bodies were thawed for 4 hours then used in training workshops. The bodies can be preserved for 2 to 4 weeks with this procedure without keeping them in immersion fluid. The cost of each kit was ~ INR 10,500 per body.

Results

We obtained feedback from all the 16 participants with hands-on experience in the third course through a questionnaire. They were asked to grade their experiences in the course from one to five (one = very bad, five = very good) based on different criteria. The results are shown in ► **Table 2**. The average sum of the grades given for color of the tissues in the cadaver as compared with live body is 3.6, for consistency of the tissues 3.3, for odorlessness 4.2, and for differentiation of different layers 4. The average

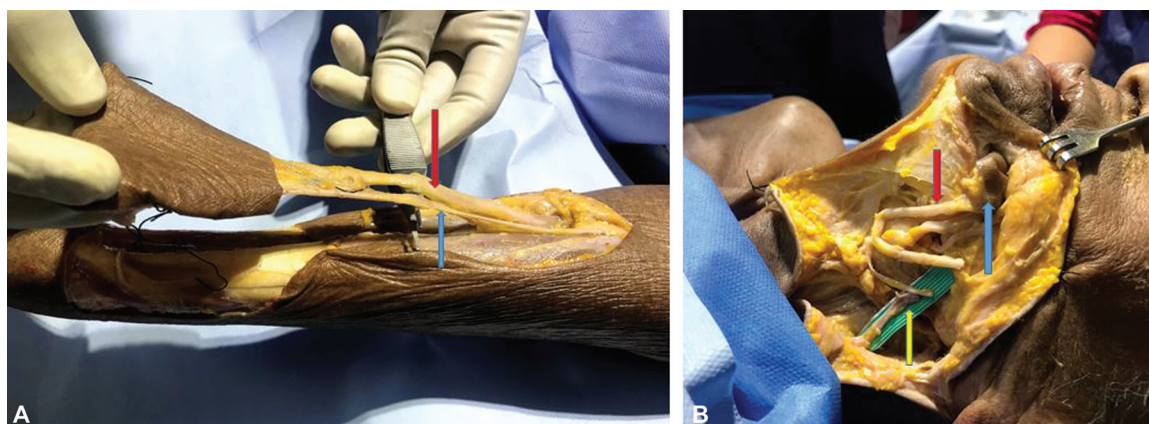


Fig. 4 (A) Radial artery forearm free flap (RAFF). Cephalic vein shown by blue arrow. Radial artery with vena comitantes shown by red arrow. (B) RAFF flap (blue arrow) transferred to the defect in the oral cavity. Flap pedicle shown by red arrow and dissected neck vessels shown by yellow arrow. Vessels aligned and prepared, ready for anastomosis.

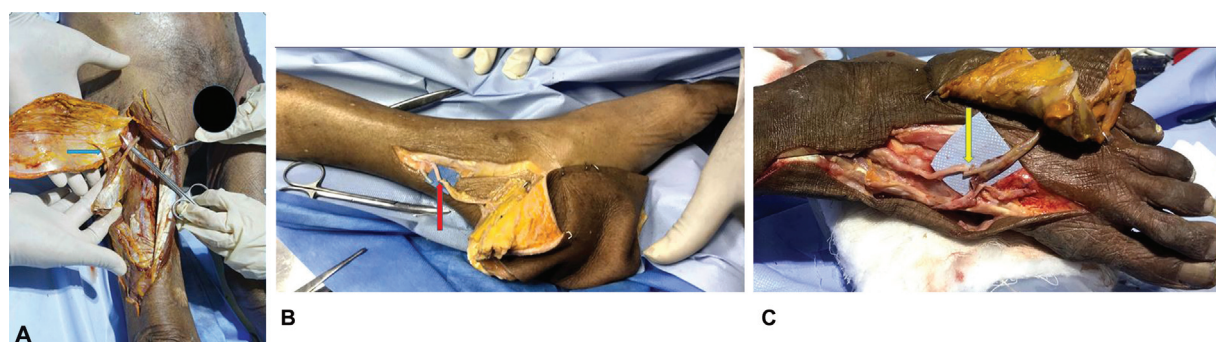


Fig. 5 (A) Anterolateral thigh flap (ALT). Perforator shown by blue arrow and descending branch of lateral circumflex femoral artery shown being lifted by scissors. (B) ALT flap transferred to the heel defect. Posterior tibial vessels dissected and aligned with flap vessels ready for anastomosis (red arrow). (C) ALT flap transferred to the sole defect. Anterior tibial vessels dissected and aligned with flap vessels ready for anastomosis (yellow arrow).

Table 2 Feedback from third course participants

S No.	Criteria	Grades 1–5
1	Color is as in living tissue	3.6
2	Consistency (soft) is similar to as in living tissue	3.3
3	Odorless	4.2
4	Layers can be differentiated well	4
5	Approach to the area is good	4.2
6	Mimics live tissue	3.5
7	Suitable for the procedure done	4
8	Improvement in confidence to replicate the same in a real-time surgery	80%

grade for ease of approach to the area (e.g., for vessel dissection in free fibula) is 4.2, for overall suitability for the procedure done 4, and for mimicking like tissue 3.5. When asked how confident each participant was in repli-

cating the same steps in sequence in a real-time surgery, the average percentage given was 80%.

Discussion

In reconstructive microsurgery, the learning curve is long, and, hands-on surgical training for residents is limited as the procedures are complex and time-taking. Free tissue transfer involves multiple steps like (1) planning a proper flap of required components and dimensions, (2) preparation of the defect (like debridement in traumatic wounds), (3) dissecting and preparation of the donor vessels, (4) harvesting a flap with required pedicle length, (5) flap transfer and inset with tension free alignment of the vessels, (6) microvascular anastomosis, and (7) closure of donor sites. In general, the majority of the plastic surgery residents report having little confidence in performing head and neck reconstructions.³ Cadaveric dissection training, if introduced as a regular teaching module in the postgraduate curriculum, and if trainees are allowed to perform all the steps independently, will help them gain more confidence at the end of the residency program.

Unlike in formalin-embalmed cadavers, dissections in soft-embalmed cadavers mimic the natural tissue planes. Various methods of soft embalming are described in literature. The most popular Theil method of soft embalming is not suitable for tropical countries. Some institutions in India are making the soft embalming liquids as described in the "modified Theil technique" by Iyer et al.⁴ However, there are restrictions on the availability of some ingredients as they are banned in a few Indian states, and some of the components (ammonium nitrate and potassium nitrate) are unsafe due to their explosive nature.⁵

One method of soft embalming using saturated salt solution described by Shirai et al⁶ looks promising and simple. We used cadavers fixed by Genelyn embalming solution in all the three dissection courses. Our anatomy department procured the Genelyn embalming solution, a proprietary solution that an Australian company has made available in India. The main advantage of Genelyn over modified Theil technique is that it is a simple embalming technique as we need not acquire and assemble different ingredients and is cheaper. It is cost effective⁷ especially for teaching institutions where cadavers are available by donation, or from unclaimed bodies in the forensic department. We observed minimal differences in color of the tissues from cadaver to cadaver that we thought might be due to the nature of the cadaver and timing of embalming from the event of death. The disadvantages of Genelyn are the limited period of preservation (2–4 weeks) and the lack of natural color.⁸ Thus, it is practically very difficult to collect enough cadavers in a short time window for running the courses. Even if it is possible for an institute to do a workshop with limited cadavers, it is difficult and costly for all the residents from another institute elsewhere to participate. It is easier for the teaching institutes to plan flap dissection training inhouse for their residents as and when cadavers are available.

For our first workshop, we had problems in obtaining cadavers as our medical college is new and our forensic department does not conduct postmortems. But with more public awareness programs and with the help of social media, we have started receiving cadaver donations. The plastic surgery departments in teaching institutions can coordinate with their institutes' anatomy departments to procure or prepare the soft embalming liquids as they are not very expensive. The Anatomy Dissection Hall can be used as a cadaveric laboratory for plastic surgery residents. Senior plastic surgeons who are experts in the other subspecialties from the same city may also be invited to guide and train the residents in their respective field of expertise and choice. We limited our first two workshops for flap dissections, but in the third, we included vessel dissections and flap transfers to simulate the clinical scenario. The participants were mainly young plastic surgeons from outstation and residents from other institutions. All the participants requested that we conduct more such workshops. Based on our experience with the three courses and the strong positive feedback after the third workshop, we are of the strong opinion that hands-on cadaveric dissection courses with microvascular training for residents and early-career plastic surgeons would play a major role in equipping them to confidently perform micro-

surgery, which is an integral part of plastic surgery and not a subspecialty. Sheckter et al³ have described their experiences with incorporating surgical simulation on cadavers into a plastic surgery resident training program over a period of 5 years, and monitored individual resident's progress. They mentioned that this resulted in significant increase in residents' confidence levels. Even perfused cadaver models for enhanced simulation in microsurgical training have been tried.^{9,10}

We feel cadaver training when clubbed with traditional microsurgical skill workshops can make up for a better training module.

The cadaveric dissection courses would also allow residents to practice other skills, such as harvesting costal cartilage, carving auricular framework, rhinoplasty, and dissecting brachial plexus and various nerves.

Conclusion

As a part of evolution of resident training in plastic surgery especially reconstructive microsurgery, incorporating dissection on soft embalmed cadavers as an in-house teaching module as and when the cadavers are available is need of the hour. Further research into better ways of including cadaver training into plastic surgery teaching and exploring suitable objective measures of improvement in skills of the participating residents is necessary.

Financial Support

Nil.

Conflict of Interest

None.

Acknowledgments

We would like to express our thanks to ESIC Medical College, Santhnagar, Hyderabad, for supporting us to conduct free cadaver workshops and we would also like to thank Srujana Katta, doctoral student (Oxford University), for editing the manuscript.

References

- 1 Bauer F, Koerdt S, Hölzle F, Mitchell DA, Wolff KD. Eight free flaps in 24 hours: a training concept for postgraduate teaching of how to raise microvascular free flaps. *Br J Oral Maxillofac Surg* 2016;54(01):35–39
- 2 Turner AJ, Mellington A, Ali F. Fresh cadaver dissection for training in plastic surgery. *Br J Plast Surg* 2005;58(05):742–743
- 3 Sheckter CC, Kane JT, Minneti M, et al. Incorporation of fresh tissue surgical simulation into plastic surgery education: maximizing extraclinical surgical experience. *J Surg Educ* 2013;70(04):466–474
- 4 Reddy R, Iyer S, Pillay M, Thankappan K, Ramu J. Soft embalming of cadavers for training purposes: optimising for long-term use in tropical weather. *Indian J Plast Surg* 2017;50(01):29–34
- 5 Janczyk P, Weigner J, Luebke-Becker A, Kaesmeyer S, Plendl J. Nitrite pickling salt as an alternative to formaldehyde for embalming in veterinary anatomy—a study based on histo- and microbiological analyses. *Ann Anat* 2011;193(01):71–75

- 6 Shirai T, Hayashi S, Itoh M. Experience of raising flaps using cadavers embalmed by saturated salt solution method. *Plast Reconstr Surg Glob Open* 2015;3(10):e543
- 7 Ng NY, Loh CY, Athanassopoulos T. A cost-effective cadaveric model for plastic surgery simulation. *Indian J Plast Surg* 2016;49(01):121–123
- 8 Jaung R, Cook P, Blyth P. A comparison of embalming fluids for use in surgical workshops. *Clin Anat* 2011;24(02):155–161
- 9 Wolff KD, Fichter A, Braun C, Bauer F, Humbs M. Flap raising on pulsatile perfused cadaveric tissue: a novel method for surgical teaching and exercise. *J Craniomaxillofac Surg* 2014;42(07):1423–1427
- 10 Carey JN, Rommer E, Shekter C, et al. Simulation of plastic surgery and microvascular procedures using perfused fresh human cadavers. *J Plast Reconstr Aesthet Surg* 2014;67(02):e42–e48