

## Ultrasound-guided superficial peroneal nerve block: A simple technique for procedural analgesia during dorsalis pedis arterial cannulation

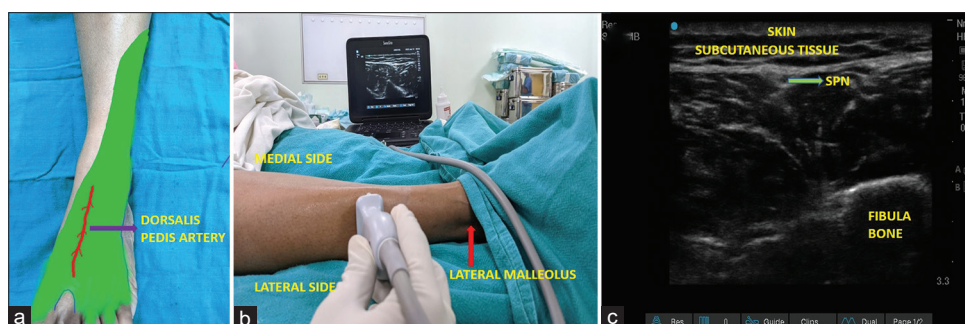Arterial cannulation (AC) is a common point of care invasive procedure performed in the perioperative settings and critical care units. Radial, femoral, and dorsalis pedis arteries (DPAs) are preferred sites owing to ease of access and minimal complications. DPA is the choice of AC for patients when the radial artery is inaccessible.<sup>[1]</sup> The AC is a painful procedure that worsens by repeated attempts to cannulate the artery.<sup>[2,3]</sup> The local lignocaine infiltration on the dorsal surface of the foot is the commonly employed technique for procedural pain relief during DPA cannulation, but the drug infiltration itself causes discomfort and provides a limited area of analgesia.<sup>[2]</sup> The ultrasound-guided peripheral nerve blocks are becoming a leading choice of pain management in recent times.<sup>[4]</sup> The selective block of the superficial peroneal nerve (SPN) can provide excellent analgesia for DPA cannulation, but this technique is not described to date.

The SPN originates as one of the two major branches of the common peroneal nerve, which descends the lateral compartment of the leg deep to the peroneus longus and innervates the peroneus longus and brevis.<sup>[5]</sup> The nerve then penetrates the deep crural fascia in the lower third of the leg and enters the foot, where it divides into medial and lateral branches, which innervates dorsal areas of the foot [Figure 1a]. The nerve can be blocked 5–10 cm above the lateral malleolus in the lateral compartment of the leg, where the nerve lies just deep into the skin and subcutaneous tissue. It is easy to identify and block the

nerve at this site due to its superficial location [Figure 1b and c]. The SPN block at the above location is not associated with any motor blockage. A standard 26-gauge 19 mm length hypodermic needle is enough to reach the site of the peripheral nerve to deposit the local anesthesia (lignocaine 1%) using the in-plane technique with a linear transducer probe (HFL38x, 13—6 MHz 6 cm; The SonoSite EDGE II; SonoSite, Inc. Bothell, WA, USA).

The lidocaine infiltration (LI), topical lidocaine cream, and ethyl chloride spray are reported methods in the literature for pain management during AC.<sup>[1-3]</sup> The topical application carries the drawback of slower onset of action, expensive, and reduced efficacy than LI.<sup>[2]</sup> The subcutaneous LI around the arterial puncture site carries significant discomfort.<sup>[2]</sup> The LI can reduce arterial palpation and can cause difficulty in AC, affecting the success rate. The SPN block can be an effective alternative to LI for procedural analgesia of dorsalis pedis AC. The other advantage the selective nerve block has compared to LI is that the block site is different from the cannulation site. The SPN block has the superiority to local infiltration when considering more proximal AC following an initial failed attempt.

To conclude, SPN block is a simple technique that can provide excellent analgesia for dorsalis pedis AC. Effective procedural pain management can improve the success rate of cannulation, and enhance patient cooperation and comfort.



**Figure 1:** (a) Shows the sensory innervation of the superficial peroneal nerve in the dorsalsurface foot (green color), the hypothetical dorsalis pedis artery shown as the red line. (b) Shows linear ultrasound probe position 5–10 cm above the lateral malleolus. (c) Ultrasound image showing the superficial peroneal nerve in the lateral compartment of the leg. (SPN: Superficial peroneal nerve)

**Financial support and sponsorship**

Nil.

**Conflicts of interest**

There are no conflicts of interest.

**CHITTA R. MOHANTY, RAKESH V. RADHAKRISHNAN<sup>1</sup>,  
NEHA SINGH<sup>2</sup>, SUBHASREE DAS,  
SESHENDRA S. AKELIA**

Departments of Trauma and Emergency, and <sup>2</sup>Anesthesiology and Critical Care, All India Institute of Medical Sciences, Bhubaneswar, Odisha, <sup>1</sup>College of Nursing, All India Institute of Medical Sciences, Bhubaneswar, Odisha, India


**Address for correspondence:** Dr. Chitta R. Mohanty, Department of Trauma and Emergency, All India Institute of Medical Science, Bhubaneswar - 751 019, Odisha, India.  
E-mail: drchitta8@gmail.com

**Submitted:** 14-Mar-2022, **Revised:** 15-Mar-2022,  
**Accepted:** 15-Mar-2022, **Published:** 03-Sep-2022

**References**

- Anand RK, Maitra S, Ray BR, Baidhya DK, Khanna P, Chowdhury SR, *et al.* Comparison of ultrasound-guided versus conventional palpatory method of dorsalis pedis artery cannulation: A randomized controlled trial. *Saudi J Anaesth* 2019;13:295-8.
- Rüsch D, Koch T, Seel F, Eberhart L. Vapocoolant spray versus lidocaine infiltration for radial artery cannulation: A prospective, randomized, controlled clinical trial. *J Cardiothorac Vasc Anesth* 2017;31:77-83.
- Bray K, Winkelman C, Bernhofer EI, Marek JF. Procedural pain in the adult neurological intensive care unit: A retrospective study examining arterial line insertion. *Pain Manag Nurs* 2020;21:323-30.
- Sehmbi H, Madjdpour C, Shah UJ, Chin KJ. Ultrasound guided distal peripheral nerve block of the upper limb: A technical review. *J Anaesthesiol Clin Pharmacol* 2015;31:296-307.
- Standring S. *Gray's Anatomy: The Anatomical Basis of Clinical Practice*. 40<sup>th</sup> ed. London UK: Churchill Livingstone Elsevier; 2008.

This is an open access journal, and articles are distributed under the terms of the Creative Commons Attribution-NonCommercial-ShareAlike 4.0 License, which allows others to remix, tweak, and build upon the work non-commercially, as long as appropriate credit is given and the new creations are licensed under the identical terms.

Access this article online	
<b>Website:</b> www.saudija.org	<b>Quick Response Code</b> 
<b>DOI:</b> 10.4103/sja.sja_227_22	

**How to cite this article:** Mohanty CR, Radhakrishnan RV, Singh N, Das S, Akelia SS. Ultrasound-guided superficial peroneal nerve block: A simple technique for procedural analgesia during dorsalis pedis arterial cannulation. *Saudi J Anaesth* 2022;16:518-9.

© 2022 Saudi Journal of Anesthesia | Published by Wolters Kluwer - Medknow