

Cervical Deformity Correction Fails to Achieve Age-Adjusted Spinopelvic Alignment Targets

PETER G. PASSIAS, MD¹; KATHERINE E. PIERCE, BS¹; SAMANTHA R. HORN, BA¹; ANAND SEGAR, MD²; LARA PASSFALL, BS¹; NICHOLAS KUMMER, BS¹; OSCAR KROL, BA¹; COLE BORTZ, BA¹; AVERY E. BROWN¹; HADDY ALAS, MD¹; FRANK A. SEGRETO, BS¹; WALEED AHMAD, MS¹; SARA NAESSIG, BS¹; AARON J. BUCKLAND, MBBS²; THEMISTOCLES S. PROTOPSALTIS, MD²; MICHAEL GERLING, MD²; RENAUD LAFAGE, MS³; FRANK J. SCHWAB, MD³; AND VIRGINIE LAFAGE, PhD³

¹Departments of Orthopaedic and Neurologic Surgery, NYU Langone Orthopedic Hospital; New York Spine Institute, New York, NY, USA; ²Department of Orthopaedics, NYU Langone Orthopedic Hospital, New York, NY, USA; ³Department of Orthopaedic Surgery, Hospital for Special Surgery, New York, NY, USA

ABSTRACT

Objective: To assess whether surgical cervical deformity (CD) patients meet spinopelvic age-adjusted alignment targets, reciprocal, and lower limb compensation changes.

Study Design: Retrospective review.

Methods: CD was defined as C2-C7 lordosis $>10^\circ$, cervical sagittal vertical angle (cSVA) >4 cm, or T1 slope minus cervical lordosis (TS-CL) $>20^\circ$. Inclusion criteria were age >18 years and undergoing surgical correction with complete baseline and postoperative imaging. Published formulas were used to create age-adjusted alignment target for pelvic tilt (PT), pelvic incidence and lumbar lordosis (PI-LL), sagittal vertical angle (SVA), and lumbar lordosis and thoracic kyphosis (LL-TK). Actual alignment was compared with age-adjusted ideal values. Patients who matched ± 10 -year thresholds for age-adjusted targets were compared with unmatched cases (under- or overcorrected).

Results: A total of 120 CD patients were included (mean age, 55.1 years; 48.4% women; body mass index, 28.8 kg/m²). For PT, only 24.4% of patients matched age-adjusted alignment, 51.1% overcorrected for PT, and 24.4% undercorrected. For PI-LL, only 27.6% of CD patients matched age-adjusted targets, with 49.4% overcorrected and 23% undercorrected postoperatively. Forty percent of patients matched age-adjusted target for SVA, 41.3% overcorrected, and 18.8% undercorrected. CD patients who had worsened in TS-CL or cSVA postoperatively displayed increased TK (-41.1° to -45.3° , $P = 1.06$). With lower extremity compensation, CD patients decreased in ankle flexion angle postoperatively (6.1° – 5.5° , $P = 0.036$) and trended toward smaller sacrofemoral angle (199.6–195.6 mm, $P = 0.286$) and knee flexion (2.6° to -1.1° , $P = 0.269$).

Conclusions: In response to worsening CD postoperatively, patients increased in TK and recruited less lower limb compensation. Almost 75% of CD patients did not meet previously established spinopelvic alignment goals, of whom a subset of patients were actually made worse off in these parameters following surgery. This finding raises the question of whether we should be looking at the entire spine when treating CD.

Level of Evidence: 3.

Cervical Spine

Keywords: cervical deformity, age-adjusted alignment, CD

INTRODUCTION

Deformity of the cervical spine is debilitating and significantly affects quality of life by increasing the energy required to sustain upright position and limiting the ability to maintain horizontal gaze. Correction of cervical deformity (CD) can lead to improved postoperative results and patient-reported outcomes.¹ There has been a recent push in spine surgery to establish and follow a patient-specific approach to deformity. Lafage et al, developed age-adjusted alignment ideals for the lumbar spine and pelvis and demonstrated that meeting those alignment targets resulted in a lower rate junction failure after long thoracolumbar fusions.^{2,3}

Reciprocal changes in the cervical spine, pelvis, and lower extremity after thoracolumbar fusion have been well investigated in the literature and have been shown to correlate with quality-of-life outcomes.^{4–10} Furthermore, it is becoming evident that changes in lower limb alignment are additional compensatory mechanisms in adult spinal deformity.¹¹

Despite this, there is a paucity in the literature describing the global dynamic changes that occur after correction of CD. Understanding the reciprocal changes in the thoracolumbar spine, pelvis, and lower limbs is important, as it enables a more refined surgical approach, has the potential to minimize fusion levels, and may improve long-term outcomes. Mizutani et al found that correction of CD can

restore both local alignment as well as global sagittal alignment; however, the authors did not relate these alignment findings to age-appropriate ideals.¹² This study aims to quantify the reciprocal changes that occur in the thoracolumbar spine, pelvis, and lower extremities after fusion for CD with comparison made to the age-adjusted ideal values defined by Lafage et al.

METHODS

Data Source

This was a retrospective review of nonconsecutive patients visiting a single academic center for spine concerning complaints from November 2013 to May 2017. Institutional Review Board approval was obtained prior to study initiation. Patient consent was not necessary to obtain due to the deidentified nature of the retrospective study design.

Data Collection

Demographic data collected included age, body mass index, and gender. Each patient underwent biplanar full-body stereographic imaging (EOS imaging, Paris, France).

Biplanar Radiographic System and Evaluation

The standardized protocol for imaging with the EOS system involves patients in a weight-bearing, free-standing position, arms flexed at 45° with finger placed upon the clavicles to avoid superimposition of the spine and to maintain the patient's center of gravity.¹³ Anteroposterior and lateral images are simultaneously acquired while translating the system vertically.¹⁴ To compute the images, Surgimap (Nemaris Inc., New York, NY, USA) was utilized at a single center. Cervical alignment was quantified by the cervical sagittal vertical angle (cSVA: angle between the C2 plumb line and the posterior superior end plate of C7), C2-C7 lordosis (cervical lordosis [CL]: angle between the inferior end plate of C2 and the inferior end plate of C7), and the T1 slope minus CL (TS-CL: angle between the superior end plate of T1 and the horizontal).

Sagittal spinopelvic parameters were quantified by the sagittal vertical angle (SVA: horizontal distance between plumb line extended from C7 vertebral body and posterosuperior S1 vertebral corner), the mismatch between pelvic incidence and lumbar lordosis (PI-LL), pelvic tilt (PT: angle between vertical and line from the center of the bicoxofemoral axis to the midpoint of S1 end plate), and the mismatch between lumbar lordosis and thoracic kyphosis (LL-TK). LL-TK has been shown to be a good predictor for sagittal balance, especially when combined with PI-LL.¹⁵ Radiographic parameters of sagittal spine-pelvis-leg alignment

included sacrofemoral angle (SFA; the angle between the line along the S1 end plate and the line along the axis of the femur), kyphotic angle (KA), ankle angle (AA), pelvic shift (PS), and global spinal alignment (GSA) (Figure 1).¹⁶

Study Inclusion Criteria

Patients included in the present analysis were adults (>18 years) with a diagnosis of CD with the radiographic criteria of C2-C7 lordosis >10°, cSVA >4 cm, or TS-CL >20°. All patients had complete baseline and postoperative biplanar full-body stereoradiographic imaging (EOS imaging, Paris, France).

Age-Alignment Grouping

Patients included in the present study were stratified into 3 age cohorts, which were established based on prior publications analyzing spinal deformity and full-body alignment: young (younger than 40 years), middle (40–65 years), elderly (65 years or older). Age-specific alignment goals for sagittal correction were set for patients in each age group for SVA, PT, PI-LL, and LL-TK according to previously published formulas²:

$$SVA = 2 * (Age - 55) + 25 \quad PT = \frac{(Age-55)}{3} + 20$$

$$PI - LL = \frac{(Age-55)}{2} + 3 \quad LL - TK = \frac{(Age-55)}{2} + 15$$

By comparing the actual postoperative alignment (ACTUAL) to the age-adjusted values (IDEAL) generated from the above (established by Lafage et al), correction groups were established: matched (MATCH), undercorrected (UNDER), and overcorrected (OVER). Matched patients' actual postoperative alignment reached a ±10-year interval of age-adjusted values compared with unmatched cases (UNDER and OVER), through the utilization of the above equations. Differences were compared for lower extremity compensatory mechanisms (SFA, KA, AA, PS, and GSA) in patients of each age group (<40, 40–65, ≥65 years), as well as preoperative to postoperative (1 year) change in lower extremity compensatory mechanisms for the overall cohort, worsened CD (categorized by an increase in TS-CL and cSVA), and improved CD (with decrease in TS-CL and cSVA).

Statistical Analysis

All statistical analyses were performed using SPSS software (version 21.0, Armonk, NY, USA), and statistical significance was set at $P < 0.05$. Descriptive statistics were used to describe categorical and continuous variables. Paired *t* tests compared changes in alignment among the

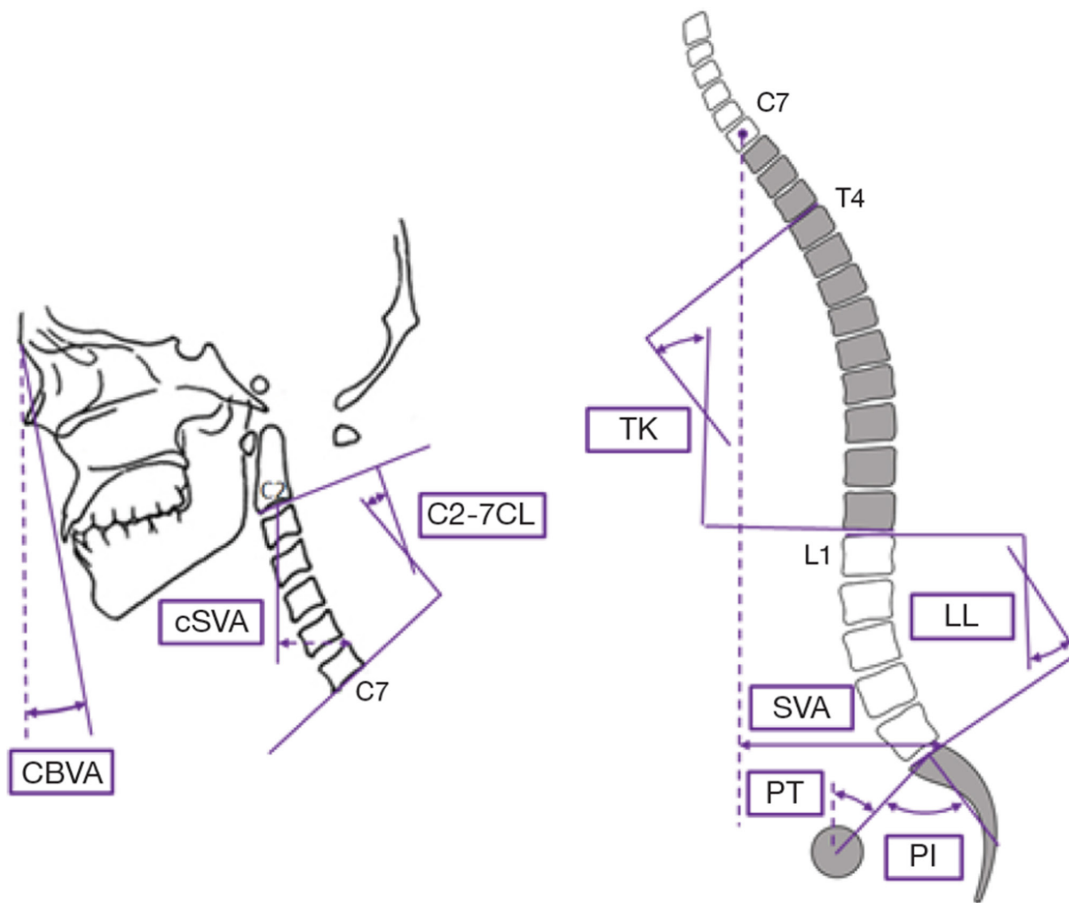


Figure. Schematic of the measured sagittal alignment parameters for the cervical and global spinopelvic spinal regions. cSVA, cervical sagittal vertical axis; CL, cervical lordosis; CBVA, chin-brow vertical angle; TK, thoracic kyphosis; LL, lumbar lordosis; SVA, sagittal vertical axis; PT, pelvic tilt; PI, pelvic incidence.

correction groups from preoperative to 1 year postoperative. Crosstabulations compared changes in radiographic parameters of spinopelvic alignment (SVA, PT, PI-LL, and LL-TK) as well as lower extremity compensation.

RESULTS

Overall Cohort Characteristics

A total of 120 patients who underwent elective surgical correction of CD with full-body EOS imaging were included in this study. The average age was 55.1 (SD \pm 12.2) years, 48.4% of patients were women, and the average body mass index was 28.8 (SD \pm 5.3) kg/m². By surgical approach, 38% had anterior-only surgery, 46% had posterior-only, and 16% had a combined approach. The median upper instrumented vertebrae of the cohort was C4, with the median lower instrumented vertebrae being at C7. The highest upper instrumented vertebrae within the cohort was C1, and the lowest lower instrumented vertebrae was L3. The low age group (<40 years) comprised 7.7% of patients, the middle age group (40–65 years) included 69%, and the older group (\geq 65 years) had 23%. All preoperative

spinopelvic parameters increased significantly across all age groups ($P < 0.050$), while lower limb alignment parameters did not ($P > 0.050$) (Table 1).

Radiographic Alignment

Baseline and postoperative imaging at 1 year for sagittal spinopelvic and cervical alignment were compared in the entirety of the cohort. PI-LL (-3.1° to -1.1° , $P = 0.034$), C2-C7 (3° – 7.7° , $P = 0.024$), and C2-T3 SVA (51.4–55.9, $P = 0.026$) all significantly increased postoperatively. Alignment parameters including PT, T4-T12, T1SS (T1 sacral slope), TS-CL, cSVA, C2-T3, C2SS (C2 sacral slope), and SVA were similar across baseline and postoperative values (Table 2).

ACTUAL vs IDEAL Radiographic Analysis

Comparison of ACTUAL 1 year postoperative and age-adjusted IDEAL alignment for each age cohort (Table 3) revealed that the youngest group of patients (<40 years) displayed significantly lower PT and higher LL-TK compared with their IDEAL measurements ($P < 0.05$). In the

Table 1. Alignment values measured preoperatively for spinopelvic and lower extremity alignment parameters across increasing patient age groups.

Actual Postoperative Alignment	Age Group			P
	<40 y	40–65 y	≥65 y	
Spinopelvic				
Sagittal vertical axis (mm)	-14 ± 15.6	-1.2 ± 48.3	16.8 ± 46.8	0.050
Pelvic tilt (°)	7.8 ± 4.8	15.7 ± 9.1	24.3 ± 9.5	<0.001
Pelvic Incidence minus lumbar lordosis (°)	-9.2 ± 9.8	-3.5 ± 11.9	5.7 ± 14.2	0.002
Lumbar lordosis and thoracic kyphosis (°)	22.1 ± 14.5	15.4 ± 13.4	-1 ± 22	<0.001
Lower extremity				
Sacrofemoral angle (°)	205.5 ± 12.7	199.3 ± 9.4	198.3 ± 11.4	0.312
Knee angle (°)	0.06 ± 4.2	3.7 ± 6.2	1.3 ± 5.7	0.743
Ankle angle (°)	4.5 ± 2.3	6.6 ± 3.1	5.5 ± 2.9	0.858
Pelvic shift (mm)	20 ± 23.5	21.6 ± 30.3	15.3 ± 36.5	0.617

Note: **Boldface** indicates statistical significance.

age group 40–65 years, all spinopelvic parameters, except for LL-TK were smaller than the IDEAL alignment values ($P < 0.005$). In the oldest age group (≥ 65 years), SVA and LL-TK were significantly smaller than the IDEAL value ($P < 0.005$). Calculated age-adjusted IDEAL alignment for the entirety of the cohort was PT = 20.1°; PI-LL = 3.1°; SVA = 25.3 mm; LL-TK = 15.1°. Comparing the ACTUAL values to IDEAL, PT, PI-LL, and SVA was significantly smaller ($P < 0.001$). The spinopelvic parameter LL-TK was similar within the cohort to the IDEAL value ($P = 0.117$) (Table 4).

Age-Adjusted Correction Groups

Table 5 shows rates of patients in MATCH (reaching a ± 10 -year interval of age-adjusted values), UNDER, and OVER groups comparing ACTUAL postoperative alignment to IDEAL age-adjusted values between age groups, as well as overall. For PT in the entirety of the cohort, 24.4% of patients matched their age-adjusted alignment goals, with 51.1% of patients OVER and 24.4% UNDER. 27.6% of CD patients matched their age-adjusted alignment targets for PI-LL, with 49.4% OVER and 23% UNDER postoperatively. For SVA, 40% of patients met their IDEAL alignment goals, 41.3% OVER, and 18.8% UNDER. 18.7% of

CD patients matched their goals for LL-TK, while 42.9% were UNDER and 38.5% OVER.

Postoperative Cervical Deformity Severity on Lower Extremity Compensation

Overall, 39.6% of patients had improvement in CD, while 32.9% worsened, leaving 27.5% of the patient population without change. This was categorized by a decrease in TS-CL and cSVA for improved patients, and an increase in these 2 alignment angles for one whose CD worsened. The overall CD cohort decreased in TK (-42.1° to -43°), SFA (199.6–195.6 mm), and KA (2.7° to -1°), though all compensatory mechanism values were not significant from baseline to 1 year postoperative ($P > 0.05$). AA also decreased postoperatively (6.1°–5.5°), but this change was found to be significant ($P = 0.036$). PS (20.9°–21.9°) and GSA (1°–2.8°) all increased postoperatively, though not significant ($P > 0.05$). When classifying the cohort into patients with improvement in CD and those whose deformity worsened, all lower extremity compensation mechanisms were not significant from preoperative values compared with postoperative alignment values (Tables 6 and 7).

DISCUSSION

Isolated correction of cervical or thoracolumbar sagittal malalignment has been shown to improve patient outcomes and quality of life.^{17,18} In cases of CD in particular, cervical radiographic parameters correlate with health-related quality-of-life measures, and it has been well established that surgical correction can create significant improvement in patient quality of life and function despite a high risk of complication.^{19–22} This improvement has been attributed both to restoration of ideal cervical alignment and to postoperative alleviation of myelopathy.²³ However, the interplay between the fused cervical or cervicothoracic segments and the unfused spine is less understood. There has been a rise in clinical appreciation of the complex global interactions

Table 2. Alignment values measured preoperatively vs 1 y postoperatively for spinopelvic and cervical alignment parameters within the entire cervical deformity cohort.

Radiographic Measure	Preoperative	1 y	P
Pelvic tilt (°)	16	16.8	0.323
Pelvic incidence and lumbar lordosis (°)	-3.1	-1.1	0.034
T4-T12 (°)	-43.1	-42	0.367
T1SS (°)	29	31.5	0.062
T1 slope minus cervical lordosis (°)	25.9	23.9	0.335
C2-C7 (°)	3	7.7	0.024*
Cervical sagittal vertical angle (mm)	26.3	27.7	0.290
C2-T3 (°)	0.74	3.1	0.357
SVA C2-T3 (°)	51.4	55.9	0.026*
C2SS (°)	22.7	20	0.245
SVA (mm)	2.5	8.8	0.142

Abbreviations: C2SS, C2 sacral slope; SVA, sagittal vertical axis; T1SS, T1 sacral slope.

Note: **Boldface** indicates statistical significance.

Table 3. Measured 1 y postoperative (ACTUAL) and age-adjusted (IDEAL) values for sagittal global and spinopelvic alignment parameters for age cohorts.

Age Group, y	Mean Age, y	Sagittal Vertical Axis (mm)		Pelvic Tilt (°)		Pelvic Incidence-Lumbar Lordosis (°)		Lumbar Lordosis-Thoracic Kyphosis (°)	
		ACTUAL	IDEAL	ACTUAL	IDEAL	ACTUAL	IDEAL	ACTUAL	IDEAL
<40	24.9 ± 6.6	1.7 ± 20.5	-12.9 ± 9	7.5 ± 4	13.7 ± 1.5	-8 ± 6.4	-6.5 ± 2.3	23.7 ± 16.3	5.5 ± 2.3
			0.181		0.010		0.499		0.022
40–65	55.9 ± 6.9	4 ± 46.4	17.6 ± 17	15.7 ± 8	18.8 ± 2.1	-3.4 ± 12	1.2 ± 3.1	13.8 ± 18	13.2 ± 3.1
			0.045		0.002		0.004		0.801
≥65	74.1 ± 6.0	27.5 ± 45.4	60.9 ± 11	25.5 ± 11.7	26 ± 1.8	8.9 ± 14	12 ± 2.7	-0.47 ± 25.4	24 ± 2.7
			0.005		0.846		0.311		<0.001

Note: **Boldface** indicates statistical significance ($P < 0.05$).

between the pelvis, spine, and lower extremities with the goal of maintaining horizontal gaze and minimizing energy expenditure. Adjustments in alignment resulting from the fused segments can lead to reciprocal changes in the unfused spine (due to its dynamic nature), as well as the pelvis and lower limbs. These compensatory changes can have implications on a patient’s global orientation and balance, such as persistent malalignment or continued compensation, ultimately leading to ongoing disability and pain. Many studies have investigated the thoracic and cervical changes that occur after extensive thoracolumbar fusion; however, there is a paucity of information on the reciprocal changes in the thoracolumbar spine after correction of CD.

This present study found that after the correction of CD, only 25% of patients met the thoracolumbar age-adjusted alignment ideals described by Lafage et al, with up to 50% being overcorrected (Table 5).² On average, the 40- to 65-year-old age group demonstrated the largest mismatch with overcorrection in SVA, PT, and PI-LL (Table 3). The younger group, age <40 years, was overcorrected for PT and LL-TK (Table 3). Most striking, the eldest age group (>65 years) was significantly overcorrected for SVA and LL-TK (Table 3). Postoperative improvement in CD led to almost no change in lower extremity sagittal alignment (Tables 6 and 7).

Reciprocal changes after thoracolumbar deformity surgery have been well reported in the literature. Klineberg et al found that a thoracic pedicle subtraction osteotomy (PSO) led to 8° decrease in the unfused LL whereas a lumbar PSO led to a 13° increase in unfused TK.⁷ Similarly,

Cacho-Rodrigues and colleagues showed that thoracic PSO for focal kyphosis led to a relaxation in cervical and lumbar hyperlordotic compensation with an upper thoracic PSO decreasing C2-C7 lordosis by 12° and a lower thoracic PSO leading to a 22° decrease in LL.⁸ An additional study identified a subgroup of lumbar deformity patients with exhibited postoperative reciprocal TK after improvement in lumbar alignment, specifically patients with a smaller initial preoperative TK (that is greater thoracic compensation) and PI-LL mismatch.⁴ Last, Ha et al looked at the reciprocal change in cervical alignment after thoracolumbar correction.⁹ They found patients with a low (<6 cm) preoperative cSVA showed a reciprocal increase in T1S and C2-C7 lordosis, and the converse was seen in those with a high (>9 cm) preoperative cVA. Through these studies, a preoperative understanding of the potential changes of the unfused spine is important as it ensures an attentive and congruous correction of deformity with the goal of long-term longevity of the fusion construct.⁶

Reciprocal changes in the thoracolumbar spine, pelvis, and lower extremities, after CD correction are less understood. Kim et al studied this topic in 48 patients undergoing anterior cervical discectomy and fusion.²⁴ Postoperatively, their patients had a decrease in C2-C7 lordosis and, unsurprisingly, a compensatory increase in PT with this pelvic retroversion helping to maintain horizontal gaze. There was no change in TK or LL. Ramachandran and the International Spine Study Group found patients with CD and an increased cSVA compensated with upper cervical (C0-C2) hyperlordosis, increased T1S, and increased PT.²⁵ Postoperatively, there was an improvement in C0-C2 lordosis (38.7°–35.4°), T1S (30.8°–34.2°), and an increase in TK (38.5°–41.1°). The authors found no change in PT or LL; however, the postoperative values were pooled according to preoperative CD severity and some of the granularity of the data may have been lost.

Mizutani et al studied 78 patients who underwent surgery for cervical kyphosis.²⁶ They found “cervical spine–imbalanced” patients, or those with a preoperative negative cSVA, compensatory lumbar hyperlordosis, and low T1S,

Table 4. Measured 1 y postoperative (ACTUAL) and age-adjusted (IDEAL) values for sagittal global and spinopelvic alignment parameters for entire cohort.

Radiographic Measure	ACTUAL	IDEAL	P
Pelvic tilt (°)	17.1	20.1	0.001
Mismatch between pelvic incidence and lumbar lordosis (°)	-1.8	3.1	<0.001
Sagittal vertical axis (mm)	1.9	25.3	<0.001
Mismatch between lumbar lordosis and thoracic kyphosis (°)	12.1	15.1	0.177

Note: **Boldface** indicates statistical significance ($P < 0.0$).

Table 5. Percentages of patients within each age cohort and overall who matched age-adjusted ideals (MATCH), those that undercorrected (UNDER) and those that overcorrected (OVER), based upon a ± 10 -y interval of age-adjusted values calculated with Renaud et al’s established formulas. Differences in lower extremity compensatory mechanisms (SFA, KA, AA, PS, GSA) by age group.

Age Adjustment Ideals	UNDER	Under Overall	MATCH	Match Overall	OVER	Over Overall
Pelvic tilt (°)						
<40 y	0%	24.40%	28.6%	24.40%	71.4%	51.10%
40–65 y	19.4%		27%		53.2%	
≥65 y	47.6%		14.3%		38.1%	
Mismatch between pelvic tilt-lumbar lordosis (°)						
<40 y	25%	23.00%	0%	27.60%	75%	49.40%
40–65 y	22.6%		27.4%		50%	
≥65 y	23.8%		33.3%		42.9%	
Sagittal vertical axis (mm)						
<40 y	42.9%	18.80%	57.1%	40.00%	0%	41.30%
40–65 y	18.5%		40.7%		40.7%	
≥65 y	10.5%		31.6%		57.9%	
Mismatch between lumbar lordosis and thoracic kyphosis (°)						
<40 y	85.7%	42.90%	14.3%	18.70%	0%	38.50%
40–65 y	46.0%		25.4%		28.6%	
≥65 y	19%		0%		81%	

had relaxed the LL (56° – 51°), increased the TK (30° – 34°), and T1S (16° – 27°), after correction of CD. No change was seen in the comparative “cervical spine–balanced” group. These findings suggest that the most severely malaligned patients exhibit flexible deformity into the lumbar spine and pelvis, that the compensatory mechanisms will relax postoperatively, and longer fusions may not be required. Unfortunately, the authors did not consider age-appropriate alignment goals or lower extremity compensation.

When considering spinal deformity, using age-adjusted alignment ideals is important. The initial association of sagittal malalignment and disability, described by Schwab et al, did not account for age and noted that

PT $\geq 22^{\circ}$, SVA ≥ 47 mm, and PI-LL $\geq 11^{\circ}$ were associated with increased disability.¹⁷ Their group further refined these thresholds with age as an important predictor and found that older patients require less rigorous correction of malalignment.² The granularity of this data then allowed Lafage et al to show that overcorrection, when compared with age-adjusted goals, leads to higher rates of junctional failure.³ Hence, correction to appropriate alignment goals is important to the long-term longevity of spinal fusions. In our study, given the oldest patient exhibits overcorrected in the lumbar spine, it is possible the risk of junctional failure could be increased.

Table 6. Differences in lower extremity compensatory mechanisms (SFA, KA, AA, PS, GSA) by age group.

Compensatory Mechanism and Age Group, y	Pre- to Postoperative Change	P
TK		
<40	-1.8	0.410
40–65	-0.79	0.502
≥65	-2.0	0.676
SFA		
<40	5.5	0.075
40–65	6.5	0.275
≥65	-2.3	0.088
KA		
<40	-2.5	0.264
40–65	5.4	0.275
≥65	-0.12	0.931
AA		
<40	-0.44	0.757
40–65	1.14	0.002 ^a
≥65	-0.74	0.241
PS		
<40	-6.4	0.517
40–65	-4.9	0.149
≥65	6.5	0.521
GSA		
<40	-0.48	0.004 ^a
40–65	-2.8	0.224
≥65	0.37	0.629

Abbreviations: AA, ankle angle; CD, cervical deformity; GSA, global sagittal angle; KA, knee angle; PS, pelvic shift; SFA, sacrofemoral angle; TK, thoracic kyphosis.
^aStatistically significant.

Table 7. Pre- to Postoperative differences in lower extremity compensatory mechanisms (SFA, KA, AA, PS, GSA) for overall, worsened (increase in TS-CL and cSVA), and improved (decrease in TS-CL and cSVA) CD cohorts.

Compensatory Mechanism and Cohort	Preoperative	Postoperative	P
TK			
Overall	-42.1	-43	0.535
Worsen	-41.1	-45.3	0.106
Improve	-42.7	-41.4	0.415
SFA			
Overall	199.6	195.6	0.286
Worsen	197.5	196.4	0.225
Improve	199.8	194.6	0.36
KA			
Overall	2.7	-1	0.27
Worsen	3.1	2.8	0.691
Improve	2.6	-2.4	0.33
AA			
Overall	6.1	5.5	0.036 ^a
Worsen	5.9	5.4	0.161
Improve	6.1	5.6	0.19
PS			
Overall	20.9	21.9	0.742
Worsen	22.7	23.1	0.921
Improve	21.9	24.7	0.55
GSA			
Overall	1	2.8	0.261
Worsen	0.79	1	0.593
Improve	1.2	4	0.258

Abbreviations: AA, ankle angle; CD, cervical deformity; cSVA, cervical sagittal vertical angle; GSA, global sagittal angle; KA, knee angle; PS, pelvic shift; SFA, sacrofemoral angle; TK, thoracic kyphosis; TS-CL, T1 slope minus cervical lordosis.
^aStatistically significant.

Lower limb compensation is well described in adult spinal malalignment. With increasing sagittal malalignment compensation with increased pelvic retroversion and loss of thoracic kyphosis is exhausted and lower limb compensatory mechanisms are recruited.⁵ These mechanisms are PS (the horizontal distance between posterosuperior corner of the sacrum and the anterior cortex of the distal tibia), KA (the angle between the sagittal mechanical axes of the femur and tibia), AA (the angle between the sagittal mechanical axis of the tibia and a vertical), and the SFA (line along the S1 end plate and the line along the axis of the femur). With an increasing SVA, PS increased, implying a posterior translation of the pelvis, along with the KA and AA.¹¹

No studies exist investigating the inter-relationship between lower extremity compensation and CD. Comparing our population to normal controls, CD patients have an increased PS (CD 199.6 mm vs normal 9.6 mm) but similar KA (CD 2.7° vs normal 3.7°) and AA (CD 6.1° vs normal 6.6°).¹¹ Furthermore, there was no difference in lower limb postoperative alignment when the population was stratified by age. This can be explained by 2 possibilities: the magnitude of CD is not severe enough to exhaust PT and TK compensation or the lower extremity mechanisms are less important in compensation for CD. Understanding this relationship will require further investigation in future studies.

A primary limitation of this study is its radiographic nature, without associations made to patient-reported outcomes. As a result, we are unable draw conclusions regarding clinical outcomes of the surgical correction. Furthermore, this is a retrospective analysis of surgeon collected data and with possible limited external validity. Thus, the results of this study are limited in their prospective application to the clinical setting. However, remains of the largest studies on reciprocal spinopelvic change after CD surgery.

CONCLUSIONS

Surgery for CD was limited in its ability to restore thoracolumbar and pelvic alignment, with almost 75% of CD patients not meeting previously established spinopelvic alignment goals. This is most concerning in the older patient group, of whom the majority exhibited overcorrected parameters. Lower extremity sagittal alignment does not seem to be affected by CD; however, further study is required. It is clear that CD affects thoracic, lumbar, and pelvic alignment. Preoperatively, the surgeon must be cognizant of potential changes in alignment of the whole spine and tailor a surgical correction that will lead to harmonious spinal balance.

REFERENCES

- Hyun S-J, Kim K-J, Jahng T-A, Kim H-J. Relationship between T1 slope and cervical alignment following multilevel posterior cervical fusion surgery: impact of T1 slope minus cervical lordosis. *Spine (Phila Pa 1976)*. 2016;41(7):E396-402. doi:10.1097/BRS.0000000000001264
- Lafage R, Schwab F, Challier V, et al. Defining spinopelvic alignment thresholds: should operative goals in adult spinal deformity surgery account for age? *Spine (Phila Pa 1976)*. 2016;41(1):62–68. doi:10.1097/BRS.0000000000001171
- Lafage R, Schwab F, Glassman S, et al. Age-adjusted alignment goals have the potential to reduce PJK. *Spine (Phila Pa 1976)*. 2017;42(17):1275–1282. doi:10.1097/BRS.0000000000002146
- Protosaltis TS, Diebo BG, Lafage R, et al. Identifying thoracic compensation and predicting reciprocal thoracic kyphosis and proximal junctional kyphosis in adult spinal deformity surgery. *Spine (Phila Pa 1976)*. 2018;43(21):1479–1486. doi:10.1097/BRS.0000000000002843
- Diebo BG, Ferrero E, Lafage R, et al. Recruitment of compensatory mechanisms in sagittal spinal malalignment is age and regional deformity dependent: a full-standing axis analysis of key radiographical parameters. *Spine (Phila Pa 1976)*. 2015;40(9):642–649. doi:10.1097/BRS.0000000000000844
- Lafage V, Ames C, Schwab F, et al. Changes in thoracic kyphosis negatively impact sagittal alignment after lumbar pedicle subtraction osteotomy: a comprehensive radiographic analysis. *Spine (Phila Pa 1976)*. 2012;37(3):E180-7. doi:10.1097/BRS.0b013e318225b926
- Klineberg E, Schwab F, Ames C, et al. Acute reciprocal changes distant from the site of spinal osteotomies affect global postoperative alignment. *Adv Orthop*. 2011;2011:415946. doi:10.4061/2011/415946
- Cacho-Rodriguez P, Campana M, Obeid I, Vital J-M, Gille O. Sagittal correction and reciprocal changes after thoracic pedicle subtraction osteotomy. *Spine (Phila Pa 1976)*. 2016;41(13):E791–E797. doi:10.1097/BRS.0000000000001386
- Ha Y, Schwab F, Lafage V, et al. Reciprocal changes in cervical spine alignment after corrective thoracolumbar deformity surgery. *Eur Spine J*. 2014;23(3):552–559. doi:10.1007/s00586-013-2953-8
- Protosaltis TS, Scheer JK, Terran JS, et al. How the neck affects the back: changes in regional cervical sagittal alignment correlate to HRQOL improvement in adult thoracolumbar deformity patients at 2-year follow-up. *J Neurosurg Spine*. 2015;23(2):153–158. doi:10.3171/2014.11.SPINE1441
- Lafage R, Liabaud B, Diebo BG, et al. Defining the role of the lower limbs in compensating for sagittal malalignment. *Spine (Phila Pa 1976)*. 2017;42(22):E1282–E1288. doi:10.1097/BRS.0000000000002157
- Mizutani J, Verma K, Endo K, et al. Global spinal alignment in cervical kyphotic deformity: the importance of head position and thoracolumbar alignment in the compensatory mechanism. *Neurosurgery*. 2018;82(5):686–694. doi:10.1093/neuros/nyx288
- Horton WC, Brown CW, Bridwell KH, Glassman SD, Suk S-I, Cha CW. Is there an optimal patient stance for obtaining a lateral 36" radiograph? A critical comparison of three techniques. *Spine (Phila Pa 1976)*. 2005;30(4):427–433. doi:10.1097/01.brs.0000153698.94091.f8

14. Wybier M, Bossard P. Musculoskeletal imaging in progress: the EOS imaging system. *Joint Bone Spine*. 2013;80(3):238–243. doi:10.1016/j.jbspin.2012.09.018

15. Yang C, Yang M, Wei X, et al. Lumbar lordosis minus thoracic kyphosis: a novel regional predictor for sagittal balance in elderly populations. *Spine (Phila Pa 1976)*. 2016;41(5):399–403. doi:10.1097/BRS.0000000000001231

16. Wang WJ, Liu F, Zhu YW, Sun MH, Qiu Y, Weng WJ. Sagittal alignment of the spine-pelvis-lower extremity axis in patients with severe knee osteoarthritis: A radiographic study. *Bone Joint Res*. 2016;5(5):198–205. doi:10.1302/2046-3758.55.2000538

17. Schwab FJ, Blondel B, Bess S, et al. Radiographical spinopelvic parameters and disability in the setting of adult spinal deformity: a prospective multicenter analysis. *Spine (Phila Pa 1976)*. 2013;38(13):E803–12. doi:10.1097/BRS.0b013e318292b7b9

18. Scheer JK, Tang JA, Smith JS, et al. Cervical spine alignment, sagittal deformity, and clinical implications: a review. *J Neurosurg Spine*. 2013;19(2):141–159. doi:10.3171/2013.4.SPINE12838

19. Tang JA, Scheer JK, Smith JS, et al. The impact of standing regional cervical sagittal alignment on outcomes in posterior cervical fusion surgery. *Neurosurgery*. 2012;71(3):662–669. doi:10.1227/NEU.0b013e31826100c9

20. Protosaltis TS, Scheer JK, Terran JS, et al. How the neck affects the back: changes in regional cervical sagittal alignment correlate to HRQOL improvement in adult thoracolumbar deformity patients at 2-year follow-up. *J Neurosurg Spine*. 2015;23(2):153–158. doi:10.3171/2014.11.SPINE1441

21. Passias PG, Horn SR, Bortz CA, et al. The relationship between improvements in myelopathy and sagittal realignment in cervical deformity surgery outcomes. *Spine (Phila Pa 1976)*. 2018;43(16):1117–1124. doi:10.1097/BRS.0000000000002610

22. Sabou S, Mehdian H, Pasku D, Boriani L, Quraishi NA. Health-related quality of life in patients undergoing cervico-thoracic osteotomies for fixed cervico-thoracic kyphosis in patients with ankylosing spondylitis. *Eur Spine J*. 2018;27(7):1586–1592. doi:10.1007/s00586-018-5530-3

23. Ames CP, Blondel B, Scheer JK, et al. Cervical radiographical alignment. *Spine*. 2013;38:S149–S160. doi:10.1097/BRS.0b013e3182a7f449

24. Kim JH, Park JY, Yi S, et al. Anterior cervical discectomy and fusion alters whole-spine sagittal alignment. *Yonsei Med J*. 2015;56(4):1060–1070. doi:10.3349/ymj.2015.56.4.1060

25. Ramchandran S, Protosaltis TS, Sciubba D, et al. Prospective multi-centric evaluation of upper cervical and infra-cervical sagittal compensatory alignment in patients with adult cervical deformity. *Eur Spine J*. 2018;27(2):416–425. doi:10.1007/s00586-017-5395-x

26. Mizutani J, Verma K, Endo K, et al. Global spinal alignment in cervical kyphotic deformity: the importance of head position and thoracolumbar alignment in the compensatory mechanism. *Neurosurgery*. 2018;82(5):686–694. doi:10.1093/neuros/nyx288

Funding: The authors received no financial support for the research, authorship, and/or publication of this article.

Declaration of Conflicting Interests: The authors report no conflicts of interest in this work.

Disclosures: Peter G. Passias, MD: Allosource: Other financial or material support. Cervical Scoliosis Research Society: Research support. Globus Medical: Paid presenter or speaker. Medtronic: Paid consultant. Royal Biologics: Paid consultant. Spine: Editorial or governing board. SpineWave: Paid consultant. Terumo: Paid consultant. Zimmer: Paid presenter or speaker. Aaron J. Buckland, MBBS: Medtronic Sofamor Danek: Paid consultant. Nuvasive: IP royalties; paid consultant. Stryker: Paid consultant. Themistocles S. Protosaltis, MD: Altus: IP royalties. Globus Medical: Paid consultant. Medtronic: Paid consultant. Medtronic: Paid consultant. Nuvasive: Paid consultant. Spine Align: Stock or stock options. Stryker: Paid consultant. Torus Medical: Stock or stock options. Michael Gerling, MD: AAOS: Board or committee member. Cervical Spine Research Society: Board or committee member. Integrity Implants: Paid consultant. Integrity Implants, Inc: IP royalties. RTI Surgical: Paid consultant. Wolf Endoscopic: Paid consultant. Virginie Lafage, PhD: Alphatec Spine: Paid consultant. DePuy, A Johnson & Johnson Company: Paid presenter or speaker. European Spine Journal: Editorial or governing board. Globus Medical: Paid consultant. International Spine Study Group: Board or committee member. Nuvasive: IP royalties. Scoliosis Research Society: Board or committee member. Stryker: Paid presenter or speaker. The remaining authors have no disclosures.

Ethical Review Committee Statement: Each institution obtained approval from their local Institutional Review Board to enroll patients in the prospective database, and informed consent was obtained from each patient.

Corresponding Author: Peter G. Passias, Department of Orthopedic Surgery, New York Spine Institute, NYU School of Medicine/NYU Medical Center – NYU Langone Orthopedic Hospital, 301 E 17th St, New York, NY, 10003, USA; Peter.Passias@nyumc.org

This manuscript is generously published free of charge by ISASS, the International Society for the Advancement of Spine Surgery. Copyright © 2022 ISASS. To see more or order reprints or permissions, see <http://ijssurgery.com>.