

BRIEF REPORT

Open Access



# Elimination of probable praziquantel-resistant *Dipylidium caninum* with nitroscanate in a mixed-breed dog: a case report

John P. Loftus<sup>1\*</sup>, Andrew Acevedo<sup>1,4</sup>, Dwight D. Bowman<sup>2</sup>, Janice L. Liotta<sup>2</sup>, Timothy Wu<sup>2</sup> and Melinda Zhu<sup>3</sup>

## Abstract

**Background:** Praziquantel is the drug of choice for treating the tapeworm *Dipylidium caninum* in dogs; however, resistance is possible, and regular, non-targeted administration of praziquantel may select for anthelmintic-resistant populations.

**Methods:** The zinc sulfate fecal floatation procedure was conducted. Gross visualization was used to identify *Dipylidium* spp. segments, and capsule endoscopy was used to visualize adult tapeworms within the intestinal tract.

**Results:** An 18-month-old spayed female terrier mix was presented due to diarrhea, hematochezia and weight loss. The dog received appropriate anthelmintic therapy for *Giardia* spp., *Ancylostoma* spp. and *Dipylidium* spp. The dog's clinical signs resolved, and elimination of *Ancylostoma* spp. was confirmed by subsequent fecal analysis. However, *Dipylidium* spp. segments were repeatedly present in the stool. Observation of the segments confirmed the presence of adult *Dipylidium* spp. in feces. Treatment with praziquantel and epsiprantel were unsuccessful in eliminating the organism but was apparently successful in flea prevention. A single dose of nitroscanate was administered and eliminated *Dipylidium* spp. infection in the dog.

**Conclusions:** Nitroscanate can be an effective treatment for praziquantel-resistant dipylidiasis in dogs. The novel application of capsule endoscopy confirmed the anthelmintic efficacy of this treatment.

**Keywords:** Praziquantel, Nitroscanate, *Dipylidium*, Capsule endoscopy

*Dipylidium caninum* is a cyclophyllidean cestode parasite of the small intestine in dogs, with an indirect life-cycle primarily transmitted by fleas (*Ctenocephalides felis felis*, *Ctenocephalides canis*, *Pulex irritans*) (see [1–3] for a description of its life-cycle). However, biting lice (*Trichodectes canis*) can also act as intermediate hosts. Gross visualization of cucumber seed-shaped proglottids

in the stool or microscopic identification of egg packets by the fecal floatation procedure is diagnostic for infection with this parasite. However, proglottids may not be uniformly present in feces, and eggs are not always identified in the fecal analysis of infected individuals [1]. The primary treatment for tapeworm infestations in dogs and cats is praziquantel, available in oral, injectable and topical forms. Many current commercial products offer praziquantel in combination with other parasiticides. When combined with other products, praziquantel can be 100% effective for treating tapeworms in dogs [4–6]. Other

\*Correspondence: jpl249@cornell.edu

<sup>1</sup> Department of Clinical Sciences, College of Veterinary Medicine, Cornell University, Ithaca, NY, USA

Full list of author information is available at the end of the article



© The Author(s) 2022. **Open Access** This article is licensed under a Creative Commons Attribution 4.0 International License, which permits use, sharing, adaptation, distribution and reproduction in any medium or format, as long as you give appropriate credit to the original author(s) and the source, provide a link to the Creative Commons licence, and indicate if changes were made. The images or other third party material in this article are included in the article's Creative Commons licence, unless indicated otherwise in a credit line to the material. If material is not included in the article's Creative Commons licence and your intended use is not permitted by statutory regulation or exceeds the permitted use, you will need to obtain permission directly from the copyright holder. To view a copy of this licence, visit <http://creativecommons.org/licenses/by/4.0/>. The Creative Commons Public Domain Dedication waiver (<http://creativecommons.org/publicdomain/zero/1.0/>) applies to the data made available in this article, unless otherwise stated in a credit line to the data.

treatments used in the past include epsiprantel, nitroscanate and off-label use of nitazoxanide [7].

Anthelmintic resistance is described as the phenomenon in which heritable genetic changes in a population of helminths result in a larger proportion of the population remaining alive following the administration of a previously effective drug dose [3]. The potential for the emergence of drug-resistant helminth populations has been attributed to a move away from infrequent, targeted treatments towards regular, metaphylactic treatment using broad-spectrum anthelmintics [8]. Indeed, reports of anthelmintic-resistant populations of canine parasites have emerged, including reports of resistant *Dirofilaria immitis*, *Ancylostoma caninum* and, most recently, *Dipylidium caninum* [3, 9]. In a 2018 report, *Dipylidium* spp. resistance to standard doses of praziquantel was described, with favorable responses to higher doses or alternative treatments, such as nitroscanate [10].

The objective of this article is to document a case of probable praziquantel-resistant *Dipylidium caninum* effectively treated with nitroscanate. We also demonstrate the utility of capsule endoscopy to monitor the effectiveness of anthelmintic therapy in a dog.

An 18-month-old spayed female terrier mix, with a body weight of 9.7 kg, was presented to her primary veterinarian with a history of chronic gastrointestinal signs and persistent *Dipylidium* spp. infection. Tapeworm segments were first found in the dog's stool at 4 months of age, prompting evaluation by the primary veterinarian. The owners reported that she was the sole dog in the household and that they had never observed fleas in their home. The dog presented with diarrhea, hematochezia and an underweight body condition score of 2/5; no evidence of fleas was noted on physical exam and from patient history. Pyrantel pamoate, metronidazole and fenbendazole were recommended for general deworming. Initial differential diagnoses included *Giardia* spp., tapeworms, hookworms, roundworms and whipworms. The initial fecal flotation procedure revealed *Ancylostoma* spp. After treatment, parasites were not detected with subsequent fecal testing (fecal ova and parasite [O&P] examination with centrifugation test, performed with zinc sulfate solution; Antech Diagnostics, Southaven, MS, USA) and *Giardia* enzyme-linked immunosorbent assay (ELISA) tests; however, the owner reported finding tapeworm segments in the stool (Fig. 1) 1 month post-treatment. Praziquantel with pyrantel pamoate (Drontal®; Bayer Animal Health) was administered. However, the organism was not eliminated, as once again the owner reported tapeworm segments in the feces at about 1 month post-treatment. The dog was then treated with milbemycin oxime (Interceptor®; Eli Lilly and Company, Indianapolis, IN, USA),



**Fig. 1** Representative images of feces containing *Dipylidium* segments. Arrow indicates tapeworm segment

afoxolaner (NexGard®; Boehringer Ingelheim, Ingelheim, Germany), imidacloprid and flumethrin (Seresto® collar; Elanco Animal Health, Greenfield, IN, USA) to control fleas as a source of reinfection, as well as with repeated doses of praziquantel with pyrantel pamoate and febantel (Drontal® Plus) (Table 1), but the infection was not eliminated. Epsiprantel (Cestex®; Zoetis, Parsippany-Troy Hills, NJ, USA) was also unsuccessful. The owners did not report evidence of a flea infestation, but it was recommended that they undertake aggressive environmental decontamination. This action included an inspection by a professional exterminator who reported no evidence of fleas and did not advise environmental treatment. However, the owners, desperate to alleviate their pet of tapeworms, used an over-the-counter “flea bomb” (Advantage® Household fogger; Elanco Animal Health) in the dog's place of residence in the hope of disrupting the parasite life-cycle. Afterward, to limit exposure to reinfection, the dog was restricted to house confinement for approximately 6 months, with no dog park or daycare exposure. Samples of the tapeworm segments were sent to Cornell University and identified as *Dipylidium* sp. In order to establish resistance in the context of clinical case management, praziquantel, milbemycin oxime, lufenuron (Sentinel®; Merck Animal Health USA, Madison, NJ, USA) and fluralaner (Bravecto®; MSD Animal Health, Rahway, NJ, USA), were dosed regularly; nitenpyram (Capstar®; Novartis, Basel, Switzerland) was administered repeatedly; and fecal samples were frequently evaluated for the presence of tapeworm segments (Table 1). Capsule endoscopy was employed to directly visualize adult tapeworms in the small intestine. For the endoscopy procedure, the patient was first fasted for 12 h. The endoscopic capsule (CapsoCam Plus® video capsule

**Table 1** Summary of treatments & diagnostic evaluations

Date	Treatment	Diagnostics	Comments
11/2019 & prior	praziquantel, <sup>1</sup> Drontal <sup>®</sup> , <sup>2</sup> Interceptor <sup>®</sup> , <sup>3</sup> Nexgard <sup>®</sup>	Fecal floatation (exact method unknown)	This was before presenting to the primary veterinarian
11/21/2019	<sup>1</sup> Drontal <sup>®</sup>		
12/1/2019	<sup>4</sup> Drontal <sup>®</sup> Plus		Segments observed
1/2020	<sup>4</sup> Drontal <sup>®</sup> Plus, <sup>5</sup> Seresto <sup>®</sup> collar, <sup>6</sup> Cestex <sup>®</sup>	Fecal O&P with Centrifugation	Segments observed
2/2020	<sup>4</sup> Drontal <sup>®</sup> Plus		The dog did not go to dog parks or daycare during COVID quarantine
4/24/2020	<sup>4</sup> Drontal <sup>®</sup> Plus		Owner observed tapeworm segments, began using a basket muzzle to source of potential unknown reinfection
5/22/2020			Owner reported exterminator visit confirming no fleas, "flea bomb" performed prophylactically. Confirmed dog is still receiving flea preventatives
6/17/2020	Praziquantel 20 mg/kg SID × 2 weeks		
6/19/2020			Live tapeworms seen in stool
7/20/2020			Cornell received tapeworm sample and confirmed identity as <i>Dipylidium</i> spp. New treatment protocol initiated
8/5/20	<sup>7</sup> Sentinel <sup>®</sup> & <sup>8</sup> Bravecto <sup>®</sup>		
8/6/20	<sup>9</sup> Capstar <sup>®</sup>		
8/7/20	<sup>9</sup> Capstar <sup>®</sup>		
8/8/20	<sup>9</sup> Capstar <sup>®</sup>		
8/9/20	<sup>9</sup> Capstar <sup>®</sup>		
8/10/20	<sup>9</sup> Capstar <sup>®</sup>	CapsoCam	Adult tapeworm(s) present
8/11/20	<sup>9</sup> Capstar <sup>®</sup>		
8/12/20	<sup>9</sup> Capstar <sup>®</sup>		
8/13/20	<sup>9</sup> Capstar <sup>®</sup>		Live tapeworm recovered in stool
8/14/20	<sup>9</sup> Capstar <sup>®</sup> & praziquantel (5 mg/kg)		
8/15/20			
8/16/20			
8/17/20		CapsoCam	Adult tapeworm(s) present
9/18/2020	<sup>10</sup> Lopato <sup>®</sup> (100 mg/kg once)		
10/7/2020		CapsoCam	No tapeworms present
11/6/2020		CapsoCam	No tapeworms present
6/2/2020		CapsoCam	No tapeworms present; no segments reported by owner after Lopato <sup>®</sup> treatment

<sup>1</sup> Praziquantel with pyrantel pamoate

<sup>2</sup> Milbemycin oximine

<sup>3</sup> Afoxolaner

<sup>4</sup> Praziquantel with pyrantel pamoate and febantel

<sup>5</sup> Imidacloprid and flumethrin

<sup>6</sup> Epsiprantel

<sup>7</sup> Lufenuron

<sup>8</sup> Fluralaner

<sup>9</sup> Nitenpyram

<sup>10</sup> Nitroscionate

system; CapsoVision, Inc., Saratoga, CA, USA0) was then administered orally by a trained veterinary technician, followed by 5–10 ml of water administered by a syringe.

The capsule was recovered in the feces and shipped to the primary author's institution. Acquired data were downloaded with software (CapsoView<sup>®</sup>; CapsoVision,

Inc., Saratoga, CA, USA) for image review. The retrieved images disclosed adult tapeworm segments in the intestinal tract before and after nitenpyram (Capstar®) treatments (Fig. 2; Additional File 1: Video). After the last nitenpyram administration, nitroscionate (Lopatul®; Novartis) was administered (one dose, 200 mg. orally). Fecal samples collected before and after the nitroscionate treatment confirmed treatment efficacy. Capsule endoscopy was repeated after the administration of nitroscionate and corroborated the elimination of *Dipylidium* organisms. At the time of writing this paper, the dog's primary veterinarian reports that after 18 months following the treatment, the dog remains tapeworm free and has not shed tapeworms.

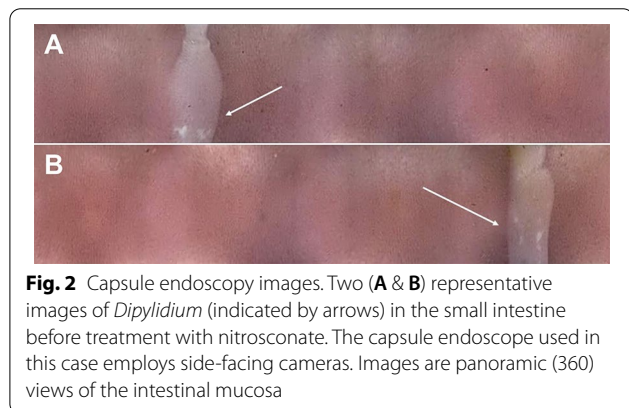
This report documents probable praziquantel-resistant *Dipylidium* sp. that was effectively treated with nitroscionate and highlights the novel use of capsule endoscopy for assessing parasite burden. Throughout this case report, the efficacy of anthelmintic therapy was evaluated by repeated testing for the presence of parasites. Monitoring the stool, grossly and through fecal flotation and *Giardia* ELISA, ruled out other differential diagnoses and assessed if treatment effectively resolved the *Dipylidium* sp. infection. Additionally, capsule endoscopy provided direct visualization of adult tapeworm scolices with segments attached to the small intestinal mucosa and proglottids. In this case, diagnosis of the resistant parasite was based on the presence of proglottids in the stool and on capsule endoscopy following treatment with praziquantel. However, subclinical infections can occur, in which helminths that are not easily visualized grossly (such as with anthelmintic-resistant *Ancylostoma caninum*); therefore, it is important for the veterinarian to routinely monitor for active parasite infections and effective treatment utilizing pre- and post-treatment coproparasitological techniques, such as fecal flotation [11].

Limitations of this case report include the authors' inability to fully assess the efficacy of environmental

decontamination done at the patient's home. Flea infestations are difficult to eliminate in a household, especially when the infestation source, usually a pet, continually re-introduces fleas. Although an over-the-counter "flea bomb" was used, it is a possibility that insufficient environmental decontamination may confound the repeated appearance of tapeworm segments in the stool. However, the aggressive course of flea treatment, environmental decontamination, and evaluation by a professional exterminator make re-infection extremely unlikely in this case. Additionally, the extensive flea treatments and monitoring conducted relative to the last dose of praziquantel makes reinfection as explanation for tapeworm persistence nearly impossible in this case. Although helpful in visualizing the small intestine, images obtained from capsule endoscopy were occasionally obscured by intestinal content, making visualization difficult.

*Dipylidium caninum* is the most common tapeworm in dogs and cats, with a prevalence ranging from 4.0% to 60.0% [7], with some reports as low as 0.3% [12]. The recommended treatment of this tapeworm is 5 mg/kg of praziquantel [6]; however, the exact dosage often varies, as products sold contain fixed amounts of the drug and are labeled for specific weight ranges. This drug tends to have mild to no adverse effects (anorexia, vomiting, lethargy, and diarrhea, which are usually associated with higher doses). It may be given at higher doses or repeated weekly or even daily to treat some infections. One study found that dogs treated with six times the recommended therapeutic dose vomited only occasionally [4]. Typically, *Dipylidium caninum* infections cause little to no clinical signs in dogs and cats. On the rare occasion that dipylidiasis causes clinical signs, abdominal pain, vomiting, diarrhea, and mild anal pruritus may be encountered. In this case, we chose nitroscionate over nitazoxanide due to availability and the lower cost of the former. The safety of nitroscionate has also been previously reported in dogs [13]. However, since treating this case, the authors have learned that nitroscionate may no longer be available, and in some cases, nitazoxanide may be the only viable treatment for cases that do not respond to the first or second-line treatments described above.

Several challenges were encountered in this case. In tapeworm infections involving flea infestations, re-infection is common, as fleas continually hatch in the environment, and a patient may ingest these new fleas after treatment. Thus, praziquantel resistance may be mistakenly assigned to situations where the infection was only temporarily eliminated. Additionally, there is a prepatent period of approximately 2.5 weeks after infection before dogs and cats begin to shed proglottids that can be seen in feces [7].



**Fig. 2** Capsule endoscopy images. Two (A & B) representative images of *Dipylidium* (indicated by arrows) in the small intestine before treatment with nitroscionate. The capsule endoscope used in this case employs side-facing cameras. Images are panoramic (360) views of the intestinal mucosa

This case corroborates the potential efficacy of nitroscanate for treating praziquantel-resistant *Dipylidium caninum*. Additionally, capsule endoscopy can assist in confirming anthelmintic treatment success in infections where fecal analysis alone may not adequately demonstrate the elimination of organisms.

## Supplementary Information

The online version contains supplementary material available at <https://doi.org/10.1186/s13071-022-05559-2>.

**Additional file 1.** Video: Capsule endoscopy video of a tapeworm in the dog's small intestine. This movie captures the tapeworm segment in the small intestine of the dog in this case report before nitroscanate administration. This is a side-facing camera capsule endoscope, therefore the images depict a panoramic (360 deg) view of the the small intestinal mucosa.

## Acknowledgements

None.

## Author contributions

PL and DDB provided treatment recommendations. MZ primarily managed the case. JLL conducted fecal analyses and was a major contributor to writing the manuscript. AA and JPL reviewed capsule endoscopy images. AA and JPL drafted the manuscript. All authors read and approved the final manuscript.

## Funding

Elanco generously provided funding for capsule endoscopy.

## Availability of data and materials

Data are available upon request, with patient identifiers redacted.

## Declarations

### Ethics approval and consent to participate

Informed owner consent was obtained.

### Consent for publication

All authors consent to this manuscript's publication.

### Competing interests

The authors disclose no conflicts of interest.

## Author details

<sup>1</sup>Department of Clinical Sciences, College of Veterinary Medicine, Cornell University, Ithaca, NY, USA. <sup>2</sup>Department of Microbiology and Immunology, College of Veterinary Medicine, Cornell University, Ithaca, NY, USA. <sup>3</sup>Williamsburg Animal Clinic, 760 Grand St., Brooklyn, NY 11211a, USA. <sup>4</sup>Present Address: Center for Bird and Exotic Animal Medicine, 11401 NE 195Th St, Bothell, WA 98011, USA.

Received: 11 August 2022 Accepted: 25 October 2022

Published online: 22 November 2022

## References

- Conboy G. Cestodes of Dogs and Cats in North America. *Vet Clin N Am Small Anim Pract.* 2009;39:1075–90.
- Georgi JR. Tapeworms. *Vet Clin N Am Small Anim Pract.* 1987;17:1285–305.
- Georgis' parasitology for veterinarians—Elsevier ebook on VitalSource, 10th edition—9780323228190 [Internet]. [cited 2022 Oct 20]. <https://evolve.elsevier.com/cs/product/9780323228190?role=student>
- Barnett S, King S, Kok D, Luempert L. Efficacy evaluation of flavored combination parasiticide tablets in a laboratory study for the removal of natural *Dipylidium caninum* (tapeworm) infections in dogs. *Int J Appl Res Vet Med.* 2013;11:36–45.
- Tüzer E, Bilgin Z, Oter K, Erçin S, Tinar R. Efficacy of praziquantel injectable solution against feline and canine tapeworms. *Türkiye Parazitoloj Derg.* 2010;34:17–20.
- Schmid K, Rohdich N, Zschiesche E, Kok DJ, Allan MJ. Efficacy, safety and palatability of a new broad-spectrum anthelmintic formulation in dogs. *Vet Rec.* 2010;167:647–51.
- Dipylidium caninum* [Internet]. Companion Animal Parasite Council. [cited 2022 Feb 3]. <https://capcvet.org/guidelines/dipylidium-caninum/>
- Thompson RC, Roberts MG. Does pet helminth prophylaxis increase the rate of selection for drug resistance? *Trends Parasitol.* 2001;17:576–8.
- von Samson-Himmelstjerna G, Thompson RA, Krücken J, Grant W, Bowman DD, Schnyder M, et al. Spread of anthelmintic resistance in intestinal helminths of dogs and cats is currently less pronounced than in ruminants and horses—yet it is of major concern. *Int J Parasitol Drugs Drug Resist.* 2021;17:36–45.
- Jesudoss Chelladurai J, Kifleyohannes T, Scott J, Brewer MT. Praziquantel resistance in the zoonotic cestode *Dipylidium caninum*. *Am J Trop Med Hyg.* 2018;99:1201–5.
- Dambrosio Fernandes F, Rojas Guerra R, Segabinazzi Ries A, Felipetto Cargnelutti J, Sangioni LA, Silveira Flores Vogel F. Gastrointestinal helminths in dogs: occurrence, risk factors, and multiple antiparasitic drug resistance. *Parasitol Res.* 2022;121:2579–86.
- Gates MC, Nolan TJ. Endoparasite prevalence and recurrence across different age groups of dogs and cats. *Vet Parasitol.* 2009;166:153–8.
- Boray JC, Strong MB, Allison JR, von Orelli M, Sarasin G, Gfeller W. Nitroscanate\* a new broad spectrum anthelmintic against nematodes and cestodes of dogs and cats. *Aust Vet J.* 1979;55:45–53.

## Publisher's Note

Springer Nature remains neutral with regard to jurisdictional claims in published maps and institutional affiliations.

Ready to submit your research? Choose BMC and benefit from:

- fast, convenient online submission
- thorough peer review by experienced researchers in your field
- rapid publication on acceptance
- support for research data, including large and complex data types
- gold Open Access which fosters wider collaboration and increased citations
- maximum visibility for your research: over 100M website views per year

At BMC, research is always in progress.

Learn more [biomedcentral.com/submissions](https://biomedcentral.com/submissions)

