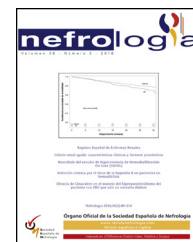




Since January 2020 Elsevier has created a COVID-19 resource centre with free information in English and Mandarin on the novel coronavirus COVID-19. The COVID-19 resource centre is hosted on Elsevier Connect, the company's public news and information website.

Elsevier hereby grants permission to make all its COVID-19-related research that is available on the COVID-19 resource centre - including this research content - immediately available in PubMed Central and other publicly funded repositories, such as the WHO COVID database with rights for unrestricted research re-use and analyses in any form or by any means with acknowledgement of the original source. These permissions are granted for free by Elsevier for as long as the COVID-19 resource centre remains active.



Letter to the Editor

Glomerulopathies after vaccination against COVID-19. Four cases with three different vaccines in Argentina

Glomerulopatías después de la vacunación frente a COVID-19. Cuatro casos con tres vacunas diferentes en Argentina

Dear Editor,

After reading some recent reports on the appearance or de novo recurrence of different glomerulopathies after the application of vaccines against COVID-19¹⁻¹⁰ we would like to contribute our experience.

Four patients (P) previously asymptomatic began with asthenia (P1, P2), foamy urine (all) and edema (P2, P3) within 2 weeks after the first dose of the COVID-19 vaccine (P1: Sinopharm, P2: Oxford-AstraZeneca, P3 and P4: Gamaleya). All presented hypertension and microscopic hematuria. The first three patients also presented with acute kidney injury, nephrotic range proteinuria, hypoalbuminemia and dyslipidemia. The P4 increased his proteinuria significantly. Renal biopsies performed showed two IgA nephropathy with crescent ([Supplementary Fig. S1, A-F](#)) and recurrence of proliferative glomerulonephritis ([Supplementary Fig. S2, A and B](#)).

P4 did not undergo a new biopsy since she had a previous diagnosis in 2020 of minimal change disease ([Supplementary Fig. S2, C and D](#)) and it was interpreted as the beginning of a recurrence of her disease. All received corticosteroids and P1 and P2 also received cyclophosphamide. P1, P2 and P3 presented partial remission and P4 complete remission ([Table 1](#)).

Although it is very difficult to prove causation, at the time of this letter there are at least 40 reports of different types of glomerulopathies after receiving the COVID-19 vaccine from different manufacturers (Pfizer, Moderna, AstraZeneca and Sinovac).¹⁻¹⁰ To our knowledge, our reports would be the first related to the Sputnik V (Gamaleya) and BBIBP-CorV (Sinopharm) vaccines. Undoubtedly, the benefits of vaccines far outweigh the risks, but these findings emphasize the importance of surveillance in patients with previous glomerulonephritis and/or the appearance of foamy urine, edemas, hypertension or laboratory abnormalities.

Table 1 – Patient demographics and clinical characteristics.

	Patient 1	Patient 2	Patient 3	Patient 4
<i>Clinical presentation</i>				
Age, yr/gender	38/female	53/male	59/female	67/female
Medical history	Obesity	HBP, overweight	HBP, Obesity, MPG (2015, CR)	Sjögren, MCD (2020, CR)
Vaccine/manufacturer	BBIBP-CorV/Sinopharm	ChaAdOx1 nCoV-19/Oxford-AstraZeneca	Gam-COVID-Vac or Sputnik V/Gamaleya	Gam-COVID-Vac or Sputnik V/Gamaleya
Dose (1st/2nd)	1st	1st	1st	1st
Days between vaccine and onset	7	10	14	6
Symptoms or signs	Asthenia, foamy urine.	Asthenia, foamy urine, edemas.	Foamy urine, edemas.	Foamy urine.
BP, mm Hg	160/100	152/94	158/96	136/78

Table 1 – (Continued)

	Patient 1	Patient 2	Patient 3	Patient 4
Laboratory results				
Serum creatinine, mg/dl	1.74	3.07	1.24	1.03
Urinary sediment	Hb+, protein+++	Hb+++, protein+++	Hb+, protein+++	Hb+
UPCR, g/g	9.37	4.43	5.53 (0.06 prior to vaccination)	0.44 (0.05 prior to vaccination)
Serum albumin, g/dl	2.8	2.9	2.5	–
Dyslipidemia	Yes	Yes	Yes	No
Immunological studies	ENA+	All negative	ANA homogeneous (1/160)	–
Histopathology report				
Glomeruli (G)	8 G; Non globally sclerosed. Diffuse proliferative GN with endocapillary hypercellularity and one cellular crescent.	13 G; 5 globally sclerosed. Diffuse crescentic GN with 62% fibrocellular crescents. Mesangial and endocapillary hypercellularity.	16 G; 1 globally sclerosed. Focal proliferative GN	(Biopsy 2020) 4 G; All with preserved size, morphology and cellularity.
Tubules and interstitium	Mild IFTA. Mild interstitial inflammation with foamy cells.	Mild acute tubular injury. Moderate IFTA. Mild interstitial inflammation.	Non-significant IFTA. Mild interstitial inflammation.	Non-significant IFTA.
Vessels	Mild intimal fibrosis.	Mild intimal fibrosis.	Mild intimal fibrosis.	Mild intimal fibrosis.
IF	Dominant glomerular IgA staining	Dominant glomerular IgA staining	No evidence of deposits	No evidence of deposits
Electron microscopy	–	–	Glomerular membranes moderately thickened. Podocytes with severe and diffuse pedicellar fusion.	Podocytes with severe and diffuse pedicellar fusion.
Treatment	CS+CP	CS+CP	CS	CS
Follow up	PR	PR	PR	CR

ANA, antinuclear antibodies; CP, cyclophosphamide; CR, complete remission; CS, corticosteroids; ENA, antibodies against extractable nuclear antigens; GN, glomerulonephritis; HBP, high blood pressure; Hb, hemoglobin; IFTA, interstitial fibrosis and tubular atrophy; MPG, mesangial proliferative glomerulonephritis; MCD, minimal change disease; PR, partial remission; UPCR, urine protein-to-creatinine ratio.

Funding

This work has not received any type of funding.

Conflict of interest

The author declares that he has no conflict of interest.

Appendix A. Supplementary data

Supplementary data associated with this article can be found, in the online version, at [doi:10.1016/j.nefro.2021.09.007](https://doi.org/10.1016/j.nefro.2021.09.007).

REFERENCES

- Bomback AS, Kudose S, D'Agati VD. De novo and relapsing glomerular diseases after COVID-19 vaccination: what do we know so far? *Am J Kidney Dis.* 2021. S0272-6386(21)00697-1.
- Hanna C, Hernandez LPH, Bu L, et al. IgA nephropathy presenting as macroscopic hematuria in 2 pediatric patients after receiving the Pfizer COVID-19 vaccine. *Kidney Int.* 2021;100:705–6.
- Park K, Miyake S, Tai C, Tseng M, Andeen NK, Kung VL. Letter regarding: “a case of gross hematuria and IgA nephropathy flare-up following SARS-CoV-2 vaccination”. *Kidney Int Rep.* 2021;6:2246–7.
- Anupama YJ, Patel RG, Vankalakunti M. Nephrotic syndrome following ChAdOx1 nCoV-19 vaccine against SARS-CoV-2. *Kidney Int Rep.* 2021;6:2248.

5. Gillion V, Jadoul M, Demoulin N, Aydin S, Devresse A. Granulomatous vasculitis after the AstraZeneca anti-SARS-CoV-2 vaccine. *Kidney Int.* 2021;100:706–7.
6. Gueguen L, Loheac C, Saidani N, Khatchatourian L. Membranous nephropathy following anti-Covid-19 mRNA vaccination. *Kidney Int.* 2021, <http://dx.doi.org/10.1016/j.kint.2021.08.006>.
7. Villa M, Díaz-Crespo F, Pérez de José A, Verdalles U, Verde E, Almeida Ruiz F, et al. A case of ANCA-associated vasculitis after AZD1222 (Oxford-AstraZeneca) SARS-CoV-2 vaccination: Casuality or causality? *Kidney Int.* 2021;100:937–8, <http://dx.doi.org/10.1016/j.kint.2021.07.026>.
8. Plasse R, Nee R, Gao S, Olson S. Acute kidney injury with gross hematuria and IgA nephropathy after COVID-19 vaccination. *Kidney Int.* 2021, <http://dx.doi.org/10.1016/j.kint.2021.07.020>.
9. Tuschen K, Bräsen JH, Schmitz J, Vischedyk M, Weidemann A. Relapse of class V lupus nephritis after vaccination with COVID-19 mRNA vaccine. *Kidney Int.* 2021, <http://dx.doi.org/10.1016/j.kint.2021.07.019>.
10. Da Y, Goh GH, Khatri P. A case of membranous nephropathy following Pfizer-BioNTech mRNA vaccine against coronavirus 2019. *Kidney Int.* 2021, <http://dx.doi.org/10.1016/j.kint.2021.07.016>.

Pehuén Fernández^{a,b,*}, María Luján Alaye^a,
María Emilia García Chiple^{b,c}, Javier De Arteaga^{a,b,d},
Walter Douthat^{a,b,d}, Jorge De La Fuente^{a,b,d},
Carlos Chiurchiu^{a,b,d}

^a Servicio de nefrología, Hospital Privado Universitario de Córdoba, Córdoba, Argentina

^b Instituto Universitario de Ciencias Biomédicas de Córdoba (IUCBC), Córdoba, Argentina

^c Servicio de anatomía patológica, Hospital Privado Universitario de Córdoba, Córdoba, Argentina

^d Fundación Nefrológica de Córdoba, Córdoba, Argentina

*Corresponding author.

E-mail address: pehuenfernandez@hotmail.com
(P. Fernández).

2013-2514/© 2021 Sociedad Española de Nefrología. Published by Elsevier España, S.L.U. This is an open access article under the CC BY-NC-ND license (<http://creativecommons.org/licenses/by-nc-nd/4.0/>).

<https://doi.org/10.1016/j.nefro.2021.09.007>